

# Rotterdam artery-vein segmentation (RAV) dataset

Jose Vargas Quiros<sup>1,2</sup>, Bart Liefers<sup>1,2</sup>, Karin van Garderen<sup>1,2</sup>, Jeroen Vermeulen<sup>1,2</sup>, Eyened Reading Center<sup>1,2</sup>, and Caroline Klaver<sup>1,2,3,4</sup>

<sup>1</sup>Department of Ophthalmology, Erasmus University Medical Center, Rotterdam, the Netherlands

<sup>2</sup>Department of Epidemiology, Erasmus University Medical Center, Rotterdam, the Netherlands

<sup>3</sup>Department of Ophthalmology, Radboud University Medical Center, Nijmegen, the Netherlands

<sup>4</sup>Institute of Molecular and Clinical Ophthalmology, University of Basel, Switzerland

Word count:

Keywords: cfi preprocessing, color fundus imaging, algorithms

## ABSTRACT

**Purpose:** To provide a diverse, high-quality dataset of color fundus images (CFIs) with detailed artery-vein (A/V) segmentation annotations, supporting the development and evaluation of machine learning algorithms for vascular analysis in ophthalmology.

**Methods:** CFIs were sampled from the longitudinal Rotterdam Study (RS), encompassing a wide range of ages, devices, and capture conditions. Images were annotated using a custom interface that allowed graders to label arteries, veins, and unknown vessels on separate layers, starting from an initial vessel segmentation mask. Connectivity was explicitly verified and corrected using connected component visualization tools.

**Results:** The dataset includes 1024x1024-pixel PNG images in three modalities: original RGB fundus images, contrast-enhanced versions, and RGB-encoded A/V masks. Image quality varied widely, including challenging samples typically excluded by automated quality assessment systems, but judged to contain valuable vascular information.

**Conclusion:** This dataset offers a rich and heterogeneous source of CFIs with high-quality segmentations. It supports robust benchmarking and training of machine learning models under real-world variability in image quality and acquisition settings.

**Translational Relevance:** By including connectivity-validated A/V masks and diverse image conditions, this dataset enables the development of clinically applicable, generalizable machine learning tools for retinal vascular analysis, potentially improving automated screening and diagnosis of systemic and ocular diseases.

# Introduction

The retinal vasculature offers a unique and non-invasive window into the human body's microcirculation. Morphological characteristics of retinal blood vessels, such as their caliber, tortuosity, and branching patterns, serve as important biomarkers for systemic health<sup>1,2</sup>. Deviations in vascular metrics have been robustly linked to a variety of systemic conditions, including hypertension, cardiovascular disease, and stroke<sup>3-5</sup>. More recently, these ocular biomarkers have also shown associations with neurodegenerative and psychiatric disorders, such as Alzheimer's disease and schizophrenia<sup>6,7</sup>, further highlighting the potential of *oculomics* in modern medicine<sup>8</sup>.

The accurate measurement of these biomarkers is predicated on the precise segmentation of the vascular tree from color fundus photographs, followed by the correct classification of each vessel segment as either an artery or a vein. Historically, this process was manual or semi-automated, making it labor-intensive and unsuitable for large-scale studies. The advent of deep learning has revolutionized this field, enabling the development of fully automated pipelines for vessel segmentation and classification<sup>9-11</sup>. However, the performance and generalizability of these data-driven models are fundamentally dependent on the availability of large, diverse, and meticulously annotated training datasets. While several datasets for artery-vein segmentation exist, such as RITE (AV-DRIVE)<sup>12</sup> and HRF<sup>13</sup>, the number and size of datasets with specific artery-vein (A/V) labels remains limited.

Table 1 provides a summary of existing A/V segmentation datasets. While these datasets have been instrumental in advancing the field, many are constrained by their relatively small size, a lack of diversity in imaging devices and conditions, or a focus on very specific patient demographics (i.e., macula- or optic disc-centered). A need persists for larger scale datasets with a wider variety of imaging devices, a broad spectrum of common ocular diseases, and both macula- and disc-centered images to foster the development of more robust and generalizable algorithms.

To address these gaps, we introduce the Rotterdam Artery-Vein (RAV) dataset, a large and diverse collection of fundus images with detailed A/V annotations from the population-based Rotterdam Study<sup>14</sup>. The RAV dataset contains 208 retinal fundus images from a well-characterized elderly cohort. Of these, 53 images are made publicly available under a CC license, and an additional 155 images are available upon request for non-commercial use.

**Table 1.** Retinal datasets with artery-vein annotations. (H: Healthy, DR: Diabetic Retinopathy, GC: Glaucoma, NTG: Normal-Tension Glaucoma, HTG: High-Tension Glaucoma, O: Other, M: Macula-centered, OD: Optic Disc-centered, NR: Not Reported).

Dataset	Images	Country	Age (years)	Pathologies	Center	FoV
DRIVE-AV <sup>15</sup>	20	NL	25-90	7 DR, 13 no DR	M	45
RITE <sup>12</sup>	40	NL	25-90	7 DR, 33 no DR	M	45
CHASE DB1 <sup>16</sup>	28	UK	11-13	Healthy children	M	30
Les-AV <sup>17</sup>	22	NR	NR	NR	OD	
HRF-AV <sup>18</sup>	45	GER	NR	15 H, 15 DR, 15 GC	M	45
AVRDB <sup>19</sup>	38	PK	NR	NR	OD	
Leuven-Haifa <sup>20</sup>	240	BE/IL	18-90	75 NTG, 63 HTG, 56H, 30 O	OD	30
Rotterdam (ours)	208	NL	40+	See Figure 1.		

The dataset is characterized by its high diversity, incorporating images from multiple camera systems, a wide range of common ocular pathologies, and a mixture of macula- and optic disc-centered fields of view.

## Methods

### Imaging sources

The dataset consists of images from Dutch cohorts available to the Department of Ophthalmology at Erasmus Medical Center in Rotterdam; mainly the Rotterdam Study (RS). The RS is a prospective population-based cohort study of people living in Ommoord, a district of the city of Rotterdam. The RS consists of four cohorts, all of which were used in this work. The minimum age of study participants varies between >55 in the first cohort and >40 in the fourth. Each cohort was followed for multiple rounds of follow-up examinations every 4 to 5 years. Most of the visits in the RS involved the capture of CFIs on both eyes. Due to the multi-decade span of the RS, multiple devices, capture conditions and fields (macula and disc centered) are present in the dataset.

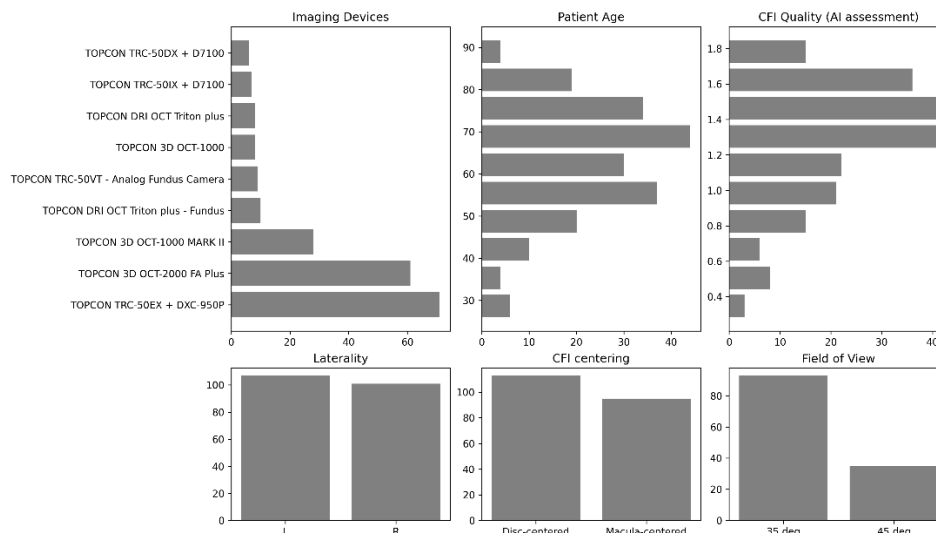


Figure 1. Statistics of the Rotterdam Artery-Vein Segmentation dataset CFIs (208 images)

## Sampling and Quality Control

We sampled CFIs at random from all available images. We included fundus images captured by OCT machines and older analog devices to improve diversity of devices in the dataset. Due to the much larger size of the Rotterdam Study compared to AMD-Life and MYST, we over-sampled CFIs from these sets to make up roughly 15% of the samples. We asked graders to exclude images for which they found the quality to be completely unusable for artery-vein segmentation due to overall low visibility of the vessels. However, we were intentionally inclusive regarding quality to encourage a more diverse and challenging development set. We included images considered unusable by quality estimation algorithms, under the consideration that although the general quality level of these images is poor, many contained clearly usable vascular information for measuring certain biomarkers.

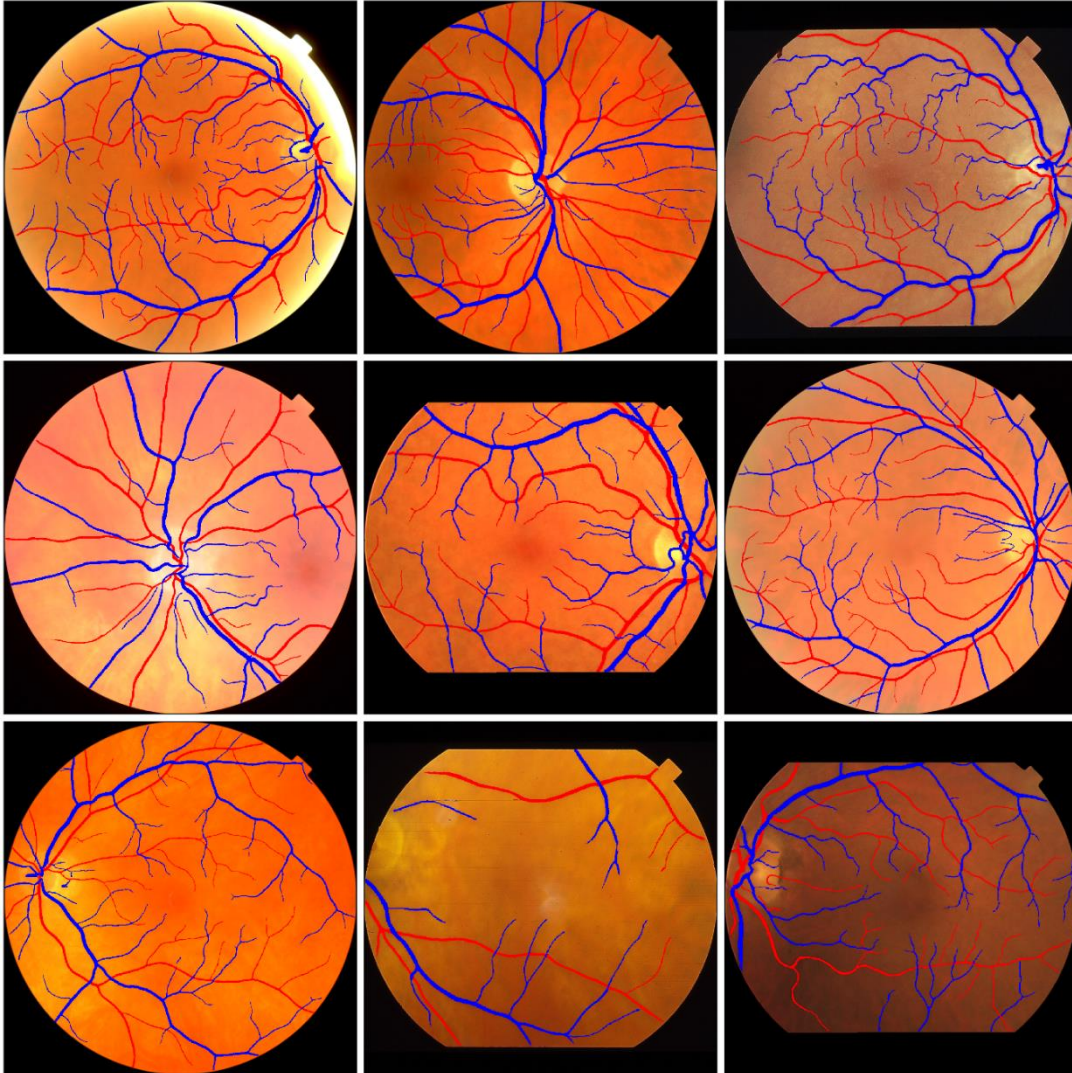
## Human Labelling of Arteries and Veins

Due to the high performance of existing vessel segmentation algorithms (which do not discriminate between arteries and veins), we designed our artery-vein labelling process around the coloring or labelling of vessel segmentation masks. In other words, we *split* the vessel segmentation mask into *Artery* and *Vein* masks. A/V crossings were labelled on both the artery and vein masks; as opposed to labelling only the visible / superior vessel. This allows models trained on the segmentations to potentially resolve the topology of the underlying vascular trees.

An interface was developed specifically for artery-vein segmentation to allow the graders to and color arteries and veins into two independent masks or layers using

drawing tools. A third layer - Unknown was added for vessels that could not be recognized as either. They were able to visualize and correct each layer independently, or all the same time. Another feature allowed them to visualize the connected components of each mask in different colors to easily find mistakes in connectivity. The entire process consisted in:

1. correcting mistakes in the provided mask (vessel segmentation).
2. coloring the mask into A/V and unknown colors/layers
3. verifying connected components on the A/V masks and filling any gaps.



*Figure 2. Sample segmentations from the Rotterdam Artery-Vein segmentation dataset.*

## Data Summary

The data is arranged into three folders, all of which contain PNG files at 1024x1024 pixels with matching names.

**rgb:** preprocessed color fundus images in 1024x1024 resolution. The images were cropped to their circular bounds from their original dimensions for consistency and in some cases to remove identifiers present in the background.

**contrast\_enhanced:** Contrast-enhanced versions via unsharp masking to enhance visibility of the vessels.

**av\_masks:** artery-vein segmentation masks. The masks are encoded in the RGB channels. R = arteries, B = veins, G = unknown

Metadata fields

A metadata file is included with basic information about the images:

**device:** manufacturer and model

**patient\_age:** patient age in years at time of acquisition

**patient\_sex:** M / F

## Technical Validation

We measured inter-rater agreement on our A/V annotation process by asking four graders to label the same independent set of images. To reduce the workload and maintain a sufficient sample of images, we asked the graders to label only a (randomly positioned) window within each CFI, within which we measured agreement in the labelled artery and vein masks, separately. Agreement was measured using both Kappa and mean Dice score between pairs of graders.

*Table 1. Inter-rater agreement between our four graders on artery and vein labelling.*

	Cohen's Kappa	Dice Score
Arteries	0.882	0.906
Veins	0.890	0.899

Note that due to the nature of our labelling process, inter-rater agreement is likely over-estimated when compared to the agreement in a labelling process where images are labelled from scratch, without the aid of a model segmentation.

## Discussion



The RAV dataset is a contribution to the biomedical imaging community by supporting the development and evaluation of better artery-vein segmentation models. Improved segmentation will in turn result in improved calculation of downstream biomarkers. The size and variability in the dataset is likely to support the creation of more robust models that are more likely to generalize to different devices and conditions as shown in [1].

The methodology used to produce the RAV dataset is also an important contribution in enabling the time and cost-efficient annotation of a large CFI dataset, thanks to the initialization with AI-generated vessel segmentations. This allowed us to obtain high quality annotations on a large image set, with human verification to ensure its quality.

We hope that our work with the RAV dataset will encourage researchers to follow our example in publishing larger scale datasets across a wider variety of imaging and patient conditions; thereby supporting the development of the technical work that is necessary in the field.

## Data Repository

The RAV dataset is available at:

<https://dataverse.nl/dataset.xhtml?persistentId=doi:10.34894/9OIMWY>

Of the entire dataset 53 images are publicly available under a CC0 1.0 Universal license. An additional 155 images are available upon request for research purposes under a EULA (End License User Agreement).

All images have been preprocessed to a standardized 1024x1024px resolution.

## Acknowledgments

The authors acknowledge the VascX consortium for supporting this project. The authors are grateful to the study participants and the staff from the Rotterdam Study. This work was funded by the Swiss National Science Foundation grant no. CRSII5 209510.



## References

1. Hubbard L, Brothers R, King W, others. Methods for evaluation of retinal microvascular abnormalities associated with hypertension/sclerosis in the Atherosclerosis Risk in Communities Study. *Ophthalmology*. 1999;106(12):2269-2280.
2. Wong T, Klein R, Klein B, others. Retinal vessel diameters and their associations with age and blood pressure. *Investigative Ophthalmology & Visual Science*. 2002;43(7):2859-2864.
3. Wong T, Islam F, Klein R, et al. Retinal vascular caliber, cardiovascular risk factors, and inflammation: The multi-ethnic study of atherosclerosis (MESA). *Investigative Ophthalmology & Visual Science*. 2006;47:2341-2350. doi:10.1167/iov.05-1539
4. Cheung C, Wong T. Quantitative and qualitative retinal microvascular characteristics and blood pressure. *Journal of Hypertension*. 2011;29:1380-1391. doi:10.1097/HJH.0b013e328347266c
5. Liew G, Wang J, Mitchell P, Wong T. Retinal vascular imaging: a new tool in microvascular disease research. *Circulation: Cardiovascular Imaging*. 2008;1(2):156-161.
6. Frost S, Kanagasingam Y, Macaulay S, others. Retinal vascular biomarkers for early detection and monitoring of Alzheimer's disease. *Translational Psychiatry*. 2013;3:e233.
7. Wagner SK, Cortina-Borja M, Silverstein SM, et al. Association Between Retinal Features From Multimodal Imaging and Schizophrenia. *JAMA Psychiatry*. 2023;80(5):478-487. doi:10.1001/jamapsychiatry.2023.0171
8. Huang Y, Cheung CY, Li D, et al. AI-integrated ocular imaging for predicting cardiovascular disease: advancements and future outlook. *Eye*. 2024;38(3):464-472. doi:10.1038/s41433-023-02724-4
9. Isensee F, Jaeger PF, Kohl SA, Petersen J, Maier-Hein KH. nnU-Net: a self-configuring method for deep learning-based biomedical image segmentation. *Nature methods*. 2021;18(2):203-211.
10. Zhou Y, Wagner SK, Chia MA, et al. AutoMorph: Automated Retinal Vascular Morphology Quantification Via a Deep Learning Pipeline. *Translational Vision Science & Technology*. 2022;11(7):12. doi:10.1167/tvst.11.7.12
11. Vargas Quiros J, Liefers B, van Garderen KA, Vermeulen JP, Klaver C. VascX Models: Deep Ensembles for Retinal Vascular Analysis From Color Fundus Images. *Trans Vis Sci Tech*. 2025;14(7):19. doi:10.1167/tvst.14.7.19

12. Hu Q, Abramoff MD, Garvin MK. Automated separation of binary overlapping trees in low-contrast color retinal images. *Med Image Comput Comput Assist Interv.* 2013;16(Pt 2):436-443. doi:10.1007/978-3-642-40763-5\_54
13. Robust Vessel Segmentation in Fundus Images - Budai - 2013 - International Journal of Biomedical Imaging - Wiley Online Library. Accessed September 3, 2025. <https://onlinelibrary.wiley.com/doi/10.1155/2013/154860>
14. Ikram MA, Kieboom BCT, Brouwer WP, et al. The Rotterdam Study. Design update and major findings between 2020 and 2024. *Eur J Epidemiol.* 2024;39(2):183-206. doi:10.1007/s10654-023-01094-1
15. Hu Q, Abramoff MD, Garvin MK. Automated separation of binary overlapping trees in low-contrast color retinal images. *Med Image Comput Comput Assist Interv.* 2013;16(Pt 2):436-443. doi:10.1007/978-3-642-40763-5\_54
16. Muhammad Moazam F, Remagnino P, Hoppe A, et al. CHASE DB1: Retinal Vessel Reference Dataset. Published online 2012. <https://researchdata.kingston.ac.uk/96/>
17. Orlando JI, Barbosa Breda J, van Keer K, Blaschko MB, Blanco PJ, Bulant CA. Towards a Glaucoma Risk Index Based on Simulated Hemodynamics from Fundus Images. In: Frangi AF, Schnabel JA, Davatzikos C, Alberola-López C, Fichtinger G, eds. *Medical Image Computing and Computer Assisted Intervention – MICCAI 2018.* Springer International Publishing; 2018:65-73.
18. Hemelings R, Elen B, Stalmans I, Van Keer K, De Boever P, Blaschko MB. Artery–vein segmentation in fundus images using a fully convolutional network. *Computerized Medical Imaging and Graphics.* 2019;76:101636. doi:10.1016/j.compmedimag.2019.05.004
19. Akbar S, Hassan T, Akram M, Yasin U, Basit I. AVRDB: Annotated Dataset for Vessel Segmentation and Calculation of Arteriovenous Ratio. In: 2017.
20. Van Eijgen J, Fhima J, Billen Moulin-Romsée MI, Behar JA, Christinaki E, Stalmans I. Leuven-Haifa High-Resolution Fundus Image Dataset for Retinal Blood Vessel Segmentation and Glaucoma Diagnosis. *Scientific Data.* 2024;11(1):257. doi:10.1038/s41597-024-03086-6