

ECG-Expert-QA: A Benchmark for Evaluating Medical Large Language Models in Heart Disease Diagnosis

Xu Wang^{1,2}, Jiaju Kang^{2,3,*}, Puyu Han^{2,4}

¹Shandong Jianzhu University ²FUXI AI Lab ³Beijing Normal University
⁴Southern University of Science and Technology

Abstract—We present ECG-Expert-QA, a comprehensive multimodal dataset designed for evaluating diagnostic capabilities in ECG interpretation, integrating real clinical data with systematically generated synthetic cases. The dataset encompasses six fundamental diagnostic tasks, comprising 47,211 meticulously curated question-answer pairs that span a spectrum of clinical scenarios, from basic rhythm analysis to complex case interpretation. By simulating challenging clinical cases through a rigorous medical knowledge-guided process, ECG-Expert-QA not only enhances the availability of annotated diagnostic data but also significantly increases the complexity and diversity of clinical presentations, including rare cardiac conditions and temporal progression patterns. This design enables comprehensive evaluation of medical language models across multiple dimensions, including diagnostic accuracy, clinical reasoning, and knowledge integration. To facilitate global research collaboration, ECG-Expert-QA is available in both Chinese and English versions, with rigorous quality control ensuring linguistic and clinical consistency. The dataset’s challenging diagnostic tasks, which include interpretation of complex arrhythmias, identification of subtle ischemic changes, and integration of clinical context, establish it as an effective benchmark for advancing AI-assisted ECG interpretation and pushing the boundaries of current diagnostic models. Our dataset is open-source and available at <https://github.com/Zaozzz/ECG-Expert-QA>.

Index Terms—Benchmark Dataset, ECG Medical Diagnostics, Evaluation of Medical LLMs, Automated Generation Pipeline

INTRODUCTION

This study systematically investigates the technological advancements and evaluation challenges of multimodal large language models (LLMs) in the field of intelligent electrocardiogram (ECG) diagnosis, proposing innovative solutions. Current research faces three systemic challenges: first, traditional manual evaluation methods suffer from efficiency bottlenecks, with their resource-intensive nature, subjective dependency, and lack of scalability severely constraining large-scale model validation; second, existing datasets exhibit significant deficiencies in case complexity, clinical scenario coverage, and multimodal reasoning capability assessment; third, linguistic homogeneity hinders the validation of applicability in cross-cultural medical settings, particularly lacking in-depth characterization of rare pathological conditions and ethical risks.

Corresponding author: kangjiaju@fuxi-lab.com

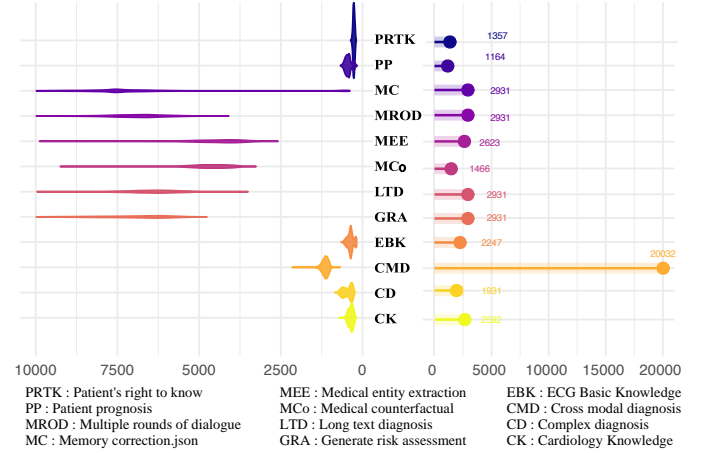


Fig. 1. ECG-Expert-QA Generate route

To address these challenges, the ECG-Expert-QA dataset developed in this study achieves multidimensional innovative breakthroughs. Through a hierarchical architecture design, the dataset systematically integrates three core evaluation modules: the basic medical knowledge verification module contains 4,839 samples, covering fundamental cardiovascular theory (2,592 items) and specialized ECG principles (2,247 items); the clinical reasoning evaluation module includes 20,032 cross-modal diagnostic cases, focusing on the model’s comprehensive decision-making capabilities in complex clinical scenarios, including patient prognosis prediction (2,931 cases), multimodal information integration (1,931 cases), and dynamic medical context reasoning (2,931 cases); the risk control module innovatively introduces medical ethics dimensions, establishing a decision safety assessment benchmark for medical AI through 2,931 ethical conflict cases and 1,357 informed consent scenarios.

The innovation of this study is primarily manifested in three aspects: First, it proposes a standardized paradigm of “evaluation as a service,” enabling quantitative assessment of model capabilities through structured task design, with complex diagnostic tasks accounting for 15.3% of total samples, significantly higher than traditional medical datasets.

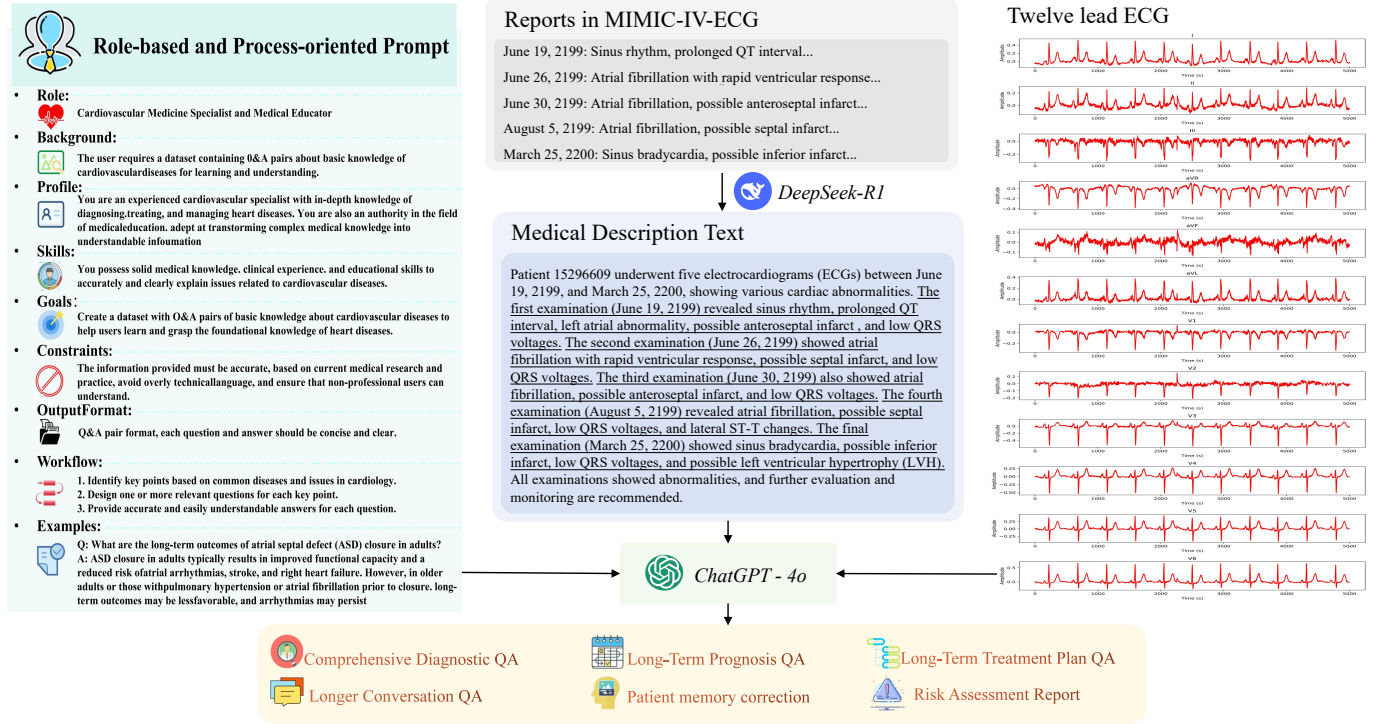


Fig. 2. ECG-Expert-QA Generate route

Second, the construction of a bilingual corpus breaks language barriers, providing a comparable benchmark for cross-cultural medical AI research, though the distribution characteristics of specific language pairs require further clarification in subsequent studies. Third, the introduction of innovative evaluation dimensions such as counterfactual reasoning (1,466 cases) and memory correction mechanisms (2,931 cases) effectively tests the clinical rationality and robustness of model decision logic.

Notably, the dataset exhibits significant interdisciplinary characteristics at the technical implementation level. By integrating the multimodal representation capabilities of natural language processing with the specialized knowledge system of cardiovascular medicine, it not only covers 20,032 cross-modal diagnostic samples but also innovatively designs medical entity extraction tasks (2,931 cases), providing new insights for the development of explainable medical AI. In the ethical dimension, the dataset specifically allocates 2.7% of samples for evaluating model decision safety in medical risk scenarios, representing a nearly 300% increase compared to conventional medical evaluation standards.

Future research directions should focus on enhancing the dynamic evaluation capabilities of the dataset, particularly strengthening validation in temporal data analysis and integration with real clinical workflows. Subsequent studies are recommended to establish quality control protocols for case collection, clarify specific implementation plans for multi-lingual support, and explore domain adaptation mechanisms within continuous learning frameworks. This study provides

important methodological references for building trustworthy medical AI evaluation systems, and its evaluation framework design principles can be extended to other specialized medical fields.

RELATED WORK

The MIT-BIH [1] Arrhythmia Database is an early representative dataset, containing 48 half-hour dual-channel dynamic ECG recordings from 47 patients, covering various types of arrhythmias. The MIT-BIH database is not only the first publicly released standardized ECG test dataset, but also specifically used for evaluating the performance of arrhythmia detection systems. All records were independently annotated by multiple cardiologists. Although the MIT-BIH database has only 48 records and 47 patients, there are certain limitations in data scale, time span, testing equipment, and sample diversity. However, the MIT-BIH database laid an important foundation for the development of subsequent ECG datasets, promoting the release of ECG datasets for various application scenarios and expanding needs.

The MIMIC-IV [2], [3] dataset compensates for the limitations of MIT-BIH in terms of data scale, time span, testing equipment, and sample diversity. This dataset includes a large amount of physiological data and diagnostic information from critically ill patients, although it lacks normal samples, it holds extremely high application value in clinical research. The PTB-XL [4], [5] dataset was constructed by Patrick Wagner and others, containing 21,837 12-lead ECG records, covering

various cardiovascular pathological states, and supplementing the normal samples missing in MIMIC-IV. Furthermore, PTB-XL provides demographic information and signal quality metrics of patients, greatly increasing the quantity and diversity of ECG data.

In MIMIC-IV-V3 [2], [3], the dataset includes 364,627 patients and 94,458 ICU admission records, marking a breakthrough in the volume of ECG datasets. However, despite these datasets providing valuable resources for automated diagnostic models like CNNs [6]–[8] and Transformers [9]–[14], supervised learning methods, which rely on large amounts of annotated data, still face many challenges, especially in terms of generalization across different patient populations and rare ECG patterns, which are significant limitations in real-world clinical applications.

In recent years, multimodal learning has emerged as a powerful paradigm in the medical field, successfully combining medical imaging and textual information. To evaluate and train large multimodal models, datasets like MEDQA [15], created by Di Jin and others, have been constructed based on medical exam question banks to test the model’s medical reasoning ability in multiple-choice formats, enriching the diversity of medical question-answering tasks. However, the application of existing ECG datasets in natural language question answering and multimodal detection remains limited. Although Jungwoo Oh and others constructed the ECG-QA [16] dataset based on PTB-XL [17], [18] and introduced initial question-answering features, its question-answering system still largely relies on framework filling, and the number of question settings is relatively limited. While its design meets the needs of large models for question-answering formats, it still falls short in handling complex diagnostic problems and simulating real interactive scenarios.

To fill this gap, the ECG-Chat [19] and CardioGPT [20], which uses a large scale 12 lead electrocardiogram database [21], [22] for arrhythmia study dataset proposed by Guohua Fu and others focuses on ECG diagnostic tasks, offering large-scale, diversity, and high-quality expert annotations, as well as the use of wavelet scattering networks for feature extraction and the ability to support multi-label classification and complex ECG pattern detection. However, it still lacks multi-round dialog-based question-answering features. To address this, the ECG-Expert-QA dataset innovatively integrates multi-round dialogue structures and patient background information, enabling long-text reasoning in complex clinical scenarios. ECG-Expert-QA not only introduces the first question-answering scenario for simulating ECG diagnostic text generation but also fills the gap in traditional ECG datasets in terms of question-answer interaction functionality. It provides unprecedented support for intelligent diagnosis and dynamic interaction tasks. This dataset, centered around question-answer interactions, deeply integrates multi-round dialogues, patient background, memory correction, and patient rights [23]–[25], breaking through the limitations of single-diagnosis labels and pioneering a new type of intelligent ECG dataset in the question-answering field, greatly expanding the breadth and

depth of model applications.

METHODS

Data Screening

The text descriptions in the dataset come from the MIMIC-IV-ECG [26] dataset and have been filtered based on the dataset’s CSV annotations. The specific steps are as follows:

- **Similarity Calculation:** Cosine similarity from `sklearn.metrics.pairwise` [27], [28] is used to compute text similarity, and data with a similarity greater than 0.8 are excluded to enhance the dataset’s diversity.
- **Report Quantity Screening:** Reports with fewer than four records are excluded to ensure the completeness of the information, thereby enhancing the model’s judgment and training capabilities.
- **Patient Case Summary:** The dataset is organized by patient, with all cases for each patient being aggregated. Only patients with more than four cases are selected, creating comprehensive patient profiles. This method allows the model to analyze data more thoroughly, considering ECG variations at different time points, thus improving its analytical capability [29].

In the end, 2,931 records were selected from 20,000 for subsequent generation tasks. After processing, the dataset’s diversity and completeness have been enhanced. This allows the model to train on more representative samples, considering ECG variations and patient background information, thus improving its judgment and diagnostic accuracy while strengthening its application potential in complex clinical scenarios.

DATASET GENERATION

This study proposes three main dataset generation methods: expert knowledge-guided professional knowledge assessment, cross-modal diagnosis in complex medical environments, and medical risk assessment. Specifically, the expert knowledge-guided method aims to generate professional question-answer pairs by guiding large models with specialized knowledge; cross-modal diagnosis transforms semi-structured data such as electrocardiograms (ECG) into textual descriptions to build diagnostic-related question-answer pairs; medical risk assessment utilizes medical diagnostic results to generate question-answer pairs involving medical counterfactuals, ethical harms, and patient informed rights. Each method employs different input forms and interaction strategies with the model to ensure that the generated datasets effectively support tasks such as knowledge learning in the medical field, pathological reasoning, and multi-turn dialogues. These methods not only significantly enhance the application capabilities of large models in specialized fields but also improve the system’s adaptability and accuracy in complex medical environments.

Expert Knowledge-Guided Professional Knowledge

This method builds a corpus of medical question-answer pairs by conducting continuous dialogues with multiple existing high-quality large language models (LLMs), such as GPT-4. The specific process includes deploying local large models

or utilizing relevant large model APIs, combining professional expert knowledge information, and using the model's programmability and role-based prompting mechanisms to create simulated doctor-patient dialogue scenarios, thereby forming a professional medical knowledge dataset.

- **Basic Cardiology:** Covers fundamental medical knowledge of heart diseases, including cardiac anatomy and function, common types of heart diseases (such as coronary artery disease, heart failure), etiology, symptoms, clinical diagnosis, and treatment methods.
- **Electrocardiogram (ECG) Expertise:** Focuses on ECG analysis, including basic principles, waveform analysis, identification of common abnormalities (such as ventricular premature beats, atrial fibrillation), and clinical applications of ECG.
- **Complex Disease Analysis:** Generates detailed analysis reports for complex cases by simulating multi-turn dialogues between doctors and patients or medical professionals to formulate diagnostic and treatment plans. These dialogues not only accurately analyze symptoms but also provide in-depth decision support for personalized treatment.

By simulating diverse interactions between doctors and patients, professional medical question-answer dialogues are generated, emphasizing the reduction of repetitive outputs and the enhancement of dataset diversity to ensure a rich corpus with clinical application value. The final generated dataset can serve as high-quality training data for medical question-answering and intelligent diagnostic systems, as well as support medical and patient education.

Cross-Modal Diagnosis in Complex Medical Environments

First, preprocess semi-structured data of ECG images (such as 12-lead ECG) and convert them into detailed textual descriptions that explain waveform characteristics, abnormal signals, related clinical symptoms, and potential diagnostic opinions. This step ensures a close association between images and text, laying the foundation for subsequent dataset generation. Next, use local models or API inputs with specified role-based prompts (such as doctor, patient) and leverage the model's powerful language processing capabilities to generate high-quality diagnostic information, forming diverse datasets. Specific applications include:

- **Cross-Modal Diagnosis:** Combines ECG images with textual descriptions to explore the relationships between various abnormal ECG waveforms and potential diagnostic opinions, covering common ECG pathological changes such as arrhythmias and myocardial infarction.
- **Patient Prognosis Analysis:** Generates data for prognosis analysis by describing the current cardiac health status and predicting disease progression or recovery periods based on abnormal signals in the images.
- **Complex Patient Background Reasoning:** Analyzes the impact of multiple factors on patient health through long textual descriptions, such as how chronic diseases like hypertension or diabetes affect ECG interpretation.

- **Medical Consultation Simulation:** Simulates multi-round interactions between doctors and patients where patients ask ECG-related questions and doctors provide professional explanations, forming dialogue datasets beneficial for medical consultations.
- **Memory Adjustment:** Tests the model's ability to modify early diagnoses or explanations based on new information, resolving ambiguities and enhancing memory adjustment in dialogues.
- **Cardiac Entity Extraction:** Uses natural language processing techniques to extract key information from textual descriptions, such as patient history, ECG abnormalities, and symptoms, creating structured datasets.

This method generates cross-modal datasets in the medical field through image descriptions, with a particular focus on ECG image description and analysis. By converting processed semi-structured ECG image data into textual descriptions and combining the model's programmability, role-based prompting, and text generation strategies, datasets covering various application scenarios are formed. These datasets support tasks such as AI-assisted diagnosis, reasoning analysis, and medical consultations.

Medical Risk Assessment

Addressing existing rights issues (such as patient informed consent rights) and medical counterfactuals and ethical issues in diagnostic reports, different dialogue methods are used for dataset generation (multi-turn dialogues for patient informed consent rights; single-turn dialogues for medical counterfactuals and medical ethics). The specific steps include using local models or API inputs with specified role-based prompts (such as doctor, patient) and leveraging the model's language processing capabilities to generate relevant outputs. The main application datasets include:

- **Patient Informed Consent Rights:** Emphasizes patients' fundamental rights in medical decision-making, including the concept of informed consent, legal and ethical issues surrounding patient autonomy, and communication norms between doctors and patients.
- **Medical Counterfactuals:** Hypothetically changes medical decisions (such as treatment plans, medication dosages) to analyze their potential impacts on patient health, providing insights for clinical decision-making.
- **Medical Ethics:** Ensures that generated content complies with ethical standards, assesses risks, and avoids misleading or providing inaccurate medical advice.

The medical risk assessment module generates high-quality question-answer pairs covering patient rights, medical decision-making, and ethical standards by simulating various dialogue scenarios. These datasets not only help train and optimize intelligent medical systems, ensuring higher accuracy and reliability when handling complex ethical and legal issues, but also provide rich educational resources for medical professionals, enhancing their decision-making capabilities and communication skills in real medical environments.

This study constructs high-quality datasets covering extensive medical knowledge and practical application scenarios through three main dataset generation methods: expert knowledge-guided professional knowledge assessment, cross-modal diagnosis in complex medical environments, and medical risk assessment. These datasets not only support medical knowledge learning and pathological reasoning but also enhance training for multi-turn dialogues and ethical risk assessments, significantly improving the application capabilities of large models in specialized medical fields. Additionally, these methods enhance the system’s adaptability and accuracy in complex medical environments. Ultimately, the generated datasets provide a solid data foundation for training and optimizing medical AI systems, promoting the development of intelligent medical technologies, and enhancing the precision of medical services and the effectiveness of patient education.

Role-based and Process-oriented Prompt: In preparing the dataset for large model invocation, we used a Role-based and Process-oriented Prompt design. This approach improves reasoning by guiding models through intermediate steps [30], enhances adaptability and generalizability [31], and enables realistic role simulation by aligning responses with specific knowledge bases [32]. This method balances reasoning, flexibility, and role fidelity, supporting model optimization.

EXPERIMENTS

Evaluation Metrics: Evaluation metrics provide objective means to assess the quality of generated text by comparing it to reference texts. They evaluate aspects such as fluency, semantic accuracy, and content coverage. Below is a concise description of key metrics like BLEU, METEOR, NIST, and ROUGE, highlighting their unique strengths in text evaluation.

- **BLEU (Bilingual Evaluation Understudy):** BLEU is an automated metric for evaluating machine translation output by comparing the generated translation with a set of reference translations. BLEU focuses on precision (how many n-grams in the generated text match n-grams in the reference texts) and applies a brevity penalty to discourage excessively short translations. The idea is that a good translation should contain most of the n-grams from the reference translations without overly repeating words.

Formula:

$$\text{BLEU} = \text{BP} \cdot \exp \left(\sum_{n=1}^N w_n \cdot \log p_n \right)$$

where:

- BP is the Brevity Penalty, which adjusts for translations that are too short. It is computed as:

$$\text{BP} = \begin{cases} 1 & \text{if } c > r \\ \exp \left(1 - \frac{r}{c} \right) & \text{if } c \leq r \end{cases}$$

where c is the length of the candidate (generated) translation, and r is the effective reference length

(usually the closest length to the candidate translation). The penalty ensures that overly short translations are penalized.

- p_n is the precision for n-grams, i.e., the proportion of n-grams in the generated text that also appear in the reference translations.

$$p_n = \frac{\text{Number of matching n-grams}}{\text{Total number of n-grams in the generated translation}}$$

- w_n is the weight for each n-gram, typically set to $w_n = \frac{1}{N}$, where N is the highest n-gram order being considered (e.g., if using 1-gram to 4-gram precision, $N = 4$).

Variants of BLEU:

- **BLEU@1 (1-gram):** Measures precision for single words (1-grams). This metric is useful for evaluating the accuracy of word choices in the generated translation. The precision is calculated as:

$$p_1 = \frac{\text{Number of matching 1-grams}}{\text{Number of 1-grams in the generated translation}}$$

- **BLEU@5 (5-gram):** Measures precision for 5-grams, which are sequences of 5 consecutive words. BLEU@5 places more emphasis on evaluating the fluency and grammatical structure of the generated translation. It ensures that not only individual words but also longer word sequences match the reference translations.

$$p_5 = \frac{\text{Number of matching 5-grams}}{\text{Number of 5-grams in the generated translation}}$$

- **METEOR (Metric for Evaluation of Translation with Explicit ORDERing):** METEOR was developed to address some of the limitations of BLEU, such as its inability to handle synonyms and word order variations. METEOR evaluates translation quality by considering word overlap, synonym matching, stemming (reduction to base forms of words), and word order. METEOR has been shown to correlate better with human judgment than BLEU, especially when it comes to evaluating readability and semantic correctness.

$$\text{METEOR} = F \cdot (1 - \alpha \cdot \text{penalty})$$

where:

- F is the harmonic mean of precision and recall, similar to the F1 score in classification tasks, which combines how many words from the generated translation are correct (precision) and how many relevant words are retrieved (recall).

$$F = \frac{10 \cdot \text{precision} \cdot \text{recall}}{9 \cdot \text{precision} + \text{recall}}$$

- α is a weight factor that controls the influence of the penalty on the final METEOR score. It is typically set to 0.5.
- penalty is a factor that penalizes the translation for word order differences. The more the order of words in the generated text differs from the reference text, the higher the penalty.

- **NIST (National Institute of Standards and Technology):** NIST is a variant of BLEU that is designed to

TABLE I
RESULTS OF ECG PROFESSIONAL KNOWLEDG

Model	BLEU@1	BLEU@5	METEOR	NIST	ROUGE-1	ROUGE-2
ChatGPT-4	0.39929	0.16525	0.43025	1.91089	0.54256	0.34027
ChatGPT-3.5-turbo	0.35547	0.13232	0.39739	1.72209	0.48996	0.28754
Qwen-plus	0.35193	0.11995	0.40641	1.71437	0.48758	0.27560
Claude 3	0.32296	0.10980	0.42207	1.57859	0.47026	0.26265
Llama 3.1 8B	0.31164	0.10625	0.38012	1.58009	0.45439	0.24375
GLM-4-Air	0.36863	0.13040	0.41310	1.77895	0.50769	0.29582
Gemini-Pro	0.35170	0.12934	0.36990	1.66379	0.48297	0.28759
NVIDIA Nemotron	0.27132	0.08588	0.41381	1.32598	0.42868	0.23479
360GPT	0.22092	0.08598	0.25399	1.02528	0.30523	0.18459

handle longer texts better and to provide more informative evaluation by incorporating the "informativeness" of the n-grams. It reduces the weight of common n-grams, allowing the evaluation to focus more on rare and informative n-grams, which is important for domains like technical documents or academic articles.

Formula:

$$\text{NIST} = \sum_{n=1}^N \left(\frac{\log c_n}{\log N} \right) \cdot p_n$$

where:

- c_n is the number of unique n-grams in the reference translation.
- p_n is the precision for n-grams.
- The logarithmic scaling of c_n adjusts the weight based on the frequency of the n-grams, allowing more informative n-grams to have a greater impact on the score.

- **ROUGE (Recall-Oriented Understudy for Gisting Evaluation):** ROUGE is a set of metrics used primarily for evaluating automatic summarization systems, though it is also used for machine translation and other NLP tasks. Unlike BLEU, which emphasizes precision, ROUGE focuses on recall, evaluating how much of the important content in the reference summary is captured by the generated summary.

- **ROUGE-1:** Measures the recall of individual words (1-grams). This metric evaluates how much of the vocabulary from the reference summary is captured in the generated summary.

$$\text{ROUGE-1} = \frac{\sum_{i=1}^n \text{Recall of 1-grams}}{n}$$

- **ROUGE-2:** Measures the recall of 2-grams, which are pairs of consecutive words. ROUGE-2 is more sensitive to the coverage of content and is useful for assessing how well the summary covers the important content of the reference.

$$\text{ROUGE-2} = \frac{\sum_{i=1}^n \text{Recall of 2-grams}}{n}$$

Through these metrics, we can comprehensively evaluate the quality of generated text, ranging from lexical accuracy to

semantic coherence and content coverage. The combined use of these metrics helps to identify the strengths and weaknesses of models, providing valuable information for performance optimization.

Model Selection: Given the computational and financial limitations of this study, we focused our practical tests on a carefully chosen subset of the dataset, specifically targeting professional knowledge related to ECG analysis. This approach allowed us to evaluate the performance of various models under realistic constraints while ensuring relevance to critical medical applications. We selected a diverse range of state-of-the-art market models for evaluation, encompassing both widely recognized and emerging systems, including ChatGPT-4, GLM-4-Air, ChatGPT-3.5-turbo, Qwen-plus, Gemini-Pro, Claude 3, Llama 3.1 8B, NVIDIA Nemotron, 360GPT, and DeepSeek-Chat. This selection reflects a balance of established benchmarks and innovative solutions, providing a comprehensive perspective on their capabilities and limitations within the domain of ECG analysis.

Experiments: We implemented a consistent prompt design across all large models, ensuring uniformity in the input structure. This approach allows for a fair and systematic evaluation by minimizing the variability introduced by prompt differences. The outputs generated by the models were then assessed against our established ground truth data, allowing a precise and objective comparison. This method not only standardizes the evaluation process, but also ensures that performance differences among models can be attributed to their inherent capabilities rather than inconsistencies in input design. By maintaining a consistent input format, we ensure reliable and reproducible results, providing meaningful insights into the strengths and weaknesses of each model.

RESULT

In this study, we constructed the ECG-Expert-QA dataset and evaluated it using various modern medical language models. The experimental results indicate significant differences in the performance of different models on ECG diagnostic tasks. In terms of evaluation metrics such as BLEU@1, METEOR, NIST, and ROUGE-1, ChatGPT-4 performed exceptionally well, particularly in generating medically relevant content, with noticeably higher semantic accuracy and content coverage compared to other models. Additionally, after multiple rounds

of dialogue and clinical reasoning tests, ChatGPT-4 demonstrated strong clinical reasoning capabilities, effectively integrating multimodal information for diagnosis. However, some models (e.g., 360GPT and NVIDIA Nemotron) performed poorly in terms of accuracy and content coverage, especially when dealing with complex ECG patterns. Overall, although current medical AI systems have made significant progress, challenges still remain in diagnosing complex pathologies and rare cases.

CONCLUSION

The ECG-Expert-QA dataset presented in this study not only provides a diversified and challenging evaluation platform but also holds significant importance in testing the diagnostic capabilities, clinical reasoning, and cross-modal information integration of medical language models. When compared with existing medical datasets, this dataset demonstrates unique value through multidimensional testing in pathology analysis, case complexity, and ethical decision-making. Nevertheless, as AI technology advances, future research should focus on enhancing dynamic evaluation capabilities in clinical workflows, optimizing multilingual support, and verifying its applicability in real-world clinical environments. In conclusion, the ECG-Expert-QA dataset provides a crucial reference for building medical AI evaluation systems and contributes to the ongoing development of intelligent medical diagnostic technologies.

REFERENCES

- [1] Moody GB, Mark RG. The impact of the MIT-BIH Arrhythmia Database. *IEEE Engineering in Medicine and Biology Magazine*. 2001;20(3):45-50.
- [2] Johnson A, Bulgarelli L, Pollard T, Gow B, Moody B, Horng S, et al. MIMIC-IV (version 3.1). *PhysioNet*; 2024. Available from: <https://doi.org/10.13026/kpb9-mt58>.
- [3] Johnson AEW, Bulgarelli L, Shen L, Gayles A, Shammout A, Horng S, et al. MIMIC-IV, a freely accessible electronic health record dataset. *Scientific Data*. 2023 jan;10(1):1. Available from: <https://doi.org/10.1038/s41597-022-01899-x>.
- [4] Wagner P, Strodtzoff N, Bousselot R, Samek W, Schaeffter T. PTB-XL, a large publicly available electrocardiography dataset (version 1.0.1). *PhysioNet*; 2020. Available from: <https://doi.org/10.13026/x4td-x982>.
- [5] Wagner P, Strodtzoff N, Bousselot RD, Kreiseler D, Lunze FI, Samek W, et al. PTB-XL, a large publicly available electrocardiography dataset. *Scientific Data*. 2020 may;7(1):154. Available from: <https://doi.org/10.1038/s41597-020-0495-6>.
- [6] Chandra BS, Sastry CS, Jana S. Robust Heartbeat Detection from Multimodal Data via CNN-based Generalizable Information Fusion; 2018. Available from: <https://arxiv.org/abs/1807.03232>.
- [7] Jun TJ, Nguyen HM, Kang D, Kim D, Kim D, Kim YH. ECG arrhythmia classification using a 2-D convolutional neural network; 2018. Available from: <https://arxiv.org/abs/1804.06812>.
- [8] Reasat T, Shahnaz C. Detection of inferior myocardial infarction using shallow convolutional neural networks. In: 2017 IEEE Region 10 Humanitarian Technology Conference (R10-HTC). IEEE; 2017. p. 718–721. Available from: <http://dx.doi.org/10.1109/R10-HTC.2017.8289058>.
- [9] Chen J, Valehi A, Razi A. Predictive Modeling of Biomedical Signals Using Controlled Spatial Transformation; 2018. Available from: <https://arxiv.org/abs/1811.00079>.
- [10] Cheng R, Zhuang Z, Zhuang S, Xie L, Guo J. MSW-Transformer: Multi-Scale Shifted Windows Transformer Networks for 12-Lead ECG Classification; 2023. Available from: <https://arxiv.org/abs/2306.12098>.
- [11] Samanta A, Karlov M, Ravikumar M, Clarke CM, Rajadas J, Hassani K. MVMtNet: A Multi-variate Multi-modal Transformer for Multi-class Classification of Cardiac Irregularities Using ECG Waveforms and Clinical Notes; 2023. Available from: <https://arxiv.org/abs/2302.11021>.
- [12] Thapa S, Howlader K, Bhattacharjee S, le W. MoRE: Multi-Modal Contrastive Pre-training with Transformers on X-Rays, ECGs, and Diagnostic Report; 2024. Available from: <https://arxiv.org/abs/2410.16239>.
- [13] Vaid A, Jiang J, Sawant A, Lerakis S, Argulian E, Ahuja Y, et al. HeartBEiT: Vision Transformer for Electrocardiogram Data Improves Diagnostic Performance at Low Sample Sizes; 2022. Available from: <https://arxiv.org/abs/2212.14040>.
- [14] Zhao Z. Transforming ECG Diagnosis: An In-depth Review of Transformer-based DeepLearning Models in Cardiovascular Disease Detection; 2023. Available from: <https://arxiv.org/abs/2306.01249>.
- [15] Jin D, Pan E, Oufattole N, Weng WH, Fang H, Szolovits P. What Disease does this Patient Have? A Large-scale Open Domain Question Answering Dataset from Medical Exams; 2020. Available from: <https://arxiv.org/abs/2009.13081>.
- [16] Oh J, Lee G, Bae S, myoung Kwon J, Choi E. ECG-QA: A Comprehensive Question Answering Dataset Combined With Electrocardiogram; 2023. Available from: <https://arxiv.org/abs/2306.15681>.
- [17] Wagner P, Strodtzoff N, Bousselot R, Samek W, Schaeffter T. PTB-XL, a large publicly available electrocardiography dataset (version 1.0.1). *PhysioNet*; 2020. Available from: <https://doi.org/10.13026/x4td-x982>.
- [18] Wagner P, Strodtzoff N, Bousselot RD, Kreiseler D, Lunze FI, Samek W, et al. PTB-XL: A Large Publicly Available ECG Dataset. *Scientific Data*. 2020. Available from: <https://doi.org/10.1038/s41597-020-0495-6>.
- [19] Zhao Y, Zhang T, Wang X, Han P, Chen T, Huang L, et al. ECG-Chat: A Large ECG-Language Model for Cardiac Disease Diagnosis; 2024. Available from: <https://arxiv.org/abs/2408.08849>.
- [20] Fu G, Zheng J, Abudayyeh I, Ani C, Rakovski C, Ehwerhemuepha L, et al. CardioGPT: An ECG Interpretation Generation Model. *IEEE Access*. 2024;12:50254-64.
- [21] Zheng J, Guo H, Chu H. A large scale 12-lead electrocardiogram database for arrhythmia study; 2022. *PhysioNet*. Available from: <https://doi.org/10.13026/wgex-er52>.
- [22] Zheng J, Chu H, Struppa D, Zhang J, Yacoub SM, El-Askary H, et al. Optimal Multi-Stage Arrhythmia Classification Approach. *Scientific Reports*. 2020 2;10(1):2898. Available from: <https://doi.org/10.1038/s41598-020-59821-7>.
- [23] Cai Y, Wang L, Wang Y, de Melo G, Zhang Y, Wang YF, et al. MedEvalHub: A Large-Scale Chinese Benchmark for Evaluating Medical Large Language Models. In: *Proceedings of the Thirty-Eighth AAAI Conference on Artificial Intelligence (AAAI-2024)*. AAAI; 2024. .
- [24] Liao Y, Meng Y, Liu H, Wang Y, Wang Y. An Automatic Evaluation Framework for Multi-turn Medical Consultations Capabilities of Large Language Models. *arXiv preprint*. 2023.
- [25] Yang Y, Liao Y, Wang Y, Wang L, He L, Zhang Y, et al. GenMedicalEval: A Unified Medical Evaluation Benchmark for Chinese LLMs. *arXiv preprint*. 2023.
- [26] Goldberger AL, Amaral LAN, Glass L, Hausdorff JM, Ivanov PC, Mark RG, et al. PhysioBank, PhysioToolkit, and PhysioNet: Components of a new research resource for complex physiologic signals. *Circulation*. 2000;101(23):e215-20.
- [27] Pedregosa F, Varoquaux G, Gramfort A, Michel V, Thirion B, Grisel O, et al. Scikit-learn: Machine Learning in Python. *Journal of Machine Learning Research*. 2011;12:2825-30. Available from: <https://jmlr.csail.mit.edu/papers/v12/pedregosa11a.html>.
- [28] Zhang J, Marszałek M, Lazebnik S, Schmid C. Local Features and Kernels for Classification of Texture and Object Categories: A Comprehensive Study. *International Journal of Computer Vision*. 2007;73(2):213-38. Available from: <https://hal.archives-ouvertes.fr/hal-00171412/document>.
- [29] Bianchi FM, Livi L, Ferrante A, Milosevic J, Malek M. Time series kernel similarities for predicting Paroxysmal Atrial Fibrillation from ECGs; 2018. Available from: <https://arxiv.org/abs/1801.06845>.
- [30] Wei J, Wang X, Schuurmans D, Bosma M, Ichter B, Xia F, et al. Chain-of-Thought Prompting Elicits Reasoning in Large Language Models; 2023. Available from: <https://arxiv.org/abs/2201.11903>.
- [31] Zhang L, Ergen T, Logeswaran L, Lee M, Jurgens D. SPRIG: Improving Large Language Model Performance by System Prompt Optimization; 2024. Available from: <https://arxiv.org/abs/2410.14826>.
- [32] Zhang B, Huang Y, Cui W, Zhang H. Thinking Before Speaking: A Role-playing Model with Mindset; 2024. Available from: <https://arxiv.org/abs/2409.13752>.

ECG Basic Knowledge

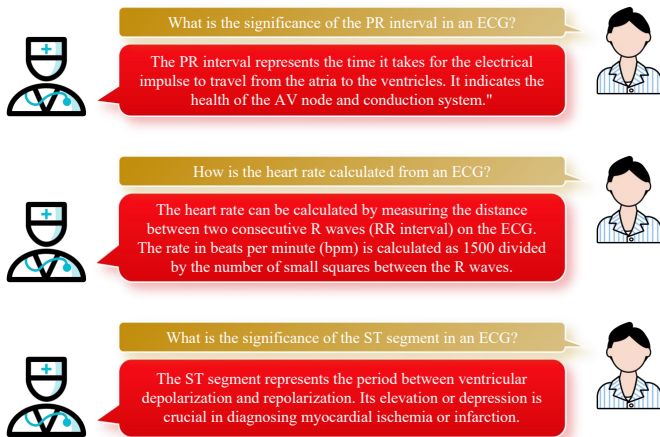


Fig. 3. Data display of ECG Basic Knowledge

Patient's right to know

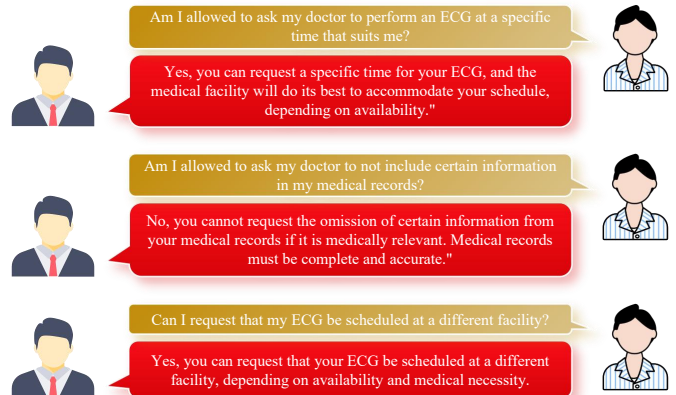


Fig. 4. Data display of Patient's right to know

Complex diagnosis

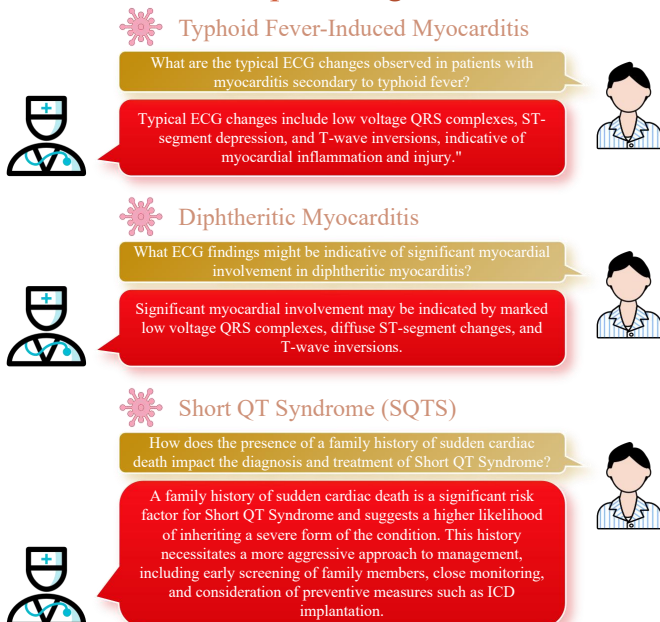


Fig. 5. Data display of Complex diagnosis

Patient prognosis

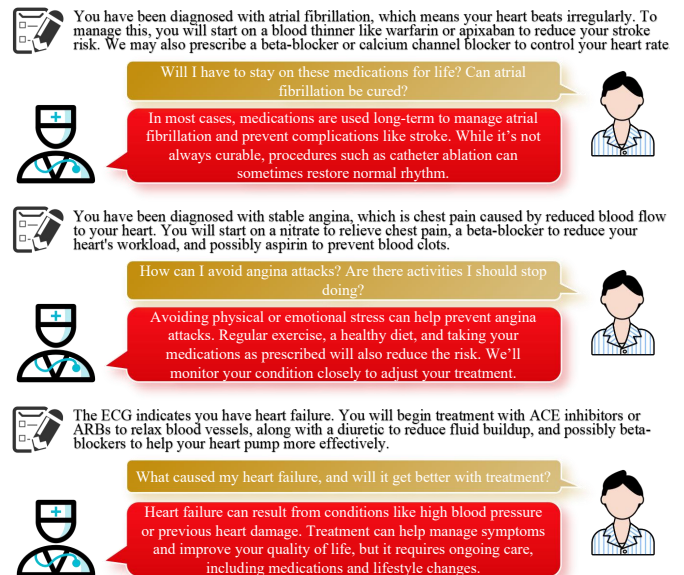


Fig. 6. Data display of Patient prognosis

Cross modal diagnosis



Reports in MIMIC-IV-ECG

Is there any abnormality in the electrocardiogram? Can you explain it in detail?

Your electrocardiogram (ECG) shows a sinus rhythm, which is a normal heart rhythm. However, there is a possible right atrial abnormality, which suggests that the right atrium of your heart may not be functioning normally. The ECG is also borderline, meaning that some results are not clearly normal or abnormal. This could indicate a potential issue that needs further evaluation, such as an atrial enlargement or other cardiac condition.



Reports in MIMIC-IV-ECG

Could you explain what my ECG results suggest and what actions I should consider next?

Your ECG shows a sinus rhythm with an rS' pattern in lead V1, which is likely a normal variant. The QRS voltages are low in the precordial leads, and the overall assessment is borderline. This ECG does not indicate any specific disease but suggests close monitoring due to the borderline nature.



Reports in MIMIC-IV-ECG

What's the heart's activity travel itinerary that this ECG is mapping?

The ECG shows a sinus rhythm with extensive T wave changes, which could indicate myocardial ischemia or myocardial infarction. The rhythm is regular, but the abnormalities in the T waves suggest significant cardiac distress. This pattern is consistent with myocardial infarction.



Cardiology Knowledge

What are the long-term outcomes of atrial septal defect (ASD) closure in adults?

ASD closure in adults typically results in improved functional capacity and a reduced risk of atrial arrhythmias, stroke, and right heart failure. However, in older adults or those with pulmonary hypertension or atrial fibrillation prior to closure, long-term outcomes may be less favorable, and arrhythmias may persist.



How does the management of hypertrophic obstructive cardiomyopathy (HOCM) differ from non-obstructive hypertrophic cardiomyopathy?"

In HOCM, the goal is to relieve left ventricular outflow tract obstruction, often with medications like beta-blockers, calcium channel blockers, or disopyramide. In refractory cases, surgical myectomy or alcohol septal ablation may be required. Non-obstructive hypertrophic cardiomyopathy focuses more on symptom relief and preventing sudden cardiac death with the use of medications and, in some cases, implantable cardioverter-defibrillators (ICDs)."



What is the role of fractional flow reserve (FFR) in the management of coronary artery disease?

FFR is an invasive measurement used to assess the physiological significance of coronary artery stenoses. FFR-guided decision-making helps to determine whether a coronary lesion should be revascularized, with revascularization typically recommended if FFR is below 0.80, indicating reduced blood flow to the myocardium."



Fig. 7. Data display of Cross modal diagnosis

Fig. 8. Data display of Cardiology Knowledge

ECG-Expert-QA report:

Patient 15296609 underwent five electrocardiograms (ECGs) between June 19, 2199, and March 25, 2200, showing various cardiac abnormalities. The first examination (June 19, 2199) revealed sinus rhythm, prolonged QT interval, left atrial abnormality, possible anteroseptal infarct, and low QRS voltages. The second examination (June 26, 2199) showed atrial fibrillation with rapid ventricular response, possible septal infarct, and low QRS voltages. The third examination (June 30, 2199) also showed atrial fibrillation, possible anteroseptal infarct, and low QRS voltages. The fourth examination (August 5, 2199) revealed atrial fibrillation, possible septal infarct, low QRS voltages, and lateral ST-T changes. The final examination (March 25, 2200) showed sinus bradycardia, possible inferior infarct, low QRS voltages, and possible left ventricular hypertrophy (LVH). All examinations showed abnormalities, and further evaluation and monitoring are recommended.



Comprehensive Diagnostic QA:

Comprehensive Diagnostic QA:
"Q": "What are the key cardiac abnormalities observed in Patient 15296609 over the five ECGs conducted between June 19, 2199, and March 25, 2200?"
"A": "The key cardiac abnormalities observed in Patient 15296609 include: Sinus Rhythm and Prolonged QT Interval: Observed in the first ECG on June 19, 2199, indicating a normal sinus rhythm but with an abnormally prolonged QT interval, which can be associated with an increased risk of arrhythmias. Left Atrial Abnormality: Also noted in the first ECG, suggesting possible left atrial enlargement or dysfunction. Anteroseptal Infarct and Inferior T Wave Changes: The first ECG also showed an anteroseptal infarct (age undetermined) and nonspecific inferior T wave changes, which could indicate previous myocardial injury or ischemia. Generalized Low QRS Voltages: Present in all ECGs, suggesting potential myocardial damage or infiltrative cardiomyopathy. Atrial Fibrillation with Rapid Ventricular Response: Observed in the second, third, and fourth ECGs, indicating a rapid and irregular heart rate due to atrial fibrillation, which can lead to poor cardiac output and increased risk of stroke. Possible Septal Infarct: Noted in the second, third, and fourth ECGs. Lateral ST-T Changes: Seen in the fourth ECG, which may indicate myocardial ischemia or injury in the lateral wall of the heart. Sinus Bradycardia and Possible Inferior Infarct: Observed in the final ECG on March 25, 2200, indicating a slow heart rate and possible infarct in the inferior wall of the heart. QRS Changes in V3/V4: Noted in the final ECG, which may be due to left ventricular hypertrophy (LVH) or other structural changes."



Longer Conversation QA:

"Q": "What are the main cardiac abnormalities observed in my ECGs?"
"A": "The main cardiac abnormalities observed in your ECGs include sinus rhythm, prolonged QT interval, left atrial abnormality, anteroseptal and inferior infarcts (age undetermined), inferior T wave changes, generalized low QRS voltages, atrial fibrillation with rapid ventricular response, lateral ST-T changes, and sinus bradycardia. These findings suggest a complex cardiac condition that may involve multiple areas of the heart."
"Q": "What does a prolonged QT interval indicate?"
"A": "A prolonged QT interval on an ECG can indicate an increased risk of abnormal heart rhythms, particularly torsades de pointes, which is a type of ventricular tachycardia. This condition can be life-threatening and may require medical intervention to correct."
"Q": "What are the implications of atrial fibrillation with a rapid ventricular response?"
"A": "Atrial fibrillation with a rapid ventricular response means that the heart's upper chambers (atria) are beating irregularly and rapidly, which can lead to a fast and irregular heartbeat in the lower chambers (ventricles). This condition can increase the risk of stroke, heart failure, and other complications. It may require medication or other interventions to control the heart rate and rhythm."
"Q": "What are the potential causes of the infarcts observed in my ECGs?"
"A": "The infarcts observed in your ECGs, both anteroseptal and inferior, suggest areas of the heart muscle that have been damaged due to reduced blood flow. This could be due to blockages in the coronary arteries, which supply blood to the heart muscle. The exact cause would need to be determined through further diagnostic tests, such as coronary angiography."
"Q": "What are the possible treatments for my condition?"
"A": "The treatment for your condition.....



Long-Term Prognosis QA:

"Q": "What are the potential long-term complications and prognosis for Patient 15296609 based on the observed cardiac abnormalities?"
"A": "The potential long-term complications and prognosis for Patient 15296609 include: Increased Risk of Arrhythmias: The prolonged QT interval and atrial fibrillation observed in multiple ECGs increase the risk of potentially life-threatening arrhythmias such as ventricular tachycardia or fibrillation. Heart Failure: The presence of low QRS voltages, infarcts, and possible LVH suggests a higher risk of developing heart failure, which can lead to symptoms such as shortness of breath, fatigue, and fluid retention. Stroke: Atrial fibrillation significantly increases the risk of stroke due to the formation of blood clots in the atria, which can embolize to the brain. Recurrent Myocardial Infarction: Given the history of infarcts and ischemic changes, there is a risk of recurrent myocardial infarction, which can further damage the heart muscle and worsen heart function. Cardiomyopathy: The rapid ventricular response in atrial fibrillation can lead to tachycardia-induced cardiomyopathy, which may improve with rate control but could persist if not managed effectively. Prognosis: The overall prognosis is guarded due to the multiple cardiac abnormalities and the risk of serious complications. However, with appropriate management and regular follow-up, the patient may experience improved quality of life and reduced risk of adverse events. Close monitoring and timely intervention are crucial to managing the patient's condition and preventing further deterioration."



Patient memory correction:

"Initial conversation between doctor and patient": "Doctor: Good morning, Mr. 15296609. I have reviewed your ECG records from the past year. Can you tell me if you have experienced any chest pain, shortness of breath, or palpitations recently? Patient: Yes, I have had some chest pain, especially when I exert myself. It feels like a pressure on my chest, and it usually goes away after I rest. Doctor: How long have you been experiencing this chest pain? Patient: It started about six months ago, but it has been getting more frequent lately. Doctor: Have you noticed any changes in your heart rhythm? For example, do you feel your heart skipping beats or racing? Patient: Yes, sometimes my heart feels like it's racing, and I can feel it pounding in my chest. It's quite unsettling.....
"Patient memory correction": "Doctor: Mr. 15296609, I noticed that your first ECG showed a prolonged QT interval and left atrial abnormality. Can you recall if you had any specific symptoms around that time? Patient: Oh, I remember now. I had some palpitations around that time, and I felt a bit dizzy. I didn't think much of it at the time. Doctor: Thank you for the clarification. That information is very helpful." "doctor adjusts diagnosis based on new information": "Doctor: Based on your recent symptoms and the ECG findings, it appears that you may have a history of myocardial infarction, particularly in the anteroseptal and inferior regions. The ECGs also show atrial fibrillation and low QRS voltages, which could indicate underlying heart disease. Patient: Is that serious? What does that mean for me? Doctor: It does suggest that you have some significant cardiac issues. We will need to conduct further tests to confirm the diagnosis and determine the best course of treatment. Doctor: Have you ever been diagnosed with high blood pressure or diabetes? Patient: Yes, I have.....



Long-Term Treatment Plan QA:

"Q": "What is the recommended long-term treatment plan for Patient 15296609 based on the observed cardiac abnormalities?"
"A": "The recommended long-term treatment plan for Patient 15296609 includes: Rate Control in Atrial Fibrillation: Given the presence of atrial fibrillation with a rapid ventricular response in multiple ECGs, medications such as beta-blockers (e.g., metoprolol) or calcium channel blockers (e.g., diltiazem) should be considered to control the heart rate and prevent tachycardia-induced cardiomyopathy. Anticoagulation: Due to the presence of atrial fibrillation, anticoagulation therapy with warfarin or a direct oral anticoagulant (DOAC) like apixaban or rivaroxaban is recommended to reduce the risk of stroke. Antiarrhythmic Therapy: If atrial fibrillation persists and is symptomatic, antiarrhythmic drugs such as amiodarone or sotalol may be considered to maintain sinus rhythm. Management of Ischemic Heart Disease: Given the presence of infarcts and ST-T changes, lifestyle modifications (e.g., smoking cessation, diet, exercise) and medications such as aspirin, statins, and ACE inhibitors or ARBs should be considered to manage ischemic heart disease and reduce the risk of further cardiac events. Monitoring and Follow-Up: Regular follow-up with ECGs, echocardiograms, and stress tests to monitor for changes in heart function, arrhythmias, and ischemia. Additionally, regular blood tests to monitor anticoagulation levels and renal function. Symptomatic Management: If the patient experiences symptoms such as chest pain, shortness of breath, or syncope, immediate medical evaluation and management should be pursued."



Risk Assessment Report:

"Patient Overview" Patient 15296609 has undergone five electrocardiograms (ECGs) between June 19, 2199, and March 25, 2200, each revealing various cardiac abnormalities. The patient's ECG findings include sinus rhythm, atrial fibrillation, prolonged QT interval, left atrial abnormality, infarcts (anteroseptal, septal, inferior), inferior T wave changes, generalized low QRS voltages, and lateral ST-T changes.
1. Atrial Fibrillation (AF): - Present in multiple ECGs, indicating a significant arrhythmia. - AF increases the risk of thromboembolism, particularly stroke. - Rapid ventricular response in AF can lead to hemodynamic instability.
2. Infarcts: - Possible anteroseptal, septal, and inferior infarcts, with age undetermined. - Infarcts suggest previous myocardial damage, which can predispose to further ischemic events.
.....
Suggested Clinical Actions:
1. Anticoagulation Therapy: - Given the atrial fibrillation, anticoagulation therapy (e.g., warfarin, direct oral anticoagulants) is recommended to reduce the risk of stroke.
2. Cardiac Monitoring: - Continuous cardiac monitoring to detect and manage any arrhythmias, especially given the prolonged QT interval.
.....
Conclusion: Patient 15296609 presents with multiple significant cardiac abnormalities, including atrial fibrillation, infarcts, and a prolonged QT interval, placing them at high risk for thromboembolism, arrhythmias, and cardiac decompensation. Immediate clinical intervention, including anticoagulation therapy, cardiac monitoring.....

Fig. 9. Data display of patient 15296609

ECG-Expert-QA report:

Patient 15772179 underwent eight ECGs between April 2, 2151, and February 11, 2153, all showing cardiac abnormalities. The first test revealed sinus rhythm with bigeminal PVCs, left axis deviation, an undetermined-age inferior infarct, and lateral ST-T changes. Subsequent tests showed atrial fibrillation, sinus tachycardia, IV conduction defects, demand pacing, atrial pacing, borderline first-degree A-V block, and extensive ST-T changes. The final ECG on February 11, 2153, indicated a possible ectopic atrial rhythm with PVCs, poor R wave progression, and an abnormal ECG.



Comprehensive Diagnostic QA:

"Q": "What are the key cardiac abnormalities observed in Patient 15772179 across the eight ECGs conducted between April 2, 2151, and February 11, 2153?"
"A": "The key cardiac abnormalities observed in Patient 15772179 include: Sinus rhythm with bigeminal PVCs and left axis deviation in the first ECG. Atrial fibrillation with rapid ventricular response, leftward axis, poor R wave progression, inferior lateral ST-T changes and possible left ventricular hypertrophy in the second ECG. Sinus tachycardia, left axis deviation, IV conduction defect, QRS changes V3/V4, and lateral ST-T changes in the third ECG. Undetermined rhythm, demand pacing, demand atrial pacing, and sinus rhythm with borderline 1st degree A-V block in subsequent ECGs. Possible ectopic atrial rhythm with PVC(s), IV conduction defect, poor R wave progression, extensive ST-T changes and abnormal ECG in the final ECG."



Longer Conversation QA:

"Q": "What does the term sinus rhythm mean in my ECG results?"
"A": "Sinus rhythm indicates that your heart is beating in a normal, regular pattern, which originates from the sinoatrial (SA) node, the natural pacemaker of the heart....."
"Q": "What are bigeminal PVCs and how do they affect my heart?"
"A": "Bigeminal PVCs refer to premature ventricular contractions (PVCs) that occur in pairs. This means that every other heartbeat is a PVC, which can cause irregularities in your heart rhythm....."
"Q": "What does left axis deviation mean, and is it serious?"
"A": "Left axis deviation means that the electrical axis of your heart is tilted more to the left than normal. This can be caused by various factors, including left ventricular hypertrophy, left anterior fascicular block, or other structural heart abnormalities....."
"Q": "What are inferior infarct - age undetermined and lateral ST-T changes?"
"A": "Inferior infarct - age undetermined suggests that there may have been a previous heart attack (myocardial infarction) affecting the inferior (bottom) part of your heart, but it is unclear when this occurred....."



Long-Term Prognosis QA:

"Q": "Based on the comprehensive diagnosis, what should be the primary components of the long-term treatment plan for Patient 15772179?"
"A": "The long-term treatment plan for Patient 15772179 should include: Antiarrhythmic therapy to manage atrial fibrillation and premature ventricular contractions (PVCs). Beta-blockers or calcium channel blockers to control heart rate and rhythm, especially in cases of sinus tachycardia and rapid ventricular response. ACE inhibitors or ARBs to manage possible left ventricular hypertrophy and improve cardiac function. Coronary artery disease management to address inferior and lateral ST-T changes, including lifestyle modifications, statins, and possibly revascularization if indicated. Pacemaker implantation if the patient continues to experience conduction defects or bradycardia, as suggested by the borderline 1st degree A-V block and demand pacing. Regular follow-up ECGs and cardiac monitoring to track the progression of abnormalities and adjust treatment as necessary."



Patient memory correction:

"Initial conversation between doctor and patient": "Doctor: Good morning, Mr. 15772179. I have reviewed your ECG records from the past few years. Can you tell me if you have experienced any chest pain, shortness of breath, or palpitations recently? Patient: Yes, I've been having some chest pain, especially when I exert myself. It feels like a tightness in my chest. Doctor: How long have you been experiencing this chest pain?" "Patient memory correction": "Patient: Wait, I just remembered something. I actually had a really bad episode of chest pain around that time. It was so severe that I had to stop what I was doing and sit down. Doctor: Thank you for sharing that. That's important information. Can you describe the severity of the chest pain during that episode? Patient: It was very intense, like an elephant was sitting on my chest. It lasted for about 10 minutes before it started to ease up. Doctor: Did you take any medication or seek medical attention during that episode? Patient: No, I didn't take anything. I just waited for it to pass."



Long-Term Treatment Plan QA:

"Q": "What are the potential long-term complications and prognosis for Patient 15772179 based on the observed cardiac abnormalities?"
"A": "The potential long-term complications and prognosis for Patient 15772179 include: Increased risk of arrhythmias, including atrial fibrillation and PVCs, which can lead to palpitations, syncope, and in severe cases, cardiac arrest. Progression of left ventricular hypertrophy and heart failure, particularly if the inferior and lateral ST-T changes worsen or if coronary artery disease is not adequately managed. Conduction system abnormalities, such as the IV conduction defect and borderline 1st degree A-V block, which may necessitate pacemaker implantation and increase the risk of bradycardia-related symptoms. Cardiovascular events, including myocardial infarction and stroke, particularly if atrial fibrillation persists and leads to thromboembolic events. Overall prognosis is guarded, with a need for close monitoring and aggressive management of risk factors to prevent complications and improve quality of life."
Risk Assessment Report:
"Patient History and ECG Findings" Multiple ECG Examinations: The patient underwent eight ECGs over a period of approximately two years, each showing various cardiac abnormalities. Initial ECG (April 2, 2151, ID: 40737557): Sinus rhythm with bigeminal PVCs, left axis deviation, inferior infarct (age undetermined), and lateral ST-T ECG. Key Risk Factors Identified: Atrial Fibrillation: Present in multiple ECGs. Potential Risk Assessment: High Risk of Cardiovascular Events: Atrial Fibrillation: Increases the risk of stroke and heart failure. Left Ventricular Hypertrophy: Indicates increased cardiac load and risk of heart failure. Inferior Infarct: Suggests a history of myocardial injury, increasing the risk of future infarctions. Lateral ST-T Changes: Indicate ongoing ischemia or myocardial injury. Suggested Clinical Actions: Immediate Actions: Cardiac Ultrasound (Echocardiogram): To evaluate left ventricular size, function, and wall thickness. Transthoracic Echocardiography (TTE): To rule out atrial thrombus in the setting of atrial fibrillation. Holter Monitoring: To assess the frequency and pattern of PVCs and atrial fibrillation.....

Fig. 10. Data display of patient 15772179

ECG-Expert-QA report:

Patient 12294203 underwent eight ECGs between October 16, 2164, and July 9, 2166, all showing cardiac abnormalities. The first test indicated sinus bradycardia, prolonged QT interval, left anterior fascicular block, IV conduction defect, and left ventricular hypertrophy. Subsequent tests revealed sinus arrhythmia, ectopic atrial bradycardia, left axis deviation, QRS changes due to left ventricular hypertrophy, and various ST-T abnormalities. The final ECG on July 9, 2166, showed possible ectopic atrial rhythm, left axis deviation, QRS changes, left ventricular hypertrophy, and lateral ST-T changes associated with hypertrophy.



Comprehensive Diagnostic QA:

"Q": "What are the key cardiac abnormalities observed in Patient 12294203 over the course of their eight ECGs?"
"A": "The key cardiac abnormalities observed in Patient 12294203 include: Sinus Bradycardia: Present in multiple ECGs, indicating a slow heart rate. Prolonged QT Interval: Observed in the first ECG. Suggesting a risk of arrhythmias. Left Axis Deviation: Present in several ECGs. Indicating a possible left ventricular hypertrophy or conduction defect. Left Ventricular Hypertrophy (LVH): Consistently noted, with QRS changes in V3/V4 and lateral ST-T changes due to hypertrophy. Conduction Defect: Seen in the first and second ECGs, suggesting a block in the intraventricular conduction system. Ectopic Atrial Rhythm: Observed in multiple ECGs, indicating irregular atrial activity."



Longer Conversation QA:

"Q": "What do the ECG results indicate about my heart condition?"
"A": "The ECG results indicate a variety of cardiac abnormalities, including sinus bradycardia (a slow heart rate), prolonged QT interval (which can be associated with arrhythmias), left axis deviation (a shift in the electrical axis of the heart), and left ventricular hypertrophy (enlargement and thickening of the left ventricle). These findings suggest that your heart is working under significant strain and may be at risk for more serious arrhythmias or heart failure."
"Q": "What are the potential causes of these abnormalities?"
"A": "The causes of these abnormalities can be multifactorial. Left ventricular hypertrophy, for example, can be due to high blood pressure, aortic valve disease, or genetic factors. Sinus bradycardia and prolonged QT interval can be related to electrolyte imbalances, certain medications, or underlying heart conditions. Left axis deviation can be due to structural heart disease or conduction system abnormalities."
"Q": "Do I need further diagnostic tests to confirm these findings?"
"A": "Yes, further diagnostic tests are necessary to confirm these findings and to understand the underlying causes. These may include echocardiograms to assess the structure and function of your heart, stress tests to evaluate how your heart performs under physical stress, and possibly a cardiac MRI or CT scan for more detailed imaging."
"Q": "What treatment options are available for my condition?"
"A": "Treatment options will depend on the underlying causes and the severity of your condition. This may include medications to manage blood pressure, reduce the risk of arrhythmias, or improve heart function. In some cases, lifestyle changes such as dietary modifications, exercise, and stress management may be recommended. If the condition is severe, surgical interventions such as valve repair or replacement, or even heart transplantation, may be considered."



Long-Term Prognosis QA:

"Q": "What is the recommended long-term treatment plan for Patient 12294203 based on their cardiac abnormalities?"
"A": "The recommended long-term treatment plan for Patient 12294203 includes: Beta-Blockers: To manage sinus bradycardia and reduce the risk of arrhythmias. ACE Inhibitors or ARBs: To manage left ventricular hypertrophy and improve heart function. Antiarrhythmics: To control ectopic atrial rhythms and reduce the frequency of PACs and PVCs. Diuretics: To manage any associated fluid overload due to left ventricular hypertrophy. Regular Monitoring: Frequent ECGs and echocardiograms to monitor the progression of LVH and any changes in conduction defects. Lifestyle Modifications: Encourage a heart-healthy diet, regular exercise, and avoidance of stimulants like caffeine and nicotine."



Patient memory correction:

"Initial conversation between doctor and patient": "Doctor: Good morning, Mr. 12294203. I have your ECG results here. Can you tell me how you've been feeling lately? Any chest pain, shortness of breath, or palpitations? Patient: Good morning, Doctor. I've been feeling a bit tired lately, especially after physical activities. I do get some chest discomfort, but it's not severe. I also feel my heart racing sometimes, but it goes away quickly."
"patient memory correction": "Doctor: Just to clarify, you mentioned that the chest discomfort started around the time of the second examination on October 28, 2164. Is that correct? Patient: Oh, I think I might have mixed up the dates. The chest discomfort actually started around the time of the third examination on August 27, 2165. I remember because it was right after a particularly stressful project at work. Doctor: Thank you for correcting that. So, the chest discomfort started around August 27, 2165, and you noticed it more during stressful periods. Is that right? Patient: Yes, that's correct."
"doctor adjusts diagnosis based on new information": "Doctor: Based on the new information, it seems that your symptoms, particularly the chest discomfort and palpitations, started around the time of the third examination on August 27, 2165. This aligns with the findings of possible ectopic atrial bradycardia with PAC(s), left axis deviation, QRS changes V3/V4 due to LVH, left ventricular hypertrophy, and inferior/lateral ST-T changes due to hypertrophy. Given this, we should focus on managing these symptoms and monitoring your condition more closely. Patient: Okay, what do you recommend? Doctor: I recommend starting you on a betablocker to help manage the palpitations and reduce the strain on your heart."



Long-Term Treatment Plan QA:

"Q": "What are the potential long-term complications and prognosis for Patient 12294203 given their cardiac abnormalities?"
"A": "The potential long-term complications and prognosis for Patient 12294203 include: Increased Risk of Arrhythmias: Due to prolonged QT interval and ectopic atrial rhythms, there is a higher risk of developing more serious arrhythmias such as atrial fibrillation or ventricular tachycardia. Progression of Left Ventricular Hypertrophy: If not managed effectively, LVH can lead to heart failure, reduced ejection fraction, and decreased quality of life. Conduction System Disorders: The IV conduction defect and left axis deviation could progress to more severe conduction blocks, potentially requiring pacemaker implantation. Cardiovascular Events: Increased risk of cardiovascular events such as myocardial infarction and stroke, particularly if atrial fibrillation persists and leads to thromboembolic events. Overall prognosis is guarded, with a need for close monitoring and aggressive management of risk factors to prevent complications and improve quality of life."



Risk Assessment Report:

Key findings include:
1. Sinus Bradycardia: Present in multiple examinations, indicating a slow heart rate.
2. Prolonged QT Interval: Seen in the first examination, which can increase the risk of arrhythmias.
3. Left Anterior Fascicular Block (LAFB): Indicated in the first examination, suggesting a conduction problem in the heart.
Potential Risk Assessment:
Given the persistent and varied cardiac abnormalities, the patient is at high risk for:
1. Progressive Heart Disease: The presence of LVH and conduction defects suggests ongoing cardiac stress and potential for further deterioration.
2. Arrhythmias: The prolonged QT interval and atrial arrhythmias increase the risk of serious arrhythmias, including ventricular tachycardia or fibrillation.
Suggested Clinical Actions:
1. Cardiac Ultrasound (Echocardiography): To evaluate the structure and function of the heart, particularly the left ventricle.
2. Holter Monitoring: To capture any intermittent arrhythmias that may not be evident on routine ECG.
3. Electrophysiological Study (EPS): If arrhythmias are suspected to be causing significant symptoms or risk.

Fig. 11. Data display of patient 12294203

ECG-Expert-QA report:

Patient 17684034 underwent eight ECGs between June 22, 2135, and October 23, 2137, all showing cardiac abnormalities. The first test suggested possible atrial flutter, left axis deviation, and repolarization changes. Subsequent tests revealed sinus rhythm with PACs, 1st-degree A-V block, prolonged QT interval, ectopic atrial bradycardia, left anterior fascicular block, and left ventricular hypertrophy, along with various ST-T abnormalities. The final ECG on October 23, 2137, showed sinus bradycardia with 1st-degree A-V block, left anterior fascicular block, left ventricular hypertrophy, and lateral ST-T changes.



Comprehensive Diagnostic QA:

"Q": "What are the primary cardiac abnormalities observed in Patient 17684034 over the course of their eight ECGs?"
"A": "The primary cardiac abnormalities observed in Patient 17684034 include: Atrial Arrhythmias: Possible atrial flutter, premature atrial contractions (PACs), ectopic atrial bradycardia, and sinus bradycardia with sinus arrhythmia. Conduction Disturbances: First-degree atrioventricular (A-V) block and left anterior fascicular block. Electrical Axis Deviations: Left axis deviation in multiple ECGs. Repolarization Changes: Lateral ST-T changes and prolonged QT interval. Structural Changes: Left ventricular hypertrophy."



Longer Conversation QA:

"Q": "What are the main cardiac abnormalities observed in my ECGs over the past few years?"
"A": "The main cardiac abnormalities observed in your ECGs include possible atrial flutter, sinus rhythm with premature atrial contractions (PACs), first-degree atrioventricular (A-V) block, left axis deviation, left anterior fascicular block, lateral ST-T changes, left ventricular hypertrophy, and prolonged QT interval. These findings suggest a complex cardiac condition that requires careful monitoring and management."
"Q": "What does left ventricular hypertrophy mean, and how does it affect my heart?"
"A": "Left ventricular hypertrophy (LVH) means that the muscle wall of your left ventricle, the main pumping chamber of your heart, has thickened. This can occur in response to increased workload on the heart, such as high blood pressure or aortic valve disease. LVH can lead to decreased heart function over time and increase the risk of heart rhythm disturbances and heart failure."
"Q": "What are the potential causes of these abnormalities?"
"A": "The potential causes of these abnormalities could include underlying heart disease, such as hypertension, coronary artery disease, or valvular heart disease. Additionally, genetic factors, lifestyle choices (such as diet and exercise), and other medical conditions (like diabetes) could contribute to these findings."
"Q": "Do I need further tests to confirm the diagnosis and assess the severity of my condition?"
"A": "Yes, further tests are necessary to confirm the diagnosis and assess the severity of your condition. These may include echocardiograms to visualize the heart structure and function, stress tests to evaluate how your heart performs under physical activity, and possibly cardiac catheterization if there is suspicion of coronary artery disease."



Long-Term Prognosis QA:

"Q": "What treatment strategies should be considered for Patient 17684034 to manage their cardiac abnormalities?"
"A": "The treatment strategies for Patient 17684034 should include: Rate Control: Medications such as beta-blockers or calcium channel blockers to manage bradycardia and control heart rate. Antiarrhythmic Therapy: Medications like amiodarone or sotalol to manage atrial arrhythmias and prevent atrial flutter or PACs. Conduction System Support: Monitoring and possibly medications to manage A-V block and left anterior fascicular block. Repolarization Management: Consideration of medications such as potassium supplements or magnesium to address prolonged QT intervals. Regular Monitoring: Frequent ECGs and echocardiograms to monitor the progression of LVH, conduction defects,....



Patient memory correction:

"Initial conversation between doctor and patient": "Doctor: Good morning, Mr. 17684034. I have reviewed your ECG records from the past few years. Can you tell me if you have experienced any symptoms related to your heart, such as chest pain, palpitations, or shortness of breath? Patient: Yes, I have had some chest discomfort, especially after physical activity. I also feel my heart racing sometimes, but it usually goes away after a few minutes. Doctor: I see. Have you noticed any pattern or triggers for these symptoms? For example, do they occur more frequently at certain times of the day or after specific activities? Patient: It seems to happen more in the evening, especially after I've been sitting for a long time. I also notice it more when I'm stressed,...."
"patient memory correction": "Doctor: Just to clarify, you mentioned that your symptoms seem to occur more in the evening and after sitting for a long time. Did you say that you also experience these symptoms after physical activity? Patient: Oh, I think I mispoke earlier. Its actually more common after physical activity, not just sitting. I feel the chest discomfort and racing heart more after I exercise,...."
"conclusion": "Doctor: Your welcome, Mr. 17684034. Well schedule your next appointment in a month to review your progress. In the meantime, please keep track of your symptoms and any changes in how you feel. If you experience any severe symptoms or have concerns, dont hesitate to contact us immediately. Take care, and well see you soon. Patient: Thank you, Doctor. Ill keep an eye on my symptoms and follow up as needed. Doctor: Great. Have a good day, and take care. Patient: You too. Goodbye."



Long-Term Treatment Plan QA:

"Q": "What are the potential long-term complications and prognosis for Patient 17684034 given their cardiac abnormalities?"
"A": "The potential long-term complications and prognosis for Patient 17684034 include: Progression of Arrhythmias: There is a risk of the atrial arrhythmias progressing to more severe forms, such as atrial fibrillation, which could increase the risk of stroke. Heart Failure: Left ventricular hypertrophy and conduction disturbances could lead to heart failure over time. Overall prognosis is guarded, with a need for close monitoring and aggressive management of risk factors to prevent complications and improve quality of life."



Risk Assessment Report:

Risk Assessment Report for Patient 17684034 Risk Factor Analysis: The patient has undergone eight electrocardiograms (ECGs) over a period of two years, each showing various cardiac abnormalities.
Key findings include:
1. Atrial Flutter/Ectopic Atrial Bradycardia: The first ECG showed possible atrial flutter, while subsequent ECGs showed irregular ectopic atrial bradycardia. These arrhythmias can increase the risk of thromboembolism and stroke.
2. Left Axis Deviation: Persistent left axis deviation is noted in multiple ECGs, indicating possible left anterior fascicular block (LAFB). LAFB is associated with left ventricular hypertrophy (LVH) and can lead to conduction abnormalities.
Potential Risk Assessment: Given the multiple cardiac abnormalities observed in the ECGs, the patient is at high risk for the following:
1. Progressive Heart Disease: The consistent findings of LVH and LAFB suggest ongoing cardiac remodeling and potential progression to heart failure.
2. Arrhythmias: The presence of atrial flutter, ectopic atrial bradycardia, and prolonged QT interval increases the risk of life-threatening arrhythmias.
Suggested Clinical Actions:
1. Cardiac Imaging: Echocardiography: To assess the structure and function of the heart, particularly the left ventricle. Transesophageal Echocardiography (TEE): To rule out atrial thrombus, especially given the atrial arrhythmias.
2. Electrophysiological Studies: - Electrophysiological Study (EPS): To evaluate the conduction system and risk of arrhythmias.

Fig. 12. Data display of patient 17684034

Medical entity extraction

"Patient 15947954 underwent seven electrocardiograms (ECGs) between July 30, 2150 and November 2, 2154, each showing various cardiac abnormalities. The first examination on July 30, 2150 (ID: 40609744) showed sinus rhythm with QRS changes in V3/V4 possibly due to left ventricular hypertrophy (LVH) and secondary repolarization abnormality. Technical details include P starting at 40ms, P ending at 144ms, QRS starting at 212ms, QRS ending at 310ms, T ending at 604ms, P axis at 77, QRS axis at 9, T axis at 131. The second examination on August 20, 2150 (ID: 46493743) showed sinus bradycardia with borderline 1st degree AV block, prolonged QT interval, and left ventricular hypertrophy. The measured values are P starting at 40ms, P ending at 104ms, QRS starting at 240ms, QRS ending at 350ms, T ending at 730ms, P axis at 31, QRS axis at 12, T axis at 163. The third examination on August 24, 2150 (ID: 47850272) showed atrial fibrillation with rapid ventricular response, leftward axis, anteroseptal infarct of undetermined age, and LVH with secondary repolarization abnormality. The measured values are P starting at 29999ms, P ending at 29999ms, QRS starting at 196ms, QRS ending at 308ms, T ending at 560ms, P axis at 29999, QRS axis at -24, T axis at 154. The fourth examination on August 25, 2150 (ID: 49460385) showed undetermined rhythm, left axis deviation, left bundle branch block, and possible inferior infarct of undetermined age. The measured values are P starting at 29999ms, P ending at 29999ms, QRS starting at 114ms, QRS ending at 288ms, T ending at 458ms, P axis at 29999, QRS axis at +41, T axis at 146. The fifth examination on October 30, 2154 (ID: 44744646) showed atrial fibrillation with slow ventricular response, prolonged QT interval, left ventricular hypertrophy, and tall T waves possibly indicating acute ischemia or hyperkalemia. The measured values are P starting at 29999ms, P ending at 29999ms, QRS starting at 200ms, QRS ending at 306ms, T ending at 736ms, P axis at 29999, QRS axis at -3, T axis at 135. The sixth examination on October 31, 2154 (ID: 41295454) showed atrial fibrillation with rapid ventricular response, QRS changes in V3/V4 possibly due to LVH, inferior/lateral ST-T changes likely due to hypertrophy or ischemia, and tall T waves possibly indicating acute ischemia or hyperkalemia. The measured values are P starting at 29999ms, P ending at 29999ms, QRS starting at 94ms, QRS ending at 200ms, T ending at 402ms, P axis at 29999, QRS axis at 7, T axis at -178. The seventh examination on November 2, 2154 (ID: 41186778) showed demand atrial pacing, high voltage in limb leads, deep S wave in anteroseptal lead, LVH with secondary repolarization abnormality, and inferior and lateral ST-T changes. The measured values are P starting at 40ms, P ending at 104ms, QRS starting at 136ms, QRS ending at 238ms, T ending at 500ms, P axis at 24, QRS axis at -2, T axis at 145

"Entity": "Electrocardiograms (ECGs)", "Type": "Diagnostic Procedure"	"Entity": "Echocardiograms", "Type": "Diagnostic Procedure"	"Entity": "Possible inferior infarct", "Type": "Cardiac Condition"
"Entity": "Cardiac abnormalities", "Type": "Medical Condition"	"Entity": "Stress tests", "Type": "Diagnostic Procedure"	"Entity": "Inferior/lateral ST-T changes", "Type": "Cardiac Abnormality"
"Entity": "Left ventricular hypertrophy (LVH)", "Type": "Medical Condition"	"Entity": "Halter monitors", "Type": "Diagnostic Procedure"	"Entity": "Tall T waves", "Type": "Cardiac Abnormality"
"Entity": "Secondary repolarization abnormality", "Type": "Medical Condition"	"Entity": "Chest pain", "Type": "Symptom"	"Entity": "Acute ischemia", "Type": "Cardiac Condition"
"Entity": "Sinus bradycardia", "Type": "Medical Condition"	"Entity": "Shortness of breath", "Type": "Symptom"	"Entity": "Hyperkalemia", "Type": "Medical Condition"
"Entity": "Borderline 1st degree AV block", "Type": "Medical Condition"	"Entity": "Dizziness", "Type": "Symptom"	"Entity": "Demand atrial pacing", "Type": "Cardiac Treatment"
"Entity": "Prolonged QT interval", "Type": "Medical Condition"	"Entity": "Changes in heart rhythm", "Type": "Symptom"	"Entity": "High voltage in limb leads", "Type": "Cardiac Abnormality"
"Entity": "Atrial fibrillation", "Type": "Medical Condition"	"Entity": "Sinus rhythm with QRS changes", "Type": "Cardiac Abnormality"	"Entity": "Deep S wave in anteroseptal lead", "Type": "Cardiac Abnormality"
"Entity": "Rapid ventricular response", "Type": "Medical Condition"	"Entity": "Left ventricular hypertrophy (LVH)", "Type": "Cardiac Condition"	"Entity": "Medications", "Type": "Treatment"
"Entity": "Slow ventricular response", "Type": "Medical Condition"	"Entity": "Secondary repolarization abnormality", "Type": "Cardiac Abnormality"	"Entity": "Lifestyle changes", "Type": "Recommendation"
"Entity": "Anteroseptal infarct", "Type": "Medical Condition"	"Entity": "Sinus bradycardia", "Type": "Cardiac Abnormality"	"Entity": "Dietary changes", "Type": "Recommendation"
"Entity": "Demand atrial pacing", "Type": "Medical Condition"	"Entity": "Borderline 1st degree AV block", "Type": "Cardiac Abnormality"	"Entity": "Regular physical activity", "Type": "Recommendation"
"Entity": "High blood pressure", "Type": "Risk Factor"	"Entity": "Prolonged QT interval", "Type": "Cardiac Abnormality"	"Entity": "Healthy weight", "Type": "Recommendation"
"Entity": "Heart rhythm problems", "Type": "Complication"	"Entity": "Atrial fibrillation", "Type": "Cardiac Abnormality"	"Entity": "Stress management", "Type": "Recommendation"
"Entity": "Heart failure", "Type": "Complication"	"Entity": "Rapid ventricular response", "Type": "Cardiac Abnormality"	"Entity": "Smoking cessation", "Type": "Recommendation"
"Entity": "Torsades de pointes", "Type": "Complication"	"Entity": "Slow ventricular response", "Type": "Cardiac Abnormality"	"Entity": "Alcohol moderation", "Type": "Recommendation"
"Entity": "Pacemaker", "Type": "Medical Device"	"Entity": "Leftward axis", "Type": "Cardiac Abnormality"	"Entity": "Follow-up ECGs", "Type": "Monitoring"
"Entity": "Catheter ablation", "Type": "Treatment"	"Entity": "Anteroseptal infarct", "Type": "Cardiac Condition"	"Entity": "Long-term prognosis", "Type": "Outcome"
"Entity": "Echocardiograms", "Type": "Diagnostic Procedure"	"Entity": "Left bundle branch block", "Type": "Cardiac Abnormality"	"Entity": "Heart failure", "Type": "Complication"

Fig. 13. Data display of Medical entity extraction

Medical counterfactual

Original Case Data:

The third examination on August 24, 2150 (ID: 47850272) showed atrial fibrillation with rapid ventricular response, leftward axis, anteroseptal infarct of undetermined age, and LVH with secondary repolarization abnormality. The measured values are P starting at 29999ms, P ending at 29999ms, QRS starting at 196ms, QRS ending at 308ms, T ending at 566ms, P axis at 29999 ~, QRS axis at -24 ~, and T axis at 154 ~.

Modified Case Data:

The third examination on August 24, 2150 (ID: 47850272) showed atrial fibrillation with rapid ventricular response, leftward axis, anteroseptal infarct of undetermined age, and LVH with secondary repolarization abnormality. The measured values are P starting at 40ms, P ending at 104ms, QRS starting at 196ms, QRS ending at 308ms, T ending at 566ms, P axis at 31 ~, QRS axis at -24 ~, and T axis at 154 ~.

Description of Modification:

The modification was made to the P wave duration and P axis values. The original values for P starting and ending were both 29999ms, and the P axis was 29999 ~. These were changed to P starting at 40ms, P ending at 104ms, and P axis at 31 ~.

Impact Assessment:

Yes, the modification affects the diagnosis and treatment recommendations.

- Original Data Analysis: The original data indicated an abnormal P wave duration and axis, which were both set to 29999ms and 29999 ~, respectively. This is clearly an error or placeholder value, which could lead to misinterpretation of the ECG results.

- Modified Data Analysis: The modified data now shows a more realistic P wave duration (40ms to 104ms) and a P axis of 31 ~, which is within a normal range. This change corrects the error and provides more accurate information about the patient's cardiac rhythm.

Suggested Modification:

The original data should be corrected to reflect the modified values, as the original values were clearly erroneous. The corrected data will provide a more accurate basis for diagnosis and treatment planning.

Reason

The P wave duration and axis are critical components of ECG interpretation. Incorrect values can lead to misdiagnosis, particularly in conditions like atrial fibrillation where the P wave may be absent or irregular. Correcting these values ensures that the ECG results are interpreted accurately, which is essential for appropriate clinical decision-making.

Fig. 14. Data display of Medical counterfactual