

LARGE-SCALE AND FINE-GRAINED VISION-LANGUAGE PRE-TRAINING FOR ENHANCED CT IMAGE UNDERSTANDING

Zhongyi Shui^{1,3,4} Jianpeng Zhang^{1,3,5} * Weiwei Cao^{1,3,5} Sinuo Wang¹ Ruizhe Guo^{3,4}
Le Lu¹ Lin Yang⁴ Xianghua Ye² Tingbo Liang² Qi Zhang² Ling Zhang¹

¹DAMO Academy, Alibaba Group

²The First Affiliated Hospital of College of Medicine, Zhejiang University, China

³Zhejiang University, China ⁴Westlake University, China ⁵Hupan Lab, 310023, China
jianpeng.zhang0@gmail.com

ABSTRACT

Artificial intelligence (AI) shows great potential in assisting radiologists to improve the efficiency and accuracy of medical image interpretation and diagnosis. However, a versatile AI model requires large-scale data and comprehensive annotations, which are often impractical in medical settings. Recent studies leverage radiology reports as a naturally high-quality supervision for medical images, using contrastive language-image pre-training (CLIP) to develop language-informed models for radiological image interpretation. Nonetheless, these approaches typically contrast entire images with reports, neglecting the local associations between imaging regions and report sentences, which may undermine model performance and interoperability. In this paper, we propose a fine-grained vision-language model (fVLM) for anatomy-level CT image interpretation. Specifically, we explicitly match anatomical regions of CT images with corresponding descriptions in radiology reports and perform contrastive pre-training for each anatomy individually. Fine-grained alignment, however, faces considerable false-negative challenges, mainly from the abundance of anatomy-level healthy samples and similarly diseased abnormalities, leading to ambiguous patient-level pairings. To tackle this issue, we propose identifying false negatives of both normal and abnormal samples and calibrating contrastive learning from patient-level to disease-aware pairing. We curated the largest CT dataset to date, comprising imaging and report data from 69,086 patients, and conducted a comprehensive evaluation of 54 major and important disease (including several most deadly cancers) diagnosis tasks across 15 main anatomies. Experimental results demonstrate the substantial potential of fVLM in versatile medical image interpretation. In the zero-shot classification task, we achieved an average AUC of 81.3% on 54 diagnosis tasks, surpassing CLIP and supervised methods by 12.9% and 8.0%, respectively. Additionally, on the publicly available CT-RATE and Rad-ChestCT benchmarks, our fVLM outperformed the current state-of-the-art methods with absolute AUC gains of 7.4% and 4.8%, respectively. Code is available at <https://github.com/alibaba-damo-academy/fvlm>

1 INTRODUCTION

Medical image interpretation is a critically important yet exceptionally burdensome task in clinical workflows, particularly when dealing with 3D imaging scans Udare et al. (2022). Radiologists are required to examine hundreds of slices across dozens of anatomies meticulously Blankemeier et al. (2024). As a result, there is a growing demand for versatile and reliable AI to assist in the automated interpretation of medical images for a wide range of diagnostic needs. Supervised learning is a prominent strategy for automating this process, demonstrating remarkable success in natural scene

*Correspondence to Jianpeng Zhang. The work was done during Zhongyi’s internship at DAMO Academy

allenges related to false negatives, primarily arising from the prevalence of anatomy-level healthy samples and similar abnormalities across different diseases, which could result in ambiguous pairings at the patient level. We introduce a simple yet effective method to identify and manage the massive false negatives from both normal and abnormal samples, and advocate for a shift in contrastive learning from a broad patient-level pairing to a more nuanced disease-aware pairing approach.

Due to privacy concerns and the scarcity of quality medical data, the limited availability of vision-language data has been one of the most significant bottlenecks for medical VLMs. To overcome this limitation, we have curated the largest CT dataset to date, named MedVL-CT69K, which includes 272,124 CT scans from 69,086 unique patients and their corresponding diagnostic reports. On this extensive dataset, our fVLM has demonstrated outstanding zero-shot diagnostic capabilities, achieving an average AUC of 81.3% across 54 disease diagnosis tasks, surpassing the competing CLIP model by 12.9% (see Fig. 1 (e)) and the supervised baseline by 8.0%. Moreover, on the publicly available CT-RATE and Rad-ChestCT datasets, our fVLM outperforms the state-of-the-art approach by 7.4% and 4.8% absolute AUC value gains, respectively. Beyond diagnostic tasks, the model also exhibits remarkable proficiency in downstream report-generation tasks. Our key contributions are summarized as follows:

1. We propose a scalable and annotation-free vision-language model, fVLM, for CT image interpretation, which demonstrates strong scaling capabilities to meet a wide range of clinical diagnostic needs.
2. We address the vision-language misalignment issues of VLMs by employing a fine-grained anatomy-level contrastive learning framework.
3. We introduce a dual false negative reduction module to alleviate the adverse effects of false negatives in both normal and abnormal samples.
4. Extensive experiments on a large-scale in-house dataset as well as two public benchmarks demonstrate the advantages of fVLM over the state-of-the-art counterparts.

2 RELATED WORK

2.1 MEDICAL VISION-LANGUAGE PRE-TRAINING

Existing medical vision-language pre-training (Med-VLP) methods primarily focus on 2D images depicting a single body part, notably chest X-rays (CXR). Most of them learn transferable representations by aligning the medical scans and corresponding reports with contrastive loss Zhang et al. (2022); Boecking et al. (2022); Tiu et al. (2022); Huang et al. (2023); Zhou et al. (2023); Zhang et al. (2023b); Lin et al. (2023); Liu et al. (2023b); Bannur et al. (2023); Cheng et al. (2023); Liu et al. (2023a); Lin et al. (2023); Sun et al. (2024); Lu et al. (2024); Christensen et al. (2024). In particular, MedKLIP Wu et al. (2023) and KAD Zhang et al. (2023c) utilize medical domain knowledge to enhance the textual information extraction, thereby improving the contextual understanding of radiology reports. Imitate Liu et al. (2023b) derives multi-level visual features from CXR images and separately aligns these features with descriptive and conclusive text in hierarchical medical reports. Given the paucity of paired image-text data in the medical domain, several studies have investigated data-efficient Med-VLP. Notably, MedCLIP Wang et al. (2022b) and PTUnifier Chen et al. (2023) use unpaired CXR images and reports for multimodal pre-training. Pairaug Xie et al. (2024) designs a pairwise augmentation approach that scales up the training data by manipulating existing image-report pairs or generating entirely new cases. Beyond inspecting a single body part, recent studies have expanded the scope of VLP to encompass broader anatomical structures within high-detail 3D CT images Cao et al. (2024); Hamamci et al. (2024); Bai et al. (2024); Lin et al. (2024); Blankemeier et al. (2024), enabling more comprehensive diagnostic support in clinical practice. Specifically, BIUD Cao et al. (2024) and CT-CLIP Hamamci et al. (2024) align chest CT volumes and radiology reports. Merlin Blankemeier et al. (2024) focuses on abdomen scenarios and incorporates structured electronic health record (EHR) data as additional supervision.

While existing Med-VLP studies have demonstrated decent performance, they predominantly employ a global alignment scheme that contrasts entire images and reports Zhang et al. (2022); Tiu et al. (2022), overlooking the local similarities or disparities between image patches and report pieces. This oversight can result in a misalignment problem Müller et al. (2022), constraining the

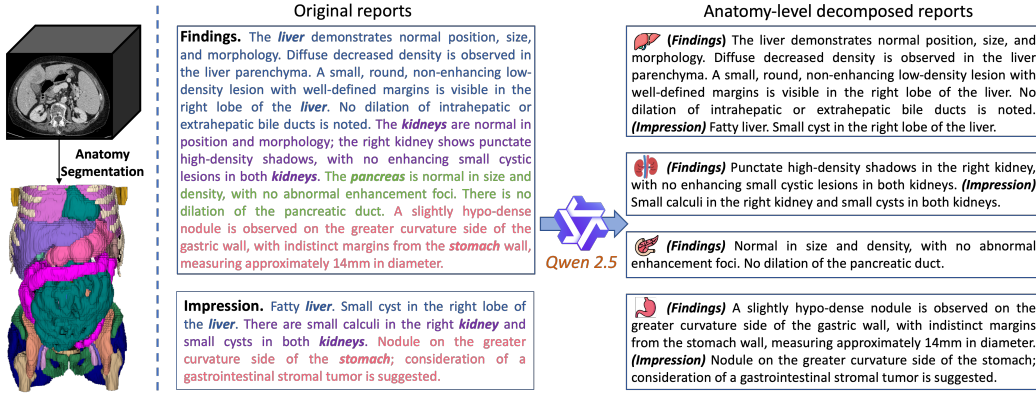


Figure 2: Illustration of CT anatomy parsing (left) and diagnostic report decomposition (right).

model to a coarse-grained understanding and limiting its capacity to capture fine-grained, clinically relevant details.

2.2 FINE-GRAINED ALIGNMENT IN MED-VLP

To address the misalignment challenge, GLoRIA Huang et al. (2021), LoVT Müller et al. (2022) and MGCA Wang et al. (2022a) integrate global contrastive learning with a local alignment technique. They leverage a cross-attention mechanism to implicitly learn fine-grained correspondences between image regions and report sentences within each sample. However, while this implicit local alignment has demonstrated effectiveness for 2D CXR data, we argue that its applicability to 3D CT volumes may be limited due to the dramatically higher data complexity. Specifically, compared to 2D CXR images that involve only a few anatomical anatomies Li et al. (2024b), 3D CT scans typically encompass hundreds of anatomical structures and provide detailed, volumetric views of the human body Wasserthal et al. (2023). This increased imaging complexity enables a deeper analysis of intricate medical conditions while concurrently yielding more extensive and nuanced radiology reports that delineate wide-ranging anatomical features and clinical findings Udare et al. (2022); Blankemeier et al. (2024). Given these distinctions, the endeavor to learn local alignments implicitly, which is already prone to be sensitive to hyper-parameters and difficult to train Müller et al. (2022), becomes exceedingly intractable in CT scenarios.

3 METHOD

3.1 DATA PRE-PROCESSING

Anatomy parsing. We utilize Totalsegmentator to generate detailed anatomical structure masks for 104 regions within CT scans Wasserthal et al. (2023), encompassing organs, bones, muscles, and vessels, as illustrated in Fig. 2. Subsequently, we group these 104 regions into 36 major anatomies to align with the granularity of descriptions in clinical reports, as detailed in Appendix Tab. 6. This grouping is necessary because CT diagnosis reports often lack precise localization of the lesion areas Li et al. (2024a). For instance, the lung is segmented into five distinct lobes in Totalsegmentator Wasserthal et al. (2023), while a report might merely state “lung inflammation” without specifying which lobe is affected. This ambiguity presents a significant challenge in precisely extracting corresponding diagnostic descriptions for each lobe from the report. Furthermore, even when the lesion locations are reported in some cases, the probability of anomalies occurring at a specific fine-grained anatomical site (*i.e.*, right middle lobe) is considerably low, leading to an overwhelming imbalance between normal and abnormal samples for that anatomical structure. As a result, most mini-batches may consist entirely of normal samples, which may skew the training process and impair the model’s diagnostic capability. Overall, anatomical grouping entails a trade-off among analytical granularity, image-text consistency, and data balance.

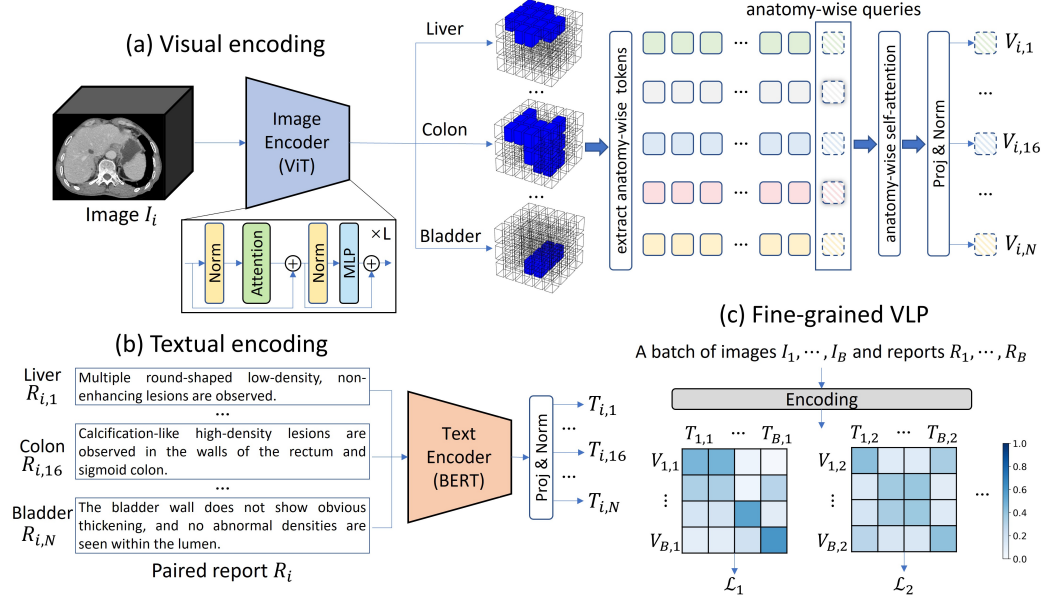


Figure 3: Framework of fVLM. (a) Visual encoding. We input a CT volume I_i into the image encoder and extract corresponding visual tokens for each anatomy. We then append an anatomy-specific query token to the extracted visual tokens of each anatomy. These query tokens are subsequently updated through self-attention, constituting the visual representations of their respective anatomies. N is the number of anatomies. (b) Textual encoding. We decompose the paired report R_i into anatomy-wise descriptions and feed them separately into the text decoder to obtain anatomy-specific textual representation. (c) Fine-grained VLP. We perform local alignment for each individual anatomy across different CT scans. L_j denotes the contrastive loss computed for the j -th anatomy.

Report decomposition. As depicted in Fig. 2, we decompose raw CT diagnostic reports according to the grouped anatomies. To reduce the complexity, we employ a divide-and-conquer strategy, executing the decomposition process for the *findings* and *impression* sections of each report independently, followed by an integration of extracted anatomy-level descriptions. Our approach is delineated in the following three steps. First, we design a prompt (see Appendix Fig. 6) and employ the LLM, Qwen 2.5 Bai et al. (2023), to identify all anatomies mentioned in both sections. Notably, we found that when one section lacks explicit references to some anatomies but instead mentions their anatomical sub-structures or uses medical terminology as referents, the LLM may fail to recognize these anatomies due to insufficient domain knowledge. To mitigate these potential omissions, we employ a complementary string-matching strategy. For instance, the inclusion of terms such as “*jejunum*”, “*ileum*”, or “*duodenum*” in the section will prompt the recognition of “*small intestine*”. Second, we use the LLM to extract anatomy-specific descriptions from both sections, with the prompt detailed in Appendix Fig. 7. Lastly, a simple post-processing is performed to integrate the anatomy-level descriptions extracted from these two sections. Specifically, for each anatomy mentioned in both sections, we concatenate the extracted *findings* content with its corresponding *impression* description. In instances where the anatomy appears in only one section, we supplement the absent component with a “*null*” string before concatenation. If one anatomy is not mentioned in either section, we default its description to “*{anatomy} shows no significant abnormalities.*” based on established clinical practice.

3.2 FINE-GRAINED CONTRASTIVE PRE-TRAINING

Our approach is grounded in the CLIP architecture Radford et al. (2021), which aligns visual and linguistic modalities through contrastive learning of positive and negative pairs. Following Bai et al. (2024); Cao et al. (2024); Lu et al. (2024), we adopt vision transformer (ViT) Dosovitskiy et al. (2020) and BERT Devlin et al. (2018) as the image and text encoder, respectively. Given a CT

volume $I_i \in \mathbb{R}^{1 \times D \times H \times W}$, where D , H and W represent the inter-slice, spatial height and width dimensions respectively, the vision encoder transforms the input into a compact visual embedding $\mathcal{F}_i \in \mathbb{R}^{c \times d \times h \times w}$. For each anatomy, we utilize its segmentation mask $M_{i,j} \in \{0, 1\}^{D \times H \times W}$, where 0 represents the background and 1 denotes the foreground, to guide the construction of anatomy-specific visual representations. Specifically, we begin by partitioning $M_{i,j}$ into non-overlapping patches of size $\frac{D}{d} \times \frac{H}{h} \times \frac{W}{w}$. Each patch spatially corresponds to a visual token in \mathcal{F}_i . Then, we locate the patches that contain foreground elements of $M_{i,j}$ and extract their associated tokens as the visual descriptors of the j -th anatomy. Next, we append a learnable anatomy-wise query token to these extracted tokens and update it via a self-attention layer. Finally, the updated query token is fed into a linear projection layer followed by L2-normalization to generate anatomy-wise visual representation $\mathbf{V}_{i,j}$. Given the irregular sizes of CT images between patients, we employ RandomCrop to facilitate the construction of mini-batches. It is important to note that anatomies truncated by the cropping operation will be overlooked to maintain the integrity of anatomical visual content during contrastive alignment. The absence of this visual information could include critical diagnostic cues, potentially resulting in alignment failures.

Given the image’s associated report R_i , we decompose it into discrete descriptions $R_{i,j}$ for each anatomy, as detailed in Sec. 3.1. Then, we employ the text encoder to transform $R_{i,j}$ into anatomy-specific textual embeddings $\mathbf{T}_{i,j}$. For a mini-batch of images $\{I_1, \dots, I_B\}$ and reports $\{R_1, \dots, R_B\}$, we calculate the softmax-normalized image-to-text and text-to-image similarity as:

$$\mathbf{p}_{i,j,k}^{i2t} = \frac{e^{\langle \mathbf{V}_{i,j}, \mathbf{T}_{k,j} \rangle / \tau}}{\sum_{k'=1}^{N_j} e^{\langle \mathbf{V}_{i,j}, \mathbf{T}_{k',j} \rangle / \tau}}, \quad \mathbf{p}_{i,j,k}^{t2i} = \frac{e^{\langle \mathbf{T}_{i,j}, \mathbf{V}_{k,j} \rangle / \tau}}{\sum_{k'=1}^{N_j} e^{\langle \mathbf{T}_{i,j}, \mathbf{V}_{k',j} \rangle / \tau}} \quad (1)$$

where j denotes anatomy index, N_j is the number of structurally complete samples for the j -th anatomy after RandomCrop, $\langle a, b \rangle$ refers to the cosine similarity between vectors a and b , τ is a learnable temperature parameter. The total loss is computed as:

$$L_{itc} = \frac{1}{2} \left(\sum_{j=1}^T \frac{1}{N_j} \sum_{i=1}^{N_j} (\mathcal{H}(\mathbf{y}_{i,j}^{i2t}, \mathbf{p}_{i,j}^{i2t}) + \mathcal{H}(\mathbf{y}_{i,j}^{t2i}, \mathbf{p}_{i,j}^{t2i})) \right) \quad (2)$$

in which T is the number of anatomy categories, and \mathcal{H} is cross-entropy loss. $\mathbf{y}_{i,j}^{i2t}$ and $\mathbf{y}_{i,j}^{t2i}$ denote ground-truth one-hot similarity, where negative pairs have a probability of 0 and the positive pair has a probability of 1.

3.3 REDUCING FALSE NEGATIVES IN IMAGE-REPORT PAIRS

The core of contrastive-based VLP lies in instance-level pairing, which brings together the vision and language modalities of the same instance while distancing different instances. However, there are often complex semantic relationships between different instances (patients) in medical contexts Hamamci et al. (2024). For example, patients diagnosed as normal are semantically consistent and abnormal samples with the same pathologies also exhibit high semantic similarities. These semantically similar samples constitute false negatives when they co-occur within the same mini-batch during contrastive pre-training, and inadvertently increasing their distances could degrade the diagnostic accuracy of medical VLMs. To address this issue, we propose a dual false negative reduction (FNR) approach that goes beyond instance-level pairing and pursues a more comprehensive understanding of the semantic landscape in medical imaging.

When performing global contrastive learning between entire images and reports Hamamci et al. (2024), a patient sample is diagnosed as normal only if all scanned anatomies are free of abnormalities. Under this definition, the proportion of normal samples is notably low (e.g., 0.2% in MedVL-CT69K). However, in our fine-grained framework, the number of normal cases increases substantially (refer to Appendix Fig. 8) due to the more granular definition of normality at the anatomy level: although a CT examination reveals abnormalities in specific anatomical structures, those unaffected anatomies can still be considered normal based on established clinical protocols. This substantial increase in normal samples leads to a proliferation of false negatives in our fine-grained contrastive learning framework. Moreover, in contrast to the relatively fixed template-style descriptions for entirely normal images Cao et al. (2024), we observe considerable variability in the descriptions for normal cases of each anatomy. As a result, how to identify and cope with these massive normal samples poses a critical challenge in unlocking the full potential of our method. We address this issue by

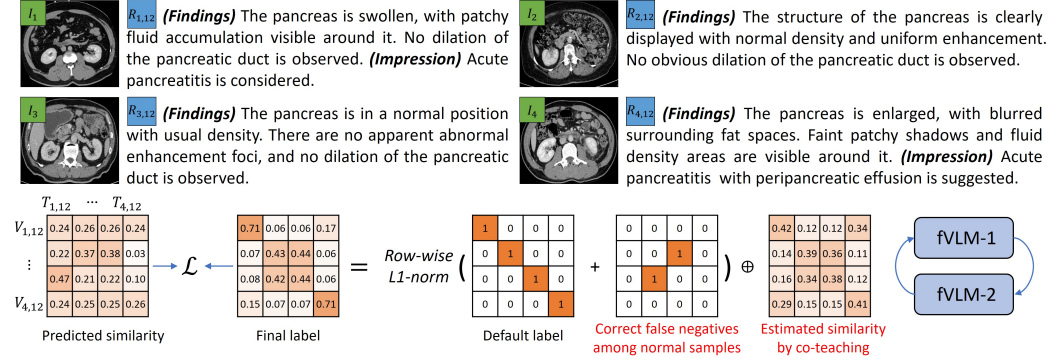


Figure 4: Illustration of the proposed dual false negative reduction approach. $V_{i,12}$ and $T_{i,12}$ represent pancreas-specific visual and textual features from the i -th sample, respectively. On one hand, we identify those samples not mentioned in the *impression* section of reports as normal and correct the corresponding labels for these semantically consistent samples to 1 in the label matrix. On the other hand, we further incorporate the estimated image-text similarities into the label matrix, aiming to capture potential semantic relationships between different samples and thereby enhance the model’s semantic comprehension. Notably, to mitigate error accumulation in this process, we propose a co-teaching strategy, wherein two fVLMs are trained alternately and the image-text similarities employed by one model are estimated from the other.

leveraging the inherently hierarchical structure of CT reports Hamamci et al. (2024); Blankemeier et al. (2024). Specifically, the *findings* section of a report outlines all observations derived from the image, including the appearance of anatomical structures, any abnormalities such as masses or lesions, and the conditions of various anatomical components. Meanwhile, the *impression* section consolidates the abnormal observations into a concise summary, offering standard diagnostic conclusions and highlighting potential diseases. Based on this prior, we empirically annotate anatomies not mentioned in the *impression* section as normal. We then correct $y_{i,j,k}^{i2t}$ and $y_{i,j,k}^{t2i}$ to 1 if the i -th and k -th patients are both normal in terms of the j -th anatomy. Moreover, to stabilize model training, we normalize $y_{i,j}^{i2t}$ and $y_{i,j}^{t2i}$ so that their sums equal 1.

Furthermore, due to the narrowed abnormality space from the entire body to specific anatomical regions, the abnormal samples in our fine-grained framework typically exhibit higher semantic similarity compared to those in global contrastive learning methods. For instance, although two patients exhibit significant overall differences, their pancreas may manifest the same pathology as described as follows: $R_{1,12}$: “The pancreas is swollen, with patchy fluid accumulation visible around it. Acute pancreatitis is considered” and $R_{2,12}$: “The pancreas is enlarged, and fluid density shadows are visible around it. Acute pancreatitis with peripancreatic fluid collection is suggested.” Here, the subscript 12 denotes the index of the pancreas in all involved anatomies. In this scenario, pushing away the visual features $V_{1,12}$ from the textual features $T_{2,12}$ is unreasonable and potentially compromises the model’s capability in pancreatitis diagnosis. To accommodate this heightened inter-sample similarity, we propose a bootstrapping strategy that utilizes the similarity scores p^{i2t} and p^{t2i} predicted by the model itself to dynamically correct the target label during contrastive pre-training. However, these predicted similarity scores may be biased. Further incorporating them into model training could cause error accumulation and ultimately result in significant performance degradation. To tackle this, we propose a co-teaching training framework that alternately trains two fVLMs, where the image-text similarity scores predicted by one model are used to correct the contrastive learning target of the other model:

$$\begin{aligned} y^{i2t} &= \alpha y^{i2t} + (1 - \alpha) p^{i2t'}, & y^{i2t'} &= \alpha y^{i2t'} + (1 - \alpha) p^{i2t} \\ y^{t2i} &= \alpha y^{t2i} + (1 - \alpha) p^{t2i'}, & y^{t2i'} &= \alpha y^{t2i'} + (1 - \alpha) p^{t2i} \end{aligned} \quad (3)$$

Here $\alpha \in [0, 1]$ is a free parameter and we empirically set it to 0.5 in this work. $p^{i2t'}$ and $p^{t2i'}$ are predicted image-to-text and text-to-image similarities from another model. To reduce the risk of concurrent errors arising from both models for the same image-text pair, we enhance their diversity

Table 1: Zero-shot performance comparison on the MedVL-CT69K dataset. The best and second-best zero-shot results are highlighted in **bold** and underlined.

| | Method | AUC | ACC | Spec | Sens | F1 | Prec |
|------------|----------------------------------|-------------|-------------|-------------|-------------|-------------|-------------|
| Supervised | Baseline | 73.3 | 69.1 | 76.2 | 62.0 | 79.4 | 17.6 |
| | CT-VocabFine | 76.7 | 72.2 | 76.1 | 68.2 | 81.6 | 20.3 |
| | CT-LiPro | 76.5 | 70.9 | 76.8 | 65.1 | 81.3 | 19.3 |
| Zero-shot | CLIP Radford et al. (2021) | 68.4 | 66.7 | 68.0 | 65.5 | 76.0 | 18.0 |
| | LOVT Müller et al. (2022) | 69.4 | 65.4 | 60.1 | <u>70.8</u> | 70.9 | 15.2 |
| | MGCA Wang et al. (2022a) | 70.1 | 66.4 | 64.5 | 68.3 | 73.9 | 16.0 |
| | Imitate Liu et al. (2023b) | 70.6 | 67.9 | 66.6 | 69.2 | 75.4 | 17.9 |
| | ASG Li et al. (2024a) | 70.1 | 67.7 | 67.4 | 68.0 | 75.9 | <u>18.8</u> |
| | CT-GLIP Lin et al. (2024) | 69.3 | 66.9 | 63.1 | 70.6 | 74.2 | 18.1 |
| | BIUD Cao et al. (2024) | 71.4 | 69.2 | 69.0 | 69.3 | 76.6 | 18.7 |
| | Merlin Blankemeier et al. (2024) | <u>71.9</u> | <u>69.5</u> | <u>69.7</u> | 69.2 | <u>77.0</u> | 18.1 |
| | Ours | 81.3 | 76.2 | 76.5 | 75.8 | 82.2 | 21.1 |

by employing different model initialization, data iteration sequences and augmentations. Fig. 4 exemplifies the calculation of the final labels.

4 EXPERIMENTS

4.1 EXPERIMENTAL SETUP

Dataset. In this study, we curate MedVL-CT69K, a large-scale CT dataset comprising 272,124 CT scans from 69,086 unique patients and their associated reports. Each patient consists of a non-contrast CT scan and contrast-enhanced CT scans, which include one or more of the following phases: arterial, venous, and delayed. We randomly split the dataset into training, validation and test sets of 64,476, 1,151, and 3,459 patients, respectively. The validation and test sets are annotated with 36 and 54 diseases by expert radiologists. A detailed distribution of these diseases is provided in Appendix Tab. 9 and Tab. 10. Additionally, we conduct experiments on two benchmarks, CT-RATE Hamamci et al. (2024) and Rad-ChestCT Draelos et al. (2021). Following Hamamci et al. (2024), we train fVLM on the training set of CT-RATE and use its test set and the whole Rad-ChestCT dataset for internal and external evaluations, respectively. The details regarding these two datasets can be found in Hamamci et al. (2024) and Draelos et al. (2021).

Evaluation metrics. We compare the performance of different pre-training methods on zero-shot abnormality detection and downstream report-generation tasks. For the zero-shot experiments, following Hamamci et al. (2024), we adopt the area under the ROC curve (AUC), balanced accuracy (ACC), specificity (Spec), sensibility (Spec), precision (Prec) and weighted F1-score as the metrics. For the report-generation task, we employ both diagnostic metrics and natural language generation metrics for model evaluation. To facilitate the calculation of diagnostic metrics, we develop a high-performing text classifier to identify abnormalities in generated radiology reports. A detailed exposition of the classifier’s training and evaluation is provided in Appendix A.1.

Implementation details are available in Appendix A.2.

4.2 ZERO-SHOT ABNORMALITY DETECTION

Through the extensive MedVL-CT69K dataset, we compare the zero-shot abnormality detection performance of different methods on 54 diseases across 15 anatomies. The results are presented in Tab. 1. It can be seen that our method outperforms all counterparts by a large margin. Specifically, it suppresses CLIP Radford et al. (2021) by 12.9 points on AUC and 9.5 points on ACC. Furthermore, compared to the second-best competitor, Merlin Blankemeier et al. (2024), our method achieves absolute gains of 9.4 points on AUC and 6.7 points on ACC. Notably, we observe that LOVT Müller et al. (2022) and MGCA Wang et al. (2022a) exhibit marginal performance improvements over CLIP, which underscores the significant limitations of implicit local alignment methodologies in CT

Table 2: Performance comparison on the CT-RATE and Rad-ChestCT benchmarks. Here, CT-CLIP refers to the CLIP model trained on the CT-RATE dataset, as named in the original paper. The best and second-best zero-shot results are highlighted in **bold** and underlined.

| Dataset | Metric | Supervised | | | Zero-shot | | | |
|-----------------------------------|--------|------------|--------------|----------|-----------|-------------|-------------|-------------|
| | | Baseline | CT-VocabFine | CT-LiPro | CT-CLIP | BIUD | Merlin | Ours |
| Internal validation (CT-RATE) | AUC | 60.3 | 75.0 | 75.1 | 70.4 | 71.3 | <u>72.8</u> | 77.8 |
| | ACC | 58.1 | 69.2 | 67.6 | 65.1 | <u>68.1</u> | 67.2 | 71.8 |
| | F1 | 63.2 | 72.8 | 71.4 | 69.1 | <u>71.6</u> | 70.9 | 75.1 |
| | Prec | 24.0 | 34.2 | 33.1 | 30.6 | <u>33.8</u> | 33.7 | 37.9 |
| | Spec | - | - | - | - | <u>68.6</u> | 66.8 | 71.7 |
| | Sens | - | - | - | - | <u>67.3</u> | <u>70.1</u> | 72.8 |
| External validation (Rad-ChestCT) | AUC | 54.1 | 64.9 | 64.7 | 63.2 | 62.9 | <u>64.4</u> | 68.0 |
| | ACC | 53.9 | 62.2 | 62.5 | 59.9 | 60.6 | <u>61.9</u> | 64.7 |
| | F1 | 58.7 | 66.5 | 66.8 | 64.8 | 65.2 | <u>66.3</u> | 68.8 |
| | Prec | 28.7 | 35.9 | 35.3 | 33.9 | 33.7 | <u>34.8</u> | 37.4 |
| | Spec | - | - | - | - | 60.2 | <u>61.7</u> | 64.6 |
| | Sens | - | - | - | - | 59.6 | <u>61.0</u> | 64.6 |

Table 3: Performance comparison on the downstream report-generation task using the MedVL-CT69K dataset. ‘IN’ means initialization with ImageNet supervised weights, while all other methods are trained with our dataset. ‘SP’ denotes the supervised baseline model.

| Encoder | Init | ACC | GREEN | BLEU-1 | BLEU-2 | BLEU-3 | BLEU-4 | METEOR | ROUGE-L | CIDEr |
|-------------|--------|-------------|-------------|-------------|-------------|-------------|-------------|-------------|-------------|-------------|
| Frozen | IN | 51.3 | 34.0 | 47.4 | 32.2 | 25.5 | 21.2 | 28.1 | <u>44.3</u> | 10.6 |
| | SP | 55.8 | 25.9 | 48.3 | 26.3 | 18.0 | 12.8 | 30.8 | 40.6 | 6.6 |
| | MAE | 50.7 | 21.6 | 49.0 | 27.1 | 18.6 | 13.1 | 30.5 | 41.6 | 6.1 |
| | CLIP | 57.3 | 33.4 | <u>49.7</u> | 28.8 | 20.7 | 15.5 | <u>31.0</u> | 42.2 | 9.6 |
| | BIUD | 58.4 | 33.7 | 47.1 | 30.4 | 23.4 | 18.9 | 29.1 | 44.2 | 13.9 |
| | Merlin | <u>58.8</u> | <u>34.2</u> | 49.5 | <u>31.4</u> | 23.9 | 19.0 | 30.0 | 43.8 | <u>14.3</u> |
| | Ours | 61.5 | 37.2 | 50.7 | 32.2 | <u>24.5</u> | <u>19.6</u> | 31.3 | 45.1 | 14.9 |
| Fine-tuning | IN | 58.0 | 33.4 | 49.4 | 29.8 | 21.9 | 16.9 | 30.4 | 43.6 | 10.0 |
| | SP | 60.6 | 35.5 | 49.9 | 30.7 | 22.9 | 17.9 | 30.6 | 43.4 | 11.7 |
| | MAE | 54.4 | 29.4 | 49.0 | 27.1 | 18.6 | 15.1 | 30.5 | 42.5 | 8.8 |
| | CLIP | 62.0 | 37.6 | 49.9 | 31.9 | 24.3 | 19.5 | 30.7 | 44.7 | 14.3 |
| | BIUD | 62.6 | 38.8 | 50.2 | 31.7 | 24.0 | 19.0 | 30.9 | 44.7 | 13.8 |
| | Merlin | <u>63.0</u> | <u>39.2</u> | <u>50.7</u> | <u>33.3</u> | <u>25.8</u> | <u>20.9</u> | <u>31.1</u> | <u>46.0</u> | 17.2 |
| | Ours | 64.5 | 40.2 | 52.2 | 34.5 | 26.8 | 21.9 | 31.6 | 46.4 | <u>17.1</u> |

imaging scenarios. We enumerate the detection performance of our model for each abnormality in Appendix Tab. 11.

Tab. 2 exhibits the performance comparison with the current state-of-the-art method (*i.e.*, CT-CLIP) on the CT-RATE and Rad-ChestCT benchmarks. In the zero-shot setting, our method demonstrates significant improvements over CT-CLIP, achieving absolute AUC gains of 7.4% and 4.8% in the internal and external evaluations, respectively. Notably, the zero-shot performance of our model even outperforms the outcomes of CT-VocabFine and CT-LiPro that are both derived from CT-CLIP through supervised fine-tuning. To be specific, in the internal test set, our approach exceeds CT-VocabFine and CT-LiPro by 2.3 and 3.7 points on F1-score. In the external test set, it surpasses these two models by 2.3 and 2.0 points on F1-score.

To further assess the clinical utility of our method, we conduct a reader study to compare our method with three board-certified radiologists. Please refer to Appendix A.3 for detailed results and discussions.

4.3 RADIOLOGY REPORT GENERATION

To assess the transfer abilities of VLMs, we conduct experiments on the downstream task of radiology report generation using the MedVL-CT69K dataset. For these experiments, we integrate each pre-trained image encoder with a BERT-base text decoder for whole report generation. The generation process is optimized using the language modeling loss Devlin et al. (2018).

Table 4: Effect of our proposed modules. CLIP serves as the baseline.

| FGA | FNCN | CoT | AUC | ACC |
|-----|------|-----|------|------|
| | | | 70.9 | 69.3 |
| ✓ | | | 76.0 | 74.0 |
| ✓ | ✓ | | 78.7 | 75.3 |
| ✓ | | ✓ | 77.5 | 74.6 |
| ✓ | ✓ | ✓ | 79.8 | 75.9 |

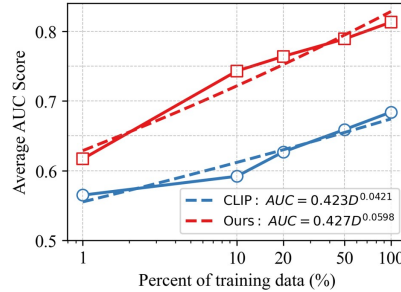


Figure 5: Scaling laws of CLIP and our method.

Tab. 3 presents the experimental results in both frozen and fine-tuning protocols, where the frozen protocol keeps the pre-trained image encoder fixed, while the fine-tuning protocol allows the entire model to be updated during training. It demonstrates that vision-language pre-trained models outperform those with purely visual pre-training, underscoring the benefits of aligning visual and textual features into a unified representation space for the report generation task. Notably, in the frozen regime, our method significantly outperforms CLIP by 4.2 points on ACC and 3.8 points on GREEN Ostmeier et al. (2024). While the performance gap attenuates in the fine-tuning protocol, our method still surpasses CLIP by a clear margin, achieving a 2.5-point improvement on ACC and a 2.6-point improvement on GREEN. Although the results have demonstrated the superiority of our approach, we argue that directly employing the fine-grained alignment model for whole report generation may not unleash its full power due to the granularity mismatch issue. We will explore a potentially more effective strategy of generating anatomy-wise diagnostic reports in our future work.

4.4 ANALYSIS OF OUR FRAMEWORK

Ablation study. We investigate the impact of three modules on the performance of fVLM on the validation set of MedVL-CT69K, including **fine-grained alignment** (FGA), **false negatives correction** between **normals** (FNCN) and **co-teaching** strategy (CoT). As shown in Tab. 4, each enhancement component contributes to the improvement of the model’s performance. Notably, the FGA and FNCN contribute the largest performance gains. The combination of them leads to an overall improvement of 7.8 points on AUC and 6.0 points on ACC. Furthermore, in Appendix A.4, we demonstrate that applying CoT to correct contrastive learning labels yields superior results compared to using either the training model or the momentum model.

Scaling law. In Fig. 5, we compute the data scaling law curves to assess how the performance of CLIP and our method improves as the volume of training data increases. It can be seen that our approach consistently outperforms CLIP across multiple data scales, exhibiting superior data efficiency.

Visualization analysis. The visualization results and discussions can be found in Appendix A.5

5 CONCLUSION

In this paper, we have presented fVLM, a fine-grained vision-language pre-training method for CT data. Our proposed methodology explicitly aligns discrete anatomical structures in CT scans with their corresponding descriptions in diagnostic reports, thereby addressing the misalignment issue of CLIP and its existing variants that contrast entire images and reports. Extensive experiments, including quantitative abnormality detection and report generation tasks as well as qualitative visualization analysis, demonstrate the superiority of fVLM.

Limitations and future work. The implementation of our fine-grained alignment methodology necessitates localizing anatomical structures in CT images and decomposing diagnostic reports into anatomy-wise sub-descriptions. This data processing step entails additional resource consumption and time commitment. For future work, we plan to investigate anatomy-wise report generation to fully unleash the potential of fVLM on this application.

Acknowledgements. Jianpeng Zhang was supported by the Zhejiang Province Postdoctoral Research Excellence Funding Program. This work was also supported by the Zhejiang Province “Pioneer Eagle + X” Research and Development Initiative (2024C03043).

REFERENCES

- Fan Bai, Yuxin Du, Tiejun Huang, Max Q. H. Meng, and Bo Zhao. M3d: Advancing 3d medical image analysis with multi-modal large language models, 2024.
- Jinze Bai, Shuai Bai, Yunfei Chu, Zeyu Cui, Kai Dang, Xiaodong Deng, Yang Fan, Wenbin Ge, Yu Han, Fei Huang, Binyuan Hui, Luo Ji, Mei Li, Junyang Lin, Runji Lin, Dayiheng Liu, Gao Liu, Chengqiang Lu, Keming Lu, Jianxin Ma, Rui Men, Xingzhang Ren, Xuancheng Ren, Chuanqi Tan, Sinan Tan, Jianhong Tu, Peng Wang, Shijie Wang, Wei Wang, Shengguang Wu, Benfeng Xu, Jin Xu, An Yang, Hao Yang, Jian Yang, Shusheng Yang, Yang Yao, Bowen Yu, Hongyi Yuan, Zheng Yuan, Jianwei Zhang, Xingxuan Zhang, Yichang Zhang, Zhenru Zhang, Chang Zhou, Jingren Zhou, Xiaohuan Zhou, and Tianhang Zhu. Qwen technical report. *arXiv preprint arXiv:2309.16609*, 2023.
- Shruthi Bannur, Stephanie Hyland, Qianchu Liu, Fernando Perez-Garcia, Maximilian Ilse, Daniel C Castro, Benedikt Boecking, Harshita Sharma, Kenza Bouzid, Anja Thieme, et al. Learning to exploit temporal structure for biomedical vision-language processing. In *Proceedings of the IEEE/CVF Conference on Computer Vision and Pattern Recognition*, pp. 15016–15027, 2023.
- Louis Blankemeier, Joseph Paul Cohen, Ashwin Kumar, Dave Van Veen, Syed Jamal Safdar Gardezi, Magdalini Paschali, Zhihong Chen, Jean-Benoit Delbrouck, Eduardo Reis, Cesar Truys, et al. Merlin: A vision language foundation model for 3d computed tomography. *arXiv preprint arXiv:2406.06512*, 2024.
- Benedikt Boecking, Naoto Usuyama, Shruthi Bannur, Daniel C Castro, Anton Schwaighofer, Stephanie Hyland, Maria Wetscherek, Tristan Naumann, Aditya Nori, Javier Alvarez-Valle, et al. Making the most of text semantics to improve biomedical vision-language processing. In *European conference on computer vision*, pp. 1–21. Springer, 2022.
- Weiwei Cao, Jianpeng Zhang, Yingda Xia, Tony CW Mok, Zi Li, Xianghua Ye, Le Lu, Jian Zheng, Yuxing Tang, and Ling Zhang. Bootstrapping chest ct image understanding by distilling knowledge from x-ray expert models. In *Proceedings of the IEEE/CVF Conference on Computer Vision and Pattern Recognition*, pp. 11238–11247, 2024.
- Zhihong Chen, Shizhe Diao, Benyou Wang, Guanbin Li, and Xiang Wan. Towards unifying medical vision-and-language pre-training via soft prompts. In *Proceedings of the IEEE/CVF International Conference on Computer Vision*, pp. 23403–23413, 2023.
- Pujin Cheng, Li Lin, Junyan Lyu, Yijin Huang, Wenhan Luo, and Xiaoying Tang. Prior: Prototype representation from medical images and reports. In *Proceedings of the IEEE/CVF International Conference on Computer Vision*, pp. 21361–21371, 2023.
- Matthew Christensen, Milos Vukadinovic, Neal Yuan, and David Ouyang. Vision-language foundation model for echocardiogram interpretation. *Nature Medicine*, pp. 1–8, 2024.
- Jia Deng, Wei Dong, Richard Socher, Li-Jia Li, Kai Li, and Li Fei-Fei. Imagenet: A large-scale hierarchical image database. In *2009 IEEE conference on computer vision and pattern recognition*, pp. 248–255. Ieee, 2009.
- Jacob Devlin, Ming-Wei Chang, Kenton Lee, and Kristina Toutanova. Bert: Pre-training of deep bidirectional transformers for language understanding. *arXiv preprint arXiv:1810.04805*, 2018.
- Alexey Dosovitskiy, Lucas Beyer, Alexander Kolesnikov, Dirk Weissenborn, Xiaohua Zhai, Thomas Unterthiner, Mostafa Dehghani, Matthias Minderer, Georg Heigold, Sylvain Gelly, et al. An image is worth 16x16 words: Transformers for image recognition at scale. *arXiv preprint arXiv:2010.11929*, 2020.

- Rachel Lea Draelos, David Dov, Maciej A Mazurowski, Joseph Y Lo, Ricardo Henao, Geoffrey D Rubin, and Lawrence Carin. Machine-learning-based multiple abnormality prediction with large-scale chest computed tomography volumes. *Medical image analysis*, 67:101857, 2021.
- Heng Guo, Jianfeng Zhang, Jiaying Huang, Tony CW Mok, Dazhou Guo, Ke Yan, Le Lu, Dakai Jin, and Minfeng Xu. Towards a comprehensive, efficient and promptable anatomic structure segmentation model using 3d whole-body ct scans. *arXiv preprint arXiv:2403.15063*, 2024.
- Ibrahim Ethem Hamamci, Sezgin Er, Furkan Almas, Ayse Gulnihan Simsek, Sevvat Nil Esirgun, Irem Dogan, Muhammed Furkan Dasdelen, Bastian Wittmann, Enis Simsar, Mehmet Simsar, et al. A foundation model utilizing chest ct volumes and radiology reports for supervised-level zero-shot detection of abnormalities. *arXiv preprint arXiv:2403.17834*, 2024.
- Kaiming He, Xinlei Chen, Saining Xie, Yanghao Li, Piotr Dollár, and Ross Girshick. Masked autoencoders are scalable vision learners. In *Proceedings of the IEEE/CVF conference on computer vision and pattern recognition*, pp. 16000–16009, 2022.
- Shih-Cheng Huang, Liyue Shen, Matthew P. Lungren, and Serena Yeung. Gloria: A multimodal global-local representation learning framework for label-efficient medical image recognition. In *Proceedings of the IEEE/CVF International Conference on Computer Vision (ICCV)*, pp. 3942–3951, October 2021.
- Zhi Huang, Federico Bianchi, Mert Yuksekogunul, Thomas J Montine, and James Zou. A visual-language foundation model for pathology image analysis using medical twitter. *Nature medicine*, 29(9):2307–2316, 2023.
- Fabian Isensee, Paul F Jaeger, Simon AA Kohl, Jens Petersen, and Klaus H Maier-Hein. nnu-net: a self-configuring method for deep learning-based biomedical image segmentation. *Nature methods*, 18(2):203–211, 2021.
- Qingqiu Li, Xiaohan Yan, Jilan Xu, Runtian Yuan, Yuejie Zhang, Rui Feng, Quanli Shen, Xiaobo Zhang, and Shujun Wang. Anatomical structure-guided medical vision-language pre-training. *arXiv preprint arXiv:2403.09294*, 2024a.
- Shiyu Li, Pengchong Qiao, Lin Wang, Munan Ning, Li Yuan, Yefeng Zheng, and Jie Chen. An organ-aware diagnosis framework for radiology report generation. *IEEE Transactions on Medical Imaging*, 2024b.
- Jingyang Lin, Yingda Xia, Jianpeng Zhang, Ke Yan, Le Lu, Jiebo Luo, and Ling Zhang. Ct-glip: 3d grounded language-image pretraining with ct scans and radiology reports for full-body scenarios. *arXiv preprint arXiv:2404.15272*, 2024.
- Weixiong Lin, Ziheng Zhao, Xiaoman Zhang, Chaoyi Wu, Ya Zhang, Yanfeng Wang, and Weidi Xie. Pmc-clip: Contrastive language-image pre-training using biomedical documents. In *International Conference on Medical Image Computing and Computer-Assisted Intervention*, pp. 525–536. Springer, 2023.
- Che Liu, Sibao Cheng, Chen Chen, Mengyun Qiao, Weitong Zhang, Anand Shah, Wenjia Bai, and Rossella Arcucci. M-flag: Medical vision-language pre-training with frozen language models and latent space geometry optimization. In *International Conference on Medical Image Computing and Computer-Assisted Intervention*, pp. 637–647. Springer, 2023a.
- Che Liu, Sibao Cheng, Miaojing Shi, Anand Shah, Wenjia Bai, and Rossella Arcucci. Imitate: Clinical prior guided hierarchical vision-language pre-training. *arXiv preprint arXiv:2310.07355*, 2023b.
- Jie Liu, Yixiao Zhang, Jie-Neng Chen, Junfei Xiao, Yongyi Lu, Bennett A Landman, Yixuan Yuan, Alan Yuille, Yucheng Tang, and Zongwei Zhou. Clip-driven universal model for organ segmentation and tumor detection. In *Proceedings of the IEEE/CVF International Conference on Computer Vision*, pp. 21152–21164, 2023c.
- Ming Y Lu, Bowen Chen, Drew FK Williamson, Richard J Chen, Ivy Liang, Tong Ding, Guillaume Jaume, Igor Odintsov, Long Phi Le, Georg Gerber, et al. A visual-language foundation model for computational pathology. *Nature Medicine*, 30(3):863–874, 2024.

- Philip Müller, Georgios Kaissis, Congyu Zou, and Daniel Rueckert. Joint learning of localized representations from medical images and reports. In *European Conference on Computer Vision*, pp. 685–701. Springer, 2022.
- Sophie Ostmeier, Justin Xu, Zhihong Chen, Maya Varma, Louis Blankemeier, Christian Bluethgen, Arne Edward Michalson, Michael Moseley, Curtis Langlotz, Akshay S Chaudhari, et al. Green: Generative radiology report evaluation and error notation. *arXiv preprint arXiv:2405.03595*, 2024.
- Alec Radford, Jong Wook Kim, Chris Hallacy, Aditya Ramesh, Gabriel Goh, Sandhini Agarwal, Girish Sastry, Amanda Askell, Pamela Mishkin, Jack Clark, et al. Learning transferable visual models from natural language supervision. In *International conference on machine learning*, pp. 8748–8763. PMLR, 2021.
- Yuxuan Sun, Chenglu Zhu, Sunyi Zheng, Kai Zhang, Lin Sun, Zhongyi Shui, Yunlong Zhang, Honglin Li, and Lin Yang. Pathasst: A generative foundation ai assistant towards artificial general intelligence of pathology. In *Proceedings of the AAAI Conference on Artificial Intelligence*, volume 38, pp. 5034–5042, 2024.
- Ekin Tiu, Ellie Talius, Pujan Patel, Curtis P Langlotz, Andrew Y Ng, and Pranav Rajpurkar. Expert-level detection of pathologies from unannotated chest x-ray images via self-supervised learning. *Nature Biomedical Engineering*, 6(12):1399–1406, 2022.
- Amar Udare, Minu Agarwal, Kiret Dhindsa, Amer Alaref, Michael Patlas, Abdullah Alabousi, Yoan K Kagoma, and Christian B van der Pol. Radiologist productivity analytics: factors impacting abdominal pelvic ct exam reporting times. *Journal of Digital Imaging*, pp. 1–11, 2022.
- Fuying Wang, Yuyin Zhou, Shujun Wang, Varut Vardhanabhuti, and Lequan Yu. Multi-granularity cross-modal alignment for generalized medical visual representation learning. *Advances in Neural Information Processing Systems*, 35:33536–33549, 2022a.
- Haoyu Wang, Sizheng Guo, Jin Ye, Zhongying Deng, Junlong Cheng, Tianbin Li, Jianpin Chen, Yanzhou Su, Ziyang Huang, Yiqing Shen, Bin Fu, Shaoting Zhang, Junjun He, and Yu Qiao. Sam-med3d, 2023.
- Zifeng Wang, Zhenbang Wu, Dinesh Agarwal, and Jimeng Sun. Medclip: Contrastive learning from unpaired medical images and text. *arXiv preprint arXiv:2210.10163*, 2022b.
- Jakob Wasserthal, Hanns-Christian Breit, Manfred T Meyer, Maurice Pradella, Daniel Hinck, Alexander W Sauter, Tobias Heye, Daniel T Boll, Joshy Cyriac, Shan Yang, et al. Totalsegmentator: robust segmentation of 104 anatomic structures in ct images. *Radiology: Artificial Intelligence*, 5(5), 2023.
- Chaoyi Wu, Xiaoman Zhang, Ya Zhang, Yanfeng Wang, and Weidi Xie. Medclip: Medical knowledge enhanced language-image pre-training for x-ray diagnosis. In *Proceedings of the IEEE/CVF International Conference on Computer Vision (ICCV)*, pp. 21372–21383, October 2023.
- Yutong Xie, Qi Chen, Sinuo Wang, Minh-Son To, Iris Lee, Ee Win Khoo, Kerolos Hendy, Daniel Koh, Yong Xia, and Qi Wu. Pairaug: What can augmented image-text pairs do for radiology? In *Proceedings of the IEEE/CVF Conference on Computer Vision and Pattern Recognition*, pp. 11652–11661, 2024.
- Jianpeng Zhang, Xianghua Ye, Jianfeng Zhang, Yuxing Tang, Minfeng Xu, Jianfei Guo, Xin Chen, Zaiyi Liu, Jingren Zhou, Le Lu, et al. Parse and recall: Towards accurate lung nodule malignancy prediction like radiologists. In *International Conference on Medical Image Computing and Computer-Assisted Intervention*, pp. 199–209. Springer, 2023a.
- Sheng Zhang, Yanbo Xu, Naoto Usuyama, Hanwen Xu, Jaspreet Bagga, Robert Tinn, Sam Preston, Rajesh Rao, Mu Wei, Naveen Valluri, et al. Biomedclip: a multimodal biomedical foundation model pretrained from fifteen million scientific image-text pairs. *arXiv preprint arXiv:2303.00915*, 2023b.

Xiaoman Zhang, Chaoyi Wu, Ya Zhang, Weidi Xie, and Yanfeng Wang. Knowledge-enhanced visual-language pre-training on chest radiology images. *Nature Communications*, 14(1):4542, 2023c.

Yuhao Zhang, Hang Jiang, Yasuhide Miura, Christopher D Manning, and Curtis P Langlotz. Contrastive learning of medical visual representations from paired images and text. In *Machine Learning for Healthcare Conference*, pp. 2–25. PMLR, 2022.

Hong-Yu Zhou, Chenyu Lian, Liansheng Wang, and Yizhou Yu. Advancing radiograph representation learning with masked record modeling. *arXiv preprint arXiv:2301.13155*, 2023.

A APPENDIX

{findings or impression}

You are a professional radiologist. Please determine if the anatomy ({anatomy}) is mentioned in this CT image report. Please answer directly with "Yes" or "No".

Figure 6: Prompt used to judge if an anatomy is mentioned in the “Findings” or “Impression” section of a clinical report.

{findings or impression}

You are a professional radiologist. Please extract the descriptive information about the specific anatomy ({anatomy}) from this CT image diagnostic report. Please follow these guidelines:

Precise extraction: Extract the descriptive information directly related to {anatomy} from the report.

Specify anatomical details: If the report mentions specific areas, parts, or anatomical details of {anatomy}, make sure to include this information in the description. This could include affected areas, normal structures, or any notable features.

Concise and clear: Directly extract the report content, avoiding unnecessary explanations or background.

Format requirement: Please provide the information in the format "{anatomy}: descriptive information", ensuring to use {anatomy} as the unified prefix for the item. Even if the anatomy has multiple independent parts or multiple lateral characteristics, it should be treated and described as a whole, returning only one comprehensive piece of information about that anatomy.

Figure 7: Prompt used to extract anatomy-specific description from the “Findings” or “Impression” section of a clinical report. Notably, we do not obtain the descriptions for all anatomies in a single query; rather, we strategically query the LLM for each anatomy individually. This approach significantly simplifies the complexity of description extraction and greatly enhances the quality of the extracted descriptions.

A.1 DETAILS ABOUT THE TEXT CLASSIFIER

We utilize the annotated validation and test sets of MedVL-CT69K to develop a text classifier that identifies 54 abnormalities in the generated radiology reports. To achieve this, we first merge these two sets and then re-split them into new training and validation sets using a 2:1 ratio. Afterwards, we train the classifier, which consists of a BERT-base encoder and a classification head, using the reports and corresponding disease labels form the training set. A binary cross-entropy loss is used to supervise the model training. Tab. 7 shows the precision, recall, and F1 scores of the text classifier across 54 abnormalities on the validation set. Notably, the model achieves an impressive average F1 score of 0.95. This high performance substantiates its reliability as a tool for assessing the diagnostic accuracy of report generation models.

A.2 IMPLEMENTATION DETAILS

For the abdominal MedVL-CT69K dataset, we reformat all CT scans so that the first axis points from inferior to superior, the second from posterior to anterior, and the third from left to right. We then resample the in-plane axial images to 1mm resolution and the out-of-plane slice thickness to 5mm spacing using trilinear interpolation. We map the Hounsfield unit range -300:400 to the range 0:1, clipping values that fall outside of this range. We use ViT-base Dosovitskiy et al. (2020), initialized with MAE ImageNet-1K pre-trained weights He et al. (2022), as the image encoder. The patch size is set to 16, 16, 32 along the axial, coronal, and sagittal axes, respectively. A pre-trained BERT-base Devlin et al. (2018) model is used as the text encoder. We train fVLM with an Adam optimizer. The learning rate linearly increases to 1e-4 in the first epoch and then decreases to 1e-6 with a cosine decay scheduler. The model undergoes training for 20 epochs on 4 A100 GPUs, with a batch size of 48. During model training, we apply RandomCrop and RandomFlip on the fly. The cropping size is set to 96, 256, and 384 along the axial, coronal, and sagittal axes, respectively. Notably,

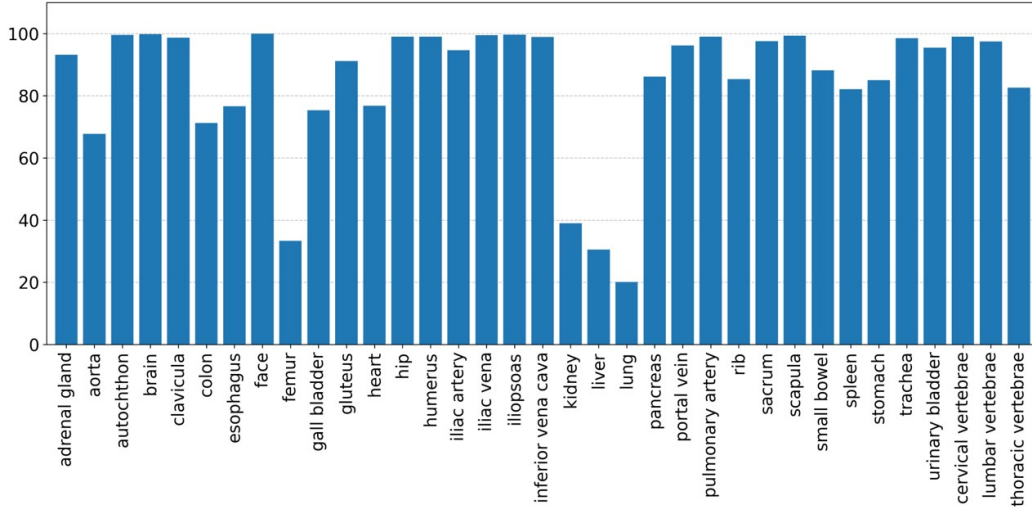


Figure 8: Percentage of normal samples for each anatomy.

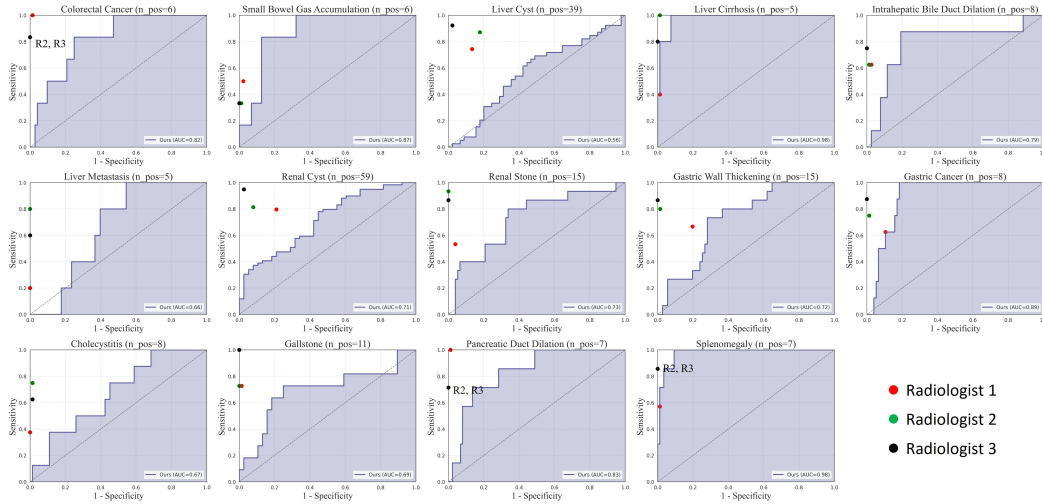


Figure 9: Performance comparison between our method and three radiologists. “n_pos” denotes the number of positive samples of each abnormality.

we observe that if a completely random cropping strategy is used, larger anatomies are more likely to be incomplete after cropping and consequently excluded from the loss calculation. This would introduce a data bias and potentially compromise the model’s performance. To address this issue, we employ a uniform sampling strategy to randomly select an anatomy that must be completely included in the cropped image region. For the chest CT-RATE dataset, we apply the same image pre-processing as CT-CLIP Hamamci et al. (2024) to ensure a fair comparison with the competitors. In our co-teaching approach, we iteratively train two fVLMs, alternating between them after each iteration. We initiate a burn-in stage of 5 epochs to allow both models to establish a baseline level of performance. After that, we leverage each model to generate soft labels for its counterpart.

A.3 READER STUDY

To further validate our method’s efficacy, we conduct a reader study to compare our approach with three board-certified radiologists. For this experiment, we randomly select 100 patients from the test set of MedVL-CT69K. Fig. 9 shows the results. Although our method has demonstrated sig-

Table 5: Performance of fVLM when using different models to correct contrastive labels.

| | Baseline | Model self | Momentum | CoT |
|-----|----------|------------|----------|------|
| AUC | 78.7 | 73.3 | 78.8 | 79.8 |
| ACC | 75.3 | 71.4 | 75.5 | 75.9 |

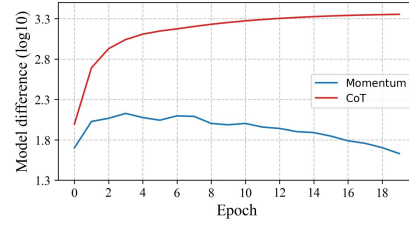


Figure 10: Difference between training model and label correction model.

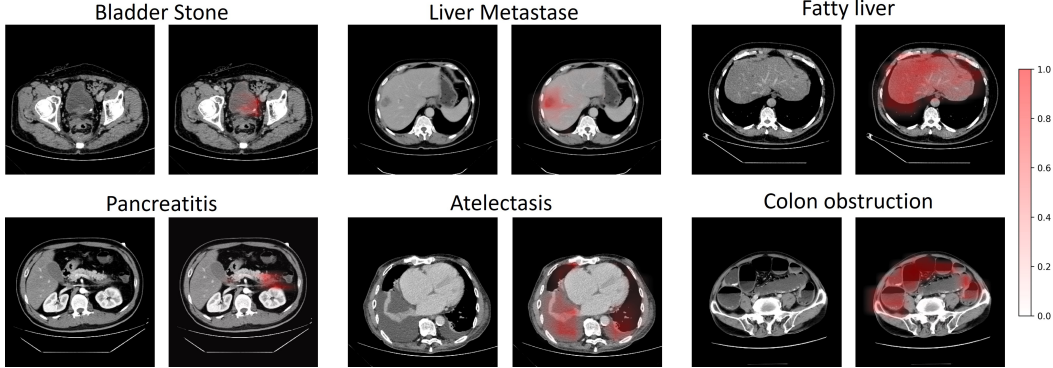


Figure 11: Visual activation maps of our model in diagnosing multiple diseases.

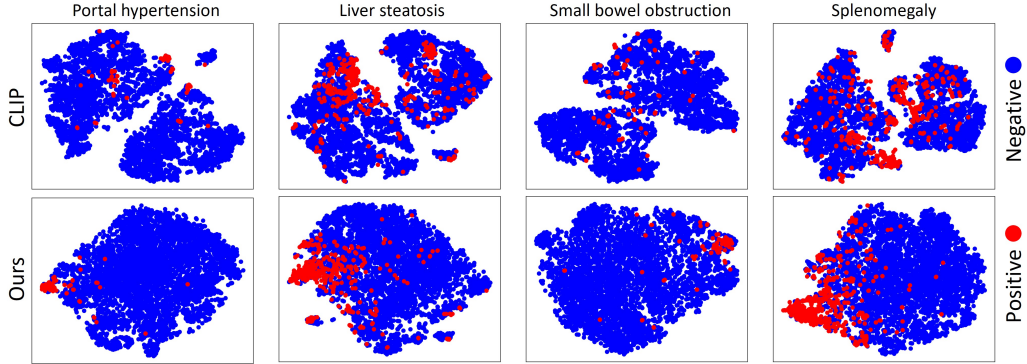


Figure 12: T-SNE visualization of visual embeddings for various abnormalities.

nificant improvements over previous approaches, there remains a noticeable performance gap compared to professional radiologists overall. However, for some diseases such as liver cirrhosis and splenomegaly, our method achieves comparable diagnostic accuracy to radiologists.

A.4 FURTHER ABLATION ANALYSIS

In Tab. 5, we compare the performance of fVLM when employing different models to correct contrastive learning labels during pre-training. It can be seen that utilizing the training model itself for label correction leads to a significant performance degradation, which could be attributed to the error accumulation issue. Moreover, the proposed CoT strategy yields greater performance gains compared to the momentum model. To explore this, we measure the difference between training model and label correction model by calculating the Euclidean distance of their parameters, as illustrated in Fig. 10. It can be observed that the momentum model, updated through exponential moving average, exhibit minimal discrepancy with the training model. This suggests they may produce similar predictions, potentially leading to error accumulation in the label correction process. In contrast, the iteratively trained models in our proposed CoT framework exhibit considerable distinctness, leading to diverse predictions and reducing the risk of error accumulation.

A.5 VISUALIZATION

We qualitatively assess the alignment efficacy of our proposed method through visualization in Fig. 11. The heatmaps illustrate the correlation between anatomy-specific visual tokens and the textual embedding of abnormality. We observe high activation in specific affected areas for both localized lesions (*e.g.*, bladder stone) and diffuse abnormalities (*e.g.*, fatty liver). The results demonstrate the model’s capacity to precisely localize pathological changes across a spectrum of conditions. Fig. 12 illustrates the distribution of visual embedding for a diverse array of abnormalities. In contrast to CLIP, our method exhibits more compact embedding clusters among positive cases of each abnormality. These findings demonstrate the improved semantic understanding and diagnostic interpretability of our fVLM.

Table 6: Anatomy grouping.

| Anatomical System | Anatomy | Grouped Anatomy |
|-------------------|---|------------------------------|
| Organs | Face | Face |
| | Brain | Brain |
| | Esophagus | Esophagus |
| | Trachea | Trachea |
| | Lung upper lobe left Lung lower lobe left Lung upper lobe right Lung middle lobe right Lung lower lobe right | Lung |
| | Heart myocardium Heart atrium left Heart atrium right Heart ventricle left Heart ventricle right | Heart |
| | Adrenal gland right Adrenal gland left | Adrenal gland |
| | Kidney right Kidney left | Kidney |
| | Stomach | Stomach |
| | Liver | Liver |
| | Gall bladder | Gall bladder |
| | Pancreas | Pancreas |
| | Spleen | Spleen |
| | Colon | Colon |
| | Small bowel Duodenum | Small bowel |
| | Urinary bladder | Urinary bladder |
| Vessels | Aorta | Aorta |
| | Inferior vena cava | Inferior vena cava |
| | Portal vein and splenic vein | Portal vein and splenic vein |
| | Pulmonary artery | Pulmonary artery |
| | Iliac artery left Iliac artery right | Iliac artery |
| | Iliac vena left Iliac vena right | Iliac vena |
| Bones | Vertebrae L1-L4 | Lumbar vertebrae |
| | Vertebrae T1-T12 | Thoracic vertebrae |
| | Vertebrae C1-C7 | Cervical vertebrae |
| | Rib left 1-12 Rib right 1-12 | Rib |
| | Humerus left Humerus right | Humerus |
| | Scapula left Scapula right | Scapula |
| | Clavicula left Clavicula right | Clavicula |
| | Femur left Femur right | Femur |
| | Hip left Hip right | Hip |
| | Sacrum | Sacrum |
| Muscles | Gluteus maximus left Gluteus maximus right Gluteus medius left Gluteus medius right Gluteus minimus left Gluteus minimus right | Gluteus |
| | Iliopsoas left Iliopsoas right | Iliopsoas |
| | Autochthon left Autochthon right | Autochthon |

Table 7: Performance of text classifier.

| Anatomical organ | Abnormality | Precision | Recall | F1-score |
|------------------|-----------------------------------|-----------|--------|----------|
| Adrenal gland | Thickening | 1.00 | 0.97 | 0.99 |
| | Nodule | 1.00 | 0.96 | 0.98 |
| Bladder | Diverticulum | 0.97 | 0.94 | 0.96 |
| | Stones | 1.00 | 1.00 | 1.00 |
| Colon | Gas | 0.84 | 0.79 | 0.81 |
| | Effusion | 0.81 | 0.71 | 0.75 |
| | Obstruction | 0.86 | 1.00 | 0.92 |
| | Diverticulum | 0.97 | 1.00 | 0.98 |
| | Colorectal Cancer | 0.97 | 0.95 | 0.96 |
| | Rectal Cancer | 1.00 | 0.95 | 0.97 |
| | Appendicitis | 1.00 | 1.00 | 1.00 |
| | Appendicolith | 0.89 | 0.96 | 0.92 |
| Esophagus | Hiatal Hernia | 0.74 | 1.00 | 0.85 |
| | Varicose Veins | 1.00 | 1.00 | 1.00 |
| Gallbladder | Cholecystitis | 0.99 | 1.00 | 0.99 |
| | Gallstone | 1.00 | 1.00 | 1.00 |
| | Adenomyomatosis | 0.92 | 0.92 | 0.92 |
| Heart | Cardiomegaly | 1.00 | 0.95 | 0.97 |
| | Pericardial Effusion | 1.00 | 1.00 | 1.00 |
| Kidney | Atrophy | 0.97 | 0.88 | 0.92 |
| | Cyst | 0.97 | 0.96 | 0.97 |
| | Hydronephrosis | 0.88 | 1.00 | 0.94 |
| | Calculi | 0.99 | 0.98 | 0.99 |
| Liver | Steatosis | 0.99 | 1.00 | 0.99 |
| | Glisson’s Capsule Effusion | 0.85 | 0.89 | 0.87 |
| | Metastase | 0.90 | 0.95 | 0.92 |
| | Intrahepatic Bile Duct Dilatation | 0.96 | 0.97 | 0.97 |
| | Cancer | 1.00 | 1.00 | 1.00 |
| | Cyst | 0.99 | 0.99 | 0.99 |
| | Abscess | 0.91 | 0.95 | 0.93 |
| | Cirrhosis | 1.00 | 1.00 | 1.00 |
| Lung | Atelectasis | 0.96 | 0.98 | 0.97 |
| | Bronchiectasis | 0.97 | 0.9 | 0.93 |
| | Emphysema | 1.00 | 0.96 | 0.98 |
| | Pneumonia | 0.98 | 0.96 | 0.97 |
| | Pleural effusion | 0.98 | 1.00 | 0.99 |
| Pancreas | Pancreatic cancer | 1.00 | 0.89 | 0.94 |
| | Atrophy | 1.00 | 0.82 | 0.90 |
| | Pancreatitis | 1.00 | 1.00 | 1.00 |
| | Pancreatic duct dilatation | 0.98 | 0.91 | 0.95 |
| | Steatosis | 0.97 | 0.87 | 0.92 |
| Portal vein | Hypertension | 1.00 | 0.91 | 0.95 |
| | Thrombosis | 0.74 | 0.74 | 0.74 |
| Small Intestine | Gas | 0.89 | 0.93 | 0.91 |
| | Effusion | 0.89 | 0.92 | 0.91 |
| | Obstruction | 0.93 | 0.93 | 0.93 |
| | Diverticulum | 0.97 | 1.00 | 0.98 |
| | Intussusception | 0.93 | 0.90 | 0.92 |
| Spleen | Hemangioma | 1.00 | 0.97 | 0.87 |
| | Infarction | 0.95 | 0.97 | 0.96 |
| | Splenomegaly | 1.00 | 0.99 | 1.00 |
| Stomach | Gastric wall thickening | 0.96 | 0.96 | 0.96 |
| | Stomach cancer | 1.00 | 0.97 | 0.99 |
| Sacrum | Osteitis | 0.97 | 1.00 | 0.99 |
| Average | | 0.95 | 0.95 | 0.95 |

Table 8: The distribution of 54 tested abnormalities in the train set. We employ the well-developed text classifier to automatically extract abnormality labels from radiology reports for each sample.

| Anatomy | Anatomy count | Abnormality | Abnormality count |
|-----------------|---------------|-----------------------------------|-------------------|
| Adrenal gland | 63915 | Thickening | 3037 |
| | | Nodule | 3687 |
| Bladder | 62182 | Diverticulum | 283 |
| | | Stones | 109 |
| Colon | 62054 | Gas | 2173 |
| | | Effusion | 975 |
| | | Obstruction | 436 |
| | | Diverticulum | 1623 |
| | | Colorectal Cancer | 817 |
| | | Rectal Cancer | 858 |
| | | Appendicitis | 1623 |
| | | Appendicolith | 1119 |
| Esophagus | 2636 | Hiatal Hernia | 184 |
| | | Varicose Veins | 609 |
| Gallbladder | 63407 | Cholecystitis | 3935 |
| | | Gallstone | 5500 |
| | | Adenomyomatosis | 1246 |
| Heart | 3701 | Cardiomegaly | 316 |
| | | Pericardial Effusion | 1067 |
| Kidney | 63618 | Atrophy | 921 |
| | | Cyst | 27019 |
| | | Hydronephrosis | 1140 |
| | | Calculi | 5356 |
| Liver | 63690 | Steatosis | 4872 |
| | | Glisson’s Capsule Effusion | 915 |
| | | Metastase | 2403 |
| | | Intrahepatic Bile Duct Dilatation | 6093 |
| | | Cancer | 888 |
| | | Cyst | 21710 |
| | | Abscess | 239 |
| | | Cirrhosis | 1772 |
| Lung | 6598 | Atelectasis | 1988 |
| | | Bronchiectasis | 781 |
| | | Emphysema | 190 |
| | | Pneumonia | 1463 |
| | | Pleural effusion | 4665 |
| Pancreas | 63627 | Pancreatic cancer | 933 |
| | | Atrophy | 942 |
| | | Pancreatitis | 1035 |
| | | Pancreatic duct dilatation | 2697 |
| | | Steatosis | 846 |
| Portal vein | 63855 | Hypertension | 1149 |
| | | Thrombosis | 760 |
| Small Intestine | 62419 | Gas | 2906 |
| | | Effusion | 2326 |
| | | Obstruction | 1174 |
| | | Diverticulum | 2352 |
| | | Intussusception | 168 |
| Spleen | 63749 | Hemangioma | 718 |
| | | Infarction | 374 |
| | | Splenomegaly | 1732 |
| Stomach | 63682 | Gastric wall thickening | 2871 |
| | | Stomach cancer | 1064 |
| Sacrum | 62055 | Osteiti | 246 |

Table 9: The distribution of 36 annotated abnormalities in the validation set.

| Anatomy | Anatomy count | Abnormality | Abnormality count |
|-----------------|---------------|-----------------------------------|-------------------|
| Adrenal gland | 1149 | Thickening | 62 |
| | | Nodule | 79 |
| Colon | 1127 | Gas | 29 |
| | | Effusion | 13 |
| | | Obstruction | 5 |
| | | Colorectal Cancer | 10 |
| | | Rectal Cancer | 16 |
| | | Appendicitis | 5 |
| Gallbladder | 1054 | Cholecystitis | 73 |
| | | Gallstone | 127 |
| | | Adenomyomatosis | 35 |
| Kidney | 1148 | Atrophy | 16 |
| | | Cyst | 492 |
| | | Hydronephrosis | 14 |
| | | Calculi | 104 |
| Liver | 1146 | Steatosis | 97 |
| | | Glisson’s Capsule Effusion | 20 |
| | | Metastase | 40 |
| | | Intrahepatic Bile Duct Dilatation | 132 |
| | | Cancer | 10 |
| | | Cyst | 381 |
| | | Cirrhosis | 30 |
| Pancreas | 1149 | Pancreatic cancer | 5 |
| | | Atrophy | 16 |
| | | Pancreatitis | 26 |
| | | Pancreatic duct dilatation | 49 |
| Portal vein | 1150 | Hypertension | 18 |
| | | Thrombosis | 10 |
| Small Intestine | 1131 | Gas | 34 |
| | | Effusion | 25 |
| | | Obstruction | 8 |
| Spleen | 1140 | Hemangioma | 12 |
| | | Infarction | 8 |
| | | Splenomegaly | 35 |
| Stomach | 1150 | Gastric wall thickening | 61 |
| | | Stomach cancer | 20 |

Table 10: The distribution of 54 annotated abnormalities in the test set.

| Anatomy | Anatomy count | Abnormality | Abnormality count |
|-----------------|---------------|-----------------------------------|-------------------|
| Adrenal gland | 3418 | Thickening | 96 |
| | | Nodule | 87 |
| Bladder | 3243 | Diverticulum | 21 |
| | | Stones | 28 |
| Colon | 3213 | Gas | 129 |
| | | Effusion | 50 |
| | | Obstruction | 17 |
| | | Diverticulum | 104 |
| | | Colorectal Cancer | 96 |
| | | Rectal Cancer | 73 |
| | | Appendicitis | 19 |
| | | Appendicolith | 74 |
| Esophagus | 105 | Hiatal Hernia | 10 |
| | | Varicose Veins | 78 |
| Gallbladder | 3134 | Cholecystitis | 246 |
| | | Gallstone | 355 |
| | | Adenomyomatosis | 60 |
| Heart | 234 | Cardiomegaly | 20 |
| | | Pericardial Effusion | 77 |
| Kidney | 3313 | Atrophy | 37 |
| | | Cyst | 1646 |
| | | Hydronephrosis | 87 |
| | | Calculi | 408 |
| Liver | 3281 | Steatosis | 263 |
| | | Glisson’s Capsule Effusion | 68 |
| | | Metastase | 122 |
| | | Intrahepatic Bile Duct Dilatation | 264 |
| | | Cancer | 61 |
| | | Cyst | 1264 |
| | | Abscess | 12 |
| | | Cirrhosis | 188 |
| Lung | 126 | Atelectasis | 70 |
| | | Bronchiectasis | 18 |
| | | Emphysema | 10 |
| | | Pneumonia | 72 |
| | | Pleural effusion | 94 |
| Pancreas | 3328 | Pancreatic cancer | 29 |
| | | Atrophy | 37 |
| | | Pancreatitis | 77 |
| | | Pancreatic duct dilatation | 94 |
| | | Steatosis | 45 |
| Portal vein | 3410 | Hypertension | 54 |
| | | Thrombosis | 55 |
| Small Intestine | 3248 | Gas | 188 |
| | | Effusion | 142 |
| | | Obstruction | 61 |
| | | Diverticulum | 113 |
| | | Intussusception | 10 |
| Spleen | 3352 | Hemangioma | 47 |
| | | Infarction | 22 |
| | | Splenomegaly | 353 |
| Stomach | 3373 | Gastric wall thickening | 206 |
| | | Stomach cancer | 117 |
| Sacrum | 3242 | Osteiti | 17 |

Table 11: Detailed zero-shot performance of our method on each abnormality.

| Anatomy | Abnormality | AUC | ACC | Spec | Sens |
|-----------------|-----------------------------------|------|------|------|------|
| Adrenal gland | Thickening | 64.6 | 62.1 | 64.8 | 59.4 |
| | Nodule | 66.8 | 64.8 | 63.0 | 66.7 |
| Bladder | Diverticulum | 85.9 | 77.8 | 74.6 | 81.0 |
| | Stones | 82.0 | 75.7 | 80.0 | 71.4 |
| Colon | Gas Accumulation | 88.7 | 80.8 | 78.6 | 82.9 |
| | Effusion | 87.6 | 80.4 | 78.7 | 82.0 |
| | Obstruction | 99.5 | 98.6 | 97.2 | 100 |
| | Diverticulum | 71.7 | 68.7 | 65.3 | 72.1 |
| | Colorectal Cancer | 72.6 | 64.6 | 65.6 | 63.5 |
| | Rectal Cancer | 85.4 | 77.0 | 82.8 | 71.2 |
| | Appendicitis | 74.9 | 71.9 | 70.2 | 73.7 |
| | Appendicolith | 65.7 | 63.1 | 62.6 | 63.5 |
| Esophagus | Hiatal Hernia | 97.7 | 92.6 | 95.1 | 90 |
| | Varicose Veins | 98.8 | 97.9 | 97.1 | 98.7 |
| Gallbladder | Cholecystitis | 67.3 | 62.7 | 61.1 | 64.2 |
| | Gallstone | 64.6 | 61.8 | 58.3 | 65.4 |
| | Adenomyomatosis | 62.6 | 61.0 | 57.0 | 65.0 |
| Heart | Cardiomegaly | 95.1 | 88.7 | 87.3 | 90.0 |
| | Pericardial Effusion | 76.5 | 74.4 | 64.4 | 84.4 |
| Kidney | Atrophy | 96.0 | 91.5 | 91.1 | 91.9 |
| | Cyst | 68.6 | 63.1 | 64.3 | 61.8 |
| | Hydronephrosis | 75.7 | 69.5 | 78.1 | 60.9 |
| | Calculi | 57.9 | 56.6 | 56.4 | 56.9 |
| Liver | Steatosis | 93.3 | 85.1 | 84.6 | 85.6 |
| | Glisson’s Capsule Effusion | 86.5 | 78.9 | 82.7 | 75.0 |
| | Metastase | 78.8 | 71.6 | 70.3 | 73.0 |
| | Intrahepatic Bile Duct Dilatation | 76.8 | 70.8 | 68.2 | 73.5 |
| | Cancer | 84.9 | 79.1 | 77.8 | 80.3 |
| | Cyst | 62.9 | 59.4 | 61.4 | 57.3 |
| | Abscess | 81.8 | 79.5 | 75.7 | 83.3 |
| | Cirrhosis | 94.7 | 88.5 | 87.5 | 89.4 |
| Lung | Atelectasis | 94.8 | 89.4 | 89.4 | 89.3 |
| | Bronchiectasis | 81.6 | 74.1 | 76.0 | 72.2 |
| | Emphysema | 75.0 | 69.3 | 68.6 | 70.0 |
| | Pneumonia | 72.8 | 69.0 | 79.8 | 58.2 |
| | Pleural Effusion | 86.7 | 81.3 | 80.5 | 82.0 |
| Pancreas | Pancreatic Cancer | 87.0 | 79.7 | 80.2 | 79.3 |
| | Atrophy | 86.4 | 77.3 | 76.3 | 78.4 |
| | Pancreatitis | 91.0 | 87.6 | 93.3 | 81.8 |
| | Pancreatic Duct Dilatation | 77.2 | 70.9 | 75.8 | 66.0 |
| | Steatosis | 84.9 | 75.7 | 78.1 | 73.3 |
| Portal vein | Hypertension | 96.8 | 92.2 | 95.5 | 88.9 |
| | Thrombosis | 96.6 | 91.8 | 90.8 | 92.7 |
| Small Intestine | Gas Accumulation | 84.1 | 77.2 | 84.7 | 69.7 |
| | Effusion | 81.5 | 74.2 | 72.4 | 76.1 |
| | Obstruction | 95.2 | 90.5 | 92.6 | 88.5 |
| | Diverticulum | 73.0 | 67.1 | 65.1 | 69.0 |
| | Intussusception | 76.5 | 72.4 | 78.0 | 66.7 |
| Spleen | Hemangioma | 63.8 | 60.6 | 59.5 | 61.7 |
| | Infarction | 89.7 | 86.2 | 90.6 | 81.8 |
| | Splenomegaly | 92.4 | 84.8 | 83.8 | 85.8 |
| Stomach | Gastric Wall Thickening | 69.6 | 65.7 | 62.5 | 68.9 |
| | Gastric Cancer | 78.7 | 72.0 | 73.1 | 70.9 |
| Sacrum | Osteiti | 87.5 | 85.8 | 83.3 | 88.2 |
| Average | | 81.3 | 76.2 | 76.5 | 75.8 |