

# **Improving Radiology Report Conciseness and Structure via Local Large Language Models**

Iryna Hartsock, PhD<sup>1</sup>, Cyrillo Araujo, MD<sup>2</sup>, Les Folio, DO, MPH, ACHIP, CIIP<sup>2</sup>, and  
Ghulam Rasool, PhD<sup>1</sup>

<sup>1</sup>Department of Machine Learning,

<sup>2</sup>Department of Diagnostic Imaging and Interventional Radiology

Moffitt Cancer Center and Research Institute, Tampa, FL, USA

Corresponding author: ghulam.rasool@moffitt.org

**This study demonstrates that open-source large language models (LLMs) run locally behind institutional firewalls can improve the conciseness and structure of radiology reports by eliminating redundancies and organizing findings by organs, thus enhancing clarity and accessibility for referring physicians.**

**Keywords:** radiology reports, large language models, conciseness, structure

**Abbreviations:** Large Language Model (LLM), Conciseness Percentage (CP), Application Programming Interface (API), Artificial Intelligence (AI)

## **Key Points**

- Locally-run LLMs behind institutional firewalls improve the conciseness and structure of radiology reports while keeping data secure.
- Condensing the radiology report before applying specific formatting instructions is an effective prompting strategy for creating concise, well-structured radiology reports.

## **Abstract**

**Purpose:** We aim to improve radiology reporting by enhancing report conciseness and structuring (also known as templating) the findings according to organs, enabling physicians to locate relevant information quickly.

**Materials and Methods:** We employ LLMs (e.g., Mixtral, Mistral, and Llama) to create concise, well-structured reports, primarily focusing on the Mixtral model due to its superior adherence to a specific output formatting requirement compared to other models. We run these LLMs locally behind our institution's firewall, ensuring the safety and privacy of data. In addition, we utilize the LangChain framework and five different prompt approaches to enforce a specific structure in radiology reporting and remove excessive words and phrases to enhance the conciseness of reports. We introduce a new metric, the Conciseness Percentage (CP) score, to evaluate report conciseness. Our dataset comprises 814 radiology reports from seven board-certified body radiologists from our cancer center.

**Results:** Our study evaluated various prompting approaches to condensing and structure radiology reports. Our results demonstrate that first prompting the LLM to make the report concise and then structuring it according to specific instructions given in the prompt is the best approach for creating concise, well-structured reports. We assessed all prompting methods based on how they handled formatting errors, reduced report length, and followed formatting instructions.

**Conclusion:** We show that open-source and locally run LLMs can improve the conciseness and structure of radiology reports according to specific instructions.

## Introduction

A significant challenge in radiology reporting is that reports tend to be overly verbose and poorly structured, making it difficult for referring physicians to discern crucial findings and potentially overlooking important information (1,2). Implementing structured (templated) reporting methods provides a viable solution, enabling physicians to access relevant information efficiently (3–5). Imaging findings can be structured in various ways, such as organizing them from head-to-toe, prioritizing from the most critical to the least important, and/or itemizing them by specific organs (6,7). Removing redundancies, unnecessary words, and phrases from a radiology report without compromising its meaning further enhances interpretation efficiency (8,9). Ultimately, well-structured and concise radiology reporting is not just about documentation; it is crucial for delivering high-quality healthcare (2,3,10).

In recent years, numerous studies have explored using LLMs to improve the readability of radiology reports (11–14). LLMs are powerful artificial intelligence (AI) models capable of analyzing and generating human-like natural language text (15–19). For instance, Jeblick et al. used ChatGPT to simplify radiology reports for a child's understanding (11). While 15 radiologists generally found the simplified reports to be factually accurate and not harmful, some noted errors and overlooked details. Adams et al. employed GPT-4 to transform 170 free-text CT and MRI reports into structured formats by selecting the best templates from a predefined list, achieving successful conversions for all reports (12). Additionally, Mallio et al. demonstrated the efficacy of ChatGPT-3.5 Turbo and GPT-4 models in reducing the verbosity of radiology reports (13). However, a key limitation of these three studies is the use of application programming interfaces (APIs) or LLMs provided as a service on the Internet, which often involves sharing data with third parties or using synthetically-generated radiology reports (11–13). Using external LLMs raises concerns regarding data privacy, security, adherence to

regulations such as the Health Insurance Portability and Accountability Act (HIPAA) (20,21), and growing usage costs.

In our IRB-approved study, we run state-of-the-art LLMs such as Mixtral (15), Mistral (16), and Llama 3 (18) locally on a Windows Desktop computer with a standard GPU. This helps us keep patient data within our healthcare institution's secure infrastructure, reducing the risk of unauthorized access. Our findings show that these LLMs not only improve radiology reports by making them concise and well-structured but also enhance data security and standardization in reporting practices.

## **Materials and Methods**

### **Radiology Reports**

In this retrospective IRB-approved quality improvement study, we sample 814 radiology reports collected from seven board-certified body radiologists at our Cancer Center. The reports were generated from CT exams of the chest, abdomen, and pelvis and were written in the years 2023 and 2024. Each report comprises two sections: "Findings", which describes medical observations in these regions, and "Impressions", which summarizes key findings. The length of the reports varies from 182 to 981 words, with a mean of 372 words and a median of 344 words. While most reports are structured by organs, they lack a consistent formatting style due to differing approaches among radiologists. Before analysis, all reports were de-identified to ensure patient confidentiality.

### **Large Language Models (LLMs)**

The study employs the Mixtral 8x7B LLM, which utilizes a sparse mixture-of-experts (SMoE) architecture with a total of 56B parameters (i.e., eight experts, each with approximately 7B parameters) (15). For efficiency, the study employed pre-existing 6Q quantized weights of

Mixtral. In the Mixtral architecture, each layer incorporates eight distinct feedforward expert blocks. During inference, based on the specific characteristics of each token, two out of these eight experts are selected to process the input, and thus, only 14B parameters are active during inference. Mixtral benefits from a substantially large context window of 32,768 tokens and was pre-trained on multilingual data extracted from the open web (15). Mixtral was selected over other LLMs, including Mistral 7B (16) and Llama 3 8B (18), due to its superior adherence to a specific output formatting requirement compared to other models. All LLMs were run locally behind a secure firewall using the Ollama framework to ensure data security and privacy (22). The temperature of the LLMs was set to zero to reduce randomness and ensure more consistent outputs.

### **Prompt Engineering (In-Context Learning)**

We employed the LangChain library to programmatically prompt LLMs (23). The LLMs used in our experiments were downloaded from the Ollama store and were not fine-tuned or updated in any manner. Each report was processed with one or two calls to the LLM to enforce adherence to the structure depicted in **Figure 1**. Our study explored five distinct prompt approaches:

- Structure: This approach used only a single prompt to structure reports in a predefined format (see **Supplementary Figure 1**).
- Structure >> Conciseness: The LLM was initially prompted to structure the reports in a specified format. Subsequently, a second prompt instructed the model to refine the structured output further for conciseness. Thus, each report processing consisted of two calls to the LLM (see **Supplementary Figure 2**).
- Conciseness >> Structure: The LLM was first prompted to generate concise reports and then instructed to organize the concise information into a predefined structure. In this case, each report processing consisted of two calls to the LLM (see **Figure 2**).

- Structure + Conciseness: The LLM was prompted to structure reports in a predefined format while also emphasizing the need for conciseness. Both instructions were included in a single prompt (see **Supplementary Figure 3**).
- Structure + Conciseness (F, I): Given two prompts, the LLM was provided the entire report each time, with one prompt focusing on structuring the "Findings" section and the other the "Impressions" section, with both prompts emphasizing conciseness (see **Supplementary Figure 4**).

Occasionally, the LLM may fail to format a report according to the required structure, causing an abrupt termination of the Python program. To address this, we configured our code to use the 'OutputFixingParser,' which gives the LLM a second chance to correct formatting issues. This parser resubmits the mis-formatted output and the original instructions, asking the LLM to fix the errors. Our code can be found in the GitHub repository: [GitHub](#).

### **Concise Percentage (CP) Score**

We introduce a Concise Percentage (CP) score to evaluate the conciseness of the radiology reports by measuring the percentage of "meaningful" words in the report. Assuming that all words in the LLM-generated report are meaningful, the CP score is computed as follows:

$$CP\ Score = \frac{Total\ number\ of\ words\ in\ LLM\ generated\ Report}{Total\ number\ of\ words\ in\ Original\ Report} \times 100\%.$$

A CP score near 100% indicates that the original report was already relatively concise, requiring the LLM to remove a small number of words. Conversely, a lower CP score suggests that the original report was less concise and required significant condensation by the LLM. A CP score exceeding 100% is also possible, as the LLM can be verbose and add content, potentially lengthening rather than condensing the report. While the CP score is valuable for evaluating the LLM effectiveness in reducing unnecessary content and improving report conciseness, it does not fully reflect the clinical utility or relevance of a radiology report's content. Also, we may get a

different CP score for the same report due to the different prompts or models used for processing the report.

## Results

We processed radiology reports with different LLM prompting strategies, assessing their effectiveness in handling formatting errors, streamlining the unstructured radiology reports, and managing different radiologists' report writing styles.

### Formatting Errors of LLMs

We observed two types of formatting errors in the radiology reports processed by LLMs. The first type of error occurs when the LLM fails to structure a report according to the format shown in **Figure 1** after two attempts. In the second type of error, the LLM generates a list of individual letters from impressions rather than the full impressions. This results in an excessively long list of impressions and CP scores exceeding 100%. We excluded such reports from further analysis. Also, a report might have formatting issues with one prompting method but not others. In such cases, we excluded the report only for the problematic prompting approaches.

In this study, we focus on the Mixtral LLM, as it has the lowest rate of formatting errors compared to Mistral 7B (v0.2) and Llama 3 8B. Llama 3 8B struggled significantly with following the formatting instructions. For instance, under the "Conciseness >> Structure" prompting approach, Llama 3 8B caused formatting errors in 726 (89.2%) reports. The Mistral 7B performed more similarly to Mixtral in adhering to formatting instructions. Under the "Conciseness >> Structure" prompting approach, Mistral 7B produced formatting errors in 107 (13.1%) reports, while Mixtral had formatting errors only in 88 (10.8%) reports.

**Table 1** shows the number of reports streamlined by Mixtral without formatting errors for all radiologists and prompting strategies. Most of the formatting errors were of the first type. Interestingly, the "Structure + Conciseness (F, I)" strategy did not cause any errors of the second type, and only 24 reports from other approaches had such errors. The "Structure + Conciseness (F, I)" approach also had the lowest number of formatting errors, with only 23 (2.8%) reports being formatted incorrectly, as it used separate prompts for the "Findings" and

Radiologists	# Reports	Structure	Structure >> Conciseness	Conciseness >> Structure	Structure + Conciseness	Structure + Conciseness (F, I)
		# Reports w/o formatting errors	# Reports w/o formatting errors	# Reports w/o formatting errors	# Reports w/o formatting errors	# Reports w/o formatting errors
Radiologist 1	111	103	85	82	99	104
Radiologist 2	151	148	122	138	140	148
Radiologist 3	126	118	102	119	114	123
Radiologist 4	96	83	73	88	92	93
Radiologist 5	192	183	143	191	175	186
Radiologist 6	80	71	59	55	67	80
Radiologist 7	58	50	49	53	52	57
<b>Total</b>	814	756 (92.9%)	633 (77.8%)	726 (89.2%)	739 (90.8%)	791 (97.2%)

"Impressions" sections. Thus, the formatting error could only occur if both prompts failed after the second attempt. In contrast, the "Structure >> Conciseness" approach resulted in the highest number of formatting errors, with 181 (22.3%) reports affected. This strategy chains two



prompts, each enforcing the LLM to follow formatting instructions, so an error from any prompt in the chain impacts the entire approach. Other prompting approaches encountered formatting errors in 58 to 88 reports (7-11%).

### **Streamlining an Unstructured Radiology Report: A Case Study**

We applied the Mixtral LLM to the radiology report with unstructured findings (see **Figure 3 A**) to assess its ability to structure the report while enhancing its conciseness. The resulting structured and concise reports generated using five different prompting strategies are shown in **Figure 3 B-F**. All CP scores of the LLM-streamlined reports range from 49.7% to 62.4%. The "Structure" approach, which only prompts the LLM to follow formatting instructions without emphasizing conciseness, achieved the highest CP score and reduced the report length by 37.6%. The lowest CP scores had the "Conciseness >> Structure" and "Structure + Conciseness (F, I)" methods, indicating they made the reports the most concise.

We observed significant variation in how Mixtral handled the "Impressions" section. With the "Conciseness >> Structure" and "Structure + Conciseness (F, I)" approaches, Mixtral extracted and condensed content directly from the "Impressions" section as instructed. In contrast, with the other three strategies, Mixtral relied more on information from the "Findings" section to generate "Impressions", deviating from the intended prompt instructions.

While Mixtral processed the "Findings" section similarly across prompting approaches, we noticed several discrepancies. We instructed Mixtral to extract findings for an organ, specifying that "Unremarkable" should be used for normal findings and "None" for the absence of findings (see **Figure 2**). As shown in **Figure 3 B, E-F**, Mixtral incorrectly indicated no findings for the hepatobiliary system and adrenals, possibly due to failure to identify certain findings or misclassifying them as "None".

Additionally, we noticed that Mixtral can attribute the same clinical findings to multiple organs simultaneously. For example, in **Figure 3 E**, Mixtral added "general osteopenia with moderate degenerative changes in the thoracic and lumbar spine" as a medical finding of other abdominal and pelvic organs as well as bones and soft tissues. Sometimes, the LLM can place findings under one organ when they are more relevant to another. For instance, in **Figure 3 E**, the finding "Slightly prominent mediastinal lymph nodes likely related to heart failure" was listed under other chest findings instead of mediastinum.

### **Evaluation of Conciseness and Prompting Approaches Across Radiologists**

For each participating radiologist, we computed the CP scores for their sampled reports using five prompting approaches. These scores are represented using boxplots in **Figure 4**, illustrating their distribution, quartiles, and outliers. The figure also reveals consistent trends in concise report writing among radiologists, with Radiologist 1 producing the least concise reports and Radiologist 7 the most concise, regardless of the prompting method. **Figure 5** compares the average word count of original reports and their successfully LLM-processed versions (where  $CP \leq 100\%$ ) using the "Conciseness >> Structure" strategy across all radiologists. Similarly, it also compares the total word count for a sample of reports, illustrating Mixtral's effectiveness in reducing verbosity.

**Table 2** summarizes the number of reports with CP scores exceeding 100% for each prompting approach and radiologist. The largest number of such reports, namely 36 (4.4%) reports, was recorded for the "Structure + Conciseness (F, I)" approach. Other methods had fewer occurrences, with no instances in the "Conciseness >> Structure" approach. In cases when CP > 100%, Mixtral often deviated from the prompting instructions, especially in the "Impressions" section, which listed most findings as impressions (see "Impressions" sections in **Figure 3 B-D** for examples).

Radiologists	# Reports	Structure	Structure >> Conciseness	Conciseness >> Structure	Structure + Conciseness	Structure + Conciseness (F, I)
		# Reports w/ CP > 100%	# Reports w/ CP > 100%	# Reports w/ CP > 100%	# Reports w/ CP > 100%	# Reports w/ CP > 100%
Radiologist 1	111	1	0	0	0	2
Radiologist 2	151	0	0	0	0	1
Radiologist 3	126	3	0	0	0	10
Radiologist 4	96	1	0	0	0	11
Radiologist 5	192	7	0	0	2	5
Radiologist 6	80	3	2	0	4	6
Radiologist 7	58	1	0	0	1	1
<b>Total</b>	814	16 (2.0%)	2 (0.2%)	0 (0.0%)	7 (0.9%)	36 (4.4%)

We also observed that Mixtral can overlook clinical findings in one or more organs, especially when those findings are unremarkable, marking them as "None". This occurred in three out of ten random reports per radiologist using the "Conciseness >> Structure" approach and in six out of ten reports with every other prompting strategy.

## **Discussion**

In this study, we demonstrated that LLMs, locally run behind institutional firewalls on a Windows Desktop with GeForce RTX 3060 GPU with 12 Gigabytes of VRAM, can effectively enhance the conciseness and structure of radiology reports. When we refer to "structured reports", we mean reports that are "templated" by organs, which differs from the ACR RADS definition that includes detailed categorization and management recommendations, potentially incorporating CDE macros (modules). In our initial experiments, we utilized several state-of-the-art open-source LLMs like Mixtral (15), Mistral (16), and Llama 3 (18). However, we focused our efforts on Mixtral due to its comparatively lower rate of formatting errors. We evaluated five different prompting methods using Mixtral across 814 radiology reports of the chest, abdomen and pelvis written by seven body radiologists, assessing the Mixtral's ability to reduce report length, minimize formatting issues, and follow prompt instructions. To our knowledge, this study is among the first to explore the application of LLMs in private, resource-constrained environments for processing radiology reports, underscoring the potential of locally deployed models in clinical settings.

Among the various prompting strategies tested, the "Conciseness >> Structure" approach proved to be the most effective. This method prioritized conciseness first, followed by addressing formatting issues, and excelled in keeping the report length within the original limits while adhering closely to the prompting instructions. We believe this strategy is superior because condensing the radiology reports first simplifies the subsequent formatting task,

reducing the risk of omitting relevant details during the formatting phase. Notably, the "Structure + Conciseness (F, I)" approach, which prompted the LLM separately for the "Findings" and "Impressions" sections, yielded the fewest formatting errors among all methods. This suggests that focused prompting for specific sections can improve accuracy in structure without compromising content.

We proposed using the CP score to evaluate the conciseness of radiology reports before and after processing by LLMs. By measuring the percentage of "meaningful" words, the CP score highlights opportunities to reduce report length while preserving essential content. However, caution is warranted when using this metric, as not all words contribute equally to the clinical relevance of a report. Certain words or phrases, though they increase the word count, may be vital for clinical interpretation, and removing them in the pursuit of conciseness could compromise the report's accuracy. The CP score can facilitate peer benchmarking, motivating radiologists to improve conciseness while maintaining both clinical relevance and informational integrity. Incorporating the CP score into training programs could further support radiology residents in tracking their progress in producing concise reports. Nevertheless, the CP score should not solely drive decisions about content reduction, as the clinical significance of specific details may outweigh the benefits of brevity and conciseness.

We observed several limitations that may be associated with the use of locally-run LLMs. One of the major challenges was the occurrence of formatting errors, which appeared in 23 to 181 reports across the five prompting strategies. These errors may be less frequent in API-based LLMs, which are often more robust due to extensive pre-training and broader infrastructure. Additionally, despite our efforts to ensure that Mixtral followed prompt instructions accurately, it occasionally missed key medical findings, particularly for organs such as the hepatobiliary system, pancreas, spleen, and adrenals, incorrectly marking them as "None." This issue was

least frequent with the "Conciseness >> Structure" approach. However, it is important to note that this limitation is not unique to smaller, locally-run LLMs; larger API-based models can also struggle to follow prompts accurately under certain conditions. Another notable issue was that 61 LLM-processed reports ended up longer than the original versions, contrary to the objective of producing concise outputs. On rare occasions, Mixtral even assigned medical findings to multiple organs simultaneously or to less relevant organs, further highlighting the need for ongoing refinement in prompting strategies and model training/fine-tuning. However, we intentionally limited our current study to prompt-only without any model fine-tuning.

In summary, our study demonstrates Mixtral's capability to streamline and structure radiology reports, with the "Conciseness >> Structure" prompting approach proving particularly effective. Despite these strengths, challenges such as formatting errors and the omission of medical findings for certain organs persist. Future work will focus on addressing these limitations through prompt refinement, expanding the LLM's vocabulary to include missing medical terminology, and incorporating feedback from participating radiologists. Additionally, model fine-tuning will be explored to improve performance in clinical contexts. These enhancements will contribute to more precise and clinically relevant report generation, ultimately advancing the practical application of LLMs in medical environments.

## References

1. Wallis A, McCoubrie P. The radiology report — Are we getting the message across? *Clin Radiol*. 2011;66:1015–1022. doi: 10.1016/j.crad.2011.05.013.
2. Franconeri A, Fang J, Carney B, Justaniah A, Miller L, Hur H-C, King LP, Alammari R, Faintuch S, Morteles KJ, et al. Structured vs narrative reporting of pelvic MRI for fibroids: clarity and impact on treatment planning. *Eur Radiol*. 2018;28:3009–3017. doi: 10.1007/s00330-017-5161-9.
3. Jorg T, Heckmann JC, Mildemberger P, Hahn F, Düber C, Mildemberger P, Kloeckner R, Jungmann F. Structured reporting of CT scans of patients with trauma leads to faster, more detailed diagnoses: An experimental study. *Eur J Radiol*. 2021;144:109954. doi: 10.1016/j.ejrad.2021.109954.

4. Kim SH, Sobez LM, Spiro JE, Curta A, Ceelen F, Kampmann E, Goepfert M, Bodensohn R, Meinel FG, Sommer WH, et al. Structured reporting has the potential to reduce reporting times of dual-energy x-ray absorptiometry exams. *BMC Musculoskelet Disord*. 2020;21:248. doi: 10.1186/s12891-020-03200-w.
5. Schwartz LH, Panicek DM, Berk AR, Li Y, Hricak H. Improving Communication of Diagnostic Radiology Findings through Structured Reporting. *Radiology*. 2011;260:174–181. doi: 10.1148/radiol.11101913.
6. Nobel JM, Kok EM, Robben SGF. Redefining the structure of structured reporting in radiology. *Insights Imaging*. 2020;11:10. doi: 10.1186/s13244-019-0831-6.
7. Siström CL, Langlotz CP. A framework for improving radiology reporting. *Journal of the American College of Radiology*. 2005;2:159–167. doi: 10.1016/j.jacr.2004.06.015.
8. Hartung MP, Bickle IC, Gaillard F, Kanne JP. How to Create a Great Radiology Report. *RadioGraphics*. 2020;40:1658–1670. doi: 10.1148/rg.2020200020.
9. Webster Riggs. Making a case for concise narrative radiology reports. *Appl Radiol*. 2015;44:4–6.
10. Schoeppe F, Sommer WH, Nörenberg D, Verbeek M, Bogner C, Westphalen CB, Dreyling M, Rummeny EJ, Fingerle AA. Structured reporting adds clinical value in primary CT staging of diffuse large B-cell lymphoma. *Eur Radiol*. 2018;28:3702–3709. doi: 10.1007/s00330-018-5340-3.
11. Jeblick K, Schachtner B, Dextl J, Mittermeier A, Stüber AT, Topalis J, Weber T, Wesp P, Sabel BO, Ricke J, et al. ChatGPT makes medicine easy to swallow: an exploratory case study on simplified radiology reports. *Eur Radiol*. 2023;34:2817–2825. doi: 10.1007/s00330-023-10213-1.
12. Adams LC, Truhn D, Busch F, Kader A, Niehues SM, Makowski MR, Bressan KK. Leveraging GPT-4 for Post Hoc Transformation of Free-text Radiology Reports into Structured Reporting: A Multilingual Feasibility Study. *Radiology*. 2023;307. doi: 10.1148/radiol.230725.
13. Mallio CA, Bernetti C, Sertorio AC, Zobel BB. ChatGPT in radiology structured reporting: analysis of ChatGPT-3.5 Turbo and GPT-4 in reducing word count and recalling findings. *Quant Imaging Med Surg*. 2024;14:2096–2102. doi: 10.21037/qims-23-1300.
14. Butler JJ, Puleo J, Harrington MC, Dahmen J, Rosenbaum AJ, Kerkhoffs GMMJ, Kennedy JG. From technical to understandable: Artificial Intelligence Large Language Models improve the readability of knee radiology reports. *Knee Surgery, Sports Traumatology, Arthroscopy*. 2024;32:1077–1086. doi: 10.1002/ksa.12133.
15. Jiang AQ, Sablayrolles A, Roux A, Mensch A, Savary B, Bamford C, Chaplot DS, Casas D de las, Hanna EB, Bressand F, et al. Mixtral of Experts. 2024;
16. Jiang AQ, Sablayrolles A, Mensch A, Bamford C, Chaplot DS, Casas D de las, Bressand F, Lengyel G, Lample G, Saulnier L, et al. Mistral 7B. 2023;
17. Touvron H, Martin L, Stone K, Albert P, Almahairi A, Babaei Y, Bashlykov N, Batra S, Bhargava P, Bhosale S, et al. Llama 2: Open Foundation and Fine-Tuned Chat Models. 2023;
18. Dubey A, Jauhri A, Pandey A, Kadian A, Al-Dahle A, Letman A, Mathur A, Schelten A, Yang A, Fan A, et al. The Llama 3 Herd of Models. 2024;
19. OpenAI, Achiam J, Adler S, Agarwal S, Ahmad L, Akkaya I, Aleman FL, Almeida D, Altenschmidt J, Altman S, et al. GPT-4 Technical Report. 2023;

20. Rosenbloom ST, Smith JRL, Bowen R, Burns J, Riplinger L, Payne TH. Updating HIPAA for the electronic medical record era. *Journal of the American Medical Informatics Association*. 2019;26:1115–1119. doi: 10.1093/jamia/ocz090.
21. Hjerpe K, Ruohonen J, Leppanen V. The General Data Protection Regulation: Requirements, Architectures, and Constraints. 2019 IEEE 27th International Requirements Engineering Conference (RE). IEEE; 2019. p. 265–275.
22. Ollama [Internet]. [cited 2024 Oct 13]. Available from: <https://ollama.com>.
23. LangChain [Internet]. [cited 2024 Oct 13]. Available from: <https://www.langchain.com>.



**FINDINGS:**

*Lines/tubes/devices:*

**CHEST:**

*Lower neck/Thyroid:*

*Mediastinum:*

*Lungs/Pleural spaces:*

*Other:*

**ABDOMEN AND PELVIS:**

*Hepatobiliary system:*

*Spleen:*

*Pancreas:*

*Adrenals:*

*Kidneys/Ureters:*

*GI tract:*

*Peritoneum/Mesentery, Retroperitoneum, Vasculature, and nodes:*

*Reproductive organs:*

*Bladder:*

*Other:*

**BONES AND SOFT TISSUES:****IMPRESSIONS:**

- 1.
- 2.
- ...

**Figure 1.** The structure of a radiology report, with organs and sub-organs ordered from head to toe, makes it intuitive and predictable for readers to quickly locate the necessary information. All five prompts proposed in this study use this structure as a template for the LLMs to follow when processing radiology reports. Thus, regardless of which radiologist writes the initial report, the LLM should generate a radiology report that adheres to this structured format.

## Prompts

**prompt1** = "Make {original\_report} concise by eliminating redundancies and unnecessary phrases such as 'no findings', 'no significant findings', 'none mentioned', 'there is', 'there are', 'at this time', 'at the present time', 'evaluated by', 'normal limits', etc. Eliminate phrases about abnormalities that are not found in the organs, for example, 'no suspicious liver mass'."

**prompt2** = "" Extract findings corresponding to organs and areas listed below from FINDINGS section and the radiologist's impressions from IMPRESSIONS section.

Report: {concise\_report}

{format\_instructions}

## Format Instructions

**Devices** = ResponseSchema(name = "Devices", description = "Medical lines, tubes, or devices present in a patient's body. If no lines, tubes, or devices are mentioned, write None.")

**Thyroid** = ResponseSchema(name = "Thyroid", description = "Findings of the lower neck, thoracic inlet, and thyroid. If findings are normal, write Unremarkable. If no findings are mentioned, write None.")

**Mediastinum** = ResponseSchema(name = "Mediastinum", description = "Findings of the mediastinum (heart, heart vessels, esophagus, and large airways). If findings are normal, write Unremarkable. If no findings are mentioned, write None.")

**Lungs** = ResponseSchema(name = "Lungs", description = "Findings of the lungs and pleural spaces. If findings are normal, write Unremarkable. If no findings are mentioned, write None.")

**Other\_chest\_findings** = ResponseSchema(name = "Other\_chest\_findings", description = "Findings of other organs and areas in the chest (e.g., axilla, breast, chest wall, diaphragm, retroareola). If findings are normal, write Unremarkable. If no findings are mentioned, write None.")

**Hepatobiliary** = ResponseSchema(name = "Hepatobiliary", description = "Findings of the hepatobiliary system (liver, biliary system, and gallbladder). If findings are normal, write Unremarkable. If no findings are mentioned, write None.")

**Spleen** = ResponseSchema(name = "Spleen", description = "Findings of the spleen. If findings are normal, write Unremarkable. If no findings are mentioned, write None.")

**Pancreas** = ResponseSchema(name = "Pancreas", description = "Findings of the pancreas. If findings are normal, write Unremarkable. If no findings are mentioned, write None.")

**Adrenals** = ResponseSchema(name = "Adrenals", description = "Findings of the adrenals. If findings are normal, write Unremarkable. If no findings are mentioned, write None.")

**Kidneys** = ResponseSchema(name = "Kidneys", description = "Findings of the kidneys and ureters. If findings are normal, write Unremarkable. If no findings are mentioned, write None.")

**GI\_tract** = ResponseSchema(name = "GI\_tract", description = "Findings of the GI tract (stomach, bowel, rectum, colon). If findings are normal, write Unremarkable. If no findings are mentioned, write None.")

**Peritoneum\_mesentery\_retroperitoneum\_vasculature** = ResponseSchema(name = "Peritoneum\_mesentery\_retroperitoneum\_vasculature", description = "Findings of the peritoneum, mesentery, retroperitoneum, vasculature, and pelvic lymph nodes. If findings are normal, write Unremarkable. If no findings are mentioned, write None.")

**Reproductive\_organs** = ResponseSchema(name = "Reproductive\_organs", description = "Findings of the reproductive organs (e.g., uterus, ovaries, vagina, prostate, testicles, penis). If findings are normal, write Unremarkable. If no findings are mentioned, write None.")

**Bladder** = ResponseSchema(name = "Bladder", description = "Findings of the bladder. If findings are normal, write Unremarkable. If no findings are mentioned, write None.")

**Other\_pelvis\_and\_abdomen\_findings** = ResponseSchema(name = "Other\_pelvis\_and\_abdomen\_findings", description = "Findings of other organs and areas in the pelvis and abdomen (e.g., Bartholin's gland, groin, inguinal region, pelvic floor, proximal thigh, spermatic cord, vulva). If findings are normal, write Unremarkable. If no findings are mentioned, write None.")

**Bones** = ResponseSchema(name = "Bones", description = "Findings of the bones and soft tissues. If findings are normal, write Unremarkable. If no findings are mentioned, write None.")

**IMPRESSIONS** = ResponseSchema(name = "IMPRESSIONS", description = "Radiologist's impressions from IMPRESSIONS section organized in a list. Do not create any new impressions and do not include clinically insignificant impressions.")

**Figure 2.** The prompts and formatting instructions used in the "Conciseness >> Structure"

prompting approach involve two steps to process the given radiology report. In the first step (prompt 1), the LLM is instructed to make the input radiology report more concise. In the second step (prompt 2), the LLM receives further instructions to structure the concise report according

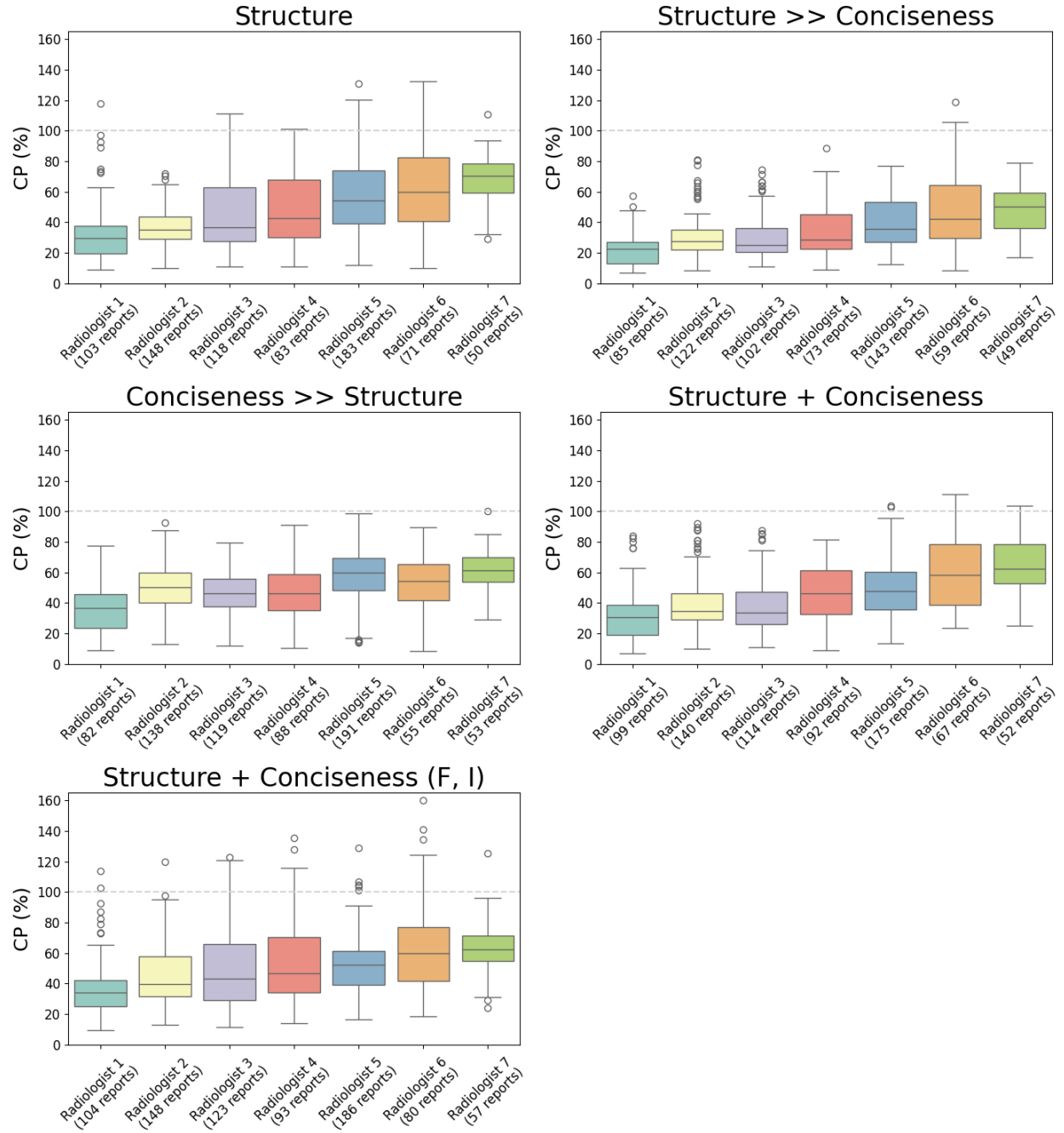
to specific formatting guidelines, as shown in **Figure 1**. This two-step approach attempts to ensure that the output report is both concise and well-structured.



A Original Report (388 words)	B LLM-processed report, Structure (242 words) CP = 62.4%	C LLM-processed report, Structure + Conciseness (219 words) CP = 56.4%
<p><b>FINDINGS:</b></p> <p><i>Lines/tubes/devices:</i> Central line present with its tip in the right atrium</p> <p><b>CHEST:</b></p> <p><i>Lower neck/Thyroid:</i> Large heterogeneously enhancing mass in the left lobe of the thyroid. This is unchanged since the previous examination. The mass causes slight compression of the trachea at the thoracic inlet and deviated slightly to the right.</p> <p>Again noted on this examination are slightly prominent mediastinal lymph nodes. These are slightly smaller than on the previous examination and likely are related to the cardiomegaly and chronic congestive heart failure rather than metastatic disease.</p> <p>The heart is enlarged with scattered coronary artery calcifications. A central line is present with its tip in the right atrium.</p> <p>A small pericardial effusion is present and is smaller than it was on previous study.</p> <p>No pleural effusions are seen.</p> <p>On lung windows, no parenchymal masses or acute infiltrates are seen. The groundglass density, probably due to pulmonary edema, seen on the previous examination has resolved.</p> <p>Scanning through the abdomen demonstrates no free fluid. No masses are seen in the liver. No adrenal masses are seen.</p> <p>The pancreas and spleen are normal.</p> <p>No renal masses are seen. The right kidney is slightly atrophic compared to the left. No hydronephrosis is seen.</p> <p>No periaortic or mesenteric adenopathy is seen. Again noted on this examination is mild soft tissue thickening around loops of distal small bowel in the right lower abdomen. This is stable since prior studies and likely not clinically significant.</p> <p>Scanning through the pelvis demonstrates the uterus to be absent. The ovaries are visualized.</p> <p>Perirectal fat stranding is again noted and unchanged since previous study. The rectal wall thickening is less than it was on previous examination. There is no evidence of bowel obstruction.</p> <p>A small perirectal lymph node remains 0.3 cm in diameter which is unchanged since previous examination.</p> <p>The bladder is nondistended. No bladder masses are seen.</p> <p>On bone windows, the bones are generally osteopenic. There are moderate degenerative changes throughout the thoracic and lumbar spine.</p> <p><b>IMPRESSIONS:</b></p> <ol style="list-style-type: none"> <li>1. Improved congestive heart failure and pulmonary edema since prior study from 9/16/2023. The groundglass density in the lungs has resolved and the mediastinal lymph nodes have decreased in size. The pericardial effusion is also slightly smaller in the interval. The heart remains enlarged.</li> <li>2. No evidence of tumor recurrence in the rectum.</li> <li>3. Small perirectal lymph node remains stable.</li> <li>4. No new abnormalities are seen.</li> </ol>	<p><b>FINDINGS:</b></p> <p><i>Lines/tubes/devices:</i> Central line present with its tip in the right atrium</p> <p><b>CHEST:</b></p> <p><i>Lower neck/Thyroid:</i> Large heterogeneously enhancing mass in the left lobe of the thyroid causing slight compression of the trachea</p> <p><i>Mediastinum:</i> Enlarged heart with scattered coronary artery calcifications and slightly prominent mediastinal lymph nodes</p> <p><i>Lungs/Pleural spaces:</i> No parenchymal masses or acute infiltrates, groundglass density probably due to pulmonary edema has resolved</p> <p><i>Other:</i> Small pericardial effusion</p> <p><b>ABDOMEN AND PELVIS:</b></p> <p><i>Hepatobiliary system:</i> None</p> <p><i>Spleen:</i> Unremarkable</p> <p><i>Pancreas:</i> Unremarkable</p> <p><i>Adrenals:</i> None</p> <p><i>Kidneys/Ureters:</i> Right kidney slightly atrophic compared to the left, no hydronephrosis</p> <p><i>GI tract:</i> Mild soft tissue thickening around loops of distal small bowel in the right lower abdomen, rectal wall thickening less than previous examination</p> <p><i>Peritoneum/Mesentery, Retroperitoneum, Vasculature, and nodes:</i> No free fluid, no periaortic or mesenteric adenopathy</p> <p><i>Reproductive organs:</i> Uterus absent, ovaries visualized</p> <p><i>Bladder:</i> Nondistended, no bladder masses</p> <p><i>Other:</i> Perirectal fat stranding, small perirectal lymph node</p> <p><b>BONES AND SOFT TISSUES:</b> Osteopenic bones with moderate degenerative changes throughout the thoracic and lumbar spine</p> <p><b>IMPRESSIONS:</b></p> <ol style="list-style-type: none"> <li>1. Large left thyroid lobe mass with tracheal deviation</li> <li>2. Enlarged heart with coronary artery calcifications</li> <li>3. Resolution of groundglass opacity in lungs, likely due to resolved pulmonary edema</li> <li>4. Small pericardial effusion</li> <li>5. Mild small bowel wall thickening in right lower quadrant</li> <li>6. Absent uterus and visualized ovaries</li> <li>7. Perirectal fat stranding with a small perirectal lymph node</li> <li>8. Osteopenic bones with moderate degenerative changes throughout the thoracic and lumbar spine</li> </ol>	<p><b>FINDINGS:</b></p> <p><i>Lines/tubes/devices:</i> Central line in right atrium</p> <p><b>CHEST:</b></p> <p><i>Lower neck/Thyroid:</i> Large heterogeneously enhancing mass in left lobe of thyroid with mild compression and deviation of trachea</p> <p><i>Mediastinum:</i> Enlarged heart with scattered coronary artery calcifications, slightly prominent mediastinal lymph nodes likely related to cardiomegaly and chronic congestive heart failure</p> <p><i>Lungs/Pleural spaces:</i> Improved congestive heart failure and pulmonary edema since prior study. No parenchymal masses or acute infiltrates.</p> <p><i>Other:</i> Unremarkable</p> <p><b>ABDOMEN AND PELVIS:</b></p> <p><i>Hepatobiliary system:</i> Unremarkable</p> <p><i>Spleen:</i> Unremarkable</p> <p><i>Pancreas:</i> Unremarkable</p> <p><i>Adrenals:</i> Unremarkable</p> <p><i>Kidneys/Ureters:</i> Right kidney slightly atrophic compared to left. No hydronephrosis.</p> <p><i>GI tract:</i> Mild soft tissue thickening around loops of distal small bowel in right lower abdomen, less rectal wall thickening than previous examination</p> <p><i>Peritoneum/Mesentery, Retroperitoneum, Vasculature, and nodes:</i> No free fluid, no masses, no periaortic or mesenteric lymphadenopathy</p> <p><i>Reproductive organs:</i> Absent uterus</p> <p><i>Bladder:</i> Unremarkable</p> <p><i>Other:</i> Unremarkable</p> <p><b>BONES AND SOFT TISSUES:</b> Unremarkable</p> <p><b>IMPRESSIONS:</b></p> <ol style="list-style-type: none"> <li>1. Improvement in congestive heart failure and pulmonary edema compared to prior study</li> <li>2. Large heterogeneously enhancing mass in left lobe of thyroid with mild compression and deviation of trachea</li> <li>3. Enlarged heart with scattered coronary artery calcifications, likely related to chronic congestive heart failure</li> <li>4. Slightly prominent mediastinal lymph nodes likely related to cardiomegaly and chronic congestive heart failure</li> <li>5. Right kidney slightly atrophic compared to left, no hydronephrosis</li> </ol>
D LLM-processed report, Structure >> Conciseness (222 words) CP = 57.2%	E LLM-processed report, Conciseness >> Structure (190 words) CP = 50.0%	F LLM-processed report, Structure + Conciseness (F, I) (193 words) CP = 49.7%
<p><b>FINDINGS:</b></p> <p><i>Lines/tubes/devices:</i> Central line present with its tip in the right atrium</p> <p><b>CHEST:</b></p> <p><i>Lower neck/Thyroid:</i> Large heterogeneously enhancing mass in left lobe causing tracheal compression and deviation to the right</p> <p><i>Mediastinum:</i> Slightly prominent mediastinal lymph nodes, enlarged heart with scattered coronary artery calcifications, small pericardial effusion</p> <p><i>Lungs/Pleural spaces:</i> Unremarkable</p> <p><i>Other:</i> Unremarkable</p> <p><b>ABDOMEN AND PELVIS:</b></p> <p><i>Hepatobiliary system:</i> Unremarkable</p> <p><i>Spleen:</i> Unremarkable</p> <p><i>Pancreas:</i> Unremarkable</p> <p><i>Adrenals:</i> Unremarkable</p> <p><i>Kidneys/Ureters:</i> Right kidney slightly atrophic compared to the left</p> <p><i>GI tract:</i> Mild soft tissue thickening around loops of distal small bowel in right lower abdomen, rectal wall thickening less than previous examination</p> <p><i>Peritoneum/Mesentery, Retroperitoneum, Vasculature, and nodes:</i> No free fluid. No periaortic or mesenteric adenopathy.</p> <p><i>Reproductive organs:</i> Uterus absent. Ovaries visualized.</p> <p><i>Bladder:</i> Nondistended. No bladder masses seen.</p> <p><i>Other:</i> Perirectal fat stranding and a small perirectal lymph node unchanged since previous examination</p> <p><b>BONES AND SOFT TISSUES:</b> Generally osteopenic with degenerative changes. No acute bone lesions.</p> <p><b>IMPRESSIONS:</b></p> <ol style="list-style-type: none"> <li>1. Large heterogeneously enhancing mass in left lobe of thyroid causing tracheal compression and deviation to the right</li> <li>2. Small pericardial effusion</li> <li>3. Right kidney slightly atrophic compared to the left</li> <li>4. Mild soft tissue thickening around loops of distal small bowel in right lower abdomen, rectal wall thickening less than previous examination</li> <li>5. Perirectal fat stranding and a small perirectal lymph node unchanged since previous examination</li> </ol>	<p><b>FINDINGS:</b></p> <p><i>Lines/tubes/devices:</i> Central line tip in the right atrium</p> <p><b>CHEST:</b></p> <p><i>Lower neck/Thyroid:</i> Large heterogeneously enhancing mass in the left lobe of the thyroid, slight trachea compression and deviation to the right</p> <p><i>Mediastinum:</i> Enlarged heart with scattered coronary artery calcifications, small pericardial effusion</p> <p><i>Lungs/Pleural spaces:</i> Unremarkable</p> <p><i>Other:</i> Slightly prominent mediastinal lymph nodes likely related to heart failure</p> <p><b>ABDOMEN AND PELVIS:</b></p> <p><i>Hepatobiliary system:</i> None</p> <p><i>Spleen:</i> Unremarkable</p> <p><i>Pancreas:</i> Unremarkable</p> <p><i>Adrenals:</i> None</p> <p><i>Kidneys/Ureters:</i> Right kidney slightly atrophic compared to the left, no hydronephrosis</p> <p><i>GI tract:</i> Mild soft tissue thickening around distal small bowel loops in the right lower abdomen</p> <p><i>Peritoneum/Mesentery, Retroperitoneum, Vasculature, and nodes:</i> None</p> <p><i>Reproductive organs:</i> Absent uterus, visualized ovaries</p> <p><i>Bladder:</i> Nondistended bladder with no masses</p> <p><i>Other:</i> Perirectal fat stranding, a 0.3 cm stable perirectal lymph node, general osteopenia with moderate degenerative changes in the thoracic and lumbar spine</p> <p><b>BONES AND SOFT TISSUES:</b> General osteopenia with moderate degenerative changes in the thoracic and lumbar spine</p> <p><b>IMPRESSIONS:</b></p> <ol style="list-style-type: none"> <li>1. Improved congestive heart failure and pulmonary edema since 9/16/2023 exam</li> <li>2. No tumor recurrence in rectum</li> <li>3. Stable small perirectal lymph node</li> <li>4. No new abnormalities detected</li> </ol>	<p><b>FINDINGS:</b></p> <p><i>Lines/tubes/devices:</i> Central line in right atrium</p> <p><b>CHEST:</b></p> <p><i>Lower neck/Thyroid:</i> Large heterogeneously enhancing mass in left lobe, slight compression of trachea and deviation to the right</p> <p><i>Mediastinum:</i> Enlarged heart with scattered coronary artery calcifications, slightly prominent mediastinal lymph nodes likely related to cardiomegaly and chronic congestive heart failure</p> <p><i>Lungs/Pleural spaces:</i> Resolved groundglass density, no parenchymal masses or acute infiltrates</p> <p><i>Other:</i> Small pericardial effusion</p> <p><b>ABDOMEN AND PELVIS:</b></p> <p><i>Hepatobiliary system:</i> None</p> <p><i>Spleen:</i> Unremarkable</p> <p><i>Pancreas:</i> Unremarkable</p> <p><i>Adrenals:</i> None</p> <p><i>Kidneys/Ureters:</i> Right kidney slightly atrophic, no hydronephrosis</p> <p><i>GI tract:</i> Mild soft tissue thickening around loops of distal small bowel in right lower abdomen, less rectal wall thickening than previous examination, perirectal fat stranding and lymph node unchanged</p> <p><i>Peritoneum/Mesentery, Retroperitoneum, Vasculature, and nodes:</i> No free fluid or masses, no periaortic or mesenteric adenopathy</p> <p><i>Reproductive organs:</i> Absent uterus, visualized ovaries</p> <p><i>Bladder:</i> Nondistended, no bladder masses</p> <p><i>Other:</i> None</p> <p><b>BONES AND SOFT TISSUES:</b> Generally osteopenic with moderate degenerative changes throughout the thoracolumbar spine</p> <p><b>IMPRESSIONS:</b></p> <ol style="list-style-type: none"> <li>1. Improved congestive heart failure and pulmonary edema since prior study from 9/16/2023</li> <li>2. No evidence of tumor recurrence in the rectum</li> <li>3. Small perirectal lymph node remains stable</li> </ol>

**Figure 3.** The performance of the Mixtral LLM on making the unstructured radiology report concise and well-structured under various prompting strategies. **(A)** Unstructured radiology report alongside its corresponding LLM-processed versions using the following prompting

approaches: **(B)** "Structure", **(C)** "Structure + Conciseness", **(D)** "Structure >> Conciseness", **(E)** "Conciseness >> Structure", and **(F)** "Structure + Conciseness (F, I)". The word count for each report is provided in parentheses. The CP scores of all LLM-processed reports are also indicated, with reports **E** and **F** having the lowest CP scores, making them the most concise.

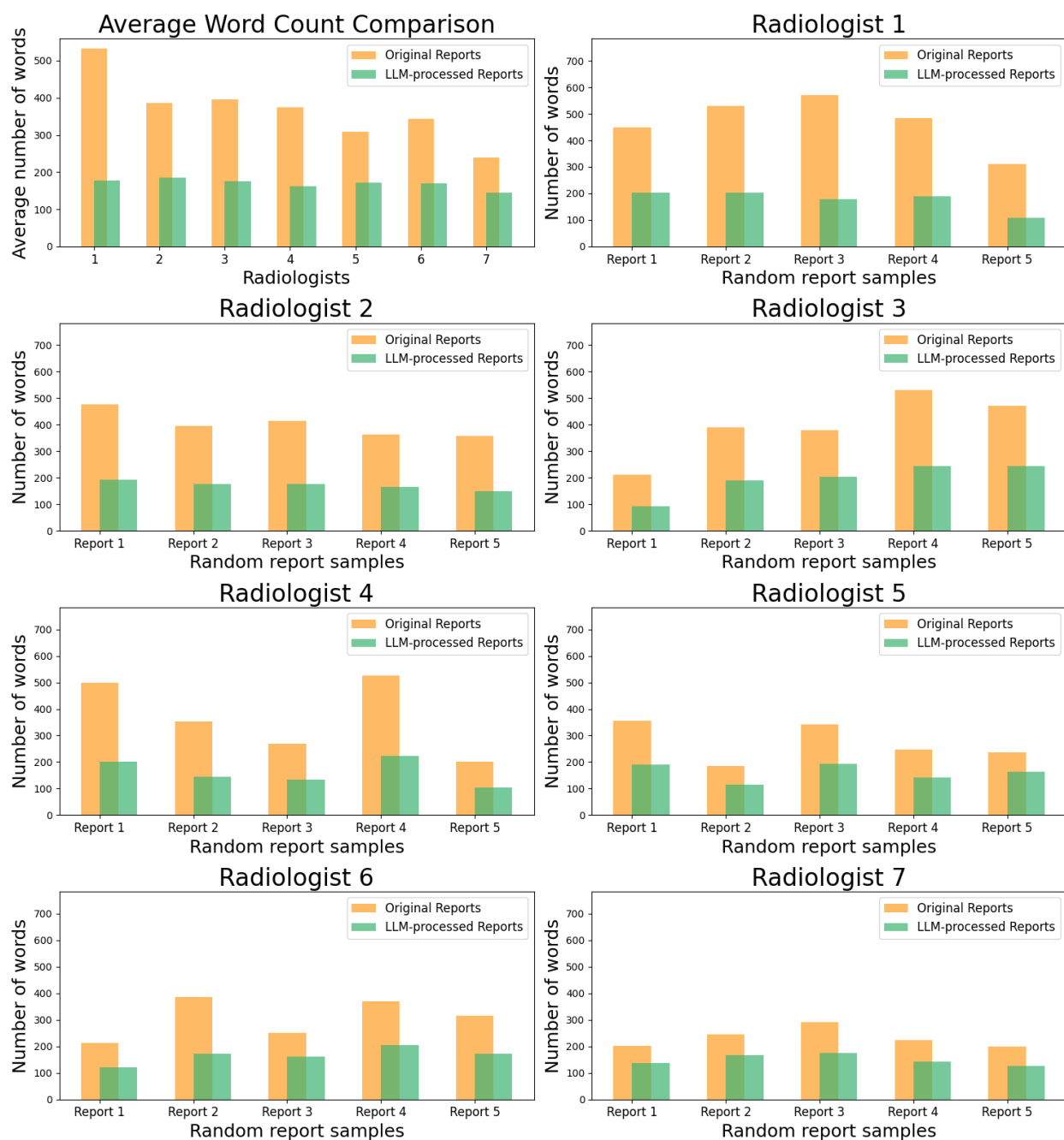


**Figure 4.** Boxplots of CP scores of seven participating radiologists for five different prompting approaches using the Mixtral LLM. Each box represents the interquartile range (IQR), with the top and bottom corresponding to the 75th and 25th percentiles, respectively. A line inside the box marks the median (50th percentile). The tips of the top and bottom whiskers correspond to the highest and lowest values, excluding outliers. The hollow circles indicate outliers. The trend

in concise report writing among radiologists across all prompting strategies is overall consistent. The trend in concise report writing among radiologists is overall consistent across all prompting strategies. Reports with CP scores exceeding 100%, where the LLM-processed report is longer than the original report, fall above the gray dashed line, with none observed in the "Conciseness >> Structure" prompting approach (see

**Table 2** for the exact numbers of such reports).

Radiologists	# Reports	Structure	Structure >> Conciseness	Conciseness >> Structure	Structure + Conciseness	Structure + Conciseness (F, I)
		# Reports w/ CP > 100%	# Reports w/ CP > 100%	# Reports w/ CP > 100%	# Reports w/ CP > 100%	# Reports w/ CP > 100%
Radiologist 1	111	1	0	0	0	2
Radiologist 2	151	0	0	0	0	1
Radiologist 3	126	3	0	0	0	10
Radiologist 4	96	1	0	0	0	11
Radiologist 5	192	7	0	0	2	5
Radiologist 6	80	3	2	0	4	6
Radiologist 7	58	1	0	0	1	1
Total	814	16 (2.0%)	2 (0.2%)	0 (0.0%)	7 (0.9%)	36 (4.4%)



**Figure 5.** The upper left plot shows the average word count of the original reports and their successfully condensed versions generated by the Mixtral LLM (i.e., reports with CP scores not exceeding 100%). The remaining plots provide a side-by-side comparison of total word counts



for a sample of original and LLM-processed reports. Five radiology reports were randomly selected for each radiologist, with CP scores between the 25th and 75th percentiles, indicating a mid-range level of conciseness. All reports were processed using the "Conciseness >> Structure" approach. This analysis highlights the effectiveness of the Mixtral LLM in streamlining content by reducing unnecessary words and phrases.

**Table 1.** The total number of radiology reports processed without formatting errors by the Mixtral LLM across five prompting approaches and seven body radiologists. The last row displays the total number of radiology reports without formatting errors for each approach and its percentage of the overall reports. The "Structure+Conciseness (F,I)" prompting strategy has the least number of formatting errors, meaning it adheres to the formatting instructions better than the other approaches.

Radiologists	# Reports	Structure	Structure >> Conciseness	Conciseness >> Structure	Structure + Conciseness	Structure + Conciseness (F, I)
		# Reports w/o formatting errors	# Reports w/o formatting errors	# Reports w/o formatting errors	# Reports w/o formatting errors	# Reports w/o formatting errors
Radiologist 1	111	103	85	82	99	104
Radiologist 2	151	148	122	138	140	148
Radiologist 3	126	118	102	119	114	123
Radiologist 4	96	83	73	88	92	93
Radiologist 5	192	183	143	191	175	186
Radiologist 6	80	71	59	55	67	80
Radiologist 7	58	50	49	53	52	57
Total	814	756 (92.9%)	633 (77.8%)	726 (89.2%)	739 (90.8%)	791 (97.2%)

**Table 2.** The total number of radiology reports processed by the Mixtral LLM with a CP score greater than 100%, indicating that the LLM-processed report is longer than the original report, is summarized across five prompting approaches and seven body radiologists. The last row displays the total number of radiology reports with a CP score greater than 100% for each approach and its percentage of the overall reports. Only a small number of radiology reports have a CP score over 100%, with no such cases in the "Conciseness >> Structure" prompting strategy.

Radiologists	# Reports	Structure	Structure >> Conciseness	Conciseness >> Structure	Structure + Conciseness	Structure + Conciseness (F, I)
		# Reports w/ CP > 100%	# Reports w/ CP > 100%	# Reports w/ CP > 100%	# Reports w/ CP > 100%	# Reports w/ CP > 100%
Radiologist 1	111	1	0	0	0	2
Radiologist 2	151	0	0	0	0	1
Radiologist 3	126	3	0	0	0	10
Radiologist 4	96	1	0	0	0	11
Radiologist 5	192	7	0	0	2	5
Radiologist 6	80	3	2	0	4	6
Radiologist 7	58	1	0	0	1	1
Total	814	16 (2.0%)	2 (0.2%)	0 (0.0%)	7 (0.9%)	36 (4.4%)

## Supplementary Material

### Prompt

**prompt** = "" Given a radiology report, your task is to extract findings corresponding to organs and areas listed below from FINDINGS section, and radiologist's impressions from IMPRESSIONS section.

Report: {original\_report}

{format\_instructions}

### Format Instructions

**Devices** = ResponseSchema(name = "Devices", description = "Medical lines, tubes, or devices present in a patient's body. If no lines, tubes, or devices are mentioned, write None.")

**Thyroid** = ResponseSchema(name = "Thyroid", description = "Findings of the lower neck, thoracic inlet, and thyroid. If findings are normal, write Unremarkable. If no findings are mentioned, write None.")

**Mediastinum** = ResponseSchema(name = "Mediastinum", description = "Findings of the mediastinum (heart, heart vessels, esophagus, and large airways). If findings are normal, write Unremarkable. If no findings are mentioned, write None.")

**Lungs** = ResponseSchema(name = "Lungs", description = "Findings of the lungs and pleural spaces. If findings are normal, write Unremarkable. If no findings are mentioned, write None.")

**Other\_chest\_findings** = ResponseSchema(name = "Other\_chest\_findings", description = "Findings of other organs and areas in the chest (e.g., axilla, breast, chest wall, diaphragm, retroareola). If findings are normal, write Unremarkable. If no findings are mentioned, write None.")

**Hepatobiliary** = ResponseSchema(name = "Hepatobiliary", description = "Findings of the hepatobiliary system (liver, biliary system, and gallbladder). If findings are normal, write Unremarkable. If no findings are mentioned, write None.")

**Spleen** = ResponseSchema(name = "Spleen", description = "Findings of the spleen. If findings are normal, write Unremarkable. If no findings are mentioned, write None.")

**Pancreas** = ResponseSchema(name = "Pancreas", description = "Findings of the pancreas. If findings are normal, write Unremarkable. If no findings are mentioned, write None.")

**Adrenals** = ResponseSchema(name = "Adrenals", description = "Findings of the adrenals. If findings are normal, write Unremarkable. If no findings are mentioned, write None.")

**Kidneys** = ResponseSchema(name = "Kidneys", description = "Findings of the kidneys and ureters. If findings are normal, write Unremarkable. If no findings are mentioned, write None.")

**GI\_tract** = ResponseSchema(name = "GI\_tract", description = "Findings of the GI tract (stomach, bowel, rectum, colon). If findings are normal, write Unremarkable. If no findings are mentioned, write None.")

**Peritoneum\_mesentery\_retroperitoneum\_vasculature** = ResponseSchema(name = "Peritoneum\_mesentery\_retroperitoneum\_vasculature", description = "Findings of the peritoneum, mesentery, retroperitoneum, vasculature, and pelvic lymph nodes. If findings are normal, write Unremarkable. If no findings are mentioned, write None.")

**Reproductive\_organ**s = ResponseSchema(name = "Reproductive\_organ", description = "Findings of the reproductive organs (e.g., uterus, ovaries, vagina, prostate, testicles, penis). If findings are normal, write Unremarkable. If no findings are mentioned, write None.")

**Bladder** = ResponseSchema(name = "Bladder", description = "Findings of the bladder. If findings are normal, write Unremarkable. If no findings are mentioned, write None.")

**Other\_pelvis\_and\_abdomen\_findings** = ResponseSchema(name = "Other\_pelvis\_and\_abdomen\_findings", description = "Findings of other organs and areas in the pelvis and abdomen (e.g., Bartholin's gland, groin, inguinal region, pelvic floor, proximal thigh, spermatic cord, vulva). If findings are normal, write Unremarkable. If no findings are mentioned, write None.")

**Bones** = ResponseSchema(name = "Bones", description = "Findings of the bones and soft tissues. If findings are normal, write Unremarkable. If no findings are mentioned, write None.")

**IMPRESSIONS** = ResponseSchema(name = "IMPRESSIONS", description = "Radiologist's impressions from IMPRESSIONS section organized in a list. Do not create any new impressions and do not include clinically insignificant impressions.")

## Supplementary Figure 1. The prompt and formatting instructions used in the "Structure"

prompting approach. The LLM is only prompted to structure the given radiology report according to specific formatting guidelines, as shown in **Figure 1**.

## Prompts

**prompt1** = "" Extract findings corresponding to organs and areas listed below from FINDINGS section and the radiologist's impressions from IMPRESSIONS section.

Report: {original\_report}

{format\_instructions}

**prompt2** = "Make {structured\_report} concise by eliminating redundancies and unnecessary phrases such as 'no findings', 'no significant findings', 'none mentioned', 'there is', 'there are', 'at this time', 'at the present time', 'evaluated by', 'normal limits', etc. Eliminate phrases about abnormalities that are not found in the organs, for example, 'no suspicious liver mass'. Keep the format {format\_instructions}."

## Format Instructions

**Devices** = ResponseSchema(name = "Devices", description = "Medical lines, tubes, or devices present in a patient's body. If no lines, tubes, or devices are mentioned, write None.")

**Thyroid** = ResponseSchema(name = "Thyroid", description = "Findings of the lower neck, thoracic inlet, and thyroid. If findings are normal, write Unremarkable. If no findings are mentioned, write None.")

**Mediastinum** = ResponseSchema(name = "Mediastinum", description = "Findings of the mediastinum (heart, heart vessels, esophagus, and large airways). If findings are normal, write Unremarkable. If no findings are mentioned, write None.")

**Lungs** = ResponseSchema(name = "Lungs", description = "Findings of the lungs and pleural spaces. If findings are normal, write Unremarkable. If no findings are mentioned, write None.")

**Other\_chest\_findings** = ResponseSchema(name = "Other\_chest\_findings", description = "Findings of other organs and areas in the chest (e.g., axilla, breast, chest wall, diaphragm, retroareola). If findings are normal, write Unremarkable. If no findings are mentioned, write None.")

**Hepatobiliary** = ResponseSchema(name = "Hepatobiliary", description = "Findings of the hepatobiliary system (liver, biliary system, and gallbladder). If findings are normal, write Unremarkable. If no findings are mentioned, write None.")

**Spleen** = ResponseSchema(name = "Spleen", description = "Findings of the spleen. If findings are normal, write Unremarkable. If no findings are mentioned, write None.")

**Pancreas** = ResponseSchema(name = "Pancreas", description = "Findings of the pancreas. If findings are normal, write Unremarkable. If no findings are mentioned, write None.")

**Adrenals** = ResponseSchema(name = "Adrenals", description = "Findings of the adrenals. If findings are normal, write Unremarkable. If no findings are mentioned, write None.")

**Kidneys** = ResponseSchema(name = "Kidneys", description = "Findings of the kidneys and ureters. If findings are normal, write Unremarkable. If no findings are mentioned, write None.")

**GI\_tract** = ResponseSchema(name = "GI\_tract", description = "Findings of the GI tract (stomach, bowel, rectum, colon). If findings are normal, write Unremarkable. If no findings are mentioned, write None.")

**Peritoneum\_mesentery\_retroperitoneum\_vasculature** = ResponseSchema(name = "Peritoneum\_mesentery\_retroperitoneum\_vasculature", description = "Findings of the peritoneum, mesentery, retroperitoneum, vasculature, and pelvic lymph nodes. If findings are normal, write Unremarkable. If no findings are mentioned, write None.")

**Reproductive\_organs** = ResponseSchema(name = "Reproductive\_organs", description = "Findings of the reproductive organs (e.g., uterus, ovaries, vagina, prostate, testicles, penis). If findings are normal, write Unremarkable. If no findings are mentioned, write None.")

**Bladder** = ResponseSchema(name = "Bladder", description = "Findings of the bladder. If findings are normal, write Unremarkable. If no findings are mentioned, write None.")

**Other\_pelvis\_and\_abdomen\_findings** = ResponseSchema(name = "Other\_pelvis\_and\_abdomen\_findings", description = "Findings of other organs and areas in the pelvis and abdomen (e.g., Bartholin's gland, groin, inguinal region, pelvic floor, proximal thigh, spermatic cord, vulva). If findings are normal, write Unremarkable. If no findings are mentioned, write None.")

**Bones** = ResponseSchema(name = "Bones", description = "Findings of the bones and soft tissues. If findings are normal, write Unremarkable. If no findings are mentioned, write None.")

**IMPRESSIONS** = ResponseSchema(name = "IMPRESSIONS", description = "Radiologist's impressions from IMPRESSIONS section organized in a list. Do not create any new impressions and do not include clinically insignificant impressions.")

## Supplementary Figure 2. The prompts and formatting instructions used in the "Structure >>

Conciseness" prompting approach involve two steps to process the given radiology report. In the first step (prompt 1), the LLM is instructed to structure the radiology report according to specific formatting guidelines, as shown in **Figure 1**. In the second step (prompt 2), the LLM receives further instructions to make the structured radiology report more concise while

maintaining the structure. This two-step approach attempts to ensure that the output report is both concise and well-structured.



## Prompt

**prompt** = "" Given a radiology report, your task is to streamline the report by doing the following:

- Extract findings corresponding to organs and areas listed below from FINDINGS section, and radiologist's impressions from IMPRESSIONS section.
- Avoid redundancies and unnecessary phrases such as "no findings", "no significant findings", "none mentioned", "there is", "there are", "at this time", "at the present time", "evaluated by", "normal limits" etc. Avoid phrases about abnormalities that are not found in the organs, for example, "no suspicious liver mass".

Report: {original\_report}

{format\_instructions}

## Format Instructions

**Devices** = ResponseSchema(name = "Devices", description = "Medical lines, tubes, or devices present in a patient's body. If no lines, tubes, or devices are mentioned, write None.")

**Thyroid** = ResponseSchema(name = "Thyroid", description = "Findings of the lower neck, thoracic inlet, and thyroid. If findings are normal, write Unremarkable. If no findings are mentioned, write None.")

**Mediastinum** = ResponseSchema(name = "Mediastinum", description = "Findings of the mediastinum (heart, heart vessels, esophagus, and large airways). If findings are normal, write Unremarkable. If no findings are mentioned, write None.")

**Lungs** = ResponseSchema(name = "Lungs", description = "Findings of the lungs and pleural spaces. If findings are normal, write Unremarkable. If no findings are mentioned, write None.")

**Other\_chest\_findings** = ResponseSchema(name = "Other\_chest\_findings", description = "Findings of other organs and areas in the chest (e.g., axilla, breast, chest wall, diaphragm, retroareola). If findings are normal, write Unremarkable. If no findings are mentioned, write None.")

**Hepatobiliary** = ResponseSchema(name = "Hepatobiliary", description = "Findings of the hepatobiliary system (liver, biliary system, and gallbladder). If findings are normal, write Unremarkable. If no findings are mentioned, write None.")

**Spleen** = ResponseSchema(name = "Spleen", description = "Findings of the spleen. If findings are normal, write Unremarkable. If no findings are mentioned, write None.")

**Pancreas** = ResponseSchema(name = "Pancreas", description = "Findings of the pancreas. If findings are normal, write Unremarkable. If no findings are mentioned, write None.")

**Adrenals** = ResponseSchema(name = "Adrenals", description = "Findings of the adrenals. If findings are normal, write Unremarkable. If no findings are mentioned, write None.")

**Kidneys** = ResponseSchema(name = "Kidneys", description = "Findings of the kidneys and ureters. If findings are normal, write Unremarkable. If no findings are mentioned, write None.")

**GI\_tract** = ResponseSchema(name = "GI\_tract", description = "Findings of the GI tract (stomach, bowel, rectum, colon). If findings are normal, write Unremarkable. If no findings are mentioned, write None.")

**Peritoneum\_mesentery\_retroperitoneum\_vasculature** = ResponseSchema(name = "Peritoneum\_mesentery\_retroperitoneum\_vasculature", description = "Findings of the peritoneum, mesentery, retroperitoneum, vasculature, and pelvic lymph nodes. If findings are normal, write Unremarkable. If no findings are mentioned, write None.")

**Reproductive\_organ**s = ResponseSchema(name = "Reproductive\_organ", description = "Findings of the reproductive organs (e.g., uterus, ovaries, vagina, prostate, testicles, penis). If findings are normal, write Unremarkable. If no findings are mentioned, write None.")

**Bladder** = ResponseSchema(name = "Bladder", description = "Findings of the bladder. If findings are normal, write Unremarkable. If no findings are mentioned, write None.")

**Other\_pelvis\_and\_abdomen\_findings** = ResponseSchema(name = "Other\_pelvis\_and\_abdomen\_findings", description = "Findings of other organs and areas in the pelvis and abdomen (e.g., Bartholin's gland, groin, inguinal region, pelvic floor, proximal thigh, spermatic cord, vulva). If findings are normal, write Unremarkable. If no findings are mentioned, write None.")

**Bones** = ResponseSchema(name = "Bones", description = "Findings of the bones and soft tissues. If findings are normal, write Unremarkable. If no findings are mentioned, write None.")

**IMPRESSIONS** = ResponseSchema(name = "IMPRESSIONS", description = "Radiologist's impressions from IMPRESSIONS section organized in a list. Do not create any new impressions and do not include clinically insignificant impressions.")

**Supplementary Figure 3.** The prompt and formatting instructions used in the "Structure + Conciseness" prompting approach. The LLM is prompted to structure the given radiology report according to specific formatting guidelines, as shown in **Figure 1**, while also emphasizing the need for conciseness.

### Prompt for “Findings” section

**prompt** = """ Extract findings corresponding to organs and areas listed below from FINDINGS section but avoid redundancies and unnecessary phrases such as "no findings", "no significant findings", "none mentioned", "there is", "there are", "at this time", "at the present time", "evaluated by", "normal limits" etc. Also, avoid phrases about abnormalities that are not found in the organs, for example, "no suspicious liver mass".

Report: {original\_report}

{format\_instructions}

### Format Instructions

**Devices** = ResponseSchema(name = "Devices", description = "Medical lines, tubes, or devices present in a patient's body. If no lines, tubes, or devices are mentioned, write None.")

**Thyroid** = ResponseSchema(name = "Thyroid", description = "Findings of the lower neck, thoracic inlet, and thyroid. If findings are normal, write Unremarkable. If no findings are mentioned, write None.")

**Mediastinum** = ResponseSchema(name = "Mediastinum", description = "Findings of the mediastinum (heart, heart vessels, esophagus, and large airways). If findings are normal, write Unremarkable. If no findings are mentioned, write None.")

**Lungs** = ResponseSchema(name = "Lungs", description = "Findings of the lungs and pleural spaces. If findings are normal, write Unremarkable. If no findings are mentioned, write None.")

**Other\_chest\_findings** = ResponseSchema(name = "Other\_chest\_findings", description = "Findings of other organs and areas in the chest (e.g., axilla, breast, chest wall, diaphragm, retroareola). If findings are normal, write Unremarkable. If no findings are mentioned, write None.")

**Hepatobiliary** = ResponseSchema(name = "Hepatobiliary", description = "Findings of the hepatobiliary system (liver, biliary system, and gallbladder). If findings are normal, write Unremarkable. If no findings are mentioned, write None.")

**Spleen** = ResponseSchema(name = "Spleen", description = "Findings of the spleen. If findings are normal, write Unremarkable. If no findings are mentioned, write None.")

**Pancreas** = ResponseSchema(name = "Pancreas", description = "Findings of the pancreas. If findings are normal, write Unremarkable. If no findings are mentioned, write None.")

**Adrenals** = ResponseSchema(name = "Adrenals", description = "Findings of the adrenals. If findings are normal, write Unremarkable. If no findings are mentioned, write None.")

**Kidneys** = ResponseSchema(name = "Kidneys", description = "Findings of the kidneys and ureters. If findings are normal, write Unremarkable. If no findings are mentioned, write None.")

**GI\_tract** = ResponseSchema(name = "GI\_tract", description = "Findings of the GI tract (stomach, bowel, rectum, colon). If findings are normal, write Unremarkable. If no findings are mentioned, write None.")

**Peritoneum\_mesentery\_retroperitoneum\_vasculature** = ResponseSchema(name = "Peritoneum\_mesentery\_retroperitoneum\_vasculature", description = "Findings of the peritoneum, mesentery, retroperitoneum, vasculature, and pelvic lymph nodes. If findings are normal, write Unremarkable. If no findings are mentioned, write None.")

**Reproductive\_organs** = ResponseSchema(name = "Reproductive\_organs", description = "Findings of the reproductive organs (e.g., uterus, ovaries, vagina, prostate, testicles, penis). If findings are normal, write Unremarkable. If no findings are mentioned, write None.")

**Bladder** = ResponseSchema(name = "Bladder", description = "Findings of the bladder. If findings are normal, write Unremarkable. If no findings are mentioned, write None.")

**Other\_pelvis\_and\_abdomen\_findings** = ResponseSchema(name = "Other\_pelvis\_and\_abdomen\_findings", description = "Findings of other organs and areas in the pelvis and abdomen (e.g., Bartholin's gland, groin, inguinal region, pelvic floor, proximal thigh, spermatic cord, vulva). If findings are normal, write Unremarkable. If no findings are mentioned, write None.")

**Bones** = ResponseSchema(name = "Bones", description = "Findings of the bones and soft tissues. If findings are normal, write Unremarkable. If no findings are mentioned, write None.")

### Prompt for “Impressions” section

**prompt** = """ Extract impressions from IMPRESSIONS section but avoid redundancies and unnecessary phrases such as "no findings", "no significant findings", "none mentioned", "there is", "there are", "at this time", "at the present time", "evaluated by", "normal limits" etc.

Report: {original\_report}

{format\_instructions}

### Format Instructions

**IMPRESSIONS** = ResponseSchema(name = "IMPRESSIONS", description = "Radiologist's impressions from IMPRESSIONS section organized in a list. Do not create any new impressions and do not include clinically insignificant impressions.")

**Supplementary Figure 4.** The prompts and formatting instructions in the "Structure + Conciseness (F, I)" approach involved giving the LLM two prompts, each with the entire radiology report as input. One prompt instructed the LLM to structure and make concise only the



"Findings" section, while the other focused solely on the "Impressions" section. As a result, the LLM-processed report is expected to have the structure shown in **Figure 1**.