

# Advancements in Radiomics and Artificial Intelligence for Thyroid Cancer

## Diagnosis

Milad Yousefi <sup>1</sup>, Shadi Farabi Maleki <sup>2</sup>, Ali Jafarizadeh <sup>2,3,\*</sup>, Mahya Ahmadpour Youshanlui <sup>3</sup>, Aida Jafari <sup>4</sup>, Siamak Pedrammehr <sup>4,5</sup>, Roohallah Alizadehsani <sup>5,\*</sup>, Ryszard Tadeusiewicz <sup>6</sup>, Paweł Pławiak <sup>7,8</sup>

*1 Faculty of Mathematics, Statistics and Computer Sciences, University of Tabriz, Tabriz, Iran*

*2 Nikookari Eye Center, Tabriz University of Medical Sciences, Tabriz, Iran*

*3 Immunology Research Center, Tabriz University of Medical Sciences, Tabriz, Iran*

*4 Faculty of Design, Tabriz Islamic Art University, Tabriz, Iran*

*5 Institute for Intelligent Systems Research and Innovation (IISRI), Deakin University, VIC 3216, Australia*

*6 AGH University of Science and Technology, Department of Biocybernetics and Biomedical Engineering, Krakow, Poland*

*7 Department of Computer Science, Faculty of Computer Science and Telecommunications, Cracow University of Technology, Warszawska 24, 31-155 Krakow, Poland*

*8 Institute of Theoretical and Applied Informatics, Polish Academy of Sciences, Bałtycka 5, 44-100 Gliwice, Poland*

### \*Corresponding Authors:

Roohallah Alizadehsani, PhD

*Institute for Intelligent Systems Research and Innovation (IISRI), Deakin University, VIC 3216, Australia*

*Tel: +61 3 524 79394*

*Postal: 75 Pigdons Rd, Waurn Ponds VIC 3216, Australia*

*Email: [r.alizadehsani@deakin.edu.au](mailto:r.alizadehsani@deakin.edu.au)*

*<https://orcid.org/0000-0003-0898-5054>*

Ali Jafarizadeh, MD, MPH

*Nikookari Eye Center, Tabriz University of Medical Sciences, Tabriz, Iran*

*Tel: +98 901 098 0062*

*Postal code: 51666/14766*

*Email: [Jafarizadeha@tbzmed.ac.ir](mailto:Jafarizadeha@tbzmed.ac.ir), [Ali.jafarizadeh.md@gmail.com](mailto:Ali.jafarizadeh.md@gmail.com)*

*<https://orcid.org/0000-0003-4922-1923>*

Name	Degree	Email	ORCID
Milad Yousefi	MSc	<a href="mailto:miladdyousefi@gmail.com">miladdyousefi@gmail.com</a>	<a href="https://orcid.org/0009-0006-5790-5144">https://orcid.org/0009-0006-5790-5144</a>
Shadi Farabi Maleki	MD	<a href="mailto:shadfa8@gmail.com">shadfa8@gmail.com</a>	<a href="https://orcid.org/0009-0003-6124-2599">https://orcid.org/0009-0003-6124-2599</a>
Ali Jafarizadeh	MD, MPH	<a href="mailto:ali.jafarizadeh.md@gmail.com">ali.jafarizadeh.md@gmail.com</a>	<a href="https://orcid.org/0000-0003-4922-1923">https://orcid.org/0000-0003-4922-1923</a>
Mahya Ahmadpour Youshanlui	MD	<a href="mailto:mahyaahmadpouryoushanlui@gmail.com">mahyaahmadpouryoushanlui@gmail.com</a>	<a href="https://orcid.org/0000-0003-2617-0561">https://orcid.org/0000-0003-2617-0561</a>
Aida Jafari	MSc	<a href="mailto:aida.Jafarey@gmail.com">aida.Jafarey@gmail.com</a>	<a href="https://orcid.org/0009-0003-3858-2886">https://orcid.org/0009-0003-3858-2886</a>
Siamak Pedrammehr	PhD	<a href="mailto:s.pedrammehr@tabriziau.ac.ir">s.pedrammehr@tabriziau.ac.ir</a>	<a href="https://orcid.org/0000-0002-2974-1801">https://orcid.org/0000-0002-2974-1801</a>
Roohallah Alizadehsani	PhD	<a href="mailto:r.alizadehsani@deakin.edu.au">r.alizadehsani@deakin.edu.au</a>	<a href="https://orcid.org/0000-0003-0898-5054">https://orcid.org/0000-0003-0898-5054</a>
Ryszard Tadeusiewicz	PhD	<a href="mailto:rtad@agh.edu.pl">rtad@agh.edu.pl</a>	<a href="https://orcid.org/0000-0002-4317-2801">https://orcid.org/0000-0002-4317-2801</a>
Paweł Pławiak	PhD	<a href="mailto:plawiak.pawel@gmail.com">plawiak.pawel@gmail.com</a>	<a href="https://orcid.org/0000-0001-9675-5819">https://orcid.org/0000-0001-9675-5819</a>

## **Abstract**

Thyroid cancer is an increasing global health concern that requires advanced diagnostic methods. The application of AI and radiomics to thyroid cancer diagnosis is examined in this review. A review of multiple databases was conducted in compliance with PRISMA guidelines until October 2023. A combination of keywords led to the discovery of an English academic publication on thyroid cancer and related subjects. 267 papers were returned from the original search after 109 duplicates were removed. Relevant studies were selected according to predetermined criteria after 124 articles were eliminated based on an examination of their abstract and title. After the comprehensive analysis, an additional six studies were excluded. Among the 28 included studies, radiomics analysis, which incorporates ultrasound (US) images, demonstrated its effectiveness in diagnosing thyroid cancer. Various results were noted, some of the studies presenting new strategies that outperformed the status quo. The literature has emphasized various challenges faced by AI models, including interpretability issues, dataset constraints, and operator dependence. The synthesized findings of the 28 included studies mentioned the need for standardization efforts and prospective multicenter studies to address these concerns. Furthermore, approaches to overcome these obstacles were identified, such as advances in explainable AI technology and personalized medicine techniques. The review focuses on how AI and radiomics could transform the diagnosis and treatment of thyroid cancer. Despite challenges, future research on multidisciplinary cooperation, clinical applicability validation, and algorithm improvement holds the potential to improve patient outcomes and diagnostic precision in the treatment of thyroid cancer.

**Keywords:** Radiomics, Artificial intelligence, Thyroid Cancer, Thyroid, Neoplasms, Machine Learning

# 1. Introduction

Thyroid cancer ranks seventh globally in incidence with 820,000 cases in 2022, and 24th in mortality with approximately 47,000 deaths. Strikingly, women face a tripled risk of thyroid cancer. This highlights the necessary need for research, specifically to overcome radioiodine therapy resistance (Ferlay et al., 2024). Of all endocrine neoplasms, thyroid carcinoma is the most frequent. Its incidence is continuously rising globally, ranking it as the fifth most frequent solid tumor in women and the sixteenth most common in males (Elhassan et al., 2023). To effectively plan treatments and manage patients, an accurate diagnosis must be made quickly. Doctors mainly use imaging tests like computed tomography (CT), ultrasound (US), and magnetic resonance imaging (MRI) to figure out what kind of thyroid nodule you have (Uludag et al., 2023). Experienced radiologists may find it challenging to interpret these imaging tests, though, as they must be able to identify subtle cancerous signs. Quantitative feature analysis of medical image data is the focus of the medical imaging subfield known as radiomics (Bi et al., 2019). These features include textural, morphological, and intensity characteristics that are methodically extracted to disclose information that has been hidden in images obtained using modalities like computed CT, MRI, or positron emission tomography (PET) (Rogers et al., 2020). Using advanced computational techniques, radiomics aims to convert conventional medical images into data that can be analyzed. Radiomics enables the detailed characterization of tissues, tumors, and other anatomical structures by extracting a multitude of quantitative features (Rogers et al., 2020). Radiomics has a wide range of applications in healthcare, with a particular focus on situations involving cancer. It is crucial for the identification, formulation, and assessment of cancer treatments. In order to analyze the extracted features, spot complex patterns, and possibly find biomarkers for prognostic and diagnostic uses, artificial intelligence (AI) and machine learning (ML) algorithms are essential (Z. Liu et al., 2019).

Radiomics is particularly helpful in the field of tumor analysis when it comes to assessing the heterogeneity within tumors, forecasting treatment outcomes, and enabling personalized medicine by tailoring treatments based on distinct tumor characteristics (Zhang et al., 2023). The combination of intricate mathematical and computational methods with medical imaging not only improves our understanding of images particularly health-related ones but also presents opportunities for future advancements in the field. This progression demonstrates the continuous advancement and improvement of methods that link mathematical sciences, computational techniques, and medical imaging to enhance prognostic and diagnostic capabilities (Pinto-Coelho, 2023).

In the contemporary landscape of thyroid cancer diagnosis, there has been a discernible surge in research endeavors, particularly those delving into the integration of radiomics and AI. The heightened interest in this specific

intersection of technologies reflects a growing recognition of their potential to reshape and enhance diagnostic approaches (Habchi et al., 2023). As the number of studies exploring the application of radiomics and AI in thyroid cancer diagnosis continues to multiply, there emerges an imperative to conduct a thorough and exhaustive review. This review aims not only to synthesize the current state of knowledge but also to identify gaps, challenges, and opportunities for further investigation. By systematically analyzing the existing body of literature, we seek to provide a comprehensive understanding of the progress made and the avenues yet to be explored, thereby laying the groundwork for continued advancements in the integration of radiomics and AI for thyroid cancer diagnosis (Dondi et al., 2024).

In this review, recent advancements in the integration of radiomics and AI for thyroid cancer are explored, with a specific focus on: 1) A comprehensive examination of AI, ML, and DL in the context of thyroid cancer. 2) An in-depth overview of thyroid cancer, considering epidemiological and pathophysiological aspects. 3) An assessment of various techniques and methods employed in thyroid cancer diagnosis. 4) The development of radiomics and AI models in the field of radiomics. 5) Compilation and analysis of studies reporting outcomes of radiomics in thyroid cancer diagnosis through the application of AI techniques.

The aim of this review is to provide valuable insights for researchers in the AI domain, aiding them in the creation and enhancement of efficient, high-performance tools for the diagnosis and treatment of thyroid cancer. Additionally, it is anticipated that this review will promote interdisciplinary collaboration, encouraging future experimental and theoretical work in healthcare, particularly in the realm of thyroid cancer diagnosis and treatment.

## **2. Literature search method**

Following the PRISMA guidelines, a thorough analysis of the body of research was conducted. This involved utilizing various scholarly scientific databases, including PubMed, Medline, EMBASE, Scopus, and Web of Sciences. The investigation focused on academic publications published up until October 1, 2023, and was restricted to those available in the English language. Additionally, supplementary articles were sourced by examining the reference sections of screened papers. An intricate search strategy was devised, incorporating a range of keyword combinations such as "radiomics," "artificial intelligence," "deep learning," "machine learning," "thyroid cancer," "thyroid neoplasm," and "thyroid tumor." These search strings were carefully constructed by combining keywords with their synonyms. Study selection involved initially identifying 267 research papers. Subsequently, 109 redundant documents were eliminated, and a review of titles and abstracts by authors [MY, SF,

AiJ] resulted in the exclusion of 124 articles that did not meet predetermined criteria. A comprehensive review of full-text articles was then conducted by authors [AIJ, MY]. All review and conference studies were eliminated, leading to the exclusion of six additional studies. Subsequently, titles and abstracts were screened to select relevant studies based on inclusion and exclusion criteria, resulting in a final set of 28 studies (Agyekum et al., 2022; Dai et al., 2022; de Koster et al., 2022; Göreke, 2023; Jiabing Gu et al., 2019; Kwon, Shin, Park, Cho, Hahn, & Park, 2020; Kwon, Shin, Park, Cho, Kim, & Hahn, 2020; Li et al., 2021; Li et al., 2023; T. Liu et al., 2019; Lu et al., 2019; Peng et al., 2021; Sharma et al., 2023; Shi et al., 2022; Wang et al., 2020; Y. G. Wang et al., 2022; Wei et al., 2021; Wu et al., 2022; Xia et al., 2021; Xu et al., 2022; Yu et al., 2020; J. Yu et al., 2022; P. Yu et al., 2022; H. Zhou et al., 2020; S. C. Zhou et al., 2020; Zhou et al., 2022; Zhu et al., 2023; Zhu et al., 2022). Figure 1 presents a detailed flow chart of the study selection procedure.

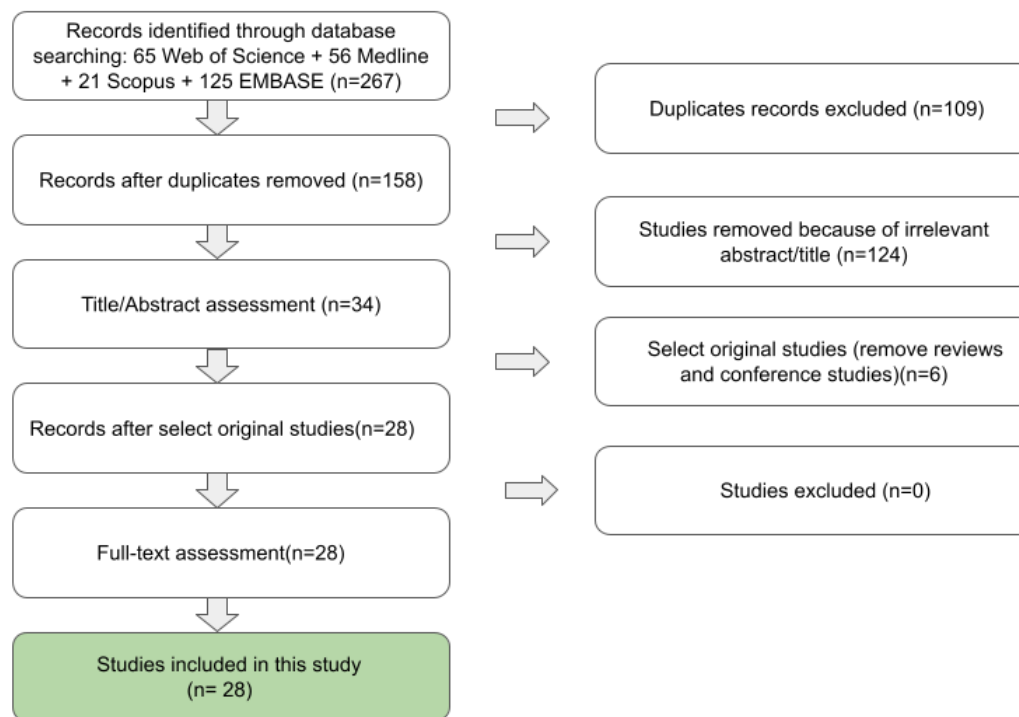


Figure 1 PRISMA flow diagram

### 3. Overview of Thyroid Cancers

#### 3.1 Epidemiology

Based on the GLOBOCAN 2022 database of cancer incidence and mortality by the WHO International Agency for Research on Cancer, Thyroid cancer, a malignancy arising in the butterfly-shaped gland at our throat's base, may not rank highest in mortality, but its global reach demands attention. The year 2022 saw it claim the unfortunate title of seventh most common incidence (820,000 cases) of cancer (Figure 2) and 24th most common in mortality (about 47000 deaths), with over 83,000 diagnosed cases (Figure 3) (Ferlay et al., 2024). While enhanced detection methods contribute to this number, a concerning shadow of overdiagnosis looms over specific regions, urging deeper understanding. This shadow falls unevenly, with women disproportionately bearing the burden. They are three times more likely to develop thyroid cancer, particularly the papillary and follicular types, which, thankfully, often boast favorable prognosis. However, even within these "well-differentiated" forms, a specter of resistance to radioiodine therapy can complicate treatment, highlighting the need for further research.

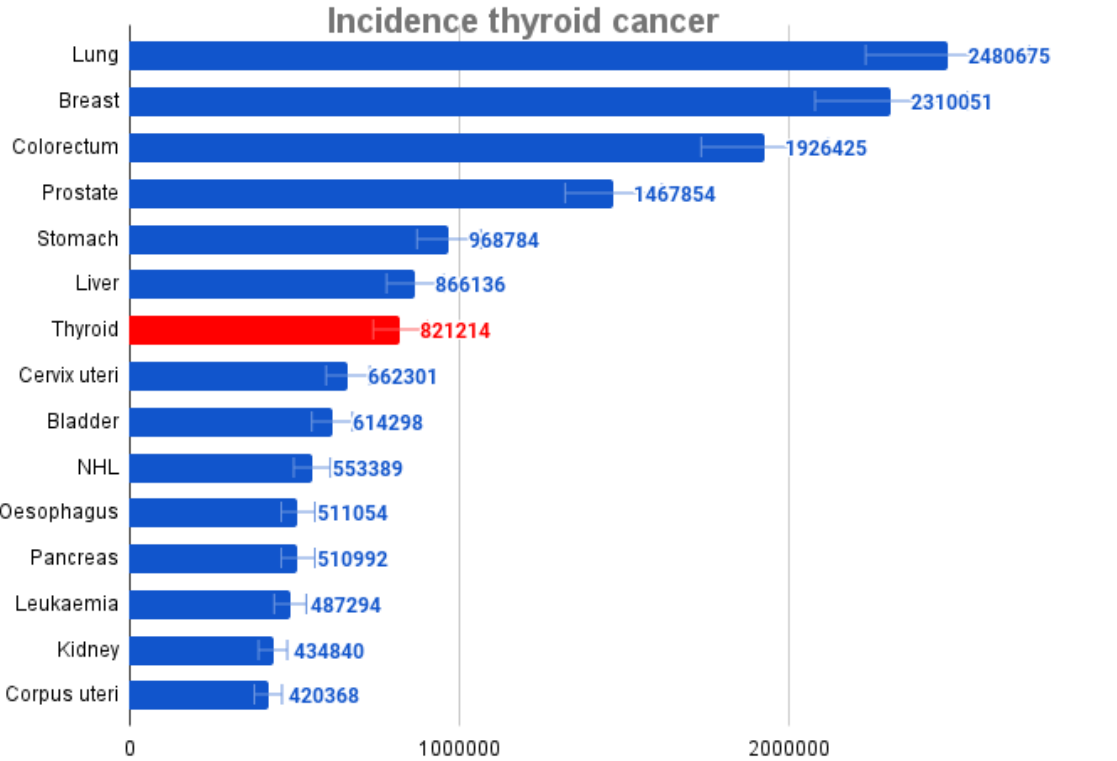


Figure 2 Presents the Incidence ranking of thyroid cancer among other types of cancers according to GLOBOCAN data from 2022

## Mortality thyroid cancer

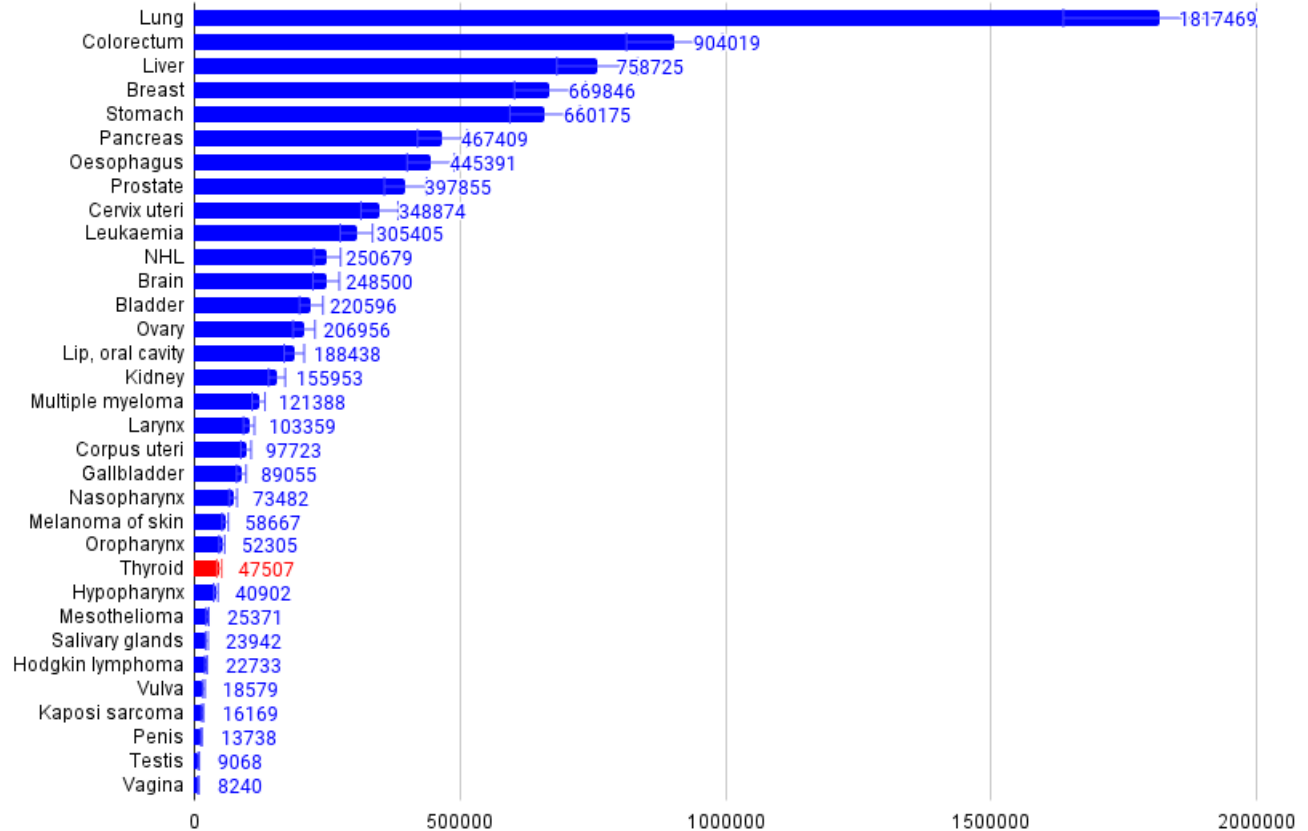


Figure 3 Presents the mortality ranking of thyroid cancer among other types of cancers according to GLOBOCAN data from 2022.

However, not all thyroid cancers share the same characteristics. Medullary cancer, although less prevalent, introduces a unique challenge with its slow growth and limited treatment options. On the opposite end of the spectrum, anaplastic carcinoma emerges as an aggressive entity with a nearly 100% mortality rate. This stark contrast in outcomes highlights the intricate nature of this disease (Concepción Zavaleta et al., 2021). Despite these challenges, glimmers of hope are evident. Researchers worldwide are delving into the intricate mechanisms of resistance, paving the way for innovative combined therapies. Both preclinical and clinical settings are buzzing with activity, providing a ray of light for patients grappling with this formidable diagnosis. Beyond mere statistics, a deeper examination reveals that the median age of diagnosis typically falls in the early 50s. However, this silent predator can strike at any stage of life, with the alarming distinction of being the most common malignancy among young adults aged 16-33. Unraveling the root causes remains crucial. Exposure to radiation, pre-existing thyroid conditions, environmental toxins, iodine deficiency, and even obesity all participate in the complex dance of risk

factors. Understanding these intricate relationships empowers preventive measures and early detection efforts (Sinnott et al., 2010).

### **3.2 Pathophysiology**

Thyroid abnormalities are divided into two benign and malignant groups. Nodular goitre, stemming from iodine deficiency, exhibits distinct classifications as endemic ( $>10\%$  prevalence) or sporadic ( $\leq 10\%$ ). While endemic cases result from absolute iodine deficiency, sporadic instances involve various factors, such as increased thyroid hormone needs, dietary iodine insufficiency, goitrogen ingestion, and subclinical dyshormonogenesis (Unlu et al., 2022). Pathologically, nodular goitre manifests as a combination of hyperplastic and involutinal changes, with challenges arising in distinguishing between follicular adenomas and hyperplastic nodules, particularly in the context of dominant nodules (Baloch & LiVolsi, 2007).

Beyond benign cases, encapsulated non-functioning nodules called follicular adenomas are common in people between the ages of 30 and 50 and can seldom result in hyperthyroidism (McHenry & Phitayakorn, 2011). A thorough histological examination is necessary to distinguish between adenoma and carcinoma. Women in their fifth decade make up the majority of patients with follicular carcinomas; these patients have thicker capsules and are diagnosed based on vascular and/or capsular invasion, the degree of which dictates the patient's chance of survival. In general, papillary carcinomas have a good prognosis and are diagnosed based on unique nuclear features rather than architectural patterns (Wang et al., 2010; Zhang et al., 2023). They are more common in young adults, especially women. Oncocytic follicular tumors have higher rates of malignancy, decreased radioiodine uptake, and an increased risk of metastasis. Initially thought to be malignant, they are now evaluated similarly to other follicular lesions (Asa, 2004). Malignant cells that are not fully differentiated exhibit behavior halfway between that of differentiated and undifferentiated carcinomas. They are characterized as solid masses with a variety of histological features (Benesch & O'Brien, 2022; Hu et al., 2021). Anaplastic carcinomas are extremely malignant and have a poor prognosis. They are composed of spindle and epithelioid cells. RET gene mutation screening is required for medullary carcinomas, which can be sporadic or familial. The former typically presents in the 40–60 age range, while the latter typically presents earlier and in both directions. In papillary carcinomas, BRAF and RET mutations activate the MAP kinase signaling pathway; in follicular lesions, PAX8/PPAR $\gamma$  and Ras mutations do the same. These molecular pathways are responsible for the differences between papillary carcinomas and follicular lesions (Hu et al., 2021). Germline mutations in the RET proto-oncogene are linked to medullary carcinoma, especially in MEN2 syndromes (Neocleous et al., 2023).



### 3.3 Thyroid Cancer Diagnosis

Palpation for thyroid gland nodules was a major diagnostic tool in the past, but it is now only used in 30–40% of cases to identify thyroid cancers (Kahn et al., 2012; Rahman et al., 2019; Sajisevi et al., 2022). A multimodal approach involving laboratory testing, imaging modalities, and clinical assessment forms the basis of modern thyroid cancer diagnosis (Brauckhoff & Biermann, 2020). The detection of thyroid cancer can now be achieved through a range of imaging modalities, such as neck and carotid USs, as well as scans of the chest, neck, and spine (Bonjoc et al., 2020). Thyroid USs are now commonly done on patients, even in the absence of palpable nodules. Furthermore, some cases are inadvertently found when people with known thyroid nodules undergo repeated ultrasonography exams. Remarkably, thyroid cancer can also be discovered after surgery when thyroid tissue that was first thought to be non-cancerous is examined (Toda et al., 2020). The ability to identify thyroid cancers even in the absence of palpable symptoms is improved by this extensive range of diagnostic techniques (Rahman et al., 2019).

One of the most important steps in the diagnosis of recently formed thyroid nodules is measuring serum thyroid-stimulating hormone (TSH) levels to assist in differentiating between nonfunctional (Uludag et al., 2023; Unlu et al., 2022). Hyperfunctioning nodules, which are rarely malignant, are indicated by subnormal TSH levels; non-functioning nodules or those with Hashimoto's thyroiditis may be more susceptible to cancer. Although a diagnostic neck ultrasonography cannot definitively determine whether a nodule is malignant, it is recommended to confirm the presence of nodules and assess any suspicious features. Fine needle aspiration (FNA) is necessary due to the elevated risk of malignancy, regardless of nodule size, especially for non-functioning nodules and if TSH is normal or elevated (Uludag et al., 2023; Unlu et al., 2022).

The outcomes of a FNA biopsy are categorized as benign, malignant, suspicious, indeterminate, or nondiagnostic concerning the diagnosis of thyroid cancer. In instances involving solid nodules, indeterminate cytology, or confirmed malignancy, the recommended course of action involves either a thyroid lobectomy or a total thyroidectomy, contingent upon the tumor's characteristics and the patient's medical history (AlSaedi et al., 2024). A repetition of the FNA is deemed necessary in the event of noticeable changes subsequent to a benign cytology outcome, necessitating ongoing ultrasonography monitoring (AlSaedi et al., 2024; Cochand-Priollet & Maleki, 2023; Uludag et al., 2023; Unlu et al., 2022). Distinct histological variants of thyroid cancer, including anaplastic, follicular, medullary, and papillary (*Figure 4*) (Abdollahi et al., 2024; AlSaedi et al., 2024; Cochand-Priollet & Maleki, 2023).

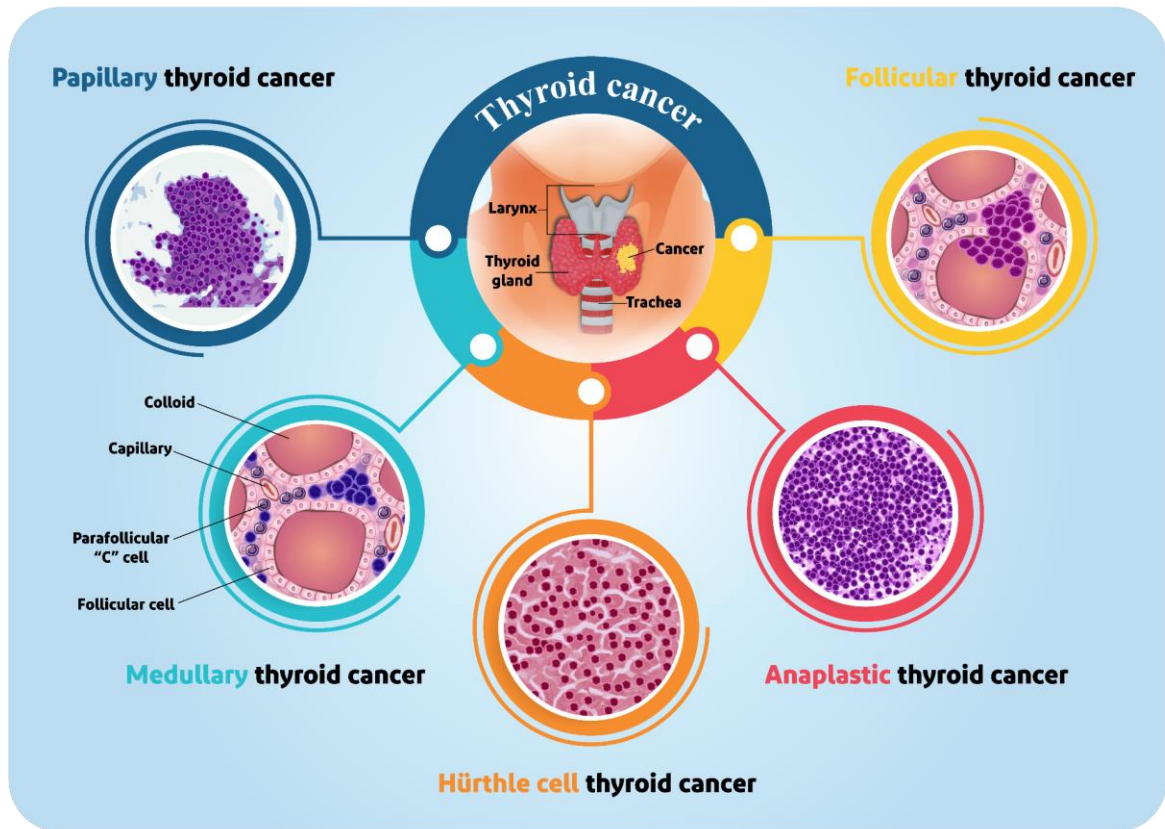


Figure 4 There are different types of thyroid cancer including: papillary thyroid cancer, follicular thyroid cancer, oncocytic cell (hurthle cell) thyroid cancer, medullary thyroid cancer, anaplastic thyroid cancer

Decisions regarding treatment and prognosis are influenced by the preoperative detection of potential metastases through neck ultrasonography. The realm of thyroid cancer diagnosis and treatment has experienced enhanced efficacy with the escalating application of radiomics in recent years (Figure 5) (Abdollahi et al., 2024; AISaedi et al., 2024; Cochand-Priollet & Maleki, 2023).

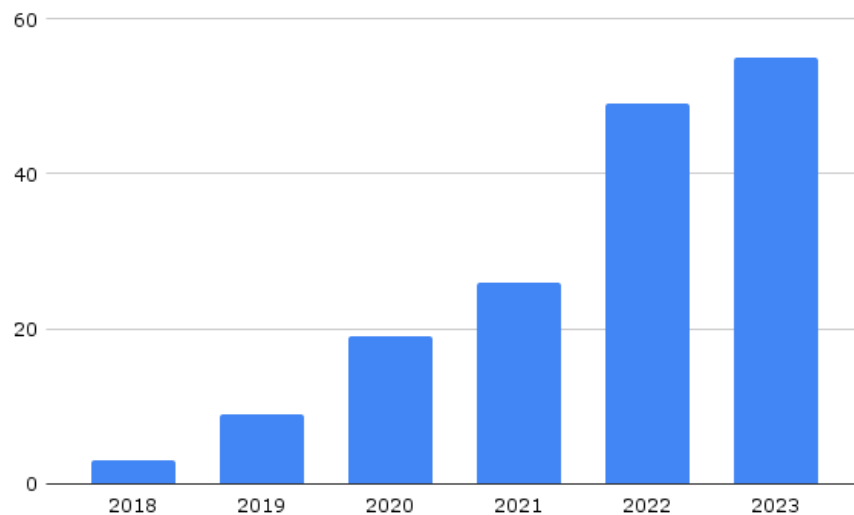


Figure 5 A bar chart display increasing investigations over the last 6 years about utilizing radiomics and AI in Thyroid cancer diagnosis

#### 4. Overview of artificial intelligence

The goal of AI, a fast developing area of computer science, is to create machines that possess traits of human intelligence. AI encompasses a wide range of methodologies, but some of the most well-known ones are natural language processing (NLP), DL, and ML (Farabi Maleki et al., 2023; Jafarizadeh et al., 2024). Notably, Large Language Models (LLMs) constitute a unique class in the AI algorithmic framework that is capable of understanding, compressing, producing, and forecasting textual content by employing large-scale datasets and advanced DL methods. Given their inherent capacity for text generation, LLMs find versatile applications in various NLP tasks, including sentiment analysis, translation, summarization, rewriting, and classification (Alowais et al., 2023; Davenport & Kalakota, 2019; Gupta & Kumar, 2023).

A branch of AI called, NLP studies how human language is conceived, decoded, and understood. This broad field includes a variety of approaches, including sentiment analysis, speech recognition, machine translation, and text mining. AI's historical trajectory has undergone notable shifts, moving from the first age of rule-based systems to the current era where ML and DL algorithms are the mainstays (Figure 6) (Alowais et al., 2023; Davenport & Kalakota, 2019; Gupta & Kumar, 2023).

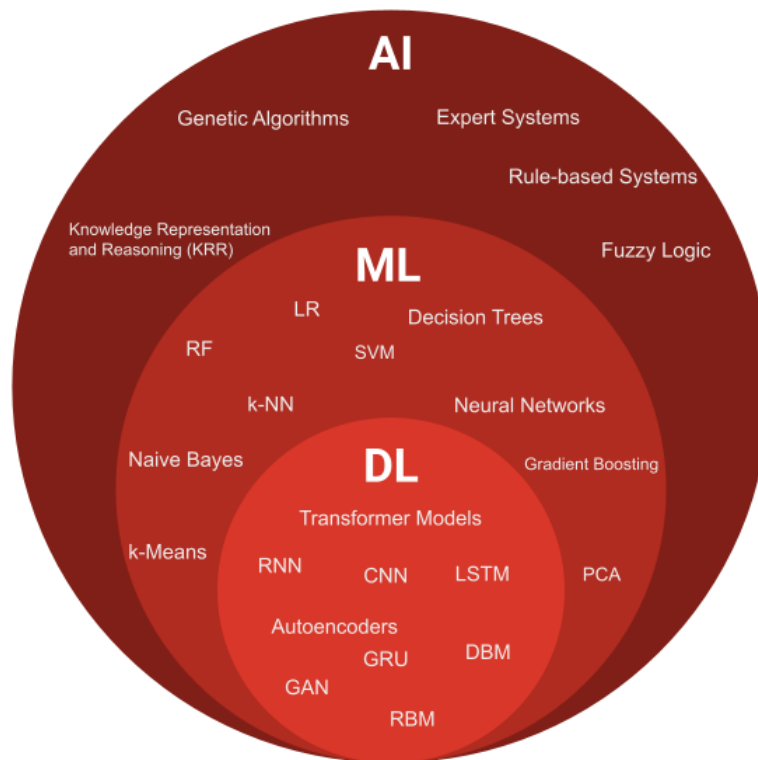


Figure 6 In ML algorithms: Linear Regression(LR), Random Forest(RF), Support Vector Machines (SVM) k-nearest neighbors (k-NN), Principal Component Analysis (PCA), Gradient Boosting Algorithms (e.g., XGBoost, LightGBM). And in DL algorithms:Convolutional Neural Networks (CNN), Recurrent Neural Networks (RNN), Long Short-Term Memory (LSTM), Gated Recurrent Unit (GRU), Generative Adversarial Networks (GAN), Deep Boltzmann Machines (DBM), Restricted Boltzmann Machines (RBM), Deep Q-Networks (DQN)

## 4.1 Machine learning

Within the field of AI, ML allows computers to grow without explicit programming by using experience as a learning tool. The primary objective is to develop algorithms that enable computers to identify patterns in data and extrapolate inferences or predictions (Ashayeri et al., 2024; Gupta & Kumar, 2023). A large amount of data (referred to as the training dataset) is fed into the system as part of standard ML procedures, and the algorithm is then allowed to search for patterns, relationships, and features in the data. By adjusting its internal parameters, the system gains experience and improves its ability to complete tasks. Artificial neural networks (ANNs), which resemble learning systems, are used in DL (Abdollahi et al., 2023; Dargan et al., 2020). ML can be divided into three main categories (*Figure 7*):

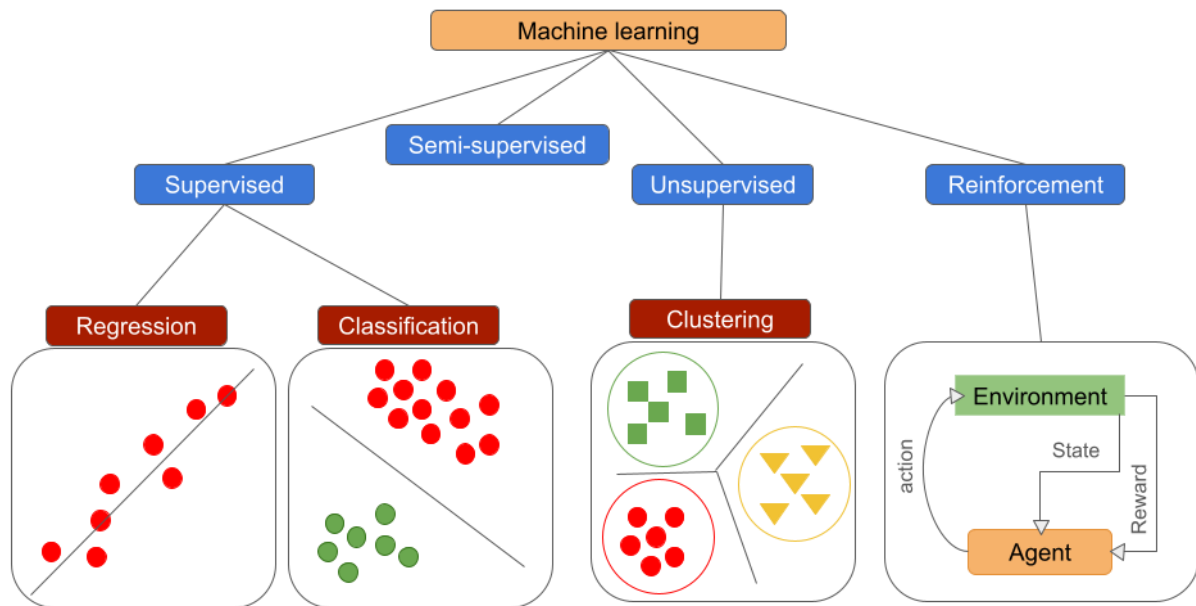


Figure 7 The diagram depicts three learning paradigms: supervised, unsupervised, and reinforcement learning. Within the supervised category, the focus is on predicting outcomes through regression and classification. In the unsupervised realm, the emphasis is on revealing patterns by employing clustering techniques. Lastly, the reinforcement learning section illustrates the dynamic process of decision-making, showcasing actions, states, and rewards.

**Supervised Learning:** In this approach, the algorithm is trained on a labeled dataset, where the input data is paired with the corresponding desired outputs. The goal is for the algorithm to learn a mapping function that can predict the output for new, unseen inputs (Badillo et al., 2020; Greener et al., 2022).

**Semi-supervised:** Semi-supervised learning occupies a middle ground between supervised and unsupervised learning methodologies within the realm of ML. This approach utilizes a limited set of labeled data in conjunction with a vast pool of unlabeled data for training purposes (Bazargani et al., 2024; Oliveira & Bollen, 2023). This hybrid training strategy proves advantageous when only a portion of the data has ground-truth labels available. Moreover, the amalgamation of labeled and unlabeled data has been observed to enhance the accuracy of classifying new instances. Examples of semi-supervised learning algorithms include restricted Boltzmann machines and deep belief networks (Oliveira & Bollen, 2023).

**Unsupervised Learning:** In this case, the algorithm is entrusted with identifying patterns or structures in the unlabeled data without the need for explicit guidance. Unsupervised learning frequently involves tasks like clustering and dimensionality reduction (Badillo et al., 2020; Greener et al., 2022).

**Reinforcement learning:** Systems can learn by interacting with real-world environments thanks to a subset of ML called reinforcement learning. The computer attempts to solve problems by making mistakes and trying different things. An entity referred to as the agent engages with the environment during this process, making observations, choosing actions, and getting rewarded or penalized in accordance with those decisions. The agent's main goal is to maximize cumulative rewards; the best course of action is known as the policy (Nguyen et al., 2020). Numerous fields, such as game theory, data science, and robotics, use reinforcement learning (Habeheh & Gohel, 2021).

Applications of ML are found in many different fields, such as recommendation systems, fraud detection, NLP, image and speech recognition, and autonomous cars. As technology develops, ML models and DL models in particular become more and more popular because of their capacity to automatically extract hierarchical features from data, which qualifies them for difficult tasks (Greener et al., 2022; Janiesch et al., 2021).

## **4.2 Deep learning**

As mentioned, fueled by advancements in computer processing, a subset of ML rooted in ANNs has emerged to address progressively intricate challenges autonomously. While early ANNs necessitated substantial human input for feature selection, the advent of DL applications has revolutionized this process by automatically extracting optimal features from raw data. DL is predominantly deployed in pattern recognition systems, showcasing its efficacy in extracting crucial information from high-dimensional datasets. Notably, DL methods have exhibited promising outcomes, particularly in computer vision and image analysis, often rivaling or surpassing traditional ML approaches reliant on manually crafted features defined by human experts (Alghamedy et al., 2022; Najafabadi et al., 2015). DL can autonomously carry out a designated task by extracting crucial features directly from unprocessed data (Najafabadi et al., 2015). A DL method is characterized by its composition of multiple layers, forming a hierarchical structure of simple models. These models nonlinearly transform their input to generate output, creating a complex mapping process. Each layer in this stack further refines the outputs from the previous layer, contributing to the enhancement of both selectivity and invariance within the representation. This iterative refinement process allows DL models to capture increasingly intricate patterns and features in the data. Overall, the multilayered architecture enables DL systems to achieve high levels of performance in various tasks, ranging from image recognition to NLP (LeCun et al., 2015).

## **5. Radiomics**

In the world of biology and medicine, many fields end in "-omics" to signify the analysis of massive data sets to uncover hidden insights. Radiomics is one such field, specifically focused on extracting valuable, measurable information from medical images, helping us unlock secrets hidden within US images, CT, MRI, or PET/CT (Chen et al., 2023). Using complex algorithms, radiomics analyzes medical images to extract a multitude of "radiomic features" (Gillies et al., 2016; Kumar et al., 2012; Lambin et al., 2012; Parekh & Jacobs, 2016; Yip & Aerts, 2016). Imagine being able to extract hidden information from a medical image, rather than just seeing shapes and shadows. That's what radiomics does. It uses complex algorithms to mine medical images for a vast number of tiny details, revealing patterns and characteristics invisible to the naked eye (Yip et al., 2017). This approach unlocks hidden insights about tumors, potentially predicting how they behave and respond to treatment. This emerging field, born from radiology and oncology, holds immense promise for personalized medicine, tailoring treatments based on the unique characteristics of each patient's disease (Chicklore et al., 2013; Cook et al., 2014; Lambin et al., 2012). While currently most advanced in these fields, its potential extends to any area where imaging unveils clues about disease processes (Parekh & Jacobs, 2017). In recent years, a discernible integration of applied mathematics and statistical sciences has been witnessed across diverse domains, particularly in the development and optimization of AI and ML algorithms. This interdisciplinary approach, heavily anchored in computer science and computational methods, has fortified the underpinnings of AI. Matrices, employed in image processing, have garnered significance, propelling the evolution of CNNs. This evolution has significantly altered the landscape of image analysis, especially within fields such as medical imaging. The utilization of matrices in image description has concurrently given rise to innovative techniques, including radiomics (Elahi et al., 2023).

## **5.1. Data acquisition**

Image acquisition, the first crucial step in radiomics, acts as the gateway to unveiling hidden information within the patient. This intricate process involves capturing medical images that serve as the foundation for subsequent feature extraction and analysis (van Timmeren et al., 2020). Beyond CT, PET, and MRI, radiomics embraces US's unique strengths and challenges. Its real-time visualization, lack of radiation, and cost-effectiveness make it ideal for dynamic assessments, monitoring, and point-of-care applications (Najjar, 2023). However, operator dependence, limited penetration, and speckle noise demand careful standardization, advanced techniques like elastography and ML, and tailored protocols. Despite these hurdles, US is unlocking its potential in radiomics for early cancer detection, assessing aggressiveness, monitoring treatment, and more, solidifying its role as a transformative force in personalized medicine (Jiang et al., 2022).

## **5.2. Region of Interest (ROI) Segmentation**

Within the burgeoning field of radiomics, the meticulous process of ROI segmentation occupies a pivotal role, particularly when unraveling the complexities of thyroid cancers. Akin to a sculptor carefully excavating a hidden masterpiece, this technique meticulously delineates the tumor region within medical images, enabling the extraction of quantitative features crucial for diagnosis, prognosis, and treatment stratification. Let us delve deeper to illuminate the significance of ROI segmentation in this context (Gao et al., 2023; Veiga-Canuto et al., 2022).

## **5.3 Fiduciary Accuracy: The Foundation of Feature Extraction**

Envision setting out on a scientific quest to find valuable features that will reveal the mysteries of tumor biology, rather than buried treasure. Accurate ROI segmentation acts as your steadfast guide, ensuring that the features that are extracted accurately capture the distinct qualities of the tumor, including its geometric structure, textural heterogeneity, and intensity distribution. This precision is critical to building strong radiomics models, which are complex algorithms that analyze these features in-depth to distinguish between benign and malignant nodules, forecast aggressive behavior, and help choose the best course of treatment. Think of them as experienced detectives. Similar to a malfunctioning compass, inaccurate segmentation can result in dangerous misinterpretations that could misclassify a benign nodule as malignant or vice versa, with serious consequences for patient care (Gao et al., 2023; Veiga-Canuto et al., 2022).

## **5.4 Converging on Standardized Segmentation to Close the Interobserver Gap**

Consider a scenario in which two detectives are looking into the same crime scene, but they each have a different perspective on it. Radiologists may exhibit intrinsic subjectivity and interobserver variability when manually segmenting a tumor by visually tracing its outline; for instance, one radiologist may perceive a jagged boundary while another sees a smoother one (Hussain et al., 2022). This discrepancy can make it extremely difficult to create trustworthy radiomics models. Automated and semi-automated techniques are becoming valuable allies in closing this gap. These techniques make use of advanced image processing algorithms to accurately and consistently identify the tumor, even when viewed by multiple observers and research projects. Envision a group of robotic investigators, outfitted with state-of-the-art equipment and unwavering accuracy, carefully examining the scene and removing any subjectivity that might skew human judgment (Alqazzaz et al., 2022; Neocleous et al., 2023; Veiga-Canuto et al., 2022).

## **5.5 Revealing Latent Heterogeneity: The Prospects for Personalized Medicine**



Consider a tumor as a varied terrain with hidden subregions that each have unique biological characteristics, rather than as a single, monolithic structure. Sophisticated segmentation techniques that combine data from various imaging modalities, such as CT, PET, and US scans, are like making an intricate topographical map of this complex terrain. With unmatched granularity, these "multi-parametric" models are able to depict the tumor's heterogeneity and identify biologically distinct subregions. With this newfound understanding, a new era of personalized medicine may well be ushered in (Hao et al., 2023). Medical practitioners may be able to tailor treatment regimens to target specific tumor regions by identifying these subregions, offering a more precise and effective way to treat the condition.

### **5.6 Pushing the Boundaries: Seeking Unrivaled Accuracy**

The constant search for advancement is essential to the spirit of scientific inquiry. In order to improve ROI segmentation techniques, researchers are constantly looking for new approaches, especially in difficult situations where the tumor boundaries are hazy or overlap with adjacent structures. To get even more accuracy, advanced image processing methods and DL algorithms are being used. Envision a novel type of detective, armed with state-of-the-art equipment and unparalleled analytical abilities, meticulously inspecting the crime scene and revealing every detail in their pursuit of the truth (Hershman et al., 2021; Hussain et al., 2022).

### **5.7 Working Together and Using Open-Source Tools to Create a Shared Future**

In addition to individual genius, the scientific community as a whole must contribute to the search for the best segmentation techniques. To create open-source software tools and standardize segmentation protocols, researchers are actively working together. Because of the increased accessibility and reproducibility, researchers from all over the world can use these resources and add to the body of knowledge. Envision an international community of investigators, exchanging their knowledge, perspectives, and resources to advance their respective specialties and, in the end, enhance patient results (Lucas et al., 2021).

The foundation of radiomics-based analysis for thyroid cancers is ROI segmentation. It enables researchers to extract useful features, build reliable models, and open the door to personalized medicine by precisely defining the tumor. Future research is expected to yield even more advanced segmentation strategies, which will fully realize the potential of radiomics to transform the treatment of thyroid cancer. And who knows? Maybe these developments will motivate a new wave of medical sleuths to use knowledge and technology to solve medical mysteries and save countless patients' lives (Gao et al., 2023; Lucas et al., 2021).

### **5.8 Extraction of features**

In radiomics, feature extraction is essential for revealing patterns and information from medical images that are not immediately visible to the human eye. This is particularly true when analyzing thyroid cancer. To assist with diagnosis, prognosis, and treatment planning, feature extraction extracts different aspects of the images using complex algorithms and computational tools. This process involves identifying and quantifying a wide range of meaningful characteristics from the image data in order to obtain significant insights into the underlying tissue characteristics and potential abnormality indicators within the thyroid gland (*Figure 8*) (Zhang et al., 2023).

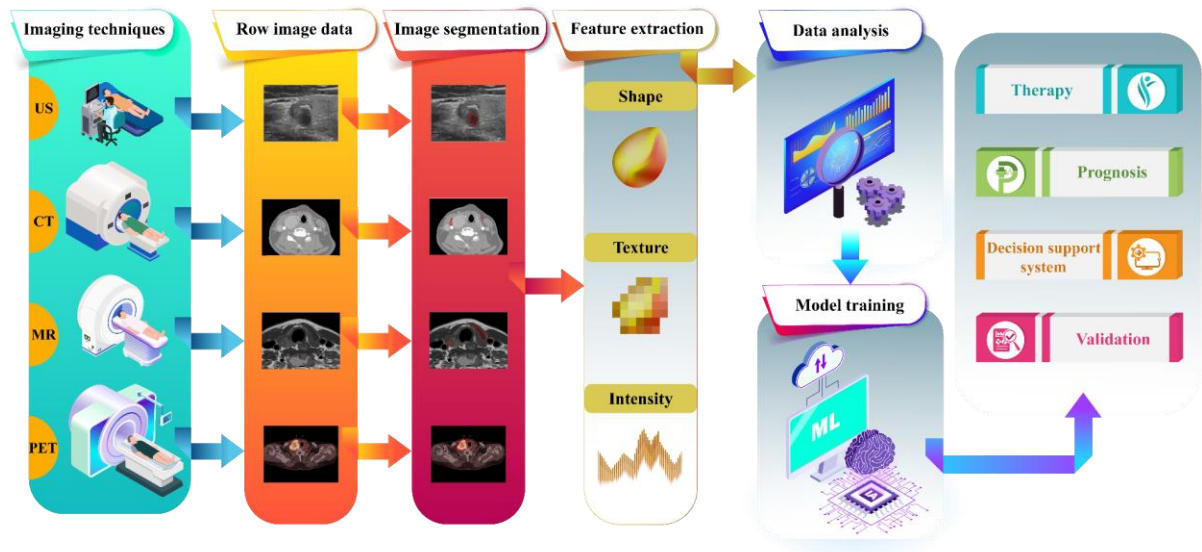


Figure 8 Radiomics analysis involves: (1) Image Acquisition, (2) Image Preprocessing, (3) ROI Segmentation, (4) Feature Extraction, (5) Feature Selection, (6) Model Development, (7) Validation, (8) Interpretation and Reporting, and (9) Clinical Translation.

### 5.9 Features of shape

These characteristics include geometric attributes like the thyroid gland's size, area, roundness, and eccentricity of its regions. Researchers and radiologists can learn more about the spatial arrangement and structural traits of tissues, which may be suggestive of malignant growth or other anomalies, by examining the shape descriptors (Lucas et al., 2021).

### 5.10 Features of intensity

The distribution of pixel values throughout the image is the main focus of intensity features. By extracting information about variations in tissue density or contrast within the thyroid region, analysis of intensity histograms can help identify lesions that may be cancerous (Gao et al., 2023; Kunapinun et al., 2023; Vijithananda et al., 2023; Zhang et al., 2023).

### 5.11 Textural features

Statistical metrics like GLCM and GLRLM, which reveal spatial correlations between pixel intensities, are used in texture features. By evaluating texture features, radiomics can help differentiate between benign and malignant thyroid nodules by providing insight into tissue heterogeneity, smoothness, and coarseness (Cao et al., 2021).

### **5.12 Wavelet Features**

By breaking down the image data into distinct frequency components, wavelet analysis makes it possible to extract spatial-frequency information. Wavelet features aid in the capture of texture patterns at different scales, providing a comprehensive analysis of the composition of thyroid tissue and possibly exposing minute alterations in texture linked to the development of thyroid cancer (Kunapinun et al., 2023; Vijithananda et al., 2023).

In order to extract minute details from medical images, feature extraction in radiomics for thyroid cancer analysis entails a careful examination of shape, intensity, texture, and wavelet features. These characteristics act as quantitative biomarkers to help doctors make well-informed decisions regarding patient care, diagnosis, and treatment planning. Through the use of advanced computational methods, radiomics plays a significant role in providing personalized and data-driven approaches to thyroid cancer assessment, ultimately contributing to precision medicine initiatives (Cao et al., 2021; Kunapinun et al., 2023; Vijithananda et al., 2023).

### **5.13 Feature selection and feature dimension reduction**

Feature selection, which comes after radiomic feature extraction in radiomics, is a crucial step in enhancing the effectiveness of ML algorithms for thyroid cancer data analysis. linked to high dimensionality, enabling quicker model training, and improving the repeatability of the acquired outcomes. Feature selection serves as a filtering mechanism to concentrate on the most pertinent characteristics that greatly aid in differentiating between various thyroid cancer phenotypes and assisting in accurate diagnostic outcomes. It does this by choosing the most informative features from the pool of extracted characteristics (Edwards et al., 2021).

To optimize the selection process in the particular context of thyroid cancer analysis, a thorough investigation included six distinct feature selection techniques. ANOVA, forward and backward elimination, Pearson correlation, ridge regression, and the least absolute shrinkage and selection operator (LASSO) were some of these techniques. By employing diverse feature selection methodologies, the investigators sought to capitalise on the advantages of each approach in pinpointing the most pivotal radiomic features that encapsulate critical details pertaining to tumor attributes, thereby facilitating a more precise and streamlined examination of thyroid cancer imaging data (Satheeshkumar et al., 2021).

The three primary categories of feature selection techniques used in this study are filter, wrapper, and embedded techniques. By using statistical tests to assess the relationship between features and tumor aggression, filters like Pearson correlation and ANOVA choose features according to their relative importance. By repeatedly modifying thresholds, wrapper techniques such as forward and backward elimination construct subsets of features with the goal of assembling a set of variables with strong predictive ability. Feature selection is integrated into the model training process through embedded techniques like LASSO and ridge regression, which combine elements of both filter and wrapper methods to balance model complexity and interpretability while optimizing predictive performance (Dougherty et al., 2009; Satheeshkumar et al., 2021).

The application of filter, wrapper, and embedded techniques in feature selection denotes a multimodal strategy for determining the most pertinent radiomic features for analysis of thyroid cancer. While wrapper methods iteratively refine feature subsets to improve prediction accuracy, filter methods help with the initial screening of features based on their statistical significance (Zhang et al., 2023). In the context of thyroid cancer radiomics, embedded techniques seamlessly integrate feature selection with model training, utilizing the advantages of both filter and wrapper methods to achieve a balance between feature relevance, model interpretability, and predictive performance. Medical researchers are using DL more and more to analyze medical images. By using this method, they can directly collect a greater amount of data rather than having to go through the laborious process of manually extracting features from the images. In recent years, this has gained popularity as a trend (Burt et al., 2018; Ha et al., 2018).

#### **5.14 Model development**

Radiomics utilizes advanced image analysis techniques to extract valuable information hidden within medical scans. This information, known as radiomic features, goes beyond the visual capabilities of traditional diagnosis. These features capture subtle characteristics of tissues, like their structure, texture, and intensity, similar to a unique fingerprint. By combining these features with powerful modeling techniques and extensive databases, Radiomics empowers the development of classifiers. These classifiers, like sophisticated detectives, analyze new medical images and predict potential outcomes, ultimately shaping the field of personalized medicine (Gao et al., 2023).

Currently, Radiomics employs a diverse toolbox of ML algorithms for building these classifiers (X. Wang et al., 2022). This toolbox includes established methods like LR, RF, SVM, and DT. Additionally, innovative techniques like k-nearest neighbors, ANNs, and Bayesian and clustering algorithms are increasingly being explored. It's

important to note that while most of these algorithms fall under the category of supervised learning, requiring pre-labeled data to train the models, some, like clustering algorithms, operate under unsupervised learning, uncovering hidden patterns without prior labels (Lee & Park, 2022).

Building a robust classifier model involves a two-stage process: training and testing (Yu et al., 2023). During the training phase, the model "learns" to distinguish between different outcomes based on the provided data. This data set, crucial for successful learning, needs to be large and representative of the broader population being studied. Once trained, the model is put to the test in the testing phase. Here, entirely new and unseen data is used to evaluate the model's accuracy and ability to accurately predict outcomes. When possible, a third stage, known as validation, can further enhance the model's performance. In this phase, the model parameters such as the quantity and significance of the various features employed are adjusted in light of the validation data (Yu et al., 2023). Through careful navigation of these phases, Radiomics opens up new possibilities for medical images and ushers in a new era of customized healthcare.

## **6. Radiomics and AI in Thyroid Cancer Diagnosis**

The use of radiomics and AI models to improve thyroid cancer diagnosis and treatment has increased significantly in the last few years. Numerous ML and DL techniques have been adopted in this rapidly developing field, showing encouraging results. Numerous studies have examined the effectiveness of these approaches in assessing ML and DL models for the diagnosis and treatment of thyroid cancer, with varying degrees of accuracy. These efforts represent a noteworthy progression in utilizing computational methods to enhance the comprehension and treatment of thyroid cancer, with great promise for enhancing oncology patient outcomes and clinical procedures (Saxena et al., 2022). A selection of these studies are presented below based on the degree of accuracy offered in assessing DL and ML models. This classification emphasizes the wide range of methodologies and the performance measures that correspond with them, highlighting the complexity of this field's research. These studies pave the way for future developments in precision medicine by rigorously evaluating and comparing data, which helps to validate and improve computational approaches for the diagnosis and treatment of thyroid cancer (Taye, 2023). Among the selected studies the utilization of MRI images was relatively limited, with only two studies incorporating this modality into their analyses. MRI offers distinct advantages in capturing detailed anatomical information and soft tissue contrast, making it a valuable imaging tool in oncology. However, its application in thyroid cancer diagnosis and treatment remains less explored compared to other modalities such as ultrasound or CT. Despite this, the studies that did incorporate MRI imaging demonstrated the potential for MRI-based radiomics to contribute to the understanding and management of thyroid cancer.

Table 1: overview of studies in field of integration of radiomics and artificial intelligence in thyroid cancers					
Reference	Imaging	Sample size	Tasks	Approaches	Performance
Zhou et al., 2020 (H. Zhou et al., 2020)	US	US images from 1734 patients	Binary Classification (Malignant or benign)	CNN, TL, DLRT	AUCs of DLRT were 0.96, 0.95, 0.97 respectively in the training, internal and external validation cohort
Kwon et al., 2020 (Kwon, Shin, Park, Cho, Hahn, & Park, 2020)	US	Gray-scale US from 96 patients	Binary Classification (presence or absence of BRAF mutation in PTC)	LR, SVM,RF	AUC of 0.651, accuracy of 64.3%, sensitivity of 66.8%, and specificity of 61.8%, on average, for the 3 models
Göreke et al., 2023 (Göreke, 2023)	US	B-mode thyroid US images from 99 patients	Binary Classification (Malignant or benign)	ANN,CNN,LSTM,RNN	AUC of 1 and recall of 0.99 for all of them,
Zhu et al., 2022 (Zhu et al., 2022)	US	US images from 306 PTC patients	Classification (Large volume lymph node metastasis (LNM))	ANN based radiomic model	AUROC of 0.856 and AUPR of 0.381 for radiomic model, AUROC of 0.910 and an AUPR of 0.463 for integrated model
Xia et al., 2021 (Xia et al., 2021)	US	Clinical and US data from 445 PTC patients	Classification (presence of lymph node metastasis or not)	SVM, PNN	F1 score of 0.88 on the central lymph node metastasis in PNN, F1 score of 0.93 on the lateral lymph node metastasis in SVM
Agyekum et al., 2022 (Agyekum et al., 2022)	US	Clinical and US data from 205 PTC patients	Classification (cervical lymph node metastasis)	USR model Clinical model, USR-Clinical model	AUC of 0.71 in USR-clinical, 0.74 in USR, and 0.63 in clinical model
Wang et al., 2020 (Wang et al., 2020)	US	US images from 1040 patients	Binary Classification (Malignant or benign)	Radiomics model,DL	Accuracy of 66.81% in radiomics and 74.69% in DL
Li et al.,2021 (Li et al., 2021)	CT	CT images of Thyroid 678 patients with PTC	Binary Classification( CLNM-,CLNM+)	KNN,LR,DT,L-SVM, Polynomial-SVM, Gaussian SVM algorithm	L-SVM:higher classification accuracy 0.709 Internal and external validation c-index 0.854
Wu et al.,2022 (Wu et al., 2022)	CT	CT images from 412 patients with PTC	Classification (TCl+, TCl-)	KNN,LR,DT,L-SVM,Polynomial-SVM, SVM	internal test cohort L-SVM, AUC=0.820 [95%CI 0.758–0.888] external test cohort, the AUC was 0.776 (0.625–0.904)
Wang et al.,2022 (Y. G. Wang et al., 2022)	US	US images from 138 Patients with PTC	Binary Classification (BRAF+, BRAF-)	LASSO-mRMR-	Elasticity US AUC 0.952, grayscale US AUC 0.792, and D combination AUC 0.914 in the training dataset, elasticity US AUC 0.931, grayscale US AUC 0.725 and combination AUC 0.938 in the test dataset
Yu et al., 2022 (P. Yu et al., 2022)	CT	CT images from 153 patients with PTC	Classification (extrathyroidal extension (ETE))	LASSO, KNN, logistic regression, DT, linear -SVM, gaussian-SVM, and polynomial-SVM	Best internal test cohort:L-SVM, AUC=0.820 best radiomics model (L-SVM, AUC = 0.733) clinical model (AUC = 0.709 external test cohort, the AUC was 0.776
Yu et al.,2022 (J. Yu et al., 2022)	US	US images from 650 patients with PTC	Binary Classification (RET/PTC, Non-RET/PTC)	DLRN logistic regression algorithm	AUC of DLRN in test cohort 0.9545 and in training cohort 0.9396
Zhou et al.,2022 (S. C. Zhou et al., 2020)	US	US images of thyroid and central cervical lymph from 609 patients with PTC	Classification	Lasso regression model -multivariable logistic regression radiomics signature, ultrasonography-reported LN	C-index of 0.816 in the primary cohort and 0.858 in the validation cohort AUC 0.858. In the validation cohort, the accuracy, sensitivity, specificity and AUC of this model were 0.812, 0.816, 0.810, and 0.858
Xu et al., 2022 (Xu et al., 2022)	CT	CT radiomics from 161 patients	Binary Classification (Malignant or benign)	LR	AUC of 94.4%, an accuracy of 87.6% in the train, and 94.2%, and 86.8% respectively for the test group
Shi et al., 2022 (Shi et al., 2022)	US	US imaging, clinical data, and radiomics of 587 PTC patients	Classification (central cervical lymph node metastasis)	Boruta algorithm, XGBoost model,	AUC 91.53%
Gu et al., 2019 (Jiabing Gu et al., 2019)	CT	CT images 103 patients with suspected thyroid nodules	Classification (malignant or benign)	SVM	AUC 0.87, sensitivity 0.93, and specificity 0.73
Li et al., 2023 (Li et al., 2023)	US	US images from 164 pediatric patients with PTC	classification (extrathyroidal extension or not)	LightGBM, KNN,SVM,RF	AUC of 0.832, 0.720, 0.784, 0.728 respectively for four model
Kwon et al., 2020 (Kwon, Shin, Park, Cho, Kim, & Hahn, 2020)	US	US radiomics from 169 patients with FTC	Classification (distant metastasis or not)	SVM classifier Radiomics and histological features	AUC of 0.90 for SVM, and 0.93 for radiomics and widely extensive histology feature
Sharma et al., 2023 (Sharma et al., 2023)	US	Two datasets: the US dataset (298 patients) and	Classification (malignant or benign)	transformation techniques	RF and PCA+FOX yielded the best performance: AUC of

		the Histopathological Dataset (156 thyroid tumors)		(PCA, TSVD, FastICA, ISOMAP, LLE, and UMP) and (LR, NB, SVC, KNN,RF)	99.13%, an accuracy of 99.13% in the US, and 95.48%, and 90.65% respectively in the histopathological dataset
Liu et al., 2019 (T. Liu et al., 2019)	US	US images from 450 PTC patients	Classification (presence of lymph node metastasis or not)	SVM	AUORC of 0.727, accuracy of 0.710
Lu et al., 2019 (Lu et al., 2019)	CT	CT images from 221 PTC patients	Classification (central cervical lymph node metastasis)	SVM, Multivariate logistic regression	AUC of 0.795 and 0.822 respectively for SVM and multivariate logistic regression
Zhu et al., 2023 (Zhu et al., 2023)	US	US images from 371 PTC patients	Binary Classification(with cervical lymph node metastasis,without cervical lymph node metastasis)	RF, LASSO, binary LR, KNN, SVM, XGboost	AUC of RF-RF model validation group (0.812)
Peng et al., 2021 (Peng et al., 2021)	US	US images 8339 patients	Binary Classification(thyroid nodules into malignant tumors or benign nodules)	ThyNet	ThyNet 0.922 radiologists 0.839
de Koster et al., 2021 (de Koster et al., 2022)	FDG-PET/CT	[18F] FDG-PET/CT thyroid nodule from 123 patients	Classification	SUV- Elastic net regression classifiers	SUV-metrices showed AUCs ranging from 0.705 to 0.729 in all, 0.708 to 0.757 in non-Hurthle and 0.533 to 0.700 in Hurthle cell
Wei et al., 2021 (Wei et al., 2021)	MRI	MRI 132 patients with PTC	Binary Classification (those with ETE and those without ETE)	DWI, T2 WI, CE-T1WI	AUC 0.87
Dai et al., 2022 (Dai et al., 2022)	MRI	MRI 107 patients with PTC	Classification(aggresiveness and non-aggressiveness)	meta-analysis-sparse representation method	CE-T1WI, T2WI and DWI combined 0.917
Yu et al., 2020 (Yu et al., 2020)	US	US images of 3172 patients with PTC	Classification of patients into groups based on the risk of lymph node metastasis in PTC	Transfer Learning-based model (TLR)	AUC main cohort : 0.90 independent cohorts:0.93
Zhou et al., 2021 (Zhou et al., 2022)	CT	CT images from 346 patients with PTC	Classification (LNM,CLNM)	MRMR,RF,LASSO,LR, Decision Curve Analysis	discrimination and calibration of training cohorts (AUC = 0.847; AUC = 0.837) validation cohorts (AUC = 0.807; AUC = 0.795

A study by Wei et al. used radiomics based on multiparametric MRI to predict extrathyroidal extension (ETE) in PTC. Thirty-two patients made up the test cohort and ninety-two patients made up the training cohort in their study. They created a radiomics predictive model that demonstrated the ability of MRI radiomics to stratify PTC patients based on ETE prior to surgery, achieving high AUCs of 0.96 and 0.87 in the training and testing sets, respectively. The study used a combination of high-performing features from DWI, T2 WI, and CE-T1WI images in a retrospective trial that involved manual segmentation of thyroid tumors for radiomic feature extraction. According to the findings, MRI-based radiomics may be able to predict ETE in PTC in a non-invasive manner, which would be helpful for preoperative evaluation and treatment planning (Wei et al., 2021).

By combining features from contrast-enhanced T1-weighted, T2-weighted, and diffusion-weighted images, Dai et al. developed a multimodality MRI-based radiomics model for predicting aggressiveness in PTC, achieving a high accuracy of 0.917. Their research, which included 107 PTC patients, attempted to provide guidance on prognosis and treatment options for severe cases. The study illustrated the potential of MRI-based radiomics in non-invasively assessing thyroid cancer aggressiveness by using a sparse representation method for feature selection and model establishment. Manual segmentation was performed for region of interest delineation, and the study highlighted the possibility of exploring DL for automatic segmentation in future work. The model's high

accuracy, supported by an AUC of 0.960, underscores the clinical relevance and utility of machine learning-based image analysis in rapid and informative cancer assessment (Dai et al., 2022).

Also, seven studies employed CT images as part of their radiomics analyses in thyroid cancer research. CT imaging offers distinct advantages, including high spatial resolution and the ability to visualize anatomical structures in detail. This modality provides valuable information on tumor size, shape, and density, facilitating accurate diagnosis and staging of thyroid cancer. In these studies, CT-based radiomics approaches were utilized to extract quantitative imaging features from CT scans, enabling the development of predictive models for various aspects of thyroid cancer, such as lymph node metastasis, extrathyroidal extension, and cervical lymph node metastasis.

A CT-based radiomics model was created in a multicenter study directed by Li et al. to forecast central cervical lymph node metastases (CLNM) in patients with PTC. By incorporating radiomic characteristics and clinical risk factors, the model demonstrated superior sensitivity and accuracy compared to a skilled radiologist, indicating its potential as a non-invasive preoperative instrument with practical applications. The model, which focused on the linear-SVM algorithm and included 4227 extracted radiomic features, showed encouraging results and good agreement when predicting CLNM across a range of test sets. Treatment decision support in PTC cases could be improved by using the developed model, which addresses diagnostic limitations (Li et al., 2021).

The use of a CT-based radiomics model for predicting thyroid capsule invasion (TCI) in PTC was examined in a two-center study directed by Wu et al. CT scans were processed to extract radiomic features, and six supervised ML models were built. In predicting TCI, the combined-linear-SVM model performed better than the radiomics and clinical models due to its stable and clinically useful integration of optimal radiomics features and clinikoradiological risk factors. Notwithstanding the limitations of the study, such as the absence of a sizable sample size and the consideration of various factors, the ML-based methodology exhibited strong predictive capacity. It is advised to conduct more research with bigger sample sizes and multiple centers to improve the generalizability and efficiency of the model (Wu et al., 2022).

Yu and colleagues created a radiomics nomogram that combines clinical risk factors with radiomics features taken from CT images to predict extrathyroidal extension (ETE) in PTC patients. The AUCs ranged from 0.642 to 0.701, indicating the potential value of the nomogram in predicting ETE, although the study was retrospective in nature. Notwithstanding, certain limitations are recognized, such as the possibility of selection bias and the requirement for prospective studies to account for confounding variables. The study sought to address the effects



of ETE, which are linked to lymph node metastasis and invade surrounding structures, both of which have an impact on outcomes. Using a variety of ML techniques, the radiomics nomogram demonstrated potential to support preoperative ETE prediction in PTC. 153 patients were included in this study; training, internal, and external test sets were used for validation, and ROI segmentation was done manually using CT scans. The performance of the nomogram was assessed using calibration curve evaluations, decision curve analysis (DCA), and ROC curve analysis (P. Yu et al., 2022).

A logistic regression model is used in the study by Xu and colleagues to examine the diagnostic potential of CT-based radiomics for differentiating between benign and malignant thyroid nodules. The research, which examined data from 161 patients, shows how accurate the model is, with an amazing AUC of 94.4% in the training group and 94.2% in the test group. The model also has corresponding sensitivities of 89.7% and 89.4% and specificities of 86.7% and 86.8%. This research addresses the common clinical challenge of differentiating between benign and malignant cases, with an emphasis on the thyroid gland as a whole rather than on individual nodules. The study's limitations, including its small sample size and dependence on single-center data, are acknowledged despite the satisfactory results obtained. This underscores the necessity of conducting additional research with larger multi-center sample sizes in order to improve the model's generalizability and applicability in predicting thyroid nodule characteristics. The study emphasizes the use of cutting-edge technologies, such as ML and CT scanning, to enhance thyroid nodule assessment diagnostic accuracy (Xu et al., 2022).

In the Gu et al. study, a radiomics model was created for the noninvasive prediction of cytokeratin 19, galectin 3, and thyroperoxidase based on CT images. The study focused on the prediction of immunohistochemistry (IHC) of suspected thyroid nodules using ML-based radiomics. 103 patients with thyroid nodules were analyzed for the study, and the IHC results were categorized as positive and recessive. For model construction, the study used feature extraction, feature reduction, and ROI segmentation with 3D Slicer software. When it came to distinguishing between benign and malignant thyroid nodules and forecasting the existence of particular markers, the radiomics model performed admirably. The study highlighted the clinical relevance of galectin 3 and cytokeratin 19, which are known to be elevated in papillary carcinoma. Positive immunoexpression of these markers also increased the diagnostic accuracy of papillary thyroid cancer. Moreover, it has been determined that thyroperoxidase immunoexpression positivity is a separate risk factor for thyroid cancer. Notwithstanding, the study recognized its limitations, including its reliance on a single center and small sample size. This underscores the need for external validation conducted across multiple centers with larger prospective patient cohorts. In the context of thyroid nodule

diagnosis, the study demonstrated the potential of a radiomics model for personalized and noninvasive prediction, offering insightful information for further investigation and clinical implementation (J. Gu et al., 2019).

Zhou studied the radiomics analysis of iodine maps from dual-energy CT (DECT) to predict cervical lymph node metastasis (CLNM) in PTC. In order to predict CLNM, two radiomics nomograms were created and validated. In both the training and validation cohorts, these nomograms showed good discrimination and calibration. These nomograms demonstrated the promise of radiomics-based risk stratification in PTC, especially in CT-reported negative subgroups where they demonstrated favorable predictive efficacy. The study compared the predictive efficacy of radiomics nomograms and clinical models using DECT scanning with post-processing for radiomics analysis. Although the nomograms demonstrated encouraging accuracy, the study recommends larger sample sizes and multicenter studies for validation in addition to radiation dose reduction strategies for DECT scans. For PTC patients, the radiomics nomograms provide useful tools for preoperative CLNM prediction, which may help with treatment planning and enhance clinical outcomes (Zhou et al., 2022).

Lu et al. present a radiomics-based approach to predict cervical lymph node metastases in PTC patients prior to surgery. The study (involving 221 PTC patients) selects a radiomic signature with improved predictive performance by extracting 546 radiomic features from CT images. The predictive value increases and shows strong discrimination, calibration, and clinical utility when this signature is included in a nomogram. The radiomic nomogram outperforms the clinical nomogram in PTC patients, suggesting a potential clinical utility for this noninvasive preoperative technique for determining cervical lymph node metastasis. The study shows how radiomics can increase predictive accuracy in thyroid cancer diagnosis, despite its retrospective design and need for outside validation (Lu et al., 2019). Additionally, de Koster et al. employed [18F]FDG-PET/CT images in their study, adding another dimension to the radiomics analysis of thyroid nodules. [18F]FDG-PET/CT imaging offers unique insights into metabolic activity and functional information, complementing the anatomical details provided by CT scans (de Koster et al., 2022).

A prospective study by Koster et al. sought to improve radiomics and [18F]FDG-PET/CT assessment in the differentiation of indeterminate thyroid nodules. The study emphasizes the significance of quantitative [18F]FDG-PET/CT assessment, especially in Hürthle cell nodules, for preoperative differentiation, and includes patients with Bethesda III or IV thyroid nodules. While it presents difficulties in Hurthle cell neoplasms, visual evaluation of [18F]FDG-PET/CT helps rule out thyroid malignancy in [18F]FDG-negative nodules. The study highlights how radiomic analysis can only play a limited role in helping to differentiate [18F]FDG-positive nodules. The study

assesses the diagnostic accuracy using elastic net regression classifiers and receiver operating characteristic (ROC) curve analysis; AUC values for various SUV metrics range from 0.705 to 0.757. According to radiomic analysis, the PET model's AUC was 0.445. Although the study recommends higher SUV cut-offs for the best rule-out performance in Hürthle cell nodules, specificity data for quantitative [18F]FDG-PET/CT evaluation is absent. In summary, the study highlights the significance of quantitative [18F]FDG-PET/CT evaluation in enhancing the distinction of indeterminate thyroid nodules, offering vital perspectives for medical application (de Koster et al., 2022).

The remaining studies in the review exclusively utilized US images as the primary imaging modality for radiomics analysis in thyroid cancer diagnosis and prognosis. US imaging is widely utilized in clinical practice due to its non-invasive nature, accessibility, and ability to provide real-time imaging with high resolution. Leveraging US images for radiomics analysis offers valuable insights into the morphological and textural features of thyroid nodules, facilitating the development of predictive models for risk stratification and treatment decision-making.

DL Radiomics of Thyroid (DLRT) was investigated by Zhou et al. as a novel method for using US images to diagnose thyroid nodules. DLRT achieved the highest AUC and sensitivity across multiple validation cohorts, outperforming other DL models and even human observers in terms of accuracy. AUCs of DLRT were 0.96, 0.95, and 0.97 in the training, internal, and external validation cohort, respectively. DLRT performed significantly better than other deep learning models and human observers. Also, DLRT demonstrated the highest diagnostic accuracy for benign and malignant thyroid nodules. Sensitivities of DLRT reached 90.1, 89.3, and 89.5 in different cohorts. DLRT had higher accuracy compared to TL model and basic CNN model. This novel approach does away with the requirement for manual segmentation, makes use of transfer learning to increase accuracy, and works well with a variety of US systems. The specificity of the model is not stated in the study, and more research is necessary to rule out any biases brought on by specimen collection and operator experience. Notwithstanding these drawbacks, DLRT shows great promise as a highly precise and broadly applicable diagnostic technique for distinguishing between benign and malignant thyroid nodules (H. Zhou et al., 2020).

The use of ultrasonography in radiomics to predict BRAF mutation in papillary thyroid carcinoma was investigated by Kwon et al, who found that the technique was at most moderately successful. Even with an AUC of 0.65 and an average accuracy of 64.3%, it was not a very good diagnostic tool. Several ML models were used in the study, but none proved to be particularly beneficial. The authors highlight several drawbacks, including a small sample size, the possibility of overfitting the models, and intrinsic difficulties in quantifying ultrasonography data in

comparison to other imaging modalities. They draw the conclusion that the current utility of radiomics using US to predict BRAF mutation is limited, and they advocate for more study with larger datasets and a wider range of diagnostic techniques to validate and improve the methodology (Kwon, Shin, Park, Cho, Hahn, & Park, 2020).

Göreke et al.'s study developed a unique DL-based Computer-Aided Diagnosis (CADx) architecture for the use of US images in the classification of thyroid nodules. Using a multi-layer deep neural network that combines morphological and texture features with features taken from US images via a pre-trained deep neural network, the suggested system outperforms existing literature in terms of performance. Recurrent Neural Network (RNN) architecture was chosen for the DL classifier due to its highest accuracy, and other noteworthy innovations include the addition of a pre-weighting layer using a modified genetic algorithm and a novel feature extraction method based on class similarity. With better performance than previous studies, the paper highlights the development of a computer-aided diagnosis system for thyroid nodules using DL and data augmentation techniques. Utilizing B-mode thyroid US images that have been manually segmented by a radiologist, the study includes a thorough comparison with previous research, bolstered by graphs and tables that demonstrate the validity and reliability of the suggested model. The efficacy of the suggested multi-layered classifier architecture is indicated by the AUC metric, which is the basis for the performance evaluation. Using a deep neural network that has already been trained on the ImageNet dataset, transfer learning is used. The study's sample size is 1254 thyroid sonographic images. It focuses on the diagnosis of thyroid cancer and uses a variety of cutting-edge techniques, including deep active contour modeling for nodule segmentation, SNDRLS for nodule identification, and a Transformer and CNN-based strategy for the segmentation of malignant thyroid lesions within a CAD system. Although the validation process is not explicitly described, the suggested CAD system performs better than previous research in terms of accuracy and uses statistical tests to determine the most discriminative approach (Göreke, 2023).

Additionally, Zhu and associates describe an US radiomics approach based on ANNs that predicts large-volume lymph node metastasis (LNM) in patients with clinical N0 PTC. The radiomic model, which makes use of a training and validation cohort, exhibits better discrimination than papillary thyroid carcinoma, which is the most common type of thyroid cancer and frequently results in metastases to the central lymph nodes. Age and male sex have been identified as risk factors for large-volume LNM, which is linked to an increased recurrence risk and upstaging. The study uses deidentified data and a retrospective methodology, utilizing ANN-based The integrated model further enhances performance with an AUROC of 0.910, while the ANN-based radiomic model achieves an Area Under the Receiver Operating Characteristic (AUROC) of 0.856. With an accuracy of 91%, the integrated model outperforms the radiomic model, which has an accuracy of 86%. Nevertheless, the information that is

currently available lacks specifics for both the integrated model and the ANN-based radiomic model. 306 clinical N0 PTC patients are included in the study, with a 6:4 ratio between the training and validation cohorts. The imaging technique is US; manual ROI segmentation is done with the open-source 3D Slicer version 4.10.2 program. The validation cohort (n = 123 patients) is randomly divided for model evaluation, and performance metrics, namely Area Under the Precision-Recall Curve (AUPR) and AUROC, are employed (Zhu et al., 2022).

Xia et al. report a study utilizing an AI algorithm to predict lymph node metastasis in patients with PTC prior to surgery. The AI algorithm uses clinico-pathologic data to predict lymph node metastasis by combining probabilistic neural network (PNN) and SVM. With an F1 score of 0.88 for central lymph node metastasis and 0.93 for lateral lymph node metastasis, the study illustrates the usefulness of this combination. Before surgery, the combination of AI algorithms and clinico-pathologic data is a useful tool for predicting lymph node metastasis in PTC patients. With the rising incidence of thyroid cancer, early detection and treatment are essential. The most prevalent subtype, PTC, is predictive of recurrence because it frequently involves lymph node metastasis. AI algorithms in particular, which are predictive models, are useful for risk stratification. In order to predict lymph node metastasis, this study makes use of SVM and PNN classifiers, highlighting the importance of pathological, demographic, and US features in the predictive model. A crucial component in the analysis of clinico-pathologic data is the AI algorithm, which consists of SVM and PNN. With the PNN classifier showing an F1 score of 0.88 for central lymph node metastasis and the SVM classifier displaying an F1 score of 0.93 for lateral lymph node metastasis, the SVM model achieves the highest verification accuracy rate. Using B-mode US features, the study imaged 251 PTCs with lymph node metastasis and 194 without. Using training and test sets, the SVM and PNN algorithms are applied independently to lymph node metastases in the central and lateral regions. For SVM model debugging, the grid search method is used to find the best parameters based on the highest verification accuracy rate. The study's overall findings highlight how well AI algorithms and clinico-pathologic data can be used to predict lymph node metastasis in PTC patients prior to surgery (Xia et al., 2021).

Cao et al. explores the use, limitations, and investigation of radiomics in the context of thyroid nodules and differentiated cancer. The procedure involves the identification of regions of interest, the extraction of features, and the execution of analyses. Radiomic features are quantitative and classified into various categories. The study emphasizes the potential uses of radiomics in radiogenomics, illness diagnosis, and outcome prediction, with a special emphasis on its applicability to thyroid cancer. A possible remedy is provided by radiomics, which improves cancer diagnosis, detection, and treatment response evaluation. The article highlights the quantitative character of radiomic features that are divided into various categories by going over popular techniques for calculating ROI and

extracting radiomics features. The intricacy of tumor cells and microenvironments, disparities in imaging protocols across institutions, and the "black box" nature of classifiers, however, make it difficult to interpret and generalize radiomics results. There are also ethical questions brought up, such as treatment response-based prognosis and patient stratification. The accuracy and discriminating power of predictive models are shown by the AUC, which is frequently used to assess the performance of radiomics. Between 66 and 86 is the average diagnostic accuracy of radiomics; however, there are significant differences in the prediction of particular mutations in differentiated thyroid cancer DTC. While there are still issues with DL's interpretability, ML algorithms including DL show excellent accuracy in classifying thyroid nodules (Cao et al., 2021).

The thorough analysis of AI in the thyroid field by Bini et al. provides insight into the advances achieved in image recognition for thyroid pathologies through the application of AI techniques. The review notes that while AI has improved things, there is still uncertainty about how well AI techniques can diagnose thyroid images. Since AI is unable to completely replicate the holistic image interpretation process, it is imperative to comprehend the AI workflow in order to avoid misleading outcomes. The potential of AI techniques as a crucial component of thyroid image assessment is emphasized, along with their integration into the clinical workflow. According to the review, AI should be used as a tool to enhance human expertise rather than to replace it. To improve image assessment, integration with mixed reality tools is suggested, and the paper urges thorough investigation to uncover mixed reality's potential in diagnostics. The critical role that medical imaging plays in early disease detection is recognized, and valuable information is extracted through quantitative analysis. The review explores computer-aided detection and diagnosis systems, with a focus on radiomics an automated medical image analysis field that uses AI techniques and its significance. The advantages and disadvantages of different AI-based methods are examined, with special attention to the difficulties in developing a generalizable model for the best possible application. The study emphasizes how crucial it is for medical professionals to comprehend how AI techniques operate in order to guarantee effective predictive models. The article highlights the drawbacks and restrictions of the AI approach and acknowledges the lack of certainty surrounding the diagnostic efficacy of AI techniques on thyroid images. The AUC metric is presented as a way to assess a classifier's effectiveness. The review notes that there is uncertainty regarding the diagnostic accuracy of AI methods applied to thyroid images, even as it suggests that these techniques may improve the accuracy of thyroid pathology diagnosis. The paper does not contain any specific information regarding specificity (Bini et al., 2021). Large datasets and computational power have led to an increase in ML algorithms, which are essential for medical imaging analysis and computer-aided diagnosis (CAD) systems. The SVM approach and feature-based supervised learning are two ML approaches that are highlighted for use in

medical imaging analysis. According to the review's referenced paper by Bini et al. each radiomic feature that is examined should require the participation of approximately 10–15 patients. It is advised to use US imaging to identify thyroid lesions early on and diagnose them. Manual delineation by experts is considered the gold standard, with various segmentation algorithms, such as region-growing-based and grey-scale threshold-based methods, discussed. It is stressed how important it is to use multiple centers, independent training and validation datasets, and feature-based supervised learning algorithms like LR, SVM, RF, and neural networks. In this context, the SVM method is frequently applied to binary classification problems (Bini et al., 2021).

The controversial field of applying AI to thyroid nodule characterization is examined in Sorrenti et al. Paper. The main ideas highlight AI's potential as a supplementary tool rather than an alternative to skilled radiologists, with results either on par with or below those of experienced US specialists. The results of current AI solutions should be examined by board-certified radiologists, as they are better suited for educational purposes. Using Computer-Aided Diagnosis (CAD) software, the research team examined thirty human studies from the PubMed and Google Scholar databases. The study emphasizes the necessity of more extensive, standardized research to properly assess AI performance. The objective, in spite of the controversy, is to create a diagnostic tool that uses ML and radiomics to classify thyroid nodules according to risk. In addition to highlighting the value of radiologist supervision, the paper makes recommendations for CAD integration with AI solutions in educational settings (Sorrenti et al., 2022).

Agyekum et al. used a ML-based Clinical-Ultrasound Radiomic (Clinical-USR) model to assess cervical lymph node metastasis (CLNM) in cases of PTC. The goal of the project is to enhance the critical preoperative identification of CLNM in PTC patients. Important conclusions and techniques consist of: The clinical-USR model outperforms an experienced sonographer in terms of accuracy when predicting CLNM in PTC patients. The model considers PTC heterogeneity, a measurable characteristic linked to malignancy, which eliminates subjectivity in standard US imaging diagnosis. PTC is the most common subtype of thyroid cancer; CLNM is present in 30-80% of patients, so precise preoperative detection is crucial. US radiomics (USR) extracts quantitative features, and ML models based on USR improve CLNM prediction. When paired with USR, clinical risk factors offer additional information that improves prediction accuracy. 205 patients from January 2015 to April 2020 were included in the retrospective study, which was divided into training and validation cohorts at a ratio of 7:3. Nine statistically significant variables were used to build the Clinical-USR model, with internal echo, shape, age, and mass being identified as the main predictors. Standard clinical statistics, such as the AUC, accuracy, sensitivity, specificity, negative predictive value (NPV), and positive predictive value (PPV), were used to assess the diagnostic

performance of the model. The research notes certain difficulties, including the challenge of using ultrasonography to detect all metastatic lymph nodes, subjectivity in standard ultrasonography diagnosis, and limited visual measurement of PTC density and tissue heterogeneity (Agyekum et al., 2022).

In Wang et al.'s study, thyroid nodule classification using US images was compared between radiomics and DL techniques. The study emphasized the value of ultrasonography for early detection and concentrated on the rising prevalence of thyroid nodules, a common thyroid condition. Specifically, DL using CNNs and radiomics were suggested as ML techniques for the classification task. The study used a dataset consisting of 3120 US images from 1040 cases. Interestingly, DL performed better than radiomics, with an accuracy of 74.69% against radiomics' 66.81%. Large datasets are essential for improving the performance of DL models, according to the research. It was suggested that future work focus on DL model optimization and multicenter data validation of efficacy. Utilizing the AUC as a performance metric, the research demonstrated a noteworthy distinction in AUC between DL and radiomics techniques. The AUC of the DL method was higher than that of radiomics. The study acknowledged certain limitations, such as the lack of a comparison between radiomics and DL techniques and the need for additional improvements to the DL model (Wang et al., 2020).

The goal of Yu et al.'s research is to predict RET rearrangement in PTC by means of a novel method that combines DL and US radiomics. AUCs of 0.9545 in the test cohort and 0.9396 in the training cohort indicate the excellent performance of the DL radiomics nomogram (DLRN), which was developed. The behavior of aggressive PTCs, RET rearrangement, was predicted by using ultrasonic radiomics and deep transfer learning. Among the clinical characteristics that separated patients with and without RET rearrangement were age, tumor size, and calcification. Additionally, the DL radiomics signatures model in conjunction with Despite its limitations—a small sample size and a single-center retrospective design the study suggests further validation in larger, multicenter surveys to increase the reliability of the suggested DLRN model. suggested model for DLRN. The importance of this strategy for enhancing preoperative prediction for RET rearrangement in PTC is emphasized in the paper (J. Yu et al., 2022).

Wang et al.'s. The aim of one study was to predict BRAF V600E mutations in PTC using grayscale imaging and elasticity US. The development of radiomic models from US images showed high accuracy in mutation prediction, with areas AUC ranging from 0.725 to 0.985. The model with the highest AUC was the combination of elasticity and grayscale. 138 PTC patients underwent preoperative ultrasonography, and radiomic features were taken out for model creation. Some of the limitations were the small sample size, the retrospective design, and the absence of outside validation. The study demonstrated the clinical utility of noninvasive US diagnoses in predicting



BRAF V600E mutations, potentially improving treatment outcomes for patients with PTC, despite these limitations. The evaluation of the radiomic models' accuracy, sensitivity, and specificity showed encouraging outcomes in terms of BRAF V600E mutation prediction. Three reliable models were developed with the help of manual ultrasonic image segmentation, AI techniques, and ML. The study underlined that in order to improve the predictive models' generalizability and reliability, more research with bigger sample sizes and external validation is required (Y. G. Wang et al., 2022).

By utilizing an US radiomics nomogram, the Zhou et al. study presents a novel method for preoperative prediction of central neck LN metastasis in papillary PTC. The study integrates radiomics features, US findings, and clinical factors to develop a predictive model in response to the suboptimal accuracy of US in diagnosing central cervical LN metastasis in PTC. This extensive nomogram shows strong discrimination and consistency; in the validation cohort, the area under the AUC was 0.858. With its high AUC values and remarkable sensitivity, specificity, and accuracy, the model shows promise for personalized predictions in clinical settings, giving doctors an important tool to improve preoperative decision-making (S. C. Zhou et al., 2020)

An US-based radiomics XGBoost model is created in the Shi et al. study to forecast central cervical lymph node metastasis (CCLNM) in PTC patients. The model uses 11 radiomics features, including important variables like capsular invasion, radiomics score, diameter, age, and calcification, to calculate the radiomics score after retrospectively analyzing data from 587 PTC patients. When compared to radiologists, the XGBoost model performs better, showing an astounding 44% increase in AUC. The stability of the XGBoost model is particularly noteworthy, as it demonstrates reliable performance on various kinds of US scanners. The study highlights the importance of CCLNM preoperative prediction in PTC and shows that US-based radiomics, XGBoost, and SHAP are effective tools for precise risk assessment and customized interpretation of predictive features in the diagnosis of thyroid cancer. The XGBoost model's positive and negative effects on each parameter are revealed by the SHAP plots, which enhances the model's interpretability and comprehension of its decision-making process. The extensive methodology emphasizes the integration of cutting-edge techniques in thyroid cancer research and includes image segmentation, feature extraction, normalization, LASSO logistic regression, and the creation of the XGBoost model. The findings point to the developed model's possible clinical utility in improving diagnostic precision in PTC patients' CCLNM prediction (Shi et al., 2022).

In a study published in 2015, Li and colleagues used a multi classifier US radiomics model to develop a machine-learning technique for predicting ETE in pediatric PTC. Four supervised ML models were created: LightGBM, k-nn, RF, SVM, and LightGBM. The LightGBM model performed exceptionally well in both the training

and validation cohorts. The model was greatly influenced by notable features like wavelet-HHH\_glszm\_SmallAreaLowGrayLevelEmphasis, original\_shape\_MinorAxisLength, and original\_shape\_Maximum2DDiameterColumn. The amalgamated model, which fused ultrasonic radiomics and ML, demonstrated exceptional prognostic potential for ETE in pediatric PTC. The study highlighted the high incidence of PTC in both adults and children, particularly the aggressive nature and recurrence potential associated with ETE. It was based on a retrospective analysis of data from 164 pediatric patients with PTC. Using a correlation coefficient screening method, ML models were developed, radiomics features were extracted from US images, and the SHAPley Additive explanations SHAP framework was utilized to explain the models. The study revealed the important radiomic features influencing the predictions and demonstrated the potential clinical utility of the developed models, especially the LightGBM model, in predicting ETE. One of the limitations was the small sample size, which suggested that larger samples and more thorough multicenter investigations were required for additional validation. The imaging modality utilized in the study was US imaging, and reliable techniques for data division, model development, and validation were used (Li et al., 2023).

In a study, Kwon et al. used radiomics analysis based on gray-scale US to predict distant metastasis in FTC. The second most common thyroid cancer is called FTC, and a major predictor of a poor prognosis is distant metastasis. The objective of the study was to create an independent biomarker for distant metastasis in FTC using radiomics signatures. Radiomics analysis used the least absolute shrinkage and selection operator to create a radiomics signature by extracting features from US images. The radiomics signature was utilized to train an SVM classifier. The classifier showed an AUC of 0.90 on the test folds. With an AUC of 0.93, multivariate analysis showed the classifier's strong diagnostic performance. Robustness was indicated by the excellent intraclass coefficient (ICC) values of a few selected radiomics features. Distant metastasis was linked to clinical factors like size, age, widely invasive histology, lymph node metastasis, and extrathyroidal extension. On the other hand, widely invasive histology and the radiomics signature were found to be independent variables linked to distant metastasis. The study stressed how critical it is to identify high-risk FTCs early and treat them aggressively. With its independent biomarker for clinical decision-making, the SVM classifier which is based on radiomics features from thyroid ultrasonography proved to be an effective tool in predicting distant metastasis in FTC. The study established a trustworthy predictive model for distant metastasis in FTC using a strong methodology that included radiomics analysis, SVM classifier training, and multivariate analysis. The potential of non-invasive and imaging-based methods in the prognosis of thyroid cancer is increased by the emphasis on US-based radiomics. Using US and histological images, Rohit Sharma provides a thorough framework for the detection of thyroid cancer that integrates

DL, meta-heuristics, and Multiple Criteria Decision Making (MCDM) algorithms. The study evaluates five classifiers using three DL techniques and six feature transformation methods, and uses MEREC-TOPSIS MCDM for model ranking. The suggested framework outperforms current diagnostic techniques for abnormalities related to the thyroid in terms of accuracy and AUC-ROC scores. By emphasizing early diagnosis, the framework seeks to reduce the workload for medical practitioners by offering enhanced diagnostic capabilities. The study highlights the significance of accurate CAD models for patient care by utilizing pre-trained DL models, dimensionality reduction techniques, and the FOX optimization algorithm for feature selection. The study highlights the framework's potential to advance thyroid cancer diagnosis through a thorough evaluation of models, techniques, and algorithms, while acknowledging limitations such as dataset focus and availability (Kwon, Shin, Park, Cho, Kim, & Hahn, 2020).

A radiomics model based on preoperative US images is presented by Liu et al. to predict lymph node metastasis in PTC patients. Fifty features are found to be more effective in predicting the status of lymph nodes after 450 US images are analyzed. With an accuracy of 0.712 and an area under the ROC curve of 0.782, the suggested model performs well. With 614 high-throughput features included, the radiomics evaluation shows promise in noninvasively determining the risk of PTC metastasis. The model predicts lymph node status in PTC patients based on preoperative US images, and its accuracy is consistent across validation and independent testing cohorts, demonstrating its potential to support early medical management and minimize overdiagnosis (Li et al., 2023).

Peng et al. introduced ThyNet, an AI model based on DL, to aid in the diagnosis and treatment of thyroid nodules. The study uses a dataset of 18,049 US images and involves 8,339 patients. The purpose of ThyNet is to differentiate between benign and malignant thyroid nodules in order to improve diagnostic precision and minimize needless FNAs. In this study, radiologists use ThyNet to assist in the diagnostic process. Radiologists alone perform the first independent review and diagnosis; their findings are then compared to the ThyNet reference diagnosis. Radiologists can choose to accept ThyNet's diagnosis or stick with their original diagnosis. The study documents both the final assisted diagnosis and the initial diagnosis. For the purpose of diagnosing thyroid nodules, the metric is the area under the receiver operating characteristic curve (AUROC). According to the study, ThyNet has much better accuracy and AUROC than radiologists alone. Both junior and senior radiologists perform better diagnoses with ThyNet's help. ThyNet also shows promise in lowering needless FNAs, which may have an effect on clinical decision-making. The study highlights how crucial it is to use AI diagnostic tools like ThyNet in clinical settings when managing thyroid nodules. The model's performance, as determined by AUROC and accuracy, suggests that it has the potential to be an important tool for enhancing the effectiveness and precision of thyroid nodule diagnosis, which

will ultimately improve patient care. ThyNet's efficacy in the real-world clinical setting is attributed to the particular DL architecture and methodology employed, including the training process on a large dataset and the integration of ThyNet with the ACR TIRADS classification (Peng et al., 2021).

Sharma et al. presented a thorough framework that makes use of DL, meta-heuristics, and multi-criteria decision-making (MCDM) algorithms to identify thyroid cancer. Using six feature transformation techniques to reduce dimensionality and three DL techniques for feature extraction, their framework integrates US and histopathological images for diagnosis. Using stratified cross-validation to evaluate five classifiers, they found a high-performing model based on PCA+FOX optimization-based feature. The framework aims to reduce the burden on medical professionals by enhancing the capabilities for diagnosing thyroid cancer. With the highest ranking Model 10 that incorporates PCA, random forest, and Swin Transformer, it achieves high accuracy, F2-score, and AUC-ROC score. The study highlights the value of early thyroid cancer detection and the help that machine learning models can provide to medical practitioners. Fortunately, the suggested framework improves patient care by outperforming current thyroid abnormality diagnostic techniques. The use of multiple imaging modalities, such as US, and the investigation of deep learning models, such as DeiT, Swin Transformer, and Mixer-MLP, for feature extraction are important components of their methodology. In addition, the novel FOX optimization algorithm for feature selection and ensemble learning was used, along with dimensionality reduction techniques such as PCA and ISOMAP. Though restricted by the availability of publicly available standard thyroid datasets, the framework shows promising results despite concentrating on two particular thyroid image datasets. The study emphasizes how crucial accuracy is for thyroid abnormalities when using computer-aided diagnosis (CAD) systems; the suggested framework exhibits high AUC-ROC scores on both US and histopathological datasets. One new development in the field is the use of the FOX optimization algorithm for feature selection and ensemble learning. But more research into ROI segmentation techniques and testing on more datasets might improve the suggested framework's resilience (Sharma et al., 2023).

Liu et al, conducted a study focusing on the prediction of lymph node metastasis in patients with PTC using a radiomics approach based on preoperative US images. After 450 US images were examined, 50 features were found to have better accuracy in predicting the status of lymph nodes. With a 0.712 accuracy and a 0.782 area under the ROC curve, the proposed model appears to be a promising noninvasive method for assessing metastasis risk. The study underlined the value of early medical management made possible by such predictive models and stressed the significance of radiomics evaluation in predicting lymph node status, particularly in patients with PTC. The method used a combined feature selection strategy, an SVM classifier for model building and validation, and

614 high-throughput features extracted from US images. The performance of the radiomics model was further assessed using independent testing cohorts, which showed how reliable it is at predicting the status of lymph nodes. Manual segmentation of tumors and a three-step feature selection method were employed to enhance the accuracy and reliability of the model. The study's findings contribute to the growing body of evidence supporting the utility of radiomics in noninvasive cancer prediction and management, particularly in high-incidence cancers like PTC (T. Liu et al., 2019).

In a retrospective study, Zhu et al. used machine learning techniques to create preoperative prediction models for evaluating lymph node metastasis (LNM) in thyroid cancer cases. The models combined clinical traits and ultrasonic radiomic features to help with diagnosis, predict recurrence, and guide treatment choices. With an accuracy of 0.7542 and an AUC of 0.812, the RF-RF model demonstrated the best predictive performance for cervical LNM among the five classifiers that were used. Notably, the most important factors influencing the effectiveness of the RF-RF model were found to be age and a variety of radiomic features. The study's results highlight the potential of ML and radiomics analysis in improving diagnostic accuracy and prognostic assessment, particularly in identifying cervical LNM, given the high rates of metastasis and recurrence associated with thyroid cancer. Using ultrasonic imaging techniques and 400 PTC nodules, the study included a validation group of 118 nodules that were chosen at random from the entire dataset. The superior performance of the RF-RF model was demonstrated by using Delong's test to compare its AUC with other models (Zhu et al., 2023).

Yu et al. presents a transfer learning radiomics (TLR) model for predicting lymph node metastasis (LNM) in PTC patients, achieving a stable LNM prediction with an average AUC of 0.90 across three datasets totaling 3,172 patients. Decision curve analysis shows that the TLR model performs better than other approaches, including DL models such as VGG, ResNet, and Inception ResNet, and benefits PTC patients more. This model offers a useful tool for preoperative LNM prediction by utilizing radiomics and transfer learning. It can be used to guide treatment decisions for PTC patients and improve diagnostic performance (Yu et al., 2020).

In this review, most studies utilized US images as the primary modality for radiomics analysis in thyroid cancers, reflecting its widespread availability and effectiveness in clinical practice. Reviewing radiomics in thyroid cancers, especially when combined with AI applications, reveals a wide range of results and approaches. On the other hand, a radiomics study that used US to predict BRAF mutation in thyroid nodules performed moderately well, with average accuracy, sensitivity, and specificity of 64.3%, 66.8%, On the other hand, a radiomics study with an average accuracy, sensitivity, and specificity of 64.3%, 66.8%, and 61.8%, respectively, demonstrated a moderate level of success in using US to predict BRAF mutation in thyroid nodules. and 61.8%, respectively. Notably, different

feature-selection strategies did not significantly improve test performance in this particular study. Furthermore, different classifiers performed differently in different studies, highlighting the variation in results (Kwon, Shin, Park, Cho, Hahn, & Park, 2020).

In contrast, some studies introduced novel approaches that demonstrated superior performance compared to existing literature. For instance, the application of a multi-layered classifier architecture, particularly utilizing RNN, exhibited high accuracy in comparison to traditional models (Göreke, 2023). Comparably, enhanced discrimination and clinical utility were demonstrated by the incorporation of artificial neural network-based US radiomics for forecasting large-volume lymph node metastasis in patients with papillary thyroid carcinoma (HajiEsmailPoor et al., 2023; Zhu et al., 2022). These results highlight how customized AI applications can improve the precision of diagnoses in particular clinical situations.

The high F1 scores that the PNN and SVM classifiers achieved in different test sets (Xia et al., 2021) showed how well AI algorithms combined with clinico-pathologic data could predict lymph node metastasis in cases of papillary thyroid carcinoma. This was the subject of another study. To fully realize the potential of the technology, a collaborative approach was suggested by emphasizing the need for a supervisory framework for AI applications that includes radiologists (Sorrenti et al., 2022). Moreover, given the variability of papillary thyroid carcinoma, the clinical-USR model outperforms a skilled sonographer in assessing central lymph node metastasis (Agyekum et al., 2022), highlighting the developing role of AI in improving diagnostic accuracy.

When comparing DL with radiomics-based methods, different results were also observed. DL consistently outperformed radiomics-based methods in terms of accuracy and AUC in predicting different parameters, including BRAF V600E mutations (Wang et al., 2020) and RET rearrangement (J. Yu et al., 2022). These findings imply that, for some diagnostic tasks, DL techniques may become more advantageous than traditional radiomics.

The literature also highlighted how radiomics is a flexible tool for predicting different aspects of thyroid cancers, including metastasis to central neck lymph nodes (Shi et al., 2022), distant metastasis in follicular thyroid cancer (Kwon, Shin, Park, Cho, Kim, & Hahn, 2020), and extrathyroidal extension (P. Yu et al., 2022). This versatile application demonstrates how radiomics can offer comprehensive insights into the features and prognosis of thyroid cancers.

In conclusion, there is a wide range of performance and utility levels in the literature on radiomics in thyroid cancers and AI applications. While some studies show encouraging outcomes and improvements in diagnostic accuracy, others draw attention to the necessity of carefully weighing the unique clinical context and cooperatively integrating AI into already-existing diagnostic frameworks (Li et al., 2020). The inconsistent results point to the

significance of individualized strategies and ongoing improvement in the use of AI and radiomics for thyroid cancer prognosis and diagnosis.

## **7. Staging**

Based on publication of the eighth edition of the American Joint Committee on Cancer (AJCC)/Union for International Cancer Control (UICC) in 2016, changes were made to the staging system for thyroid cancer (Amin et al., 2017). Remarkably, age was taken into consideration; the age cutoff was 55 instead of 45. Significant downstaging of tumor classifications resulted from the revisions; 38% of patients had their tumor classifications downstaged, and the percentage of patients classified as Stage I or II increased from 64% to 94%. These modifications provided a more accurate prognosis by better aligning staging with disease-specific survival. The American Thyroid Association's (ATA) risk stratification system and AJCC staging together enhanced the prediction of disease-specific survival (Thewjitcharoen et al., 2021).

Detectable thyroid nodules are present in only 30–40% of thyroid cancer instances, rendering them a secondary diagnostic preference. Essential for identifying thyroid nodules are imaging techniques like cross-sectional and ultrasound imaging (Bonjoc et al., 2020). However, the concern of overdiagnosis underscores the importance of exercising prudence and adhering to evidence-based guidelines discouraging screening for asymptomatic individuals. Ultrasound emerges as the favored imaging modality for evaluating nodule characteristics, though its application requires circumspection to prevent misdiagnoses. Presently, fine needle aspiration (FNA) remains a dependable diagnostic approach, particularly when coupled with risk assessment tools (Fresilli et al., 2021). Molecular diagnostic methodologies, exemplified by ThyroSeq v3 and Afirma, have mitigated the necessity for diagnostic lobectomy in cases of indeterminate nodules. Striking a judicious balance between early detection and the risk of overdiagnosis persists as a formidable challenge confronting medical practitioners (Khan & Zeiger, 2020).

## **8. Challenges, Limitations and Future Directions**

Obstacles and restrictions in the use of radiomics and AI in the detection and prognosis of thyroid cancer. A persistent issue pertains to the dependence on operator expertise and specimen gathering, which may introduce errors in production, underscoring the necessity of standardization and careful handling (H. Zhou et al., 2020).

There are inherent limitations with US-based radiomics, especially in predicting the status of BRAF mutations. These include operator dependence, difficulties with quantitative analysis, and the need for larger datasets to improve the efficacy of particular features (Kwon, Shin, Park, Cho, Hahn, & Park, 2020). In order to achieve more reliable and broadly applicable results, prospective multicenter approaches to validation are crucial, as evidenced by the retrospective nature of certain studies and the uneven distribution of data (Zhu et al., 2022).

One major issue that arises is the interpretability of AI models, since classifiers are "black boxes," making it difficult to understand the causal relationships between them. Variations in tumor microenvironments and imaging protocols make generalizing models even more difficult, highlighting the necessity of fully comprehending the underlying concepts and incorporating clinical data (Cao et al., 2021; S. C. Zhou et al., 2020). Even with their promising performance, AI systems perform on par with or worse than experienced ultrasonography specialists, highlighting the necessity of a supervisory structure for radiologists as of right now (Sorrenti et al., 2022).

Problems with the dataset include small sample sizes, single-center designs, and low diversity, which emphasizes the significance of using multi-modal, multi-center data for thorough validation (Kwon, Shin, Park, Cho, Kim, & Hahn, 2020; Y. G. Wang et al., 2022; Wu et al., 2022; J. Yu et al., 2022). Different imaging modalities, like [18F]FDG-PET/CT, present difficulties for radiomics methodology due to limited specificity and difficult differentiation (de Koster et al., 2022).

As seen by the difficulties in US radiomics, a common theme in radiomics models is a lack of standardization. It will take work to standardize the field, cut down on mistakes, and improve US radiomics' applicability in a variety of clinical contexts (Kwon, Shin, Park, Cho, Kim, & Hahn, 2020). The necessity for additional validation in prospective datasets, with careful consideration of potential biases, is highlighted by retrospective study designs (Lu et al., 2019).

The difficulties in making clinical decisions like the erratic US physicians' rating skills and the lack of certainty in cytopathological diagnosis—highlight how difficult it is to incorporate these technologies into real-world medical settings (Peng et al., 2021). Additionally, limitations in the knowledge base for head and neck diseases, coupled with a scarcity of studies on radiomics in certain thyroid cancers, the need for comprehensive research in these areas (Gul et al., 2021).

To overcome the challenges and limitations in the application of radiomics and AI for thyroid cancer detection and prognosis, concerted efforts and innovative solutions will be required. Standardization efforts are essential for enhancing reliability and repeatability in a range of clinical settings, and multimodal data integration presents the possibility of developing comprehensive predictive models. Advancements in explainable AI



technology have the potential to improve the interpretability of machine learning models, thereby simplifying their integration into clinical environments. Prospective multicenter studies with larger datasets are necessary to validate the efficacy and generalizability of radiomics models, and personalized medicine approaches can customize treatment regimens to the specific features of individual tumors. The creation of clinical decision support systems and funding for training and education programs for medical professionals are crucial for the widespread adoption and application of radiomics-based approaches. By embracing these new directions, the field will be able to advance and enhance patient outcomes in the treatment of thyroid cancer by facilitating more accurate diagnosis and customized treatment.

## 9. Conclusion

This review presents a landscape of changing approaches and results from a thorough analysis of the literature on the use of AI and radiomics in thyroid cancer diagnosis and prognosis. Due to its widespread availability and efficacy in clinical practice, US images have been the primary modality for radiomics analysis in the majority of studies in this domain. Notably, combining computational power with state-of-the-art imaging techniques has shown promise in improving accuracy, effectiveness, and customized patient care. Numerous approaches and methodologies have been used in the reviewed studies, producing a wide range of outcomes and results. While some research has presented innovative techniques that outperform conventional approaches, other studies have emphasized the difficulties and restrictions that come with using AI and radiomics to diagnose thyroid cancer. Research employing multi-layered classifier architectures, specifically with RNN, has demonstrated superior accuracy in certain clinical situations. Furthermore, integrating artificial neural network-based US radiomics has demonstrated potential in predicting parameters like large-volume lymph node metastasis in papillary thyroid cancer patients. But problems like operator dependence, AI model interpretability problems, dataset limitations, and the ongoing need for standardization efforts still exist. Furthermore, variations in performance and outcomes amongst studies highlight the necessity of additional methodology validation and improvement. Different results have been observed when comparing radiomics-based methods, with DL consistently outperforming radiomics-based methods in some diagnostic tasks. This implies that in some situations, DL techniques might be more advantageous than traditional radiomics. Despite the variability in results and performance levels observed in the literature, radiomics appears to be a flexible tool capable of predicting various aspects of thyroid cancers, including metastasis to central neck lymph nodes, distant metastasis in follicular thyroid cancer, and extrathyroidal extension. This adaptability emphasizes radiomics' potential to

provide thorough insights into the characteristics and prognosis of thyroid cancers. In conclusion, there is considerable potential for these technologies to transform thyroid cancer diagnosis and prognosis, even though the literature on radiomics in thyroid cancers and AI applications shows a wide range of performance and utility levels. However, coordinated efforts in standardization, validation, and integration into clinical practice will be necessary to realize this potential. By taking on obstacles and utilizing creative solutions, the field can progress toward better patient outcomes and a more thorough comprehension of the pathophysiology of thyroid cancer.

## **Declaration**

### **Ethics approval and consent to participate:**

This study was conducted under the principles outlined in the Declaration of Helsinki.

### **Consent for publication**

N/A

### **Availability of data**

N/A

### **Competing interests**

The authors declare that there is no conflict of interest.

### **Funding Sources**

None.

### **CRedit Statement**

**Conceptualization:** AJz **Data curation:** AJz, MY, SFM, MAY, and AJ **Investigation:** MY, SFM, MAY, AJ, and AJz **Supervision:** SP, PP, RT, RAS, and AJz **Visualization:** MY **Writing – original draft:** AJ, MY, SFM, MAY, and AJz **Writing – review & editing:** SP, PP, RT, RAS, and AJz **Project administration:** AJz

It should be noted that AJz and RAS are co-corresponding authors of this manuscript.

## **Acknowledgments**

None.

## References

- Abdollahi, M., Jafarizadeh, A., Asbagh, A. G., Sobhi, N., Pourmoghtader, K., Pedrammehr, S., Aasdi, H., Tan, R. S., & Acharya, U. R. (2023). Artificial Intelligence in Assessing Cardiovascular Diseases and Risk Factors via Retinal Fundus Images: A Review of the Last Decade. arXiv preprint arXiv:2311.07609. <https://doi.org/10.48550/arXiv.2311.07609>
- Abdollahi, M., Nateghian, H., Sobhi, N., Abdshah, A., & Jafarizadeh, A. (2024). Uveal metastasis arising from thyroid neoplasms: A case study synthesis. *European Journal of Ophthalmology*, 11206721241236528. <https://doi.org/10.1177/11206721241236528>
- Agyekum, E. A., Ren, Y. Z., Wang, X., Cranston, S. S., Wang, Y. G., Wang, J., Akortia, D., Xu, F. J., Gomashie, L., Zhang, Q., Zhang, D., & Qian, X. (2022). Evaluation of Cervical Lymph Node Metastasis in Papillary Thyroid Carcinoma Using Clinical-Ultrasound Radiomic Machine Learning-Based Model. *Cancers (Basel)*, 14(21). <https://doi.org/10.3390/cancers14215266>
- Alghamedy, F. H., Shafiq, M., Liu, L., Yasin, A., Khan, R. A., & Mohammed, H. S. (2022). Machine Learning-Based Multimodel Computing for Medical Imaging for Classification and Detection of Alzheimer Disease. *Comput Intell Neurosci*, 2022, 9211477. <https://doi.org/10.1155/2022/9211477>
- Alowais, S. A., Alghamdi, S. S., Alsuhebany, N., Alqahtani, T., Alshaya, A. I., Almohareb, S. N., Aldairem, A., Alrashed, M., Bin Saleh, K., Badreldin, H. A., Al Yami, M. S., Al Harbi, S., & Albekairy, A. M. (2023). Revolutionizing healthcare: the role of artificial intelligence in clinical practice. *BMC Medical Education*, 23(1), 689. <https://doi.org/10.1186/s12909-023-04698-z>
- Alqazzaz, S., Sun, X., Nokes, L. D. M., Yang, H., Yang, Y., Xu, R., Zhang, Y., & Yang, X. (2022). Combined Features in Region of Interest for Brain Tumor Segmentation. *Journal of Digital Imaging*, 35(4), 938-946. <https://doi.org/10.1007/s10278-022-00602-1>
- AlSaedi, A. H., Almalki, D. S., & ElKady, R. M. (2024). Approach to Thyroid Nodules: Diagnosis and Treatment. *Cureus*, 16(1), e52232. <https://doi.org/10.7759/cureus.52232>
- Amin, M. B., Greene, F. L., Edge, S. B., Compton, C. C., Gershenwald, J. E., Brookland, R. K., Meyer, L., Gress, D. M., Byrd, D. R., & Winchester, D. P. (2017). The Eighth Edition AJCC Cancer Staging Manual: Continuing to build a bridge from a population-based to a more “personalized” approach to cancer staging. *CA: A Cancer Journal for Clinicians*, 67(2), 93-99. <https://doi.org/https://doi.org/10.3322/caac.21388>
- Asa, S. L. (2004). My approach to oncocytic tumours of the thyroid. *J Clin Pathol*, 57(3), 225-232. <https://doi.org/10.1136/jcp.2003.008474>
- Ashayeri, H., Jafarizadeh, A., Yousefi, M., Farhadi, F., & Javadzadeh, A. (2024). Retinal imaging and Alzheimer’s disease: a future powered by Artificial Intelligence. *Graefe’s Archive for Clinical and Experimental Ophthalmology*, 1-13. <https://doi.org/10.1007/s00417-024-06394-0>
- Badillo, S., Banfai, B., Birzele, F., Davydov, II, Hutchinson, L., Kam-Thong, T., Siebourg-Polster, J., Steiert, B., & Zhang, J. D. (2020). An Introduction to Machine Learning. *Clin Pharmacol Ther*, 107(4), 871-885. <https://doi.org/10.1002/cpt.1796>
- Baloch, Z. W., & LiVolsi, V. A. (2007). Our approach to follicular-patterned lesions of the thyroid. *J Clin Pathol*, 60(3), 244-250. <https://doi.org/10.1136/jcp.2006.038604>
- Bazargani, Y. S., Mirzaei, M., Sobhi, N., Abdollahi, M., Jafarizadeh, A., Pedrammehr, S., Alizadehsani, R., Tan, R. S., Islam, S. M. S., & Acharya, U. R. (2024). Artificial Intelligence and Diabetes Mellitus: An Inside Look Through the Retina. arXiv preprint arXiv:2402.18600. <https://doi.org/10.48550/arXiv.2402.18600>
- Benesch, M. G. K., & O’Brien, S. B. L. (2022). Epidemiology of Undifferentiated Carcinomas. *Cancers (Basel)*, 14(23). <https://doi.org/10.3390/cancers14235819>
- Bi, W. L., Hosny, A., Schabath, M. B., Giger, M. L., Birkbak, N. J., Mehrtash, A., Allison, T., Arnaout, O., Abbosh, C., Dunn, I. F., Mak, R. H., Tamimi, R. M., Tempny, C. M., Swanton, C., Hoffmann, U.,

- Schwartz, L. H., Gillies, R. J., Huang, R. Y., & Aerts, H. (2019). Artificial intelligence in cancer imaging: Clinical challenges and applications. *CA Cancer J Clin*, 69(2), 127-157. <https://doi.org/10.3322/caac.21552>
- Bini, F., Pica, A., Azzimonti, L., Giusti, A., Ruinelli, L., Marinozzi, F., & Trimboli, P. (2021). Artificial Intelligence in Thyroid Field—A Comprehensive Review. *Cancers*, 13(19), 4740. <https://www.mdpi.com/2072-6694/13/19/4740>
- Bonjoc, K.-J., Young, H., Warner, S., Gemon, T., Maghami, E., & Chaudhry, A. (2020). Thyroid cancer diagnosis in the era of precision imaging. *Journal of Thoracic Disease*, 12(9), 5128-5139. <https://jtd.amegroups.org/article/view/36169>
- Brauckhoff, K., & Biermann, M. (2020). Multimodal imaging of thyroid cancer. *Current Opinion in Endocrinology, Diabetes and Obesity*, 27(5), 335-344. <https://doi.org/10.1097/med.0000000000000574>
- Burt, J. R., Torosdagli, N., Khosravan, N., RaviPrakash, H., Mortazi, A., Tissavirasingham, F., Hussein, S., & Bagci, U. (2018). Deep learning beyond cats and dogs: recent advances in diagnosing breast cancer with deep neural networks. *The British journal of radiology*, 91(1089), 20170545. <https://doi.org/10.1259/bjr.20170545>
- Cao, Y., Zhong, X., Diao, W., Mu, J., Cheng, Y., & Jia, Z. (2021). Radiomics in Differentiated Thyroid Cancer and Nodules: Explorations, Application, and Limitations. *Cancers*, 13(10), 2436. <https://www.mdpi.com/2072-6694/13/10/2436>
- Chen, M., Copley, S. J., Viola, P., Lu, H., & Aboagye, E. O. (2023). Radiomics and artificial intelligence for precision medicine in lung cancer treatment. *Semin Cancer Biol*, 93, 97-113. <https://doi.org/10.1016/j.semcancer.2023.05.004>
- Chicklore, S., Goh, V., Siddique, M., Roy, A., Marsden, P. K., & Cook, G. J. (2013). Quantifying tumour heterogeneity in 18F-FDG PET/CT imaging by texture analysis. *Eur J Nucl Med Mol Imaging*, 40(1), 133-140. <https://doi.org/10.1007/s00259-012-2247-0>
- Cochand-Priollet, B., & Maleki, Z. (2023). Cytology and Histology of Thyroid Nodules: Exploring Novel Insights in the Molecular Era for Enhanced Patient Management. *Curr Oncol*, 30(8), 7753-7772. <https://doi.org/10.3390/curroncol30080562>
- Concepción Zavaleta, M. J., Ildefonso Najarro, S. P., Plasencia Dueñas, E. A., Quispe Flores, M. A., Moreno Marreros, D. M., Concepción Urteaga, L. A., Luna Victorio, L. E., & Fernández Dávila, F. V. (2021). New-onset thyrotoxicosis in a patient with anaplastic thyroid carcinoma: a diagnostic challenge. *Endocrinol Diabetes Metab Case Rep*, 2021. <https://doi.org/10.1530/edm-21-0053>
- Cook, G. J. R., Siddique, M., Taylor, B. P., Yip, C., Chicklore, S., & Goh, V. (2014). Radiomics in PET: principles and applications. *Clinical and Translational Imaging*, 2(3), 269-276. <https://doi.org/10.1007/s40336-014-0064-0>
- Dai, Z., Wei, R., Wang, H., Hu, W., Sun, X., Zhu, J., Li, H., Ge, Y., & Song, B. (2022). Multimodality MRI-based radiomics for aggressiveness prediction in papillary thyroid cancer. *BMC Medical Imaging*, 22(1), 54. <https://doi.org/10.1186/s12880-022-00779-5>
- Dargan, S., Kumar, M., Ayyagari, M. R., & Kumar, G. (2020). A Survey of Deep Learning and Its Applications: A New Paradigm to Machine Learning. *Archives of Computational Methods in Engineering*, 27(4), 1071-1092. <https://doi.org/10.1007/s11831-019-09344-w>
- Davenport, T., & Kalakota, R. (2019). The potential for artificial intelligence in healthcare. *Future Healthc J*, 6(2), 94-98. <https://doi.org/10.7861/futurehosp.6-2-94>
- de Koster, E. J., Noortman, W. A., Mostert, J. M., Booij, J., Brouwer, C. B., de Keizer, B., de Klerk, J. M. H., Oyen, W. J. G., van Velden, F. H. P., de Geus-Oei, L.-F., Vriens, D., & for the Ef, F. t. s. g. (2022). Quantitative classification and radiomics of [18F]FDG-PET/CT in indeterminate thyroid nodules. *European Journal of Nuclear Medicine and Molecular Imaging*, 49(7), 2174-2188. <https://doi.org/10.1007/s00259-022-05712-0>
- Dondi, F., Gatta, R., Treglia, G., Piccardo, A., Albano, D., Camoni, L., Gatta, E., Cavadini, M., Cappelli, C., & Bertagna, F. (2024). Application of radiomics and machine learning to thyroid diseases in nuclear medicine: a systematic review. *Reviews in Endocrine and Metabolic Disorders*, 25(1), 175-186. <https://doi.org/10.1007/s11154-023-09822-4>
- Dougherty, E. R., Hua, J., & Sima, C. (2009). Performance of feature selection methods. *Curr Genomics*, 10(6), 365-374. <https://doi.org/10.2174/138920209789177629>

- Edwards, K., Halicek, M., Little, J. V., Chen, A. Y., & Fei, B. (2021). Multiparametric Radiomics for Predicting the Aggressiveness of Papillary Thyroid Carcinoma Using Hyperspectral Images. *Proc SPIE Int Soc Opt Eng*, 11597. <https://doi.org/10.1117/12.2582147>
- Elahi, M., Afolaranmi, S. O., Martinez Lastra, J. L., & Perez Garcia, J. A. (2023). A comprehensive literature review of the applications of AI techniques through the lifecycle of industrial equipment. *Discover Artificial Intelligence*, 3(1), 43. <https://doi.org/10.1007/s44163-023-00089-x>
- Elhassan, M. M. A., Gismalla, M. D. A., Mohamed, S. A. H., & Faggad, A. (2023). Clinicopathological profile and management of thyroid carcinoma: a Sub-Saharan country experience. *Thyroid Research*, 16(1), 35. <https://doi.org/10.1186/s13044-023-00173-5>
- Farabi Maleki, S., Yousefi, M., Afshar, S., Pedrammehr, S., Lim, C. P., Jafarizadeh, A., & Asadi, H. (2023). Artificial Intelligence for Multiple Sclerosis Management Using Retinal Images: Pearl, Peaks, and Pitfalls. *Semin Ophthalmol*, 1-18. <https://doi.org/10.1080/08820538.2023.2293030>
- Ferlay, J., Ervik, M., Lam, F., Colombet, M., Mery, L., Piñeros, M., Znaor, A., Soerjomataram, I., & Bray, F. (2024). Global Cancer Observatory: Cancer Today (version 1.1). *Lyon, France: international agency for research on cancer*. Available from: <https://gco.iarc.who.int/today>, accessed [14 March 2024]
- Fresilli, D., David, E., Pacini, P., Del Gaudio, G., Dolcetti, V., Lucarelli, G. T., Di Leo, N., Bellini, M. I., #039, Andrea, V., Sorrenti, S., Mascagni, D., Biffoni, M., Durante, C., Grani, G., De Vincentis, G., & Cantisani, V. (2021). Thyroid Nodule Characterization: How to Assess the Malignancy Risk. Update of the Literature. *Diagnostics*, 11(8), 1374. <https://www.mdpi.com/2075-4418/11/8/1374>
- Gao, X., Ran, X., & Ding, W. (2023). The progress of radiomics in thyroid nodules. *Front Oncol*, 13, 1109319. <https://doi.org/10.3389/fonc.2023.1109319>
- Gillies, R. J., Kinahan, P. E., & Hricak, H. (2016). Radiomics: Images Are More than Pictures, They Are Data. *Radiology*, 278(2), 563-577. <https://doi.org/10.1148/radiol.2015151169>
- Göreke, V. (2023). A Novel Deep-Learning-Based CADx Architecture for Classification of Thyroid Nodules Using Ultrasound Images. *Interdiscip Sci*, 15(3), 360-373. <https://doi.org/10.1007/s12539-023-00560-4>
- Greener, J. G., Kandathil, S. M., Moffat, L., & Jones, D. T. (2022). A guide to machine learning for biologists. *Nat Rev Mol Cell Biol*, 23(1), 40-55. <https://doi.org/10.1038/s41580-021-00407-0>
- Gu, J., Zhu, J., Qiu, Q., Wang, Y., Bai, T., & Yin, Y. (2019). Prediction of Immunohistochemistry of Suspected Thyroid Nodules by Use of Machine Learning-Based Radiomics. *AJR Am J Roentgenol*, 213(6), 1348-1357. <https://doi.org/10.2214/ajr.19.21626>
- Gu, J., Zhu, J., Qiu, Q., Wang, Y., Bai, T., & Yin, Y. (2019). Prediction of Immunohistochemistry of Suspected Thyroid Nodules by Use of Machine Learning-Based Radiomics. *American Journal of Roentgenology*, 213(6), 1348-1357. <https://doi.org/10.2214/ajr.19.21626>
- Gul, M., Bonjoc, K. C., Gorlin, D., Wong, C. W., Salem, A., La, V., Filippov, A., Chaudhry, A., Imam, M. H., & Chaudhry, A. A. (2021). Diagnostic Utility of Radiomics in Thyroid and Head and Neck Cancers. *Front Oncol*, 11, 639326. <https://doi.org/10.3389/fonc.2021.639326>
- Gupta, N. S., & Kumar, P. (2023). Perspective of artificial intelligence in healthcare data management: A journey towards precision medicine. *Comput Biol Med*, 162, 107051. <https://doi.org/10.1016/j.compbiomed.2023.107051>
- Ha, R., Chang, P., Karcich, J., Mutasa, S., Fardanesh, R., Wynn, R. T., Liu, M. Z., & Jambawalikar, S. (2018). Axillary Lymph Node Evaluation Utilizing Convolutional Neural Networks Using MRI Dataset. *J Digit Imaging*, 31(6), 851-856. <https://doi.org/10.1007/s10278-018-0086-7>
- Habchi, Y., Himeur, Y., Kheddar, H., Boukabou, A., Atalla, S., Chouchane, A., Ouamane, A., & Mansoor, W. (2023). AI in Thyroid Cancer Diagnosis: Techniques, Trends, and Future Directions. *Systems*, 11(10), 519. <https://www.mdpi.com/2079-8954/11/10/519>
- Habeheh, H., & Gohel, S. (2021). Machine Learning in Healthcare. *Curr Genomics*, 22(4), 291-300. <https://doi.org/10.2174/1389202922666210705124359>
- HajiEsmailPoor, Z., Kargar, Z., & Tabnak, P. (2023). Radiomics diagnostic performance in predicting lymph node metastasis of papillary thyroid carcinoma: A systematic review and meta-analysis. *European Journal of Radiology*, 168, 111129. <https://doi.org/10.1016/j.ejrad.2023.111129>



- Hao, X., Yin, L., Li, X., Zhang, L., & Yang, R. (2023). A Multi-Objective Semantic Segmentation Algorithm Based on Improved U-Net Networks. *Remote Sensing*, 15(7), 1838. <https://www.mdpi.com/2072-4292/15/7/1838>
- Hershman, M., Yousefi, B., Serletti, L., Galperin-Aizenberg, M., Roshkovan, L., Luna, J. M., Thompson, J. C., Aggarwal, C., Carpenter, E. L., Kontos, D., & Katz, S. I. (2021). Impact of Interobserver Variability in Manual Segmentation of Non-Small Cell Lung Cancer (NSCLC) Applying Low-Rank Radiomic Representation on Computed Tomography. *Cancers (Basel)*, 13(23). <https://doi.org/10.3390/cancers13235985>
- Hu, J., Yuan, I. J., Mirshahidi, S., Simental, A., Lee, S. C., & Yuan, X. (2021). Thyroid Carcinoma: Phenotypic Features, Underlying Biology and Potential Relevance for Targeting Therapy. *Int J Mol Sci*, 22(4). <https://doi.org/10.3390/ijms22041950>
- Hussain, S., Mubeen, I., Ullah, N., Shah, S., Khan, B. A., Zahoor, M., Ullah, R., Khan, F. A., & Sultan, M. A. (2022). Modern Diagnostic Imaging Technique Applications and Risk Factors in the Medical Field: A Review. *Biomed Res Int*, 2022, 5164970. <https://doi.org/10.1155/2022/5164970>
- Jafarizadeh, A., Maleki, S. F., Pouya, P., Sobhi, N., Abdollahi, M., Pedrammehr, S., Lim, C. P., Asadi, H., Alizadehsani, R., Tan, R. S., Islam, S. M. S., & Acharya, U. R. (2024). Current and future roles of artificial intelligence in retinopathy of prematurity. arXiv preprint arXiv:2402.09975. <https://doi.org/10.48550/arXiv.2402.09975>
- Janiesch, C., Zschech, P., & Heinrich, K. (2021). Machine learning and deep learning. *Electronic Markets*, 31(3), 685-695. <https://doi.org/10.1007/s12525-021-00475-2>
- Jiang, M., Li, C.-L., Luo, X.-M., Chuan, Z.-R., Chen, R.-X., Tang, S.-C., Lv, W.-Z., Cui, X.-W., & Dietrich, C. F. (2022). Radiomics model based on shear-wave elastography in the assessment of axillary lymph node status in early-stage breast cancer. *European Radiology*, 32(4), 2313-2325. <https://doi.org/10.1007/s00330-021-08330-w>
- Kahn, C., Simonella, L., Sywak, M., Boyages, S., Ung, O., & O'Connell, D. (2012). Pathways to the diagnosis of thyroid cancer in New South Wales: a population-based cross-sectional study. *Cancer Causes Control*, 23(1), 35-44. <https://doi.org/10.1007/s10552-011-9852-2>
- Khan, T. M., & Zeiger, M. A. (2020). Thyroid Nodule Molecular Testing: Is It Ready for Prime Time? *Front Endocrinol (Lausanne)*, 11, 590128. <https://doi.org/10.3389/fendo.2020.590128>
- Kumar, V., Gu, Y., Basu, S., Berglund, A., Eschrich, S. A., Schabath, M. B., Forster, K., Aerts, H. J., Dekker, A., Fenstermacher, D., Goldgof, D. B., Hall, L. O., Lambin, P., Balagurunathan, Y., Gatenby, R. A., & Gillies, R. J. (2012). Radiomics: the process and the challenges. *Magn Reson Imaging*, 30(9), 1234-1248. <https://doi.org/10.1016/j.mri.2012.06.010>
- Kunapinun, A., Songsaeng, D., Buathong, S., Dailey, M. N., Keatmanee, C., & Ekpanyapong, M. (2023). Explainable Automated TI-RADS Evaluation of Thyroid Nodules. *Sensors*, 23(16), 7289. <https://www.mdpi.com/1424-8220/23/16/7289>
- Kwon, M. R., Shin, J. H., Park, H., Cho, H., Hahn, S. Y., & Park, K. W. (2020). Radiomics Study of Thyroid Ultrasound for Predicting BRAF Mutation in Papillary Thyroid Carcinoma: Preliminary Results. *AJNR Am J Neuroradiol*, 41(4), 700-705. <https://doi.org/10.3174/ajnr.A6505>
- Kwon, M. R., Shin, J. H., Park, H., Cho, H., Kim, E., & Hahn, S. Y. (2020). Radiomics Based on Thyroid Ultrasound Can Predict Distant Metastasis of Follicular Thyroid Carcinoma. *J Clin Med*, 9(7). <https://doi.org/10.3390/jcm9072156>
- Lambin, P., Rios-Velazquez, E., Leijenaar, R., Carvalho, S., van Stiphout, R. G., Granton, P., Zegers, C. M., Gillies, R., Boellard, R., Dekker, A., & Aerts, H. J. (2012). Radiomics: extracting more information from medical images using advanced feature analysis. *Eur J Cancer*, 48(4), 441-446. <https://doi.org/10.1016/j.ejca.2011.11.036>
- LeCun, Y., Bengio, Y., & Hinton, G. (2015). Deep learning. *Nature*, 521(7553), 436-444. <https://doi.org/10.1038/nature14539>
- Lee, K. S., & Park, H. (2022). Machine learning on thyroid disease: a review. *Front Biosci (Landmark Ed)*, 27(3), 101. <https://doi.org/10.31083/j.fbl2703101>
- Li, J., Wu, X., Mao, N., Zheng, G., Zhang, H., Mou, Y., Jia, C., Mi, J., & Song, X. (2021). Computed Tomography-Based Radiomics Model to Predict Central Cervical Lymph Node Metastases in Papillary Thyroid Carcinoma: A Multicenter Study. *Front Endocrinol (Lausanne)*, 12, 741698. <https://doi.org/10.3389/fendo.2021.741698>

- Li, J., Xia, F., Wang, X., Jin, Y., Yan, J., Wei, X., & Zhao, Q. (2023). Multiclassifier Radiomics Analysis of Ultrasound for Prediction of Extrathyroidal Extension in Papillary Thyroid Carcinoma in Children. *Int J Med Sci*, 20(2), 278-286. <https://doi.org/10.7150/ijms.79758>
- Li, L. R., Du, B., Liu, H. Q., & Chen, C. (2020). Artificial Intelligence for Personalized Medicine in Thyroid Cancer: Current Status and Future Perspectives. *Front Oncol*, 10, 604051. <https://doi.org/10.3389/fonc.2020.604051>
- Liu, T., Zhou, S., Yu, J., Guo, Y., Wang, Y., Zhou, J., & Chang, C. (2019). Prediction of Lymph Node Metastasis in Patients With Papillary Thyroid Carcinoma: A Radiomics Method Based on Preoperative Ultrasound Images. *Technol Cancer Res Treat*, 18, 1533033819831713. <https://doi.org/10.1177/1533033819831713>
- Liu, Z., Wang, S., Dong, D., Wei, J., Fang, C., Zhou, X., Sun, K., Li, L., Li, B., Wang, M., & Tian, J. (2019). The Applications of Radiomics in Precision Diagnosis and Treatment of Oncology: Opportunities and Challenges. *Theranostics*, 9(5), 1303-1322. <https://doi.org/10.7150/thno.30309>
- Lu, W., Zhong, L., Dong, D., Fang, M., Dai, Q., Leng, S., Zhang, L., Sun, W., Tian, J., Zheng, J., & Jin, Y. (2019). Radiomic analysis for preoperative prediction of cervical lymph node metastasis in patients with papillary thyroid carcinoma. *Eur J Radiol*, 118, 231-238. <https://doi.org/10.1016/j.ejrad.2019.07.018>
- Lucas, A. M., Ryder, P. V., Li, B., Cimini, B. A., Eliceiri, K. W., & Carpenter, A. E. (2021). Open-source deep-learning software for bioimage segmentation. *Molecular Biology of the Cell*, 32(9), 823-829. <https://doi.org/10.1091/mbc.E20-10-0660>
- McHenry, C. R., & Phitayakorn, R. (2011). Follicular adenoma and carcinoma of the thyroid gland. *Oncologist*, 16(5), 585-593. <https://doi.org/10.1634/theoncologist.2010-0405>
- Najafabadi, M. M., Villanustre, F., Khoshgoftaar, T. M., Seliya, N., Wald, R., & Muharemagic, E. (2015). Deep learning applications and challenges in big data analytics. *Journal of Big Data*, 2(1), 1. <https://doi.org/10.1186/s40537-014-0007-7>
- Najjar, R. (2023). Redefining Radiology: A Review of Artificial Intelligence Integration in Medical Imaging. *Diagnostics*, 13(17), 2760. <https://www.mdpi.com/2075-4418/13/17/2760>
- Neocleous, V., Fanis, P., Frangos, S., Skordis, N., & Phylactou, L. A. (2023). RET Proto-Oncogene Variants in Patients with Medullary Thyroid Carcinoma from the Mediterranean Basin: A Brief Report. *Life (Basel)*, 13(6). <https://doi.org/10.3390/life13061332>
- Nguyen, T., Nguyen, N. D., & Nahavandi, S. (2020). Deep Reinforcement Learning for Multiagent Systems: A Review of Challenges, Solutions, and Applications. *IEEE Transactions on Cybernetics*, PP, 1-14. <https://doi.org/10.1109/TCYB.2020.2977374>
- Oliveira, R. A. d., & Bollen, M. H. J. (2023). Deep learning for power quality. *Electric Power Systems Research*, 214, 108887. <https://doi.org/https://doi.org/10.1016/j.epr.2022.108887>
- Parekh, V., & Jacobs, M. A. (2016). Radiomics: a new application from established techniques. *Expert Rev Precis Med Drug Dev*, 1(2), 207-226. <https://doi.org/10.1080/23808993.2016.1164013>
- Parekh, V. S., & Jacobs, M. A. (2017). Integrated radiomic framework for breast cancer and tumor biology using advanced machine learning and multiparametric MRI. *NPJ Breast Cancer*, 3, 43. <https://doi.org/10.1038/s41523-017-0045-3>
- Peng, S., Liu, Y., Lv, W., Liu, L., Zhou, Q., Yang, H., Ren, J., Liu, G., Wang, X., Zhang, X., Du, Q., Nie, F., Huang, G., Guo, Y., Li, J., Liang, J., Hu, H., Xiao, H., Liu, Z., . . . Xiao, H. (2021). Deep learning-based artificial intelligence model to assist thyroid nodule diagnosis and management: a multicentre diagnostic study. *The Lancet. Digital health*, 3(4), e250-e259. [https://doi.org/10.1016/s2589-7500\(21\)00041-8](https://doi.org/10.1016/s2589-7500(21)00041-8)
- Pinto-Coelho, L. (2023). How Artificial Intelligence Is Shaping Medical Imaging Technology: A Survey of Innovations and Applications. *Bioengineering (Basel)*, 10(12). <https://doi.org/10.3390/bioengineering10121435>
- Rahman, S. T., McLeod, D. S. A., Pandeya, N., Neale, R. E., Bain, C. J., Baade, P., Youl, P. H., & Jordan, S. J. (2019). Understanding Pathways to the Diagnosis of Thyroid Cancer: Are There Ways We Can Reduce Over-Diagnosis? *Thyroid*, 29(3), 341-348. <https://doi.org/10.1089/thy.2018.0570>
- Rogers, W., Thulasi Seetha, S., Refaee, T. A. G., Lieverse, R. I. Y., Granzier, R. W. Y., Ibrahim, A., Keek, S. A., Sanduleanu, S., Primakov, S. P., Beuque, M. P. L., Marcus, D., van der Wiel, A. M. A., Zerka, F., Oberije, C. J. G., van Timmeren, J. E., Woodruff, H. C., & Lambin, P. (2020). Radiomics:

- from qualitative to quantitative imaging. *The British journal of radiology*, 93(1108), 20190948. <https://doi.org/10.1259/bjr.20190948>
- Sajisevi, M., Caulley, L., Eskander, A., Du, Y. J., Auh, E., Karabachev, A., Callas, P., Conradie, W., Martin, L., Pasternak, J., Golbon, B., Rolighed, L., Abdelhamid Ahmed, A. H., Badhey, A., Cheung, A. Y., Corsten, M., Forner, D., Liu, J. C., Mavedatnia, D., . . . Davies, L. (2022). Evaluating the Rising Incidence of Thyroid Cancer and Thyroid Nodule Detection Modes: A Multinational, Multi-institutional Analysis. *JAMA Otolaryngol Head Neck Surg*, 148(9), 811-818. <https://doi.org/10.1001/jamaoto.2022.1743>
- Satheeshkumar, P. S., El-Dallal, M., & Mohan, M. P. (2021). Feature selection and predicting chemotherapy-induced ulcerative mucositis using machine learning methods. *Int J Med Inform*, 154, 104563. <https://doi.org/10.1016/j.ijmedinf.2021.104563>
- Saxena, S., Jena, B., Gupta, N., Das, S., Sarmah, D., Bhattacharya, P., Nath, T., Paul, S., Fouda, M. M., Kalra, M., Saba, L., Pareek, G., & Suri, J. S. (2022). Role of Artificial Intelligence in Radiogenomics for Cancers in the Era of Precision Medicine. *Cancers*, 14(12), 2860. <https://www.mdpi.com/2072-6694/14/12/2860>
- Sharma, R., Mahanti, G. K., Panda, G., Rath, A., Dash, S., Mallik, S., & Hu, R. (2023). A Framework for Detecting Thyroid Cancer from Ultrasound and Histopathological Images Using Deep Learning, Meta-Heuristics, and MCDM Algorithms. *J Imaging*, 9(9). <https://doi.org/10.3390/jimaging9090173>
- Shi, Y., Zou, Y., Liu, J., Wang, Y., Chen, Y., Sun, F., Yang, Z., Cui, G., Zhu, X., Cui, X., & Liu, F. (2022). Ultrasound-based radiomics XGBoost model to assess the risk of central cervical lymph node metastasis in patients with papillary thyroid carcinoma: Individual application of SHAP. *Front Oncol*, 12, 897596. <https://doi.org/10.3389/fonc.2022.897596>
- Sinnott, B., Ron, E., & Schneider, A. B. (2010). Exposing the thyroid to radiation: a review of its current extent, risks, and implications. *Endocr Rev*, 31(5), 756-773. <https://doi.org/10.1210/er.2010-0003>
- Sorrenti, S., Dolcetti, V., Radzina, M., Bellini, M. I., Frezza, F., Munir, K., Grani, G., Durante, C., D'Andrea, V., David, E., Calò, P. G., Lori, E., & Cantisani, V. (2022). Artificial Intelligence for Thyroid Nodule Characterization: Where Are We Standing? *Cancers (Basel)*, 14(14). <https://doi.org/10.3390/cancers14143357>
- Taye, M. M. (2023). Understanding of Machine Learning with Deep Learning: Architectures, Workflow, Applications and Future Directions. *Computers*, 12(5), 91. <https://www.mdpi.com/2073-431X/12/5/91>
- Thewjitcharoen, Y., Chatchomchuan, W., Karndumri, K., Porramatikul, S., Krittiyawong, S., Wanothayaroj, E., Butadej, S., Nakasatien, S., Veerasomboonsin, V., Kanchanapituk, A., Rajatanavin, R., & Himathongkam, T. (2021). Impacts of the American Joint Committee on Cancer (AJCC) 8(th) edition tumor, node, metastasis (TNM) staging system on outcomes of differentiated thyroid cancer in Thai patients. *Heliyon*, 7(3), e06624. <https://doi.org/10.1016/j.heliyon.2021.e06624>
- Toda, S., Iwasaki, H., Suganuma, N., Okubo, Y., Hayashi, H., Masudo, K., Nakayama, H., & Masuda, M. (2020). Occult Thyroid Carcinoma without Malignant Thyroid Gland Findings during Preoperative Examination: Report of Three Cases. *Case Reports in Endocrinology*, 2020, 4249067. <https://doi.org/10.1155/2020/4249067>
- Uludag, M., Unlu, M. T., Kostek, M., Aygun, N., Caliskan, O., Ozel, A., & Isgor, A. (2023). Management of Thyroid Nodules. *Sisli Etfal Hastan Tip Bul*, 57(3), 287-304. <https://doi.org/10.14744/semb.2023.06992>
- Unlu, M. T., Kostek, M., Aygun, N., Isgor, A., & Uludag, M. (2022). Non-Toxic Multinodular Goiter: From Etiopathogenesis to Treatment. *Sisli Etfal Hastan Tip Bul*, 56(1), 21-40. <https://doi.org/10.14744/semb.2022.56514>
- van Timmeren, J. E., Cester, D., Tanadini-Lang, S., Alkadhi, H., & Baessler, B. (2020). Radiomics in medical imaging—"how-to" guide and critical reflection. *Insights into Imaging*, 11(1), 91. <https://doi.org/10.1186/s13244-020-00887-2>
- Veiga-Canuto, D., Cerdà-Alberich, L., Sangüesa Nebot, C., Martínez de Las Heras, B., Pötschger, U., Gabelloni, M., Carot Sierra, J. M., Taschner-Mandl, S., Düster, V., Cañete, A., Ladenstein, R., Neri, E., & Martí-Bonmatí, L. (2022). Comparative Multicentric Evaluation of Inter-Observer



- Variability in Manual and Automatic Segmentation of Neuroblastic Tumors in Magnetic Resonance Images. *Cancers (Basel)*, 14(15). <https://doi.org/10.3390/cancers14153648>
- Vijithananda, S. M., Jayatilake, M. L., Gonçalves, T. C., Rato, L. M., Weerakoon, B. S., Kalupahana, T. D., Silva, A. D., Dissanayake, K., & Hewavithana, P. B. (2023). Texture feature analysis of MRI-ADC images to differentiate glioma grades using machine learning techniques. *Sci Rep*, 13(1), 15772. <https://doi.org/10.1038/s41598-023-41353-5>
- Wang, W., Ozolek, J. A., & Rohde, G. K. (2010). Detection and classification of thyroid follicular lesions based on nuclear structure from histopathology images. *Cytometry A*, 77(5), 485-494. <https://doi.org/10.1002/cyto.a.20853>
- Wang, X., Wang, X., Zhang, Y., Zhang, D., Song, Z., Meng, Q., Li, Y., & Wang, C. (2022). Development of the prediction model based on clinical-imaging omics: molecular typing and sentinel lymph node metastasis of breast cancer. *Ann Transl Med*, 10(13), 749. <https://doi.org/10.21037/atm-22-2844>
- Wang, Y., Yue, W., Li, X., Liu, S., Guo, L., Xu, H., Zhang, H., & Yang, G. (2020). Comparison Study of Radiomics and Deep Learning-Based Methods for Thyroid Nodules Classification Using Ultrasound Images. *IEEE Access*, 8, 52010-52017. <https://doi.org/10.1109/access.2020.2980290>
- Wang, Y. G., Xu, F. J., Agyekum, E. A., Xiang, H., Wang, Y. D., Zhang, J., Sun, H., Zhang, G. L., Bo, X. S., Lv, W. Z., Wang, X., Hu, S. D., & Qian, X. Q. (2022). Radiomic Model for Determining the Value of Elasticity and Grayscale Ultrasound Diagnoses for Predicting BRAF(V600E) Mutations in Papillary Thyroid Carcinoma. *Front Endocrinol (Lausanne)*, 13, 872153. <https://doi.org/10.3389/fendo.2022.872153>
- Wei, R., Wang, H., Wang, L., Hu, W., Sun, X., Dai, Z., Zhu, J., Li, H., Ge, Y., & Song, B. (2021). Radiomics based on multiparametric MRI for extrathyroidal extension feature prediction in papillary thyroid cancer. *BMC Medical Imaging*, 21(1), 20. <https://doi.org/10.1186/s12880-021-00553-z>
- Wu, X., Yu, P., Jia, C., Mao, N., Che, K., Li, G., Zhang, H., Mou, Y., & Song, X. (2022). Radiomics Analysis of Computed Tomography for Prediction of Thyroid Capsule Invasion in Papillary Thyroid Carcinoma: A Multi-Classifer and Two-Center Study [Original Research]. *Frontiers in Endocrinology*, 13. <https://doi.org/10.3389/fendo.2022.849065>
- Xia, E., Chi, Y., Jin, L., Shen, Y., Hirachan, S., Bhandari, A., & Wang, O. (2021). Preoperative prediction of lymph node metastasis in patients with papillary thyroid carcinoma by an artificial intelligence algorithm. *Am J Transl Res*, 13(7), 7695-7704.
- Xu, H., Wang, X., Guan, C., Tan, R., Yang, Q., Zhang, Q., Liu, A., & Liu, Q. (2022). Value of Whole-Thyroid CT-Based Radiomics in Predicting Benign and Malignant Thyroid Nodules. *Front Oncol*, 12, 828259. <https://doi.org/10.3389/fonc.2022.828259>
- Yip, S. S., & Aerts, H. J. (2016). Applications and limitations of radiomics. *Phys Med Biol*, 61(13), R150-166. <https://doi.org/10.1088/0031-9155/61/13/r150>
- Yip, S. S. F., Liu, Y., Parmar, C., Li, Q., Liu, S., Qu, F., Ye, Z., Gillies, R. J., & Aerts, H. (2017). Associations between radiologist-defined semantic and automatically computed radiomic features in non-small cell lung cancer. *Sci Rep*, 7(1), 3519. <https://doi.org/10.1038/s41598-017-02425-5>
- Yu, J., Deng, Y., Liu, T., Zhou, J., Jia, X., Xiao, T., Zhou, S., Li, J., Guo, Y., Wang, Y., Zhou, J., & Chang, C. (2020). Lymph node metastasis prediction of papillary thyroid carcinoma based on transfer learning radiomics. *Nat Commun*, 11(1), 4807. <https://doi.org/10.1038/s41467-020-18497-3>
- Yu, J., Zhang, Y., Zheng, J., Jia, M., & Lu, X. (2022). Ultrasound images-based deep learning radiomics nomogram for preoperative prediction of RET rearrangement in papillary thyroid carcinoma. *Front Endocrinol (Lausanne)*, 13, 1062571. <https://doi.org/10.3389/fendo.2022.1062571>
- Yu, L., Zhao, X., Huang, J., Hu, H., & Liu, B. (2023). Research on Machine Learning with Algorithms and Development. *Journal of Theory and Practice of Engineering Science*, 3, 7-14. [https://doi.org/10.53469/jtpes.2023.03\(12\).02](https://doi.org/10.53469/jtpes.2023.03(12).02)
- Yu, P., Wu, X., Li, J., Mao, N., Zhang, H., Zheng, G., Han, X., Dong, L., Che, K., Wang, Q., Li, G., Mou, Y., & Song, X. (2022). Extrathyroidal Extension Prediction of Papillary Thyroid Cancer With Computed Tomography Based Radiomics Nomogram: A Multicenter Study. *Front Endocrinol (Lausanne)*, 13, 874396. <https://doi.org/10.3389/fendo.2022.874396>
- Zhang, Y.-P., Zhang, X.-Y., Cheng, Y.-T., Li, B., Teng, X.-Z., Zhang, J., Lam, S., Zhou, T., Ma, Z.-R., Sheng, J.-B., Tam, V. C. W., Lee, S. W. Y., Ge, H., & Cai, J. (2023). Artificial intelligence-driven

- radiomics study in cancer: the role of feature engineering and modeling. *Military Medical Research*, 10(1), 22. <https://doi.org/10.1186/s40779-023-00458-8>
- Zhou, H., Jin, Y., Dai, L., Zhang, M., Qiu, Y., Wang, K., Tian, J., & Zheng, J. (2020). Differential Diagnosis of Benign and Malignant Thyroid Nodules Using Deep Learning Radiomics of Thyroid Ultrasound Images. *Eur J Radiol*, 127, 108992. <https://doi.org/10.1016/j.ejrad.2020.108992>
- Zhou, S. C., Liu, T. T., Zhou, J., Huang, Y. X., Guo, Y., Yu, J. H., Wang, Y. Y., & Chang, C. (2020). An Ultrasound Radiomics Nomogram for Preoperative Prediction of Central Neck Lymph Node Metastasis in Papillary Thyroid Carcinoma. *Front Oncol*, 10, 1591. <https://doi.org/10.3389/fonc.2020.01591>
- Zhou, Y., Su, G. Y., Hu, H., Tao, X. W., Ge, Y. Q., Si, Y., Shen, M. P., Xu, X. Q., & Wu, F. Y. (2022). Radiomics from Primary Tumor on Dual-Energy CT Derived Iodine Maps can Predict Cervical Lymph Node Metastasis in Papillary Thyroid Cancer. *Acad Radiol*, 29 Suppl 3, S222-s231. <https://doi.org/10.1016/j.acra.2021.06.014>
- Zhu, H., Yu, B., Li, Y., Zhang, Y., Jin, J., Ai, Y., Jin, X., & Yang, Y. (2023). Models of ultrasonic radiomics and clinical characters for lymph node metastasis assessment in thyroid cancer: a retrospective study. *PeerJ*, 11, e14546. <https://doi.org/10.7717/peerj.14546>
- Zhu, W., Huang, X., Qi, Q., Wu, Z., Min, X., Zhou, A., & Xu, P. (2022). Artificial Neural Network-Based Ultrasound Radiomics Can Predict Large-Volume Lymph Node Metastasis in Clinical N0 Papillary Thyroid Carcinoma Patients. *J Oncol*, 2022, 7133972. <https://doi.org/10.1155/2022/7133972>