

# Artificial Intelligence in Image-based Cardiovascular Disease Analysis: A Comprehensive Survey and Future Outlook

Xin Wang and Hongtu Zhu

**Abstract**—Recent advancements in Artificial Intelligence (AI) have significantly influenced the field of Cardiovascular Disease (CVD) analysis, particularly in image-based diagnostics. Our paper presents an extensive review of AI applications in image-based CVD analysis, offering insights into its current state and future potential. We systematically categorize the literature based on the primary anatomical structures related to CVD, dividing them into non-vessel structures (such as ventricles and atria) and vessel structures (including the aorta and coronary arteries). This categorization provides a structured approach to explore various imaging modalities like Magnetic Resonance Imaging (MRI), which are commonly used in CVD research. Our review encompasses these modalities, giving a broad perspective on the diverse imaging techniques integrated with AI for CVD analysis. Additionally, we compile a list of publicly accessible cardiac image datasets and code repositories, intending to support research reproducibility and facilitate data and algorithm sharing within the community. We conclude with an examination of the challenges and limitations inherent in current AI-based CVD analysis methods and suggest directions for future research to overcome these hurdles.

**Index Terms**—AI, Cardiovascular Diseases, Cardiac Image, Deep Learning, Medical Image Analysis, Survey.

## 1 INTRODUCTION

CARDIOVASCULAR diseases (CVDs) are the leading cause of mortality worldwide, accounting for an estimated 17.9 million deaths annually, as per the World Health Organization (WHO). In the United States, CVDs, encompassing heart disease and stroke, rank as the primary cause of death. Heart disease alone was responsible for approximately 697,000 deaths in 2020, according to the Centers for Disease Control and Prevention (CDC). These statistics underscore the profound impact of CVDs on global public health and underscore the critical need for enhanced medical research and healthcare strategies in this domain. Consequently, timely and accurate diagnosis, risk assessment, and treatment planning are essential to mitigate their impact and improve patient outcomes [1], [2].

Cardiac imaging encompasses a variety of medical imaging modalities designed to visualize and assess the heart's structure and function [3]. These modalities offer detailed insights into the heart's chambers, blood vessels, and associated tissues, serving multiple critical functions in healthcare. (i) Cardiac imaging aids in identifying biomarkers linked to the risk, progression, and treatment response of heart diseases [4]. Indicators such as carotid artery wall thickness can act as a biomarker for atherosclerosis and predict future cardiovascular events. It can also reveal changes in heart tissue or blood flow that serve as biomarkers for various heart conditions [5], enhancing disease understanding and guiding treatment decisions. (ii) Cardiac imaging is integral to both the planning and monitoring of treatments for various cardiovascular diseases, including coronary artery disease, heart failure, and

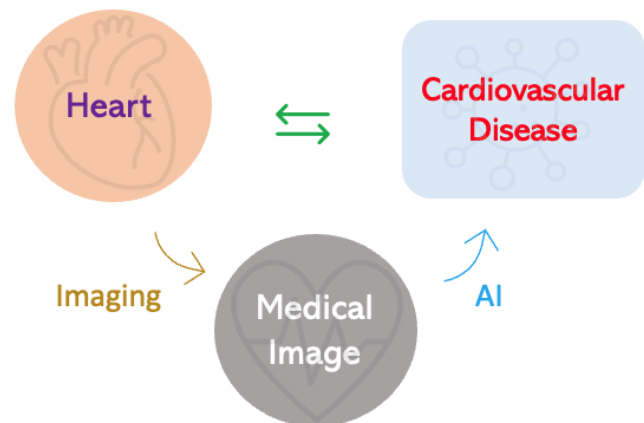


Fig. 1: This figure illustrates our comprehensive approach to exploring CVDs. We categorize these diseases according to the primary anatomical structures they impact and their respective functions. Our analysis also encompasses a variety of medical imaging modalities employed in the diagnosis and study of these diseases. Furthermore, we highlight the significant role of Artificial Intelligence (AI) in enhancing image-based cardiovascular disease analysis, showcasing the integration of advanced AI techniques with traditional imaging methods.

valvular heart disease. Techniques like angiography are instrumental in visualizing blood flow in coronary arteries and detecting obstructions, while echocardiography evaluates heart function and detects structural or motion abnormalities. These imaging methods enable physicians to devise optimal treatment strategies and adjust them over time based on patient progress. (iii) In the realm of clinical trials, cardiac imaging plays a pivotal role in evaluating the safety and efficacy of new medical therapies. It allows for real-

- Xin Wang is with the Departments of Epidemiology and Biostatistics, School of Public Health, University at Albany, State University of New York (SUNY), NY, USA. (e-mail: xwang56@albany.edu).
- Hongtu Zhu is with the Departments of Biostatistics, Statistics, Computer Science, and Genetics, University of North Carolina at Chapel Hill, Chapel Hill, USA. (e-mail: htzhu@email.unc.edu). Corresponding author: Hongtu Zhu.

time visualization of the heart’s internal structures and functions and can track morphological or functional changes induced by new drugs or treatments. This capability is essential for determining the effectiveness and safety of treatments before their widespread adoption.

The incorporation of Artificial Intelligence (AI) in medical imaging has significantly transformed the analysis of image-based CVDs [6], [7]. AI, particularly deep learning methods [8], [9], [10], has markedly improved the precision, efficiency, and objectivity of interpreting cardiovascular images [11], [12]. The integration of AI with various cardiovascular imaging techniques, including MRI, CT, X-ray, and ultrasound, has enabled more comprehensive and dynamic evaluations of cardiovascular structures and functions [13], [14]. Recent AI advancements have facilitated breakthroughs in cardiovascular imaging tasks, including segmentation, disease classification, risk prediction, and clinical decision-making support for treatment planning [11], [15]. These developments highlight AI’s crucial role in enhancing the fight against cardiovascular diseases.

In this comprehensive review, we delve into the recent advancements and trends in Artificial Intelligence (AI) applied to the image-based analysis of cardiovascular diseases (CVDs), as illustrated in Figure 1. Our approach is threefold: (i) *Categorization Based on Anatomical Structures*: We systematically organize an extensive collection of CVD research according to the primary anatomical structures impacted and their functions. This categorization creates two principal groups: non-vessel structures such as atria and ventricles, and vessel structures, including the aorta and coronary arteries (See Figure 2). This classification is based on similarities in both the anatomical features and the analysis techniques employed. For example, vessel structure analyses often involve methods like vessel tracing and stenosis degree estimation. (ii) *Integration with Other Data Types*: Beyond traditional medical imaging, our review includes studies that integrate imaging with additional data types, like genomics, for a more holistic analysis of CVDs [16]. This expansive coverage, which includes a variety of cardiac imaging structural analysis tasks—such as chamber segmentation, coronary artery segmentation, and coronary artery branch labeling—sets our review apart. Additionally, we explore functional simulation methods, such as fractional flow reserve (FFR), a vital diagnostic measure in cardiology for assessing the severity of coronary artery stenosis. (iii) *Large-Scale Population-Based Studies*: The review expands to encompass large-scale studies using AI for image-based analysis of CVDs. The merger of imaging genetics with AI in cardiovascular disease research represents a significant leap forward. It provides researchers with the tools to decode the genetic foundations of these diseases, significantly improving diagnosis, treatment strategies, and prognostic evaluations [16].

There exists a range of survey papers that have provided overviews of AI applications in cardiovascular imaging tasks, such as segmentation [17], [18], [19], or that have focused on specific diseases [20], types of CVD like Congenital heart disease (CHD) [21], or singular medical image modalities [22]. However, these surveys have typically lacked a comprehensive approach that encompasses both structural and functional aspects of cardiovascular analysis. Notably, critical techniques like coronary flow analysis [23] are often omitted. In our survey, we address this gap by discussing cardiac imaging modalities along with their unique characteristics, advantages, and the diseases they are most relevant to. Our approach covers both the anatomical aspects

(such as chamber volume and coronary artery morphology) and functional aspects (including cardiac motion and blood flow) of cardiovascular imaging. Additionally, we provide a summary of publicly available datasets and code repositories to enhance research reproducibility, foster collaboration, and accelerate scientific advancements in this field. Furthermore, our survey engages in insightful discussions about the current challenges in AI-based cardiovascular imaging and outlines potential directions for future research in this rapidly evolving domain.

The key contributions of our survey are outlined as follows:

- We provide the first comprehensive survey that thoroughly examines the use of AI in cardiac imaging. This survey uniquely emphasizes both the structural and functional aspects of the heart, encompassing a broad range of cardiac diseases. Our approach offers a holistic view of the transformative role of AI in cardiac imaging, providing valuable insights into its capabilities and limitations, thereby setting the stage for future innovations in this field.
- A significant aspect of our work is the integration of cardiac imaging with large-scale, population-based studies through AI technologies. We explore how AI can effectively analyze image-based CVD data in combination with genetic, lifestyle, and environmental health factors. This multidisciplinary approach results in a nuanced understanding of CVD, considering the interplay between medical imaging data and broader genetic and environmental factors. Such comprehensive analysis is crucial for developing more personalized and effective strategies for CVD prevention and management.
- Our survey also sheds light on potential future research directions, particularly emphasizing the need for integrating diverse data types. This includes combining environmental and genetic data to develop sophisticated AI models for addressing complex clinical challenges in heart disease. By leveraging such multi-scale data, AI models can significantly improve our understanding of heart diseases, aiding in early detection, accurate diagnosis, and the formulation of effective treatment plans. This suggests that future advancements in AI will likely concentrate on leveraging these diverse data modalities to address intricate clinical questions in cardiology, aiming to enhance patient outcomes significantly.

The remaining content of this paper is organized as follows. After introducing cardiac imaging modalities as the background in Section 2, we describe the heart structures (non-vessel and vessel), the common diseases, and the related AI works in Section 3. We also review the population-based cardiovascular imaging analysis works in Section 4. In Sections 5, we summarize the public datasets and code. We discuss the limitations of the current AI-based methods and the future works in Section 6. Finally, we conclude the paper in Section 7.

## 2 BACKGROUND - CARDIAC IMAGING

In this section, we delve into the commonly employed modalities in cardiac imaging (examples are shown in Figure 3). Depending on the specific clinical requirements and the information needed by healthcare professionals, these imaging techniques are either used in combination or selectively chosen to provide the most accurate and comprehensive assessment of cardiac health.

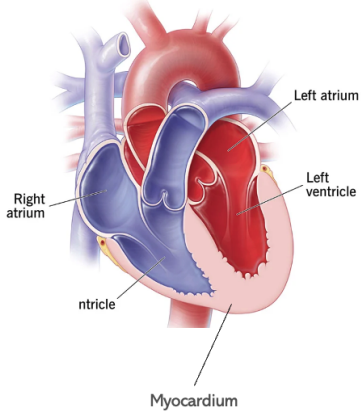
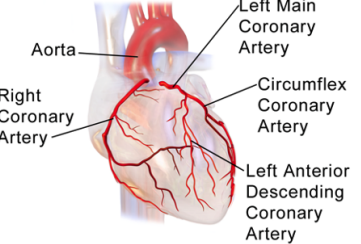
Heart	Target	Modality	Structure	Lesion/Function	Related Disease
<p><b>Non-vessel</b></p> 	<b>Atria</b>	LEG MRI	LA Wall Seg	LA fibrosis	Atrial Fibrillation
	<b>Ventricle</b>	Ultrasound	Ventricle Seg	Ventricle Function	Ejection Fraction Estimation
	<b>Myocardium</b>	Cardiac tagging MRI	Landmarks tracking	Motion Fields	Ischemic Heart Disease
<p><b>Vessel</b></p> 	<b>Aorta</b>	4D Flow MRI	Aorta Seg	Aorta Flow	Aorta Dissections
	<b>Coronary Arteries</b>	CTA	Coronary Artery Seg	Fractional Flow Reserve	Coronary Artery Disease

Fig. 2: This figure categorizes cardiovascular diseases (CVDs) by highlighting the key anatomical structures involved and their functions, also showcasing the data modalities and AI-based methods used for analysis. **Top:** It includes examples of non-vessel anatomical structures, such as (a) atria [20], (b) ventricles [24] and (c) Myocardium [25]. **Bottom:** It presents vessel structures, including the (d) aorta [26] and (e) coronary arteries [27], [28].

### 2.1 Electrocardiogram (ECG)

An electrocardiogram (ECG) is a critical medical test that captures the heart’s electrical activity [38]. It graphically represents this activity over time, with the x-axis denoting time and the y-axis the amplitude of the electrical signal. The ECG can be perceived as a form of medical imaging, mapping the heart’s electrical impulses through wave patterns on a graph [39]. To obtain an ECG, electrodes are strategically placed on the patient’s skin to record electrical impulses generated during the heart’s contraction and relaxation cycles. Each heartbeat begins with an electrical impulse originating from the heart’s sinoatrial (SA) node. This impulse travels through the heart muscle, prompting it to contract and pump blood. The ECG machine detects and amplifies these impulses, transforming them into waveforms that offer insights into heart function.

ECG is an indispensable diagnostic tool in cardiovascular medicine, offering clinicians immediate insight into the heart’s electrical function [40]. It is essential for diagnosing a variety of heart-related conditions, including: (i) Heart Rhythm Disorders:

An ECG is effective in identifying abnormal heart rhythms or arrhythmias, such as atrial fibrillation or ventricular tachycardia. (ii) Heart Attacks: The ECG is instrumental in recognizing patterns indicative of myocardial ischemia (reduced blood flow) or infarction (tissue death due to lack of oxygen), which are key markers of heart attacks. (iii) Structural Heart Abnormalities: An ECG can reveal structural heart changes that suggest conditions like cardiomyopathy or hypertrophy, where the heart muscle is enlarged or altered [41].

### 2.2 Cardiac X-ray Imaging

Cardiac X-ray imaging, often employed in coronary angiography, is a diagnostic technique that uses X-rays to produce two-dimensional images of the heart and blood vessels [42]. This method is particularly useful in emergency settings for initial assessments due to its quick execution and relatively low radiation exposure, making it safer for a wide range of patients [43]. It is excellent for identifying coronary artery disease (CAD) by directly visualizing the coronary arteries and informing treatment



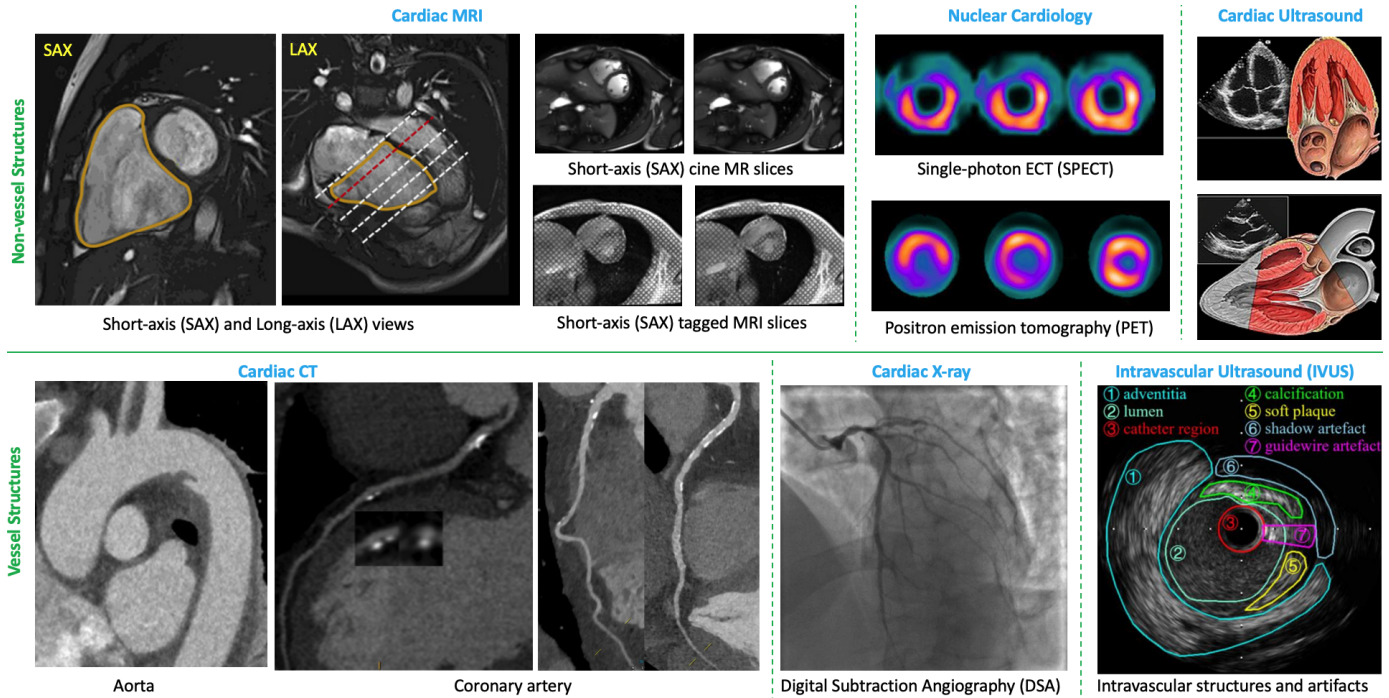


Fig. 3: Examples of Cardiac Data Modalities. **Top (Non-vessel):** Cardiac MRI [29], Cine MRI and Tagged Cine MRI [30], Nuclear Cardiology [31], Cardiac Ultrasound [32]. **Bottom (Vessel):** Cardiac CT (Aorta [33], Coronary [34], [35]), Cardiac X-ray [36], Intravascular Ultrasound (IVUS) [37].

strategies like angioplasty or stenting to restore heart muscle blood flow [44].

**Digital Subtraction Angiography (DSA):** This advanced technique in cardiac X-ray imaging enhances image clarity by digitally removing background structures, focusing solely on blood vessels. The use of contrast dye in conjunction with rapid image acquisition results in high-resolution images that are crucial for identifying vascular abnormalities [45].

**Interventional Coronary Angiography (ICA):** ICA is a specialized application of Cardiac X-ray imaging used for interventional procedures such as percutaneous coronary intervention (PCI). During PCI, a catheter is inserted to treat blockages in coronary arteries, often employing techniques like angioplasty and stenting. The X-ray system plays a crucial role in guiding the catheter’s placement and monitoring the progress of the intervention [46].

### 2.3 Cardiac Computed tomography (CT)

Cardiac Computed Tomography (CT), utilizing advanced X-ray technology, provides detailed cross-sectional, three-dimensional images of the heart and surrounding vessels. Compared to Cardiac X-ray imaging, Cardiac CT involves higher levels of radiation exposure but offers more detailed and comprehensive views. This imaging method is particularly valuable for assessing cardiac anatomy, with a primary focus on the coronary arteries. It plays a crucial role in identifying blockages or narrowing within these arteries, which are key indicators of coronary artery disease [47]. In the following sections, we will explore various Cardiac CT modalities and their specific applications in cardiac imaging [48].

**Coronary CT Angiography (CTA):** Non-contrast CT imaging utilizes tissue density differences to create images, allowing distinction between soft tissues, calcium, fat, and air. This is useful for estimating calcium presence in coronary arteries. In contrast-enhanced coronary CTA, acquired post-contrast agent injection,

the imaging provides detailed views of cardiac chambers, vessels, and coronaries, effectively detecting non-calcified coronary plaques [49]. It’s widely employed for diagnosing coronary artery disease (CAD), coronary anomalies, and pre-surgical evaluations for coronary bypass. Additionally, it assesses stent patency post-implantation [50].

**Calcium-Scoring Heart Scan:** This scan, also known as coronary artery calcium (CAC) scoring, is a specialized X-ray test that measures calcifications in coronary arteries, indicative of coronary artery disease (CAD). These calcifications, even before symptom onset, signal potential heart-related events. The derived calcium score helps in risk assessment for CAD, with higher scores suggesting increased risk of heart attacks [51].

**Functional Cardiovascular CT:** This CT form is essential for non-invasive evaluation of heart and vascular structures. Known for producing detailed body cross-sections, it offers insights into both structural and functional aspects of the cardiovascular system. Functional Cardiovascular CT is instrumental in assessing myocardial perfusion and ventricular function, useful in evaluating ischemic heart disease, cardiomyopathies, and heart failure [52].

**Cardiac Dual-Energy CT (DECT):** DECT applies dual-energy imaging principles to the heart and vasculature, utilizing two X-ray energy spectra to yield detailed information on cardiac tissues and pathologies. It enhances plaque characterization in arteries and differentiates tissue types, aiding in myocardial infarction diagnosis and tumor identification [53].

### 2.4 Cardiac Ultrasound (Echocardiography)

Cardiac ultrasound imaging is a fundamental tool in cardiovascular assessment, employing sound waves to produce real-time images of the heart [54], [55]. These images reveal critical details about the heart’s size, shape, function, and blood flow patterns [56].

Echocardiography's non-invasive approach, combined with the absence of ionizing radiation and its capability for immediate imaging, makes it a preferred choice for initial diagnosis in a range of cardiac conditions [57]. It is crucial in identifying and managing various heart diseases, such as Valvular Heart Disease, Cardiomyopathies, and Congenital Heart Disease [21], [58].

For the vessels, Intravascular Ultrasound (IVUS) is a medical imaging methodology used in cardiology to visualize the inside of the heart's coronary arteries from within the artery itself [59]. It involves using a specially designed catheter with a miniaturized ultrasound probe attached to its distal end. The catheter is threaded through the coronary vasculature to the area of interest, and ultrasound is used to produce detailed images of the coronary arteries' interior walls. [60].

## 2.5 Nuclear Cardiology

Nuclear imaging in cardiology utilizes small amounts of radioactive tracers injected into the patient's bloodstream. These tracers emit gamma rays, captured by specialized cameras to generate images of the heart's structure and function [61]. Nuclear cardiology, including single-photon emission computed tomography (SPECT) and positron emission tomography (PET), have been a key non-invasive imaging modality for patients with known or suspected cardiovascular disease.

**Cardiac Single-Photon Emission Computed Tomography (SPECT):** SPECT is a vital diagnostic tool for evaluating heart function and blood flow. As a non-invasive imaging technique, it offers essential information regarding the heart's structure, blood supply, and overall health. It plays a significant role in diagnosing, managing, and monitoring various cardiovascular conditions, contributing to better patient care and treatment planning [62].

**Positron Emission Tomography (PET):** PET is a highly advanced and non-invasive imaging technique used in the evaluation of heart diseases. It utilizes a small amount of radioactive material, a PET scanner, and a computer to evaluate the function and metabolism of the heart. This technique stands out for its exceptional accuracy in detecting coronary artery disease, assessing myocardial perfusion (blood flow to the heart muscle), and evaluating heart function. Cardiac PET is particularly effective in identifying areas of reduced blood flow, differentiating between viable and non-viable heart muscle, and diagnosing various cardiac conditions. Its high sensitivity and specificity make it a valuable tool in the management of heart diseases [63].

## 2.6 Cardiac Magnetic Resonance Imaging (MRI)

Cardiac MRI is a non-invasive imaging technique that uses a powerful magnetic field and radio waves to produce detailed images of the heart, offering crucial insights into its structure, function, and blood flow [85], [86]. We discuss several MRI modalities commonly used in cardiac imaging.

**Cine MRI:** Cine MRI captures a series of images across the cardiac cycle to visualize the beating heart in real time, allowing evaluation of heart structure, ventricular size, wall motion, and ejection fraction. It's essential in detecting conditions like ventricular hypertrophy, myocardial infarction, and various valvular disorders [87], [88].

**Cardiac tagging magnetic resonance imaging (t-MRI).** Cardiac tagging magnetic resonance imaging (t-MRI), also known as myocardial tagging or t-MRI, offers a unique approach to evaluating

myocardial movement and deformation. During imaging, a grid-like pattern or "tags" are superimposed on the heart muscle, revealing intricate details about myocardial function. These tags change shape as the heart beats, providing valuable insights into both global and regional cardiac function. Regarded as the gold standard for assessing regional myocardial deformation and strain, cardiac tagging is pivotal in the diagnosis, management, and research of various heart conditions, particularly in diseases such as Ischemic Heart Disease and Dilated Cardiomyopathy [25].

**Late Gadolinium Enhancement (LGE) MRI.** LGE MRI is a crucial imaging technique that enhances the visibility of myocardial damage or fibrosis by using a gadolinium-based contrast agent. It plays a key role in evaluating myocardial viability and identifying pathological tissues, such as scarred areas. This method is particularly effective in diagnosing and assessing various cardiac conditions, including myocardial infarction, myocarditis, and different types of cardiomyopathies. LGE MRI is also increasingly recognized as a valuable tool for assessing scar tissues in patients with atrial fibrillation (AF), offering an advanced alternative for detailed cardiac evaluation [20].

**T2-weighted MRI Images:** T2-weighted MRI stands out for its ability to provide enhanced contrast by distinguishing tissues based on water content and physiological state. This feature is particularly valuable in identifying myocardial abnormalities, such as inflammation, edema, or ischemia. T2-weighted MRI is especially effective in detecting myocardial edema caused by inflammation or acute ischemia, offering critical insights for diagnosis and treatment [89].

**Myocardial Perfusion MRI:** This imaging modality is instrumental in assessing blood flow to the heart muscle, crucial for identifying regions with insufficient blood supply. It involves injecting a contrast agent and capturing images as the contrast first passes through the heart. Myocardial perfusion MRI is essential for diagnosing and managing conditions like coronary artery disease and ischemic heart disease [90], [91].

**Diffusion-Weighted Imaging (DWI):** DWI provides a unique perspective by evaluating the diffusion of water molecules within tissues, revealing information about tissue microstructure. This technique is particularly useful for assessing areas of acute or chronic myocardial ischemia, as alterations in water diffusion properties can indicate tissue damage [92].

**4D Flow MRI:** 4D Flow MRI is a cutting-edge technique that visualizes the velocity and direction of blood flow in three dimensions over time. This comprehensive approach to blood flow analysis is crucial for assessing abnormalities in blood vessels, such as aortic aneurysms, aortic dissections, and congenital heart defects [93].

In summary, various imaging modalities are specialized to detect modality-specific features critical to their clinical use for CVD diagnostics [94], [95], [96], [97]. For example, CT scans are utilized to detect characteristics such as density and tissue contrast, which are important for identifying calcifications, while MRI scans concentrate on identifying features related to soft tissue contrast and motion.

## 3 AI IN INDIVIDUAL IMAGING CVD ANALYSIS

In this section, we focus on AI pipelines for individual CVD analysis, targeting both non-vessel and vessel cardiac structures. Our aim is to outline prevalent cardiac diseases and their analysis using AI technologies in cardiac imaging. We provide an overview

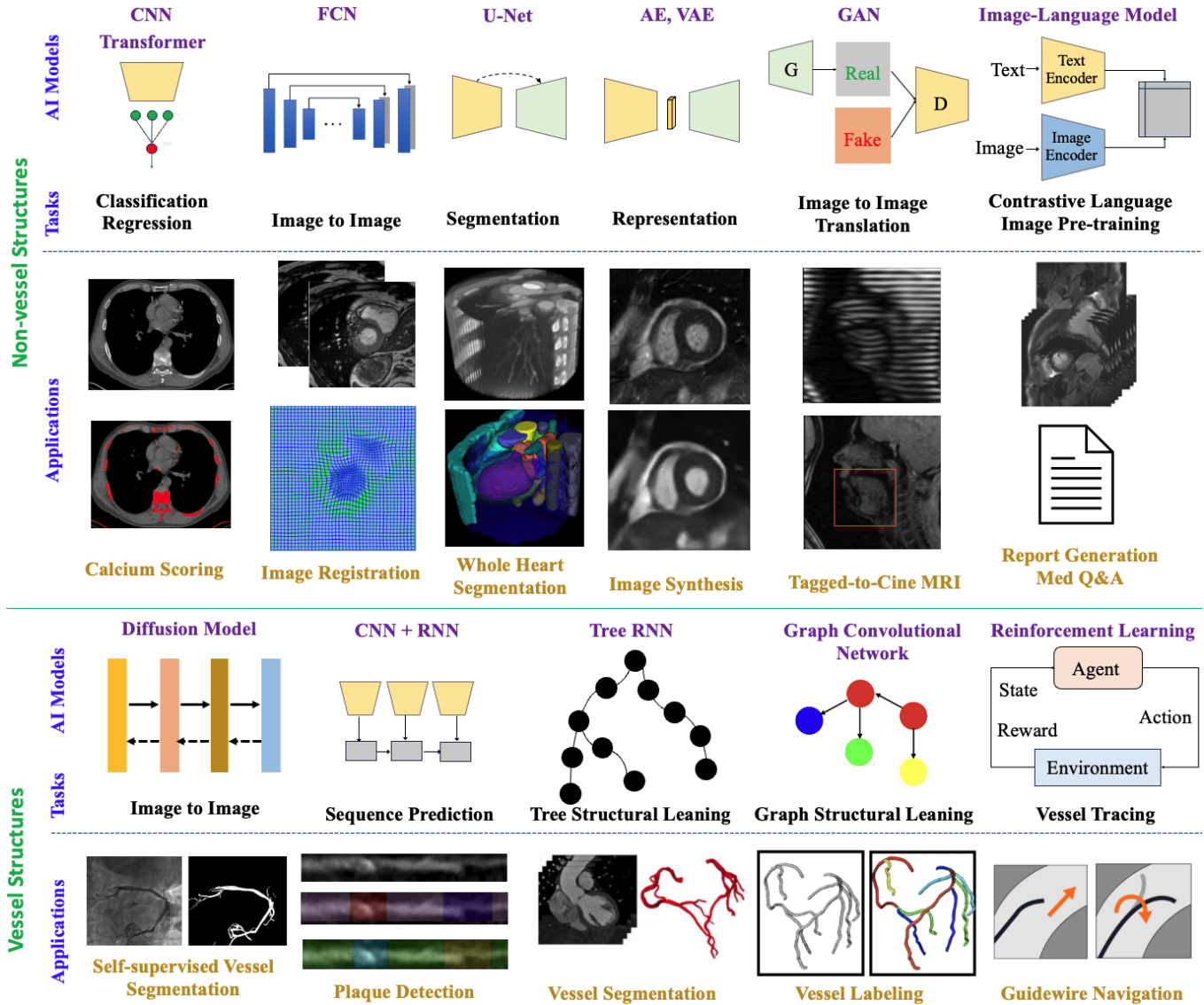


Fig. 4: Examples of recent representative AI models for CVD Analysis. **Top (Non-vessel).** *Examples of Networks and Tasks:* Convolutional neural network (CNN) [64], Transformer [65], Fully convolutional networks (FCN) [66], U-Net [67], Autoencoders (AE) and variational autoencoders (VAE) [68], Generative adversarial networks (GAN) [69], and Contrastive Language Image Pre-training (CLIP) [70]. *Examples of Applications:* Calcium Scoring [71], Image Registration [72], Whole Heart Segmentation [73], Image Synthesis [74], Tagged MRI to Cine MRI Transform [75], and Report Generation [14]. **Bottom (Vessel).** *Examples of Networks and Tasks:* Diffusion Model [76], CNN+Recurrent Neural Networks (RNN) [77], Tree-structured RNN [78], Graph Neural Network (GNN) [79], and Reinforcement Learning (RL) [80]. *Examples of Applications:* Self-supervised Vessel Segmentation [81], Vessel Stenosis Detection [82], Vessel Segmentation [78], Vessel Labeling [83] and Guidewire Navigation [84].

of key diseases, the data modalities used for their study, and recent AI methodologies in this area. The application of some representative AI models in cardiac imaging is depicted in Figure 4, offering insights into the integration of AI in cardiac health and disease management.

### 3.1 AI Methods and Pipelines

Our review delves into the cardiac image analysis pipeline, encompassing both non-vessel and vessel structures, as depicted in Figure 5. This figure provides a comprehensive overview of the pipeline stages, including segmentation, feature extraction, and registration, alongside specific examples. Although these structures share analytical techniques, they are often examined

separately in existing literature, leading to an oversight of their interconnected dynamics. This separation creates a gap in understanding, as the focus typically remains on one type of structure without acknowledging their interrelation. In our survey, we emphasize the intertwined nature of non-vessel and vessel structures in CVD analysis. We explore the significance of their interaction in achieving a complete understanding of CVD. This approach offers valuable insights into the intricacies of cardiac health and disease, highlighting the importance of considering both structures in tandem for comprehensive cardiac analysis.

Figure 5 illustrates that cardiac image segmentation plays a crucial role in numerous clinical applications [106], [107]. This process is key to identifying and analyzing essential anatomi-



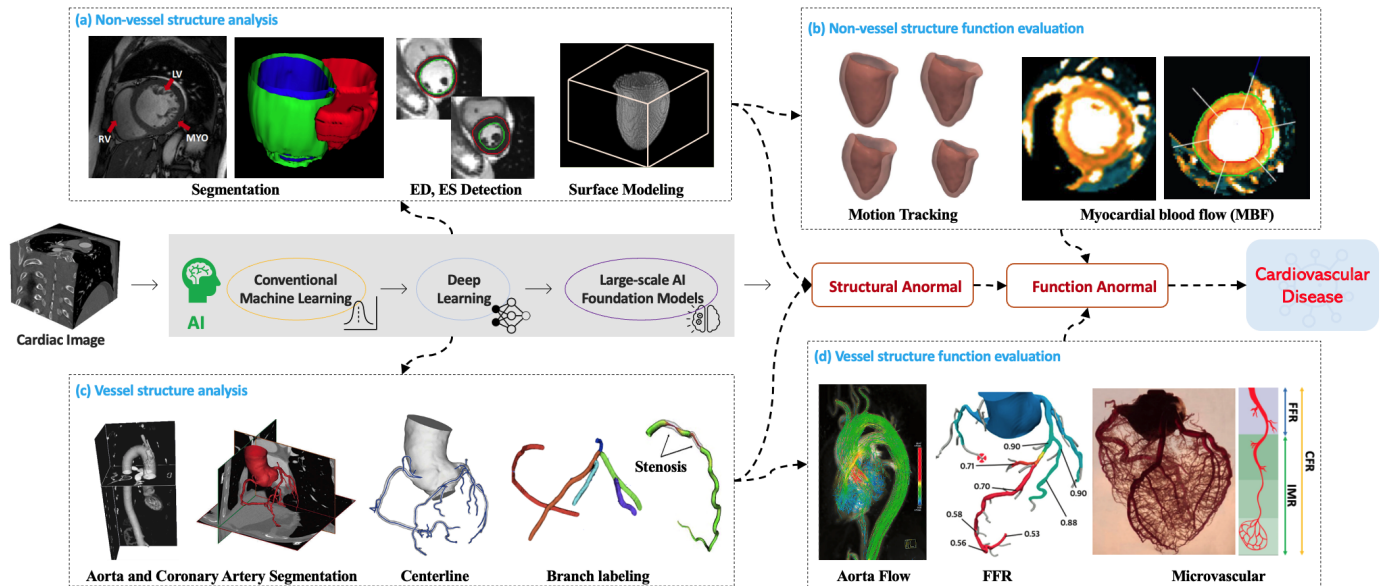


Fig. 5: Overview of the Cardiac Image Analysis Pipeline and Examples. **Top: Non-vessel.** (a): Cardiac segmentation [98], End-diastole (ED) and End-systole (ES) phases detection and Surface Model [99]. (b): Cardiac Motion Tracking [99]. Myocardial blood flow (MBF) maps [100]. **Middle:** Medical images serve as inputs for AI models in the CVD diagnosis pipeline. **Bottom: Vessel.** (c): Segmentation and quantification of vessel structures, with a focus on the Aorta [101]. Coronary Artery Segmentation [102], centerline extraction using segmentation masks [102], Coronary Artery Branch Labeling based on centerline structures [83], and detection of Coronary Artery Stenosis [103]. (d): Evaluation of vessel function. Aorta flow Speed with 3D streamlined visualization [104]. Interpretation of CT-FFR results showing significant hemodynamic impact [34], and Coronary Microvascular [105]. Vessel abbreviations: LAD = left anterior descending; LCX = left circumflex; RCA = right coronary artery. Physiological measurements: CFR = coronary flow reserve; FFR = fractional flow reserve; IMR = index of microvascular resistance.

cal structures [108], as it divides the image into regions with distinct semantic meanings and facilitates the extraction of various quantitative metrics. In the context of non-vessel structures, segmentation aids in calculating important metrics such as the volumes and ejection fractions of the left and right ventricles (LV and RV), atrial sizes, myocardial mass, and wall thickness [17]. For vessel structures, segmentation is pivotal for analyzing aspects of coronary arteries, including centerline extraction [109], plaque identification, and other vascular features. Such detailed segmentation provides invaluable insights for both the diagnosis and treatment planning processes.

The U-Net architecture, introduced by [67], is a prominent model in medical image segmentation. Its popularity stems from its flexibility, efficient design, and proven success across various imaging modalities [110]. U-Net comprises two main components: the Encoder and the Decoder. The Encoder path captures semantic and contextual features through downsampling and convolutional blocks, while the Decoder path uses convolutional and upsampling blocks to gradually increase spatial resolution and facilitate pixel-wise classification. U-Net’s defining feature is its skip connections, which bridge each level of the Encoder to the corresponding Decoder level, ensuring the transfer of high-resolution contextual details. This feature promotes the combination of low-level details with high-context information for precise localization. Furthermore, U-Net’s architecture easily integrates with Recurrent Neural Network (RNN) structures. An example of this integration is the use of ConvLSTM [111] by Azad et al. [112], which nonlinearly combines features from both the encoder and the preceding decoder layers. Since its inception, U-Net has established itself as a benchmark in medical image segmentation, inspiring

various advanced derivatives that enhance its original design. For a comprehensive review of U-Net variants, see [113]. In addition to U-Net, Generative Adversarial Networks (GANs) also play a significant role in medical image segmentation [114], [115], [116], [117]. More recently, denoising diffusion models, a notable subset of generative models, have recently attracted significant attention in the field of deep learning. They have demonstrated remarkable utility across a wide range of applications, especially in the enhancement of medical image segmentation [118]. These models have demonstrated their effectiveness in generating high-quality segmented images, further expanding the possibilities in medical imaging analysis.

As illustrated in the right panel of Figure 5, following segmentation, the AI system engages in feature extraction for precise quantification. This stage involves measuring physical heart parameters like chamber volumes, wall thickness, and myocardial mass [108]. Utilizing the segmented structures and the features derived, AI models then conduct functional analysis. This encompasses the calculation of ejection fraction, wall motion, and blood flow dynamics, crucial indicators of the heart’s efficiency and overall functioning [108]. By integrating segmented images, extracted features, and quantification metrics, the AI system forms a comprehensive assessment of cardiac structure and function, invaluable for diagnosing cardiac conditions and formulating treatment plans. The details of methods in Figure 5 are introduced in Section 3.2 for non-vessel structures and Section 3.3 vessel structures. For clinical utility, the AI pipeline presents results in an easily interpretable format, often through 3D models or quantitative maps, compiled into reports for cardiologists’ evaluation. Additionally, it incorporates clinician feedback to refine models,

enhancing accuracy and adaptability to new data and insights. This AI-driven approach in cardiology transforms complex imaging data into practical medical information, potentially revolutionizing the diagnosis and treatment of heart diseases.

Image registration plays a critical role in analyzing heart structures and diseases, especially when merging data from different imaging modalities or tracking disease progression over time [119]. Accurate registration is essential for mapping structural changes precisely and is indispensable in longitudinal studies, treatment planning, and assessing therapeutic efficacy [120]. The task of cardiac image registration is particularly challenging due to the significant variability in cardiac shape and motion among individuals [121]. It often involves aligning heart images captured at different times or under varying conditions, such as different phases of the cardiac cycle or using diverse imaging techniques like CT, MRI, or ultrasound [122]. Given the dynamic nature of the heart and the influence of respiratory movements, non-rigid registration is crucial for cardiac images [72]. This approach is key to understanding disease progression or treatment effects by comparing temporal image sequences. Advancements in AI models are vital for enhancing registration accuracy and efficiency. The development of real-time registration systems is particularly significant for their potential application in surgical or interventional settings [80], promising to significantly improve patient outcomes and procedural precision in cardiac care [123].

## 3.2 Non-vessel Structures

### 3.2.1 Atria

The atria, consisting of the left and right atrium, are the upper chambers of the heart responsible for receiving blood, as depicted in Figure 2 (a). The right atrium collects blood returning from the body, and the left atrium receives oxygenated blood from the lungs. Both chambers play a crucial role in channeling blood into the ventricles. This section focuses on common diseases that impact the atria and examines the application of AI technologies in their analysis and diagnosis.

**Atrial Diseases.** We examine several common diseases related to the atria [124], [125]. A key condition, Atrial fibrillation (AF), is a prevalent cardiac arrhythmia marked by irregular and rapid atrial electrical activity [126], [127]. Instead of regular contractions, the atria fibrillate or quiver, resulting in an irregular heartbeat, leading to symptoms like palpitations, shortness of breath, fatigue, and dizziness [128]. Crucially, AF heightens the risk of stroke due to potential blood clot formation in the atria [129].

For detecting AF-related abnormalities, primary imaging techniques include ECG and cardiac MRI. ECG is preferred for its real-time imaging, while cardiac MRI, especially Late Gadolinium Enhancement (LGE) MRI, offers high-resolution images vital for assessing structural changes and fibrosis. Deep learning algorithms trained on extensive ECG datasets can effectively identify AF patterns [129], achieving high accuracy that often matches or exceeds human experts [130]. As shown in Figure 2 (a), the AI analysis pipeline for AF ablation involves tasks like LA cavity and wall segmentation, scar segmentation, quantification, and applications such as locating ablation gaps from LGE MRI [131].

Quantifying atrial abnormalities often involves measuring atrial volume, detecting fibrotic tissue, and assessing atrial wall thickness. These features are derived using various image processing methods and quantified through shape and intensity metrics.

While these features are generally specific and sensitive, particularly with advanced imaging, the variability in AF manifestations challenges standardization. For comprehensive information on AI methods in AF research, including LA cavity, wall, and scar segmentation from LGE MRI, refer to a recent survey [20].

Atrial Enlargement (AE), another prevalent atrial condition, involves the enlargement of one or both atria, often resulting from chronic issues like hypertension and heart valve diseases [132]. AE is linked to an increased risk of arrhythmias and heart failure [133]. Various imaging modalities, including ECG, echocardiography, cardiac MRI, and CT scans, are employed to detect and assess AE. ECG stands out for its real-time imaging and widespread availability, effectively identifying atrial size and function. Doppler echocardiography complements ECG by providing detailed hemodynamic data. Cardiac MRI and CT scans are valued for their high spatial resolution, enabling precise quantification of atrial volume with heightened sensitivity and specificity. Deep learning technologies, particularly Convolutional Neural Networks (CNNs), have been trained on extensive datasets to recognize ECG patterns indicative of AE [133]. These models offer clinicians a rapid and accurate preliminary diagnosis based on ECG data. The quantification of AE involves measuring atrial dimensions, volume, and area, as well as assessing shape descriptors and functional parameters like atrial emptying fractions. While MRI and CT provide high specificity and sensitivity for these measurements, echocardiography may encounter challenges related to image quality and variability among operators [134]. The integration of these imaging techniques with AI advancements offers a powerful toolkit for the early detection and quantification of atrial enlargement.

### 3.2.2 Ventricle

The heart ventricles, comprising the lower two chambers, are vital components of the heart's anatomy, as illustrated in Figure 2 (b). The left ventricle, recognized as the heart's largest and strongest chamber, plays a critical role in receiving oxygen-rich blood from the left atrium and pumping it into the systemic circulation. This function is essential for supplying oxygen and nutrients to the body's organs and tissues. On the other hand, the right ventricle is responsible for receiving oxygen-depleted blood from the right atrium and directing it into the pulmonary circulation [135], [136]. In this section, we explore various diseases related to the ventricles and delve into how AI technologies are being utilized to analyze these conditions [137]. This discussion will highlight the intersection of advanced technological applications and cardiology, demonstrating the impact of AI in the understanding and treatment of ventricular diseases.

**Ventricular Diseases.** We delve into various anomalies related to the structure and function of the ventricles, each presenting unique characteristics and clinical implications [138]. For instance, abnormal heart rhythms can originate from the ventricles, ranging from benign conditions like premature ventricular contractions (PVCs) to more serious disorders such as ventricular tachycardia or fibrillation [139]. These arrhythmias can compromise the heart's normal pumping function, potentially leading to life-threatening situations [140]. In contrast, Ventricular Septal Defect (VSD) is a congenital heart defect characterized by an abnormal opening in the septum dividing the ventricles. This defect allows the mixing of oxygen-rich and oxygen-poor blood, impacting the heart's efficiency. The size and severity of VSDs can vary [12].



As indicated in Figure 2 (b), the Ejection Fraction (EF) is a key measure of the heart’s pumping efficiency, particularly of the left ventricle. It is critical for identifying patients at risk of heart dysfunctions such as heart failure [141]. EF represents the proportion of blood ejected from the left ventricle with each heartbeat [142]. Normally, the left ventricle effectively pumps out over half of its blood content with each beat. A reduced EF signifies impaired heart pumping function [143]. A notable recent study introduced a model using Graph Neural Networks (GNNs) to estimate EF from echocardiography videos. This model, EchoGNN, demonstrates EF prediction accuracy comparable to current leading methods and offers crucial explainability, addressing the high variability often seen in observer interpretations [144].

### 3.2.3 Myocardium

The myocardium, the heart’s muscular tissue and its middle layer, is crucial for the organ’s function, as illustrated in Figure 2 (c). Comprising specialized cardiac muscle cells called cardiomyocytes, the myocardium is responsible for the heart’s contractions and relaxations, essential for pumping blood throughout the body. Its role in maintaining heart function and ensuring proper blood circulation is fundamental [145]. The myocardium receives its supply of oxygenated blood from the coronary arteries, which nourish the myocardial cells with oxygen and essential nutrients. With each heartbeat, the myocardium contracts, effectively propelling blood from the heart chambers into the circulatory system. Various diseases can impair the myocardium, affecting its ability to function effectively. In the following discussion, we explore several common myocardial conditions and their implications [146]. These diseases illustrate the myocardium’s vulnerability and the importance of maintaining its health for overall cardiovascular well-being.

**Myocardial Diseases.** Myocardial Infarction (Heart Attack) is a critical myocardial function-related disease, arising when blood flow to a part of the myocardium is obstructed, typically by a clot in the coronary arteries [147], [148]. This blockage can cause damage or death to the affected myocardial area, leading to chest pain, shortness of breath, and potentially severe complications [149]. Innovations in deep learning have enabled the use of non-enhanced cardiac MRI to detect and quantify chronic myocardial infarction, potentially reducing reliance on gadolinium contrast injections [150]. Additionally, [151] developed machine learning models that combine cardiac troponin levels with clinical features to evaluate an individual’s myocardial infarction risk. Myocardial perfusion MRI, a noninvasive imaging technique, plays a vital role in detecting ischemic heart disease with high accuracy. Figure 2 (c) demonstrates how AI models provide detailed heart blood flow images, crucial for diagnosing conditions associated with impaired blood supply to the heart muscle, thereby aiding in effective cardiac health management.

Cardiomyopathy, another prevalent structural myocardial anomaly, encompasses diseases that affect the heart muscle, potentially impacting ejection fraction [152]. A notable subtype, Hypertrophic Cardiomyopathy, is a genetic disorder marked by abnormal myocardial thickening, especially in the left ventricle [153]. This thickening can hinder effective blood pumping, manifesting as chest pain, shortness of breath, fainting, and arrhythmias [154]. Hypertrophic cardiomyopathy is especially significant as a leading cause of sudden cardiac arrest in young people.

## 3.3 Vessel Structure and Diseases

In this section, we provide a summary of CVD analysis focusing on the vessel structures. For each part, we summarize the related diseases and the AI technologies for Coronary Artery Disease (CAD) analysis, including coronary artery segmentation, stenosis detection, and functional simulation.

### 3.3.1 Aorta

The aorta, the human body’s largest artery, is a crucial component of the circulatory system, as depicted in Figure 2 (d). Arising from the heart’s left ventricle, it distributes oxygenated blood throughout the body, providing essential nutrients and oxygen to various organs and tissues [155]. Structurally, the aorta is segmented into the ascending aorta, the aortic arch, and the descending aorta, each playing a distinct role in blood circulation [156]. This section offers an overview of some common diseases associated with the aorta. Understanding these conditions is essential for comprehending the aorta’s critical role in maintaining overall cardiovascular health and identifying potential risks and complications that may arise from aortic disorders.

**Aortic Diseases.** Aortic Stenosis, as outlined in [157], is a condition marked by the narrowing of the aortic valve, impeding blood flow from the left ventricle to the aorta. Common in adults due to valve calcification or age-related degeneration, it can cause chest pain, shortness of breath, fatigue, and fainting [158]. The evaluation of heart function is critically enhanced through the analysis of hemodynamic flow parameters [159], [160]. Four-dimensional (4D) flow MRI, a significant advancement in cardiovascular imaging, is extensively discussed in [161]. This technology enables the detailed study of flow dynamics in vivo, essential for understanding and quantifying the parameters relevant to aortic disease [162]. The importance of discerning these flow dynamics lies in their potential to contribute to or worsen vascular diseases, as detailed in [163]. Notably, the innovative 4DFlowNet, introduced in [164], demonstrates the capability to enhance the spatial resolution of 4D flow MRI, showing its effectiveness in both phantom and actual patient data.

Aortic Dissection, as detailed in [165], is a critical condition characterized by a tear in the aorta’s inner wall. This tear permits blood flow between the layers of the aortic wall, potentially causing separation of these layers and the formation of a false lumen. Aortic dissection typically presents with abrupt and severe chest or back pain and is a medical emergency requiring immediate attention. Its life-threatening nature demands prompt treatment. For further insights into AI’s role in aortic dissection imaging, refer to the comprehensive review [166]. This review sheds light on three key aspects: the processes involved in screening for aortic dissection, the application of image segmentation techniques, and the use of predictive analytics in determining patient outcomes. The review encapsulates the significant advancements AI has made in the field, providing a thorough understanding of its applications in diagnosing and managing aortic dissection.

### 3.3.2 Coronary Arteries

Coronary arteries, as illustrated in Figure 2 (e), play a crucial role in the human circulatory system by delivering oxygen-rich blood to the heart muscle [167], [168], [169], [170], [171]. These arteries branch out from the aorta—the body’s main artery—and envelop the heart, forming an extensive network of vessels essential for cardiac function. Diseases affecting the coronary arteries can lead

to myocardial ischemia, a condition characterized by reduced blood flow to the heart muscle [172], [173], [174]. Chronic ischemia or its associated complications can progressively impair the heart's pumping efficiency, posing significant health risks [175]. Early detection and timely medical intervention are crucial for conditions related to coronary arteries, as they can be life-threatening if left unaddressed [176].

In the subsequent discussion, we delve into the realm of AI-driven analysis of diseases associated with coronary arteries. This exploration includes a comprehensive overview of the latest AI methodologies applied in the detection, diagnosis, and management of coronary artery diseases.

**Coronary Artery Diseases (CAD).** CAD, the most prevalent form of heart disease, arises when coronary arteries are narrowed or blocked due to fatty plaque buildup [181]. This condition can significantly reduce or completely obstruct blood flow to the heart, leading to angina, manifested as chest pain or discomfort. CAD may also precipitate a heart attack, or myocardial infarction, where a part of the heart muscle sustains damage or death due to insufficient blood supply [182].

Advanced stages of CAD often necessitate invasive treatments like Percutaneous Coronary Intervention (PCI) or coronary angioplasty, which involve widening narrowed arteries using a balloon device and potentially placing a stent to keep the artery open. In more severe cases with multiple blockages, Coronary Artery Bypass Grafting (CABG) surgery might be performed, creating alternative pathways for blood flow using vessels from other parts of the body [183]. Timely and effective management of CAD is crucial. Below, we discuss significant research challenges associated with CAD.

Over the years, AI techniques have become extensively utilized in the field of Coronary Artery Disease detection [184]. For example, Coronary Artery Stenosis is a predominant structural concern in coronary arteries. The detection, characterization, and monitoring of stenosis severity and plaque development are vital, as these conditions can lead to serious events like heart attacks [82]. Medical imaging is central to these tasks [168], [169], [185], [186], [187], [188], [189], [190]. Notably, interpretations of coronary computed tomography angiography (CTA) by less experienced clinicians often overestimate the severity of stenosis compared to expert analyses [49]. AI solutions present a promising alternative. A recent study [191] assessed AI-augmented quantitative coronary computed tomography (AI-QCT) angiography for detecting and grading coronary stenoses.

**Coronary Flow Reserve (CFR) in Cardiac Assessment.** CFR is an essential measure in cardiology, gauging the coronary arteries' capacity to augment blood flow in response to increased cardiac demand, as depicted in Figure 5 (d). This metric is particularly useful in evaluating patients who exhibit ischemic symptoms without significant stenosis, helping to guide decisions on revascularization or medication management. CFR's estimation can be achieved non-invasively through Transthoracic Doppler Echocardiography, MRI, and PET, offering a safer alternative for certain patient groups [192]. Unlike Fractional Flow Reserve (FFR) that evaluates the significance of arterial narrowing, and the Index of Microcirculatory Resistance (IMR) that measures microcirculation resistance, CFR provides an overarching view of the entire coronary circulatory system's flow capacity, encompassing both large and small vessels. Typically, CFR is assessed through invasive coronary catheterization, where blood flow velocity is measured at rest and during induced hyperemia using specialized

Doppler guidewires or pressure sensors.

**Fractional Flow Reserve (FFR) in Coronary Assessment.** FFR is an index for quantifying blockage severity in coronary arteries, typically determined through invasive catheter-based methods, as illustrated in Figure 2 (e). However, modern approaches are exploring non-invasive FFR estimation, using anatomical data from CT scans of the heart and coronary arteries. Despite their promise, these methods, mainly physics-based models, face challenges due to high computational demands, limiting their routine clinical application.

With the integration of computational AI, there's a growing interest in developing non-invasive FFR estimation techniques from medical imaging modalities like coronary computed tomography angiography (CCTA). These AI-driven methodologies are aimed at circumventing the need for invasive procedures, making CAD assessment more patient-friendly and efficient. As seen in Figure 5 (c, d), a typical AI-powered FFR analysis workflow includes segmentation of coronary arteries within CTA images to delineate their anatomical structure [193], [194], [195]. This process is often supplemented with automated branch labeling systems [196], enhancing lesion localization accuracy in coronary arteries [83], [197], [198], [199]. The culminating step involves leveraging deep learning models, trained on the segmented and labeled structural and functional features, to predict FFR. These AI models present a compelling alternative to traditional physics-based methods, offering potentially quicker and equally accurate FFR estimations [200], [201].

**Coronary Microvascular Disease (CMVD).** CMVD disease within the coronary circulatory system, particularly affecting the microvasculature, can lead to clinical events in patients without obvious epicardial coronary stenosis [202]. CMVD specifically targets the heart's small blood vessels or microcirculation, often resulting in symptoms like chest pain and shortness of breath, though it can also be asymptomatic. Unlike obstructive coronary artery disease, which impacts larger vessels, CMVD involves reduced blood flow through these microvessels (See Figure 5 (d)). Traditional angiography typically fails to detect CMVD, as it mainly visualizes larger coronary arteries, necessitating alternative diagnostic approaches.

**Index of Microcirculatory Resistance (IMR) in Microvascular Assessment.** IMR serves as a key invasive metric for directly evaluating coronary microvascular function. This index is obtained using specialized pressure and temperature-sensitive wires, similar to those used in FFR measurements. It's crucial to recognize that high FFR values, typically above 0.80, do not entirely rule out the risk of future clinical events. Patients with high FFR readings may still experience clinical issues, emphasizing the need for comprehensive assessments beyond FFR [23].

IMR is particularly insightful for diagnosing microvascular dysfunction, proving valuable in both stable patients and those with acute or recent MI [203]. Despite its utility, the medical field still seeks reliable and non-invasive quantitative techniques for diagnosing CMVD. Developing such methods is essential for selecting appropriate treatments for coronary artery disease and improving coronary microcirculation outcomes [204]. Innovation in this area includes the recent introduction of a novel parameter, 'caIMR,' aimed at characterizing the physiological effects of microcirculatory dysfunction [205]. This novel metric potentially offers critical insights into microvascular diseases, enhancing patient evaluation and treatment strategies. The application of 'caIMR' could represent a significant advancement in understanding and

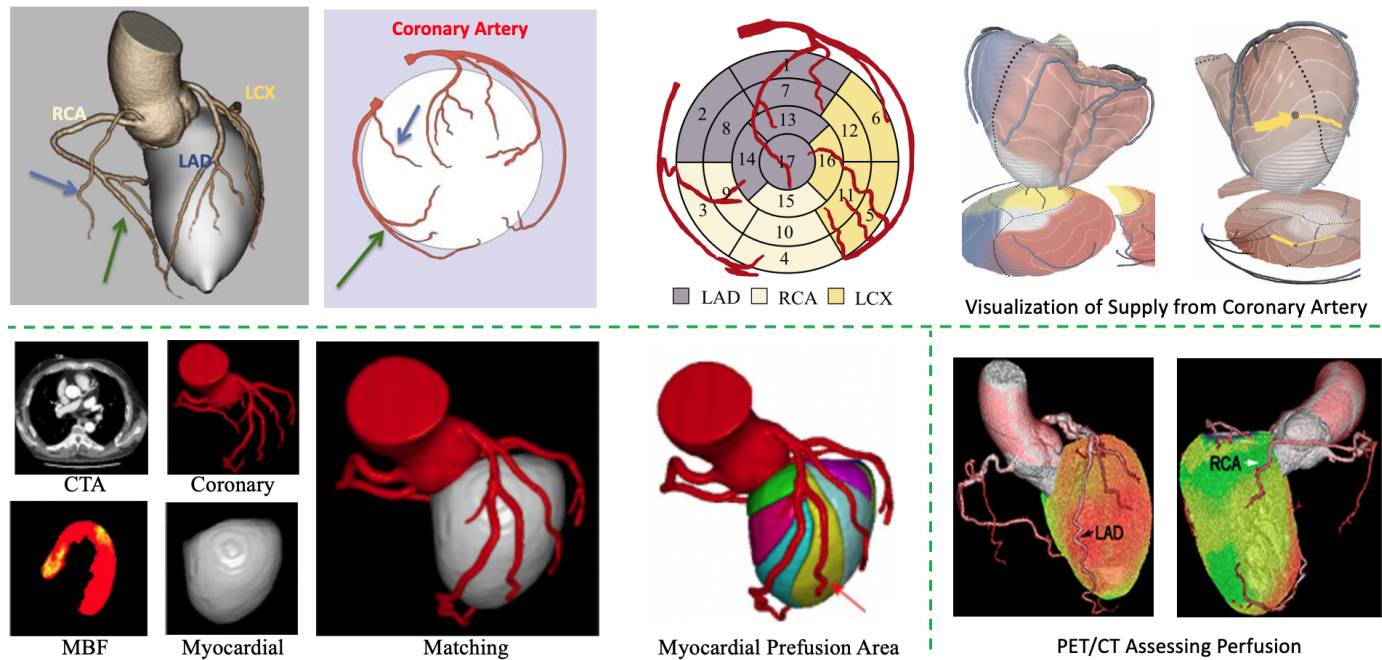


Fig. 6: Examples of connections of non-vessel and vessel structures. **Top:** An relation example of the Coronary Artery with corresponding LV regions for providing blood. (LAD: left anterior descending; RCA: right CA; LCX: left circumflex) [3], [177] and Visualization of Myocardial Perfusion from Coronary Anatomy [178]. **Bottom (left):** Determination of Myocardial Perfusion Territory [179]. **Bottom (right):** PET/CT assessing perfusion and Coronary Artery anatomy [180].

managing microvascular conditions.

### 3.4 Connections between Non-vessel and Vessel Structures

The heart’s functionality is intricately dependent on both its non-vessel and vessel structures. Understanding the interplay between these two types of structures is pivotal for a holistic comprehension of cardiac function, specifically how structural integrity and blood supply interact.

As illustrated in Figure 6 (Top), the myocardium’s dependency on a continuous supply of oxygen and nutrients, primarily delivered by the coronary arteries, is a key aspect of cardiac function. Disruptions in this supply, such as from atherosclerosis or thrombosis in the coronary arteries, can result in myocardial ischemia or infarction, impairing the heart’s pumping efficiency [3]. Conversely, changes in non-vessel structures, like ventricular hypertrophy or valvular diseases, can influence the heart’s blood demand and workload, subsequently affecting coronary circulation. For instance, ventricular hypertrophy heightens the myocardium’s oxygen needs, which can lead to an imbalance if the coronary arteries are unable to meet this increased demand.

There exists a dynamic feedback loop between myocardial performance and coronary vessel health. For example, myocardial damage from infarction can alter blood flow dynamics, impacting cardiac output and the stress on coronary vessels [177]. The cardiac cycle involves myocardial contraction and relaxation, as well as valve operation, all of which are vital for effective blood propulsion through the coronary vessels and into systemic circulation. Structural or functional abnormalities in these non-vessel components can hamper blood circulation efficiency, thereby affecting overall cardiac function [63]. As shown in Figure 6 (Bottom), the myocardial computed tomographic perfusion

(CTP) derived fractional flow reserve (CTP-FFR) models have been initially established [179], [180]. The models demonstrate superior diagnostic capabilities for coronary artery disease (CAD), particularly in cases of mild to moderate stenosis.

A recent work developed a multiscale, patient-specific model to enable blood flow simulation from major coronary arteries down to myocardial tissue [206]. Specifically, a stand-alone coronary model and an integrated coronary-myocardium coupled model were developed and examined with the objective of simulating myocardial perfusion under both healthy and pathological conditions. The patient’s vasculature is initially segmented from coronary computed tomography angiography data and then extrapolated to the arteriole level using a network of synthetic trees. Then, the CTP-FFR blood flow is modeled by integrating a coronary artery model with a single-compartment Darcy myocardium model for the joint hyperemic Myocardial Blood Flow (MBF) for the coupled model. Finally, the predicted and true perfusion maps are compared. This work represents an instance of a computational model simulating blood flow from epicardial coronary arteries to the left ventricle myocardium, applied and validated using human data.

Currently, the application of AI in comprehensively understanding the connection between non-vessel and vessel structures remains limited. However, such understanding is critical for diagnosing and treating cardiac diseases, as it aids in identifying the root causes of cardiac dysfunction, informs surgical intervention planning, and supports long-term cardiac health management strategies.

## 4 POPULATION IMAGE-BASED CVD ANALYSIS

Our exploration in this section delves into understanding cardiovascular diseases (CVDs) through detailed population-based imaging studies, utilizing AI and statistical tools. We address the



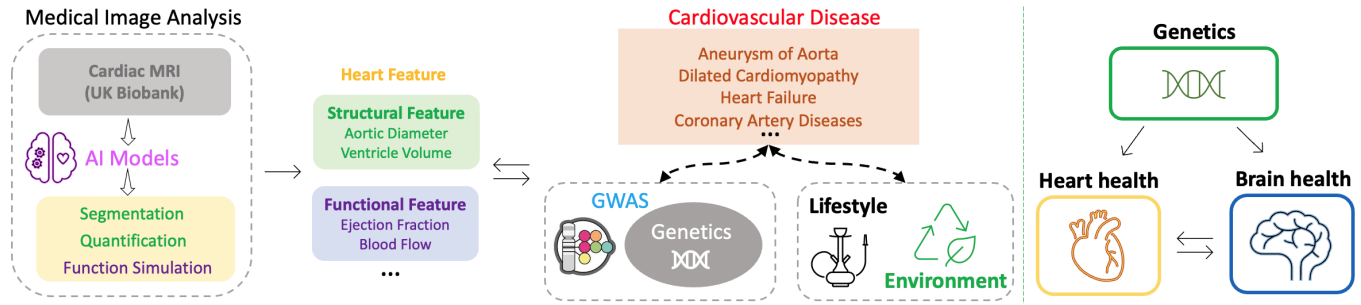


Fig. 7: **Left:** Cardiac Imaging Genetic Analysis Pipeline: This diagram illustrates the process of extracting detailed features of heart structure and function using AI models from cardiac imaging data, followed by the exploration of endophenotypic and genetic associations through Genome-wide association studies (GWAS), with a consideration of lifestyle and environmental factors. **Right:** Overview of the study, which used Cardiovascular magnetic resonance (CMR) and brain MRI traits as endophenotypes to explore the phenotypic and genetic connections between the heart and the brain [16].

diversity of CVDs, encompassing various disorders like coronary artery disease, heart failure, and arrhythmias, each with its own clinical and pathophysiological traits. Acknowledging the significant influence of lifestyle and behavioral factors on these diseases, our focus extends to how these elements, along with genetics and age, shape CVD risks [207]. We aim to construct temporal Causal Genetic-Imaging-Clinical (CGIC) pathways to examine the causal relationships between genetic predispositions, cardiac imaging features, and clinical outcomes in CVDs. This integrative approach is designed to deepen our understanding of CVD etiology and to enhance strategies for prevention, diagnosis, and treatment.

#### 4.1 Cardiac Imaging Genetics

The intricate genetic architecture of CVDs has been elucidated through numerous genome-wide association studies (GWAS) over the past decade and a half, highlighting the interplay of genetic and environmental factors in these diseases. Studies cataloged in the GWAS Catalog [208] reveals that nearly 1,700 studies on 450 CVD-related phenotypes have been conducted. This research has advanced our understanding of cardiovascular biology and pathophysiology, uncovering complex interactions between genetic and non-genetic risk factors. Overall, these studies underline the importance of continued exploration into the genetic basis of CVDs to enhance prevention, diagnosis, and treatment strategies.

Heritability estimates for CVDs vary across different conditions. For instance, Coronary Heart Disease and some arrhythmias like atrial fibrillation have heritability estimates between 40-60%. A study on twins estimated the heritability of atrial fibrillation to be as high as 62% [209], indicating a strong genetic component. Similarly, hypertension shows a heritability of about 30-50%. While heart failure and stroke also have significant heritability, the extent varies depending on the type and associated conditions.

Case-control GWAS is the most direct method to discover common genetic risk factors underlying disease. GWAS initially focused on common complex diseases like Coronary Artery Disease (CAD) and myocardial infarction (MI), atrial fibrillation (AF), heart failure, stroke, and hypertension. For instance, although the heritability of CAD/MI is estimated to be around 40-50%, only about 30% of this heritability is explained by the currently identified Single Nucleotide Polymorphisms (SNPs) [210], [211]. This suggests that there are still genetic factors of CAD/MI yet to be discovered.

For more rare cardiovascular conditions, GWAS have begun to reveal the role of common genetic variants as either modifiers of disease penetrance and severity in cases with rare Mendelian variants or as substantial contributors to overall disease risk in non-Mendelian cases [212], [213]. This highlights the need for further research and collaboration in understanding these diseases.

The development of Polygenic Risk Scores (PRS), which summarize the aggregate effect of all identified risk variants for a disease, has been a notable advancement. PRS have shown potential for risk stratification, especially when combined with traditional risk factors [214]. However, the integration of PRS into clinical practice requires further research to understand its benefits and workflows.

Imaging genetics in CVDs integrates advanced imaging and genetic analysis to decode the genetic underpinnings of heart conditions [215], [216]. This field examines the impact of genetic variations on cardiovascular traits observed through medical imaging, such as MRI or CT scans, facilitating the identification of genetic markers linked to CVD development and progression. An overview of the heart imaging genomics pipeline is shown in Figure 7 (left). This method proves invaluable for complex diseases like heart failure, coronary artery disease, and arrhythmias, aiding in early risk detection, understanding disease mechanisms, and tailoring treatment strategies to individual genetic profiles.

The inclusion of cardiac structural and functional measures in CGIC pathways is justified by three key factors. Firstly, genetic variations more significantly influence cardiac imaging traits than the broader, more heterogeneous categories of behaviorally defined diseases (e.g., Ischemic heart disease, heart failure, and hypertensive heart disease). Secondly, understanding the genetic variations related to cardiac changes enhances our grasp of the mechanisms that predispose individuals to such behaviorally defined disorders. Thirdly, the difficulty in gathering sufficiently large cohorts for rare diseases makes the study of disease-relevant endophenotypes in large biobank cohorts essential for discovering genetic influences on these rare conditions.

The enhanced power of ECG trait GWAS to detect substantially more genetic associations compared with rare disease case-control studies may provide more informative PRS, new insights into disease mechanisms and pathways, and the potential to identify novel Mendelian disease genes or drug targets.

Recent GWAS have analyzed numerous ECG quantitative traits across tens of thousands of individuals, leading to the

identification of hundreds of significant genetic associations [217], [218]. These studies have focused on traits crucial for cardiac functions, such as heart rate, PR interval, QRS duration for cardiac conduction, and QT interval for repolarization. The significant findings in these GWAS have underscored the importance of endophenotype GWAS in understanding cardiac diseases, especially when strong signals are identified at genes known to be associated with arrhythmias, suggesting these may be the causal genes. For instance, variations at key Long QT Syndrome (LQTS) genes like *KCNQ1*, *KCNH2*, and *SCN5A* have shown strong associations with the QT interval, and *SCN5A* with PR and QRS traits as well, linking these to both common and rare cardiac conduction diseases. The correlation between the effect sizes for QT interval-associated Single Nucleotide Polymorphisms (SNPs) in the general population and disease risk in LQTS highlights the relevance of such studies. The ability of ECG trait GWAS to uncover more genetic associations compared to rare disease case-control studies may enhance PRS, provide new insights into disease mechanisms, and potentially identify novel Mendelian disease genes or drug targets.

In cardiomyopathies, the key endophenotypes involve traits that delineate the heart's structure and function, best assessed via advanced imaging as discussed in Sections 2 and 3. The recent availability of large-scale datasets (e.g., the UK Biobank (UKB)) marks significant progress, despite the complexity and cost associated with these techniques. The critical endophenotypes for Hypertrophic Cardiomyopathy (HCM) and Dilated Cardiomyopathy (DCM) concern the left ventricle (LV), including its mass and wall thickness, myocardial deformation, volumes, and functional measures such as ejection fraction. Compared with traditional cardiomyopathy case-control studies, initial imaging genetics analyses have uncovered numerous genome-wide significant associations [219], [220]. It's notable that many loci are linked with multiple LV traits, underscoring their genetic and phenotypic correlation. Importantly, some loci are proximal to established Mendelian cardiomyopathy genes, like *TTN* and *PLN*, reinforcing the endophenotypes' relevance in uncovering biological processes common to cardiomyopathies. PRS based on LV endophenotypes have shown predictive value for heart failure and DCM in UKB subsets.

Pirruccello et al.'s [221] pioneering study leveraged deep learning to analyze left atrial characteristics from cardiovascular MRI scans of over 40,000 UKB participants, focusing on key metrics such as minimum and maximum volumes, stroke volume, and emptying fraction. Their subsequent GWAS on individuals without prior cardiovascular conditions revealed 20 genetic loci associated with LA traits, illuminating the genetic underpinnings of LA structure, function, and atrial fibrillation risk. Another study by the same group extended this methodology to the right heart chamber, identifying and measuring the right atrium, ventricle, and pulmonary artery [222]. This comprehensive analysis identified 130 genetic loci associated with right heart measurements, some near genes linked to congenital heart disease, and highlighted the potential of genome-wide polygenic predictors in understanding the genetic basis of right heart structure and function, offering new insights into cardiovascular diseases and their treatment.

A recent study [223] introduced groundbreaking findings on the relationship between CMR measured Pericardial Adipose Tissue (PAT) and various cardiovascular structure and function indicators. The study analyzed PAT data from over 42,000 UKB participants. It delved into the connections between PAT and

the risk factors for heart failure, ischemic heart disease (IHD), adverse LV adiposity, and AF. Significantly, this research sought to ascertain whether these associations remain distinct from conventional vascular risk factors and different obesity measures, including body metrics, impedance-based fat assessments, and MRI evaluations of abdominal visceral fat.

A new study [245] embarked on uncovering the genetic factors that influence the dimensions of key cardiovascular structures, including the left ventricular outflow tract (LVOT), aortic root, and ascending aorta, noted for their complex structure and unique developmental origins. The study meticulously measured diameters at specific points within these structures to conduct GWAS aimed at identifying associated genetic variants. Furthermore, the study by Aung [246] delved into the genetic basis of RV structure and function. This research, involving 29,506 UKB participants and leveraging cardiovascular MRIs analyzed by advanced deep learning algorithms, identified 25 unique genetic loci associated with RV phenotypes. Notably, some candidate genes were found to overlap with genes linked to Mendelian cardiomyopathy, shedding light on their roles in cardiac muscle contraction and cellular adhesion. Additionally, the study highlighted the association of RV PRS with DCM and CAD, offering new insights into the genetic foundations of RV-related cardiac conditions.

In summary, utilizing AI models allows for exploring intricate relationships between genetic variations and imaging characteristics, facilitating the identification of new associations and the creation of improved predictive models. AI algorithms can effectively amalgamate genetic and imaging data, enabling the delineation of distinct disease subtypes grounded in both genetic profiles and imaging attributes [247].

## 4.2 Lifestyle and Environmental Factors

The analysis of population-based data illuminates the complexities and prevalence of cardiovascular conditions, highlighting the multifaceted influences on heart health (See Figure 7 (left)). This includes genetic predispositions, lifestyle choices such as diet and physical activity, and environmental factors, all contributing to cardiovascular risk profiles [248], [249], [250]. Modern genomics connects genetic markers to heart health changes, while demographic factors like age and gender add another layer to cardiovascular risks. Integrating cardiovascular imaging with data on lifestyle, genetics, demographics, and environmental factors facilitates a holistic view of heart health, enabling tailored and more effective cardiovascular interventions [251].

Environmental influences, ranging from geographic location changes to lifestyle adaptations, air pollution, and social policies, significantly affect cardiovascular health [248], [249], [250]. The interplay between the natural environment, including aspects like sunlight exposure and green spaces, and the social environment, characterized by urbanization, pollution, and social networks, shapes lifestyle choices that impact cardiovascular risks. A comprehensive understanding of these interactions is crucial for devising innovative prevention and treatment strategies, addressing the global challenge of cardiovascular diseases. Advancements in AI and imaging genetics are poised to enhance our understanding of these complex relationships, offering promising avenues for research and clinical practice in cardiovascular health.

## 4.3 Interactions between Heart and Other Organs

The integration of AI in analyzing cardiovascular diseases through imaging techniques has significantly advanced our understanding

Dataset	Target	Task	Year	Modality	Disease
LAScarQS [224]	LA, LA Scar	Segmentation	2022	LGE MRI	Atrial fibrillation, etc
CMRxMotion [225]	LV, Myo	Segmentation	2022	MRI	Respiratory Motion, etc
MyoPS 2020 [226]	LV, RV, Myo	Segmentation	2020	Cine MRI	Myocardial Infarction, etc
MSD Cardiac [227]	LA	Segmentation	2019	MRI	CVD, Atrial fibrillation, etc
MM - Whole Heart Segmentation [228]	Whole Heart	Segmentation	2019	MRI, CT	Atrial fibrillation, etc
CAMUS [24]	LV LA	Segmentation	2019	2D Ultrasound	ejection fraction
Atria Segmentation challenge [229]	LA	Segmentation	2018	LEG MRI	Atrial fibrillation
Left Ventricle Full Quantification Challenge [230]	LA	Quantification	2018	Cine MRI	General CVD
ACDC, MICCAI challenge [231]	LV, RV, Myo	Segmentation	2017	Cine MRI	Myocardial infarction, etc
HVSMR, MICCAI workshop [232]	Blood pool, Myo	Segmentation	2016	3D MRI	Congenital heart defects
CETUS, MICCAI challenge [233]	LV	Segmentation	2014	3D Ultrasound	Myocardial infarction
Left Atrial Segmentation challenge [234]	Left Atrial	Segmentation	2013	3D MRI	General CVD
Left Ventricle Infarct Segmentation [235]	Left Ventricle	Segmentation	2012	LGE MRI	Ischemic cardiomyopathy
CDEMRIS fibrosis scar challenge [236]	LA fibrosis and scar	Segmentation	2012	LGE MRI	Atrial fibrillation
Right Ventricle Segmentation challenge [237]	RV	Segmentation	2012	Cine MRI	Myocarditis, etc
LV Segmentation Challenge (LVSC) [238]	LV, Myo	Segmentation	2011	Cine MRI	Coronary artery disease, etc
Cardiac Atlas Project (CAP) [239]	Whole Heart	Multi-tasks	2011	MRI	General CVD
CardioVascular Research Grid (CVRG) [240]	Whole Heart	Multi-tasks	2011	Multi-modality	General CVD
Sunnybrook Cardiac Data [241]	LV, Myo	Segmentation	2009	Cine MRI	Hypertrophy, heart failure, etc
York [242]	LV, Myo	Segmentation	2008	Cine MRI	Cardiomyopathy, etc
Aortic Stiffness 4D Flow (AS4DF) [243]	Aorta	Hemodynamics	2021	MRI	Arterial Hypertension, etc
ImageCAS [195]	Coronary artery	Segmentation	2022	CTA	Vessel stenosis, etc
CLS12 [103]	Coronary artery	Segmentation	2012	CTA	Stenosis Analysis
Coronary Artery Tracking Challenge [244]	Coronary artery	Segmentation	2008	CTA	Calcium Analysis

TABLE 1: Summary of public cardiac image datasets on cardiac image analysis. **Top:** Non-vessel structures and **Bottom:** Vessel structures.

of the heart’s connections with other bodily organs and systems. This comprehensive approach enables the identification of complex interrelations, such as the cardiovascular system’s impact on neurological health, and vice versa. For instance, AI algorithms are instrumental in analyzing cerebral blood flow and detecting stroke risks, providing insights into the cardiovascular origins of neurological events.

As shown in Figure 7 (right), a notable study [16] leveraging multiorgan MRI data from a large cohort has illuminated the phenotypic and genetic connections between cardiovascular health and brain attributes. This research has identified genomic loci that influence both heart and brain characteristics, suggesting a shared genetic foundation for cardiovascular and neurological conditions. Such findings underscore the potential of heart conditions to contribute causally to brain disorders, offering new perspectives on human health.

AI’s role extends beyond mere data analysis; it facilitates the extraction of critical insights from imaging data, encompassing the heart and its systemic interactions. By employing advanced AI techniques and multimodal data fusion, these models enhance the detection and quantification of abnormalities. This not only aids in accurate diagnosis and risk assessment but also enriches treatment strategies for cardiovascular diseases. The amalgamation of AI with extensive patient data, including imaging and clinical records, presents a holistic view of the cardiovascular system’s interplay with other organs, thereby promising to improve patient care and outcomes significantly.

## 5 PUBLIC DATASETS AND CODE

In recent years, several notable large-scale public image datasets for cardiovascular research have been made available, fostering collaboration and innovation in this domain.

### 5.1 Public Datasets

Public datasets are invaluable for advancing AI in cardiac imaging by providing diverse, annotated data crucial for developing and testing algorithms. These resources facilitate collaborative efforts, benchmarking, and the sharing of innovative solutions across the research community, propelling the field forward. The accessibility of such datasets not only enhances model training and validation processes but also plays a pivotal role in the seamless integration of AI technologies into clinical settings, thereby elevating the standard of patient care.

The table below (Table 1) categorizes available public datasets based on their focus areas and the dates they were made available. In the sections that follow, we delve into the specifics of selected datasets, offering insights into their composition, applications, and impact on cardiovascular disease research.

**UKB [258].** The UK Biobank (UKB) stands as a monumental biomedical database, offering genetic and health data from half a million UK participants, making it a cornerstone for research on prevalent and life-threatening diseases. It includes cardiac MRI among other imaging data, making it a treasure trove for AI-driven cardiovascular research.

**Automatic Cardiac Diagnosis Challenge (ACDC) [231].** The ACDC dataset is tailored for benchmarking cardiac diagnosis and segmentation algorithms, featuring cardiac MRI scans from diverse cardiovascular conditions, annotated for left ventricle contours, thus facilitating the development of precise AI segmentation and diagnostic tools.

**Multi-Ethnic Study of Atherosclerosis (MESA) [259].** The Multi-Ethnic Study of Atherosclerosis (MESA) dataset, renowned in cardiovascular research, includes MRI scans from a broad demographic, paired with extensive clinical data, enabling in-depth studies on conditions like coronary artery disease and aiding in the advancement of AI diagnostic algorithms.

**Cardiac Acquisitions for Multi-structure Ultrasound Segmentation (CAMUS) [24].** The CAMUS contains 2D echocar-



Modality	Target	Task	Method	Code repo
Cine MRI	LV, RV, Myo	Cardiac Segmentation and Automated Diagnosis	Fully Convolutional Multi-scale Residual DenseNets	[252]
Cine MRI	LV, RV, Myo	Cardiac Segmentation	Deep Fully Convolutional Network	[253]
Cine MRI	LV, RV, Myo	Cardiac Segmentation	2D and 3D Deep Learning Techniques	[254]
Cine-MRI	LV	Left Ventricle Segmentation and Quantification	Spatio-temporal Multi-task Learning	[255]
Cine-MRI	WH	Synthesis of Myocardial Velocity	hybrid deep learning digital twin framework	[256]
LGE-CMR	LV	Cardiac Segmentation	V-Net	[257]

TABLE 2: Overview of Some Representative Publicly Available Resources for Cardiac Image Analysis.

diographic sequences with two and four-chamber views of 500 patients. The size of this dataset and its tight connection to everyday clinical issues give the possibility to train AI methods to automatically analyze echocardiographic data. In addition, CAMUS includes manual expert annotations for the left ventricle endocardium (LVEndo), the myocardium (epicardium contour more specifically, named LVEpi) and the left atrium (LA).

**Aortic Stiffness 4D Flow (AS4DF)** [243]. The AS4DF data includes MRI data of a subject-specific thoracic aorta model embedded into a physiological flow circuit. The aorta model was manufactured using compliant 3D-printing technology. Multiple imaging experiments were performed on multiple models that differed regarding wall compliance. The acquired data includes 2D phase contrast, 2D gradient echo cine, 3D spoiled gradient echo, and 4D flow (at three temporal resolutions).

**Coronary Artery Calcium (CAC)** [260]. The CAC datasets consist of CT scans of the coronary arteries, focusing on the identification and quantification of coronary artery calcification. These datasets provide valuable information for assessing cardiovascular risk and diagnosing coronary artery disease. They facilitate the development of AI algorithms for automated calcium scoring and the prediction of cardiovascular events.

**Cardiac Atlas Project (CAP)** [261]. CAP is a global consortium and an online platform dedicated to the integration and sharing of cardiac imaging examinations. It encompasses parametric model-based functional analyses and related clinical data. The initiative has led to the creation of an extensive database featuring a wide range of cardiac imaging examinations, associated models, and derived measurements. The primary aim is to develop a comprehensive, web-accessible atlas that delineates both the normal and diseased states of the heart’s structure and function, serving clinical, research, and educational needs [239].

**CardioVascular Research Grid (CVRG)** [240]. CVRG is a collaborative platform designed to advance cardiovascular research by facilitating the sharing and integration of data across the field. It provides researchers and clinicians with access to an extensive database, encompassing a wide range of cardiovascular data including imaging studies, clinical information, and research findings. This platform not only accelerates the understanding and treatment of heart diseases but also contributes to the development of personalized medicine in cardiology. By centralizing resources and fostering a global research community, the CVRG plays a crucial role in informing clinical practices and advancing global health initiatives related to cardiovascular diseases [262].

## 5.2 Public Code

The adoption of AI in cardiac image analysis necessitates transparency, accessibility, and the establishment of trust. Public code repositories address these requirements by making AI algorithms’ codebase and datasets openly available. This transparency allows for the thorough examination of methodologies and validation

of model performance, ensuring that AI solutions operate as intended. Moreover, public code underpins the principle of reproducibility in scientific research, permitting independent verification of results from AI-based cardiac image analysis.

Open collaboration, enabled by public code, fosters rapid advancements in the field. It invites contributions and enhancements from a global community of experts, thereby improving the efficacy and accuracy of AI algorithms over time. To facilitate this collaborative effort, public code is organized by specific tasks, such as segmentation, detection, regression, or classification. See Table 2. This categorization simplifies access for researchers and developers, promoting further innovation and development in AI-driven cardiac image analysis.

## 6 FUTURE DIRECTIONS

While significant progress has been made in leveraging AI for image-based CVD analysis, there are still several avenues for future research and development. We discuss several promising directions, and the overview is illustrated in Figure 8.

**Precision Medicine in Cardiology.** Precision medicine is revolutionizing healthcare by customizing medical treatments to each individual’s unique genetic makeup, environmental factors, and lifestyle. This approach has the potential to dramatically transform how we diagnose, track, and treat diseases [263]. A particularly promising area is the application of AI in integrating heart medical imaging with other modalities, like genomics, proteomics, and metabolomics, to improve clinical decision-making and disease management [264]. This integration offers a more comprehensive understanding of a patient’s health status, but also raises challenges such as data privacy, ethical considerations in the use of personal health information, and the need for stringent validation of AI predictions to ensure reliability and safety [265].

**Digital Twins (DT) of Heart.** The goal of creating a digital twin of the heart is to facilitate tailored and precise treatments for cardiovascular diseases [266]. The process involves collecting a wide array of patient data, including advanced imaging, genetic profiles, and physiological metrics [267]. These data points are synthesized using sophisticated AI techniques to construct a dynamic, virtual model of the patient’s heart, reflecting its detailed anatomy and functions [268]. The DT model enables simulations to test various therapeutic strategies, offering insights into the most effective treatments. It’s continuously updated with new patient data, allowing for real-time health monitoring and enabling informed clinical decisions to adjust treatments as needed. Digital twins of the heart offer significant benefits by enabling healthcare professionals to test and refine treatment strategies in a risk-free environment [269]. This innovative approach can lead to safer patient care, lower healthcare costs, and improved outcomes. Additionally, digital twins have the potential to spur new therapeutic discoveries and enhance our understanding of cardiovascular diseases [270]. However, their widespread implementation faces hurdles such

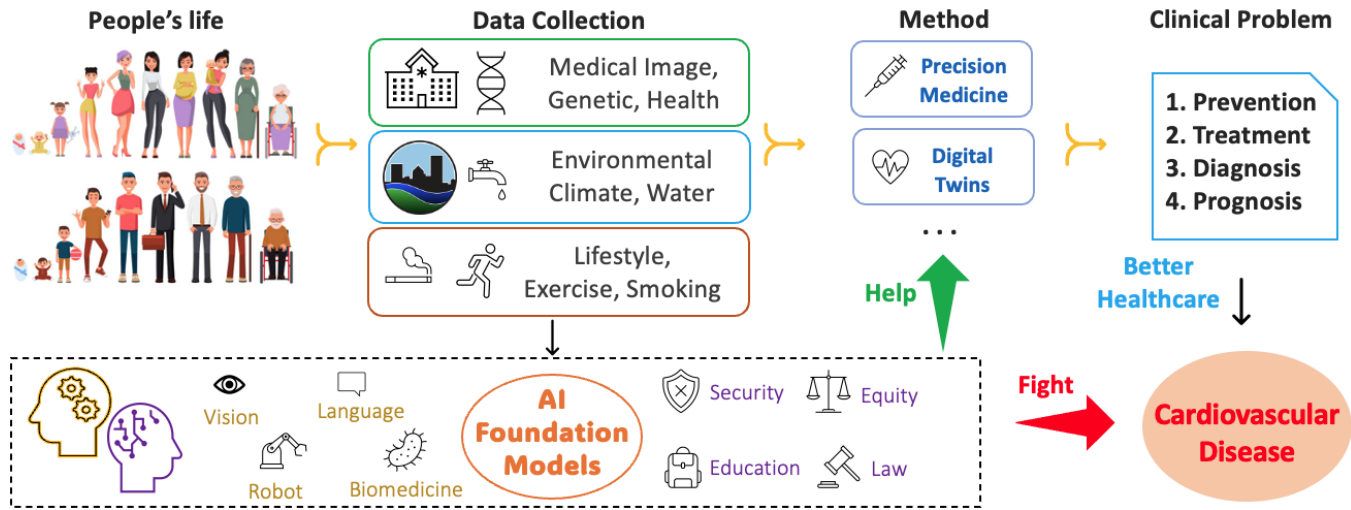


Fig. 8: Exploring the future with AI Foundation Models: Harnessing medical imaging as the core modality alongside auxiliary data for clinical innovation and combating cardiovascular diseases through precision medicine and digital twin technologies.

as ensuring data privacy, meeting computational demands, and achieving model accuracy.

**AI-based Cardiac Image Generation.** Digitally Reconstructed Radiographs (DRR) serve as a pivotal technique in medical imaging, simulating X-ray images from 3D medical data such as CT or MRI scans, thereby reducing unnecessary radiation exposure for patients [271]. The integration of advanced deep learning models, including 3D convolutional neural networks, GANs [69], variational autoencoders [272], and diffusion model [118], [273] enhances the reconstruction quality but demands considerable computational resources and extensive training data [274]. The advent of Neural Radiance Fields (NeRF) has brought significant advancements in natural image reconstruction, though their application in medical imaging remains challenging due to the complexity of medical data [275]. Innovations like Medical image NeRFs [276], [277] are making strides by learning to map radiance values to pixels, revealing intricate details of internal anatomy from 2D images, and offering potential for reducing radiation risks and examination costs, especially in orthopedics and surgery.

**Explainable CVDs Diagnosis Models with LLMs.** Large Language Models (LLMs) hold significant promise in revolutionizing the diagnosis of CVDs, the leading global cause of mortality. By leveraging their vast data processing capabilities, LLMs can substantially improve diagnostic precision. However, the opaque nature of these models raises concerns about transparency and trust among medical professionals and patients [278]. To address this, it's crucial to incorporate explainability into LLMs, ensuring they not only deliver accurate diagnoses but also provide comprehensible rationales for their decisions [279], [280], [281]. Enhancing the explainability of LLMs [282] involves creating or improving interpretability methods tailored to medical diagnostic needs. This step is essential for the models' acceptance and practical application in healthcare. Moreover, thorough real-world clinical validations are imperative to confirm the model's dependability and effectiveness across various healthcare applications.

**AI Foundation Models for Heart Health.** AI is increasingly becoming the primary approach for analyzing CVD through imaging, aiming to reduce costs and the reliance on invasive

procedures [194], [197], [201]. AI algorithms have been developed for tasks such as disease classification, risk prediction, treatment planning, and clinical decision-making in cardiovascular imaging [283]. However, most current AI approaches in this field rely on task-specific models [78], which may not fully capture the complexity and diversity of medical data due to their smaller size and task-focused design. The emergence of AI foundation models, particularly prominent in computer vision and natural language processing [284], [285], [286], [287], [288], represents a significant shift. These large-scale models, with millions or billions of parameters, are capable of handling more complex data and identifying a wide range of patterns and relationships, often achieving state-of-the-art results across various tasks due to their scalability and generalization capabilities [289], [290], [291], [292]. In cardiovascular health, foundation models have the potential to be adapted or fine-tuned for specific CVD analysis tasks [293], such as Atrial Fibrillation [20], Ischemic Heart Disease [90], and Coronary Artery Diseases [201]. Adapting these models to the diverse imaging modalities used in CVD analysis presents challenges due to the significant differences from natural images, based on various physics-based properties and energy sources [294]. A potential solution involves training foundation models on both medical and natural images through fine-tuning approaches [295], [296], aiming to provide a robust foundational solution for clinical challenges in CVD. This advancement could significantly improve the effectiveness and efficiency of diagnosing and treating cardiovascular diseases, marking a substantial step forward in the field [297]. Furthermore, developing more efficient neural network architectures is crucial for advancing foundation models. Notably, Mamba [298], a State Space Model, has emerged as a significant innovation for its adeptness at efficiently modeling long-range dependencies in sequential data, attributed to its exceptional memory efficiency and computational speed [299], [300].

## 7 CONCLUSION

The integration of AI in cardiovascular imaging is significantly enhancing diagnostic accuracy, personalized treatment planning, and early disease detection in the field of cardiology. This paper offers an in-depth examination of AI applications in cardiovascular

disease analysis through imaging, covering a range of topics from imaging modalities and processing techniques to disease-specific analysis methods. Challenges such as the collection, annotation, and standardization of large-scale datasets are discussed, emphasizing the critical role of public datasets and code repositories in promoting research collaboration and algorithm validation. The paper also sheds light on promising future directions, including imaging genetics, the concept of digital twins, and the utilization of AI foundational models, which are expected to drive substantial progress in cardiovascular imaging. Looking ahead, the paper anticipates further advancements in AI algorithms, hardware, and imaging technologies, which will lead to more precise and efficient diagnostic and treatment processes. Moreover, the integration of AI with electronic health records, genomics, and other clinical data will facilitate a comprehensive and personalized approach to cardiovascular care, aligning with the evolving landscape of patient-centered healthcare.

## ACKNOWLEDGMENT

Copyrights of the figures belong to their own authors and/or holders (sources are cited in the captions). The author sincerely thanks all readers for taking the time to read the manuscript. If any related work has been overlooked, please do not hesitate to contact us. The feedback will be greatly appreciated and help us considerably improve this survey.

Xin Wang is supported by SUNY at Albany Start-up Grant. The research of Dr. Hongtu Zhu is partially supported by the National Institute on Aging (NIA) of the National Institute of Health (NIH) under Award Number RF1AG082938.

## REFERENCES

- [1] A. S. Update, "Heart disease and stroke statistics—2017 update," *Circulation*, vol. 135, pp. e146–e603, 2017.
- [2] F. Sun, J. Yao, S. Du, F. Qian, A. A. Appleton, C. Tao, H. Xu, L. Liu, Q. Dai, B. T. Joyce *et al.*, "Social determinants, cardiovascular disease, and health care cost: a nationwide study in the united states using machine learning," *Journal of the American Heart Association*, vol. 12, no. 5, p. e027919, 2023.
- [3] L. Li, W. Ding, L. Huang, X. Zhuang, and V. Grau, "Multi-modality cardiac image computing: A survey," *Medical Image Analysis*, p. 102869, 2023.
- [4] R. S. Vasan, "Biomarkers of cardiovascular disease: molecular basis and practical considerations," *Circulation*, vol. 113, no. 19, pp. 2335–2362, 2006.
- [5] S. A. Michelhaugh and J. L. Januzzi, "Using artificial intelligence to better predict and develop biomarkers," *Clinics in Laboratory Medicine*, vol. 43, no. 1, pp. 99–114, 2023.
- [6] P. Bizopoulos and D. Koutsouris, "Deep learning in cardiology," *IEEE reviews in biomedical engineering*, vol. 12, pp. 168–193, 2018.
- [7] C. Krittanawong, A. M. S. Omar, S. Narula, P. P. Sengupta, B. S. Glicksberg, J. Narula, and E. Argulian, "Deep learning for echocardiography: Introduction for clinicians and future vision: State-of-the-art review," *Life*, vol. 13, no. 4, p. 1029, 2023.
- [8] Y. LeCun, Y. Bengio, and G. Hinton, "Deep learning," *nature*, vol. 521, no. 7553, pp. 436–444, 2015.
- [9] S. Mascarenhas and M. Agarwal, "A comparison between vgg16, vgg19 and resnet50 architecture frameworks for image classification," in *2021 International conference on disruptive technologies for multi-disciplinary research and applications (CENTCON)*, vol. 1. IEEE, 2021, pp. 96–99.
- [10] S. K. Zhou, H. Greenspan, C. Davatzikos, J. S. Duncan, B. Van Ginneken, A. Madabhushi, J. L. Prince, D. Rueckert, and R. M. Summers, "A review of deep learning in medical imaging: Imaging traits, technology trends, case studies with progress highlights, and future promises," *Proceedings of the IEEE*, vol. 109, no. 5, pp. 820–838, 2021.
- [11] D. Shen, G. Wu, and H.-I. Suk, "Deep learning in medical image analysis," *Annual review of biomedical engineering*, vol. 19, pp. 221–248, 2017.
- [12] H. Yang, J. Pan, W. Wang, T. Guo, and T. Ma, "Application of artificial intelligence-based auxiliary diagnosis in congenital heart disease screening," *Anatolian Journal of Cardiology/Anadolu Kardiyoloji Dergisi*, vol. 27, no. 4, 2023.
- [13] B. He, A. C. Kwan, J. H. Cho, N. Yuan, C. Pollick, T. Shiota, J. Ebinger, N. A. Bello, J. Wei, K. Josan *et al.*, "Blinded, randomized trial of sonographer versus ai cardiac function assessment," *Nature*, vol. 616, no. 7957, pp. 520–524, 2023.
- [14] G. Litjens, F. Ciompi, J. M. Wolterink, B. D. de Vos, T. Leiner, J. Teuwen, and I. Išgum, "State-of-the-art deep learning in cardiovascular imaging," *JACC: Cardiovascular imaging*, vol. 12, no. 8 Part 1, pp. 1549–1565, 2019.
- [15] H.-C. Shin, H. R. Roth, M. Gao, L. Lu, Z. Xu, I. Nogues, J. Yao, D. Mollura, and R. M. Summers, "Deep convolutional neural networks for computer-aided detection: Cnn architectures, dataset characteristics and transfer learning," *IEEE transactions on medical imaging*, vol. 35, no. 5, pp. 1285–1298, 2016.
- [16] B. Zhao, T. Li, Z. Fan, Y. Yang, J. Shu, X. Yang, X. Wang, T. Luo, J. Tang, D. Xiong *et al.*, "Heart-brain connections: Phenotypic and genetic insights from magnetic resonance images," *Science*, vol. 380, no. 6648, p. abn6598, 2023.
- [17] C. Chen, C. Qin, H. Qiu, G. Tarroni, J. Duan, W. Bai, and D. Rueckert, "Deep learning for cardiac image segmentation: a review," *Frontiers in Cardiovascular Medicine*, vol. 7, p. 25, 2020.
- [18] Y. Li and Y. Fan, "Medical image segmentation with domain adaptation: A survey," *arXiv preprint arXiv:2311.01702*, 2023.
- [19] Y. Fu, Y. Lei, T. Wang, W. J. Curran, T. Liu, and X. Yang, "A review of deep learning based methods for medical image multi-organ segmentation," *Physica Medica*, vol. 85, pp. 107–122, 2021.
- [20] L. Li, V. A. Zimmer, J. A. Schnabel, and X. Zhuang, "Medical image analysis on left atrial lge mri for atrial fibrillation studies: A review," *Medical image analysis*, p. 102360, 2022.
- [21] P.-N. Jone, A. Gearhart, H. Lei, F. Xing, J. Nahar, F. Lopez-Jimenez, G.-P. Diller, A. Marelli, L. Wilson, A. Saidi *et al.*, "Artificial intelligence in congenital heart disease: Current state and prospects," *JACC: Advances*, vol. 1, no. 5, p. 100153, 2022.
- [22] M. Jafari, A. Shoeibi, M. Khodatars, N. Ghassemi, P. Moridian, R. Alizadehsani, A. Khosravi, S. H. Ling, N. Delfan, Y.-D. Zhang *et al.*, "Automated diagnosis of cardiovascular diseases from cardiac magnetic resonance imaging using deep learning models: A review," *Computers in Biology and Medicine*, p. 106998, 2023.
- [23] C. Berry *et al.*, "Fractional flow reserve, coronary flow reserve and the index of microvascular resistance in clinical practice," *Radcliffe Cardiology. Feb*, pp. 1–6, 2014.
- [24] S. Leclerc, E. Smistad, J. Pedrosa, A. Østvik, F. Cervenansky, F. Espinosa, T. Espeland, E. A. R. Berg, P.-M. Jodoin, T. Grenier *et al.*, "Deep learning for segmentation using an open large-scale dataset in 2d echocardiography," *IEEE transactions on medical imaging*, vol. 38, no. 9, pp. 2198–2210, 2019.
- [25] M. Ye, M. Kanski, D. Yang, Q. Chang, Z. Yan, Q. Huang, L. Axel, and D. Metaxas, "Deeptag: An unsupervised deep learning method for motion tracking on cardiac tagging magnetic resonance images," in *Proceedings of the IEEE/CVF conference on computer vision and pattern recognition*, 2021, pp. 7261–7271.
- [26] S. Pirola, B. Guo, C. Menichini, S. Saitta, W. Fu, Z. Dong, and X. Y. Xu, "4-d flow mri-based computational analysis of blood flow in patient-specific aortic dissection," *IEEE Transactions on Biomedical Engineering*, vol. 66, no. 12, pp. 3411–3419, 2019.
- [27] B. Serrano-Antón, A. Otero-Cacho, D. López-Otero, B. Díaz-Fernández, M. Bastos-Fernández, V. Pérez-Muñuzuri, J. R. González-Juanatey, and A. P. Muñuzuri, "Coronary artery segmentation based on transfer learning and unet architecture on computed tomography coronary angiography images," *IEEE Access*, 2023.
- [28] K. K. Kolli and J. K. Min, "Image-based computational fluid dynamic analysis for surgical planning of sequential grafts in coronary artery bypass grafting," in *2018 40th Annual International Conference of the IEEE Engineering in Medicine and Biology Society (EMBC)*. IEEE, 2018, pp. 4893–4896.
- [29] C. Martín-Isla, V. M. Campello, C. Izquierdo, K. Kushibar, C. Sendra-Balcells, P. Gkontra, A. Sojoudi, M. J. Fulton, T. W. Arega, K. Punithakumar *et al.*, "Deep learning segmentation of the right ventricle in cardiac mri: The m&ms challenge," *IEEE Journal of Biomedical and Health Informatics*, 2023.
- [30] A. P. Dhaene, M. Loecher, A. J. Wilson, and D. B. Ennis, "Myocardial segmentation of tagged magnetic resonance images with transfer learning using generative cine-to-tagged dataset transformation," *Bio-engineering*, vol. 10, no. 2, p. 166, 2023.



- [31] A. Blach and J. Kwiecinski, "The role of positron emission tomography in advancing the understanding of the pathogenesis of heart and vascular diseases," *Diagnostics*, vol. 13, no. 10, p. 1791, 2023.
- [32] K. Ekambaram and K. Hassan, "Establishing a novel diagnostic framework using handheld point-of-care focused-echocardiography (hope) for acute left-sided cardiac valve emergencies: A bayesian approach for emergency physicians in resource-limited settings," *Diagnostics*, vol. 13, no. 15, p. 2581, 2023.
- [33] A. Heinrich, F. Streckenbach, E. Beller, J. Groß, M.-A. Weber, and F. G. Meinel, "Deep learning-based image reconstruction for ct angiography of the aorta," *Diagnostics*, vol. 11, no. 11, p. 2037, 2021.
- [34] F. Baessato, M. Guglielmo, G. Muscogiuri, A. Baggiano, L. Fusini, S. Scafuri, M. Babbaro, R. Mollace, A. Collevocchio, A. I. Guaricci *et al.*, "The incremental role of coronary computed tomography in chronic coronary syndromes," *Journal of Clinical Medicine*, vol. 9, no. 12, p. 3925, 2020.
- [35] S. Giusca, M. Schuetz, F. Kronbach, D. Wolf, P. Nunninger, and G. Korosoglou, "Coronary computer tomography angiography in 2021—acquisition protocols, tips and tricks and heading beyond the possible," *Diagnostics*, vol. 11, no. 6, p. 1072, 2021.
- [36] M. Zhai, T. Du, R. Yang, and H. Zhang, "Coronary artery vascular segmentation on limited data via pseudo-precise label," in *2019 41st Annual International Conference of the IEEE Engineering in Medicine and Biology Society (EMBC)*. IEEE, 2019, pp. 816–819.
- [37] M. Xia, W. Yan, Y. Huang, Y. Guo, G. Zhou, and Y. Wang, "Ivus image segmentation using superpixel-wise fuzzy clustering and level set evolution," *Applied Sciences*, vol. 9, no. 22, p. 4967, 2019.
- [38] S. K. Berkaya, A. K. Uysal, E. S. Gunal, S. Ergin, S. Gunal, and M. B. Gulmezoglu, "A survey on ecg analysis," *Biomedical Signal Processing and Control*, vol. 43, pp. 216–235, 2018.
- [39] H. Li and P. Boulanger, "A survey of heart anomaly detection using ambulatory electrocardiogram (ecg)," *Sensors*, vol. 20, no. 5, p. 1461, 2020.
- [40] A. Darmawahyuni, S. Nurmaini, M. N. Rachmatullah, B. Tutuko, A. I. Sapitri, F. Firdaus, A. Fansyuri, and A. Predyansyah, "Deep learning-based electrocardiogram rhythm and beat features for heart abnormality classification," *PeerJ Computer Science*, vol. 8, p. e825, 2022.
- [41] J. S. Ryu, S. Lee, Y. Chu, M.-S. Ahn, Y. J. Park, and S. Yang, "Coat-mixer: Self-attention deep learning framework for left ventricular hypertrophy using electrocardiography," *Plos one*, vol. 18, no. 6, p. e0286916, 2023.
- [42] R. Matsuoka, H. Akazawa, S. Kodera, K. Soma, H. Yagi, M. Umei, H. Kadowaki, J. Ishida, H. Shinohara, S. Katsushika *et al.*, "Deep learning-based approach for detecting signs of atrial septal defect on chest radiographs: a proof of concept study," *medRxiv*, pp. 2022–01, 2022.
- [43] S. Çimen, A. Gooya, M. Grass, and A. F. Frangi, "Reconstruction of coronary arteries from x-ray angiography: A review," *Medical image analysis*, vol. 32, pp. 46–68, 2016.
- [44] M. Yu, Z. Lu, W. Li, M. Wei, J. Yan, and J. Zhang, "Coronary plaque characteristics on baseline ct predict the need for late revascularization in symptomatic patients after percutaneous intervention," *European Radiology*, vol. 28, pp. 3441–3453, 2018.
- [45] B. T. Crabb, F. Hamrick, T. Richards, P. Eiswirth, F. Noo, A. Hsiao, and G. C. Fine, "Deep learning subtraction angiography: Improved generalizability with transfer learning," *Journal of Vascular and Interventional Radiology*, vol. 34, no. 3, pp. 409–419, 2023.
- [46] N. Niimi, Y. Shiraishi, M. Sawano, N. Ikemura, T. Inohara, I. Ueda, K. Fukuda, and S. Kohsaka, "Machine learning models for prediction of adverse events after percutaneous coronary intervention," *Scientific reports*, vol. 12, no. 1, p. 6262, 2022.
- [47] Y. Garg, K. Seetharam, M. Sharma, D. K. Rohita, and W. Nabi, "Role of deep learning in computed tomography," *Cureus*, vol. 15, no. 5, 2023.
- [48] J. Gu, T. S. Yang, J. C. Ye, and D. H. Yang, "Cyclegan denoising of extreme low-dose cardiac ct using wavelet-assisted noise disentanglement," *Medical image analysis*, vol. 74, p. 102209, 2021.
- [49] A. Lin, N. Manral, P. McElhinney, A. Killekar, H. Matsumoto, J. Kwiecinski, K. Pieszko, A. Razipour, K. Grodecki, C. Park *et al.*, "Deep learning-enabled coronary ct angiography for plaque and stenosis quantification and cardiac risk prediction: an international multicentre study," *The Lancet Digital Health*, vol. 4, no. 4, pp. e256–e265, 2022.
- [50] C. Xu, Y. Yi, M. Xu, J. Yan, Y.-B. Guo, J. Wang, Y. Wang, Y.-M. Li, Z.-Y. Jin, and Y.-N. Wang, "Coronary artery stent evaluation by cta: impact of deep learning reconstruction and subtraction technique," *American Journal of Roentgenology*, vol. 220, no. 1, pp. 63–72, 2023.
- [51] D. Eng, C. Chute, N. Khandwala, P. Rajpurkar, J. Long, S. Shleifer, M. H. Khalaf, A. T. Sandhu, F. Rodriguez, D. J. Maron *et al.*, "Automated coronary calcium scoring using deep learning with multicenter external validation," *NPJ digital medicine*, vol. 4, no. 1, p. 88, 2021.
- [52] J. Peper, D. Suchá, M. Swaans, and T. Leiner, "Functional cardiac ct—going beyond anatomical evaluation of coronary artery disease with cine ct, ct-ffr, ct perfusion and machine learning," *The British Journal of Radiology*, vol. 93, no. 1113, p. 20200349, 2020.
- [53] S. Bruns, J. M. Wolterink, R. A. Takx, R. W. van Hamersvelt, D. Suchá, M. A. Viergever, T. Leiner, and I. Išgum, "Deep learning from dual-energy information for whole-heart segmentation in dual-energy and single-energy non-contrast-enhanced cardiac ct," *Medical physics*, vol. 47, no. 10, pp. 5048–5060, 2020.
- [54] J. Zhou, M. Du, S. Chang, and Z. Chen, "Artificial intelligence in echocardiography: detection, functional evaluation, and disease diagnosis," *Cardiovascular ultrasound*, vol. 19, no. 1, pp. 1–11, 2021.
- [55] B. Liu, H. Chang, D. Yang, F. Yang, Q. Wang, Y. Deng, L. Li, W. Lv, B. Zhang, L. Yu *et al.*, "A deep learning framework assisted echocardiography with diagnosis, lesion localization, phenogrouping heterogeneous disease, and anomaly detection," *Scientific Reports*, vol. 12, no. 1, p. 3, 2023.
- [56] I. Aly, A. Rizvi, W. Roberts, S. Khalid, M. W. Kassem, S. Salandy, M. du Plessis, R. S. Tubbs, and M. Loukas, "Cardiac ultrasound: an anatomical and clinical review," *Translational Research in Anatomy*, vol. 22, p. 100083, 2021.
- [57] J. Lu, F. Millioz, F. Varray, J. Porée, J. Provost, O. Bernard, D. Garcia, and D. Friboulet, "Ultrafast cardiac imaging using deep learning for speckle-tracking echocardiography," *IEEE TRANSACTIONS ON ULTRASONICS, FERROELECTRICS, AND FREQUENCY CONTROL*, 2023.
- [58] A. Ghorbani, D. Ouyang, A. Abid, B. He, J. H. Chen, R. A. Harrington, D. H. Liang, E. A. Ashley, and J. Y. Zou, "Deep learning interpretation of echocardiograms," *NPJ digital medicine*, vol. 3, no. 1, p. 10, 2020.
- [59] J. Xu and S. Lo, "Fundamentals and role of intravascular ultrasound in percutaneous coronary intervention," *Cardiovascular Diagnosis and Therapy*, vol. 10, no. 5, p. 1358, 2020.
- [60] C. L. De Korte and A. F. Van Der Steen, "Intravascular ultrasound elastography: an overview," *Ultrasonics*, vol. 40, no. 1-8, pp. 859–865, 2002.
- [61] N. Tamaki and O. Manabe, "Current status and perspectives of nuclear cardiology," *Annals of Nuclear Medicine*, vol. 38, no. 1, pp. 20–30, 2024.
- [62] I. D. Apostolopoulos, N. I. Papandrianos, A. Feleki, S. Moustakidis, and E. I. Papageorgiou, "Deep learning-enhanced nuclear medicine spect imaging applied to cardiac studies," *EJNMMI physics*, vol. 10, no. 1, p. 6, 2023.
- [63] P. J. Slomka, J. B. Moody, R. J. Miller, J. M. Renaud, E. P. Ficaro, and E. V. Garcia, "Quantitative clinical nuclear cardiology, part 2: Evolving/emerging applications," *Journal of Nuclear Cardiology*, vol. 28, pp. 115–127, 2021.
- [64] Y. LeCun, Y. Bengio, and G. Hinton, "Deep learning," *nature*, vol. 521, no. 7553, pp. 436–444, 2015.
- [65] A. Vaswani, N. Shazeer, N. Parmar, J. Uszkoreit, L. Jones, A. N. Gomez, Ł. Kaiser, and I. Polosukhin, "Attention is all you need," *Advances in neural information processing systems*, vol. 30, 2017.
- [66] J. Long, E. Shelhamer, and T. Darrell, "Fully convolutional networks for semantic segmentation," in *Proceedings of the IEEE conference on computer vision and pattern recognition*, 2015, pp. 3431–3440.
- [67] O. Ronneberger, P. Fischer, and T. Brox, "U-net: Convolutional networks for biomedical image segmentation," in *Medical Image Computing and Computer-Assisted Intervention—MICCAI 2015: 18th International Conference, Munich, Germany, October 5-9, 2015, Proceedings, Part III 18*. Springer, 2015, pp. 234–241.
- [68] J. Ehrhardt and M. Wilms, "Autoencoders and variational autoencoders in medical image analysis," in *Biomedical Image Synthesis and Simulation*. Elsevier, 2022, pp. 129–162.
- [69] I. Goodfellow, J. Pouget-Abadie, M. Mirza, B. Xu, D. Warde-Farley, S. Ozair, A. Courville, and Y. Bengio, "Generative adversarial networks," *Communications of the ACM*, vol. 63, no. 11, pp. 139–144, 2020.
- [70] Z. Zhao, Y. Liu, H. Wu, Y. Li, S. Wang, L. Teng, D. Liu, X. Li, Z. Cui, Q. Wang *et al.*, "Clip in medical imaging: A comprehensive survey," *arXiv preprint arXiv:2312.07353*, 2023.
- [71] I. Išgum, M. Prokop, M. Niemeijer, M. A. Viergever, and B. Van Ginneken, "Automatic coronary calcium scoring in low-dose chest computed tomography," *IEEE transactions on medical imaging*, vol. 31, no. 12, pp. 2322–2334, 2012.
- [72] A. Sheikhjafari, D. Krishnaswamy, M. Noga, N. Ray, and K. Punithakumar, "Unsupervised diffeomorphic cardiac image registration us-

- ing parameterization of the deformation field,” *arXiv preprint arXiv:2208.13275*, 2022.
- [73] V. Bui, S. M. Shanbhag, O. Levine, M. Jacobs, W. P. Bandettini, L.-C. Chang, M. Y. Chen, and L.-Y. Hsu, “Simultaneous multi-structure segmentation of the heart and peripheral tissues in contrast enhanced cardiac computed tomography angiography,” *IEEE Access*, vol. 8, pp. 16 187–16 202, 2020.
- [74] J. M. Jaén-Lorites, M. Pérez-Pelegrí, V. Laparra, M. P. López-Lereu, J. V. Monmeneu, A. M. Maceira, and D. Moratal, “Synthetic generation of cardiac mr images combining convolutional variational autoencoders and style transfer,” in *2022 44th Annual International Conference of the IEEE Engineering in Medicine & Biology Society (EMBC)*. IEEE, 2022, pp. 2084–2087.
- [75] X. Liu, F. Xing, J. L. Prince, A. Carass, M. Stone, G. El Fakhri, and J. Woo, “Dual-cycle constrained bijective vae-gan for tagged-to-cine magnetic resonance image synthesis,” in *2021 IEEE 18th International Symposium on Biomedical Imaging (ISBI)*. IEEE, 2021, pp. 1448–1452.
- [76] J. Ho, A. Jain, and P. Abbeel, “Denoising diffusion probabilistic models,” *Advances in neural information processing systems*, vol. 33, pp. 6840–6851, 2020.
- [77] J. Donahue, L. Anne Hendricks, S. Guadarrama, M. Rohrbach, S. Venugopalan, K. Saenko, and T. Darrell, “Long-term recurrent convolutional networks for visual recognition and description,” in *Proceedings of the IEEE conference on computer vision and pattern recognition*, 2015, pp. 2625–2634.
- [78] Y. Lu, B. Kong, F. Gao, K. Cao, S. Lyu, S. Zhang, S. Hu, Y. Yin, and X. Wang, “Attention-driven tree-structured convolutional lstm for high dimensional data understanding,” *Frontiers in Physics*, vol. 11, p. 1095277, 2023.
- [79] Z. Wu, S. Pan, F. Chen, G. Long, C. Zhang, and S. Y. Philip, “A comprehensive survey on graph neural networks,” *IEEE transactions on neural networks and learning systems*, vol. 32, no. 1, pp. 4–24, 2020.
- [80] X. Wang, Z. Luo, J. Hu, C. Feng, S. Hu, B. Zhu, X. Wu, and S. Lyu, “Deep reinforcement learning for image-to-image translation,” *arXiv preprint arXiv:2309.13672*, 2023.
- [81] B. Kim, Y. Oh, and J. C. Ye, “Diffusion adversarial representation learning for self-supervised vessel segmentation,” *arXiv preprint arXiv:2209.14566*, 2022.
- [82] M. Zreik, R. W. Van Hamersvelt, J. M. Wolterink, T. Leiner, M. A. Viergever, and I. Išgum, “A recurrent cnn for automatic detection and classification of coronary artery plaque and stenosis in coronary ct angiography,” *IEEE transactions on medical imaging*, vol. 38, no. 7, pp. 1588–1598, 2018.
- [83] H. Yang, X. Zhen, Y. Chi, L. Zhang, and X.-S. Hua, “Cpr-gcn: Conditional partial-residual graph convolutional network in automated anatomical labeling of coronary arteries,” in *Proceedings of the IEEE/CVF conference on computer vision and pattern recognition*, 2020, pp. 3803–3811.
- [84] J. Kweon, K. Kim, C. Lee, H. Kwon, J. Park, K. Song, Y. I. Kim, J. Park, I. Back, J.-H. Roh *et al.*, “Deep reinforcement learning for guidewire navigation in coronary artery phantom,” *IEEE Access*, vol. 9, pp. 166 409–166 422, 2021.
- [85] M. Saeed, T. A. Van, R. Krug, S. W. Hetts, and M. W. Wilson, “Cardiac mr imaging: current status and future direction,” *Cardiovascular diagnosis and therapy*, vol. 5, no. 4, p. 290, 2015.
- [86] G. A. Bello, T. J. Dawes, J. Duan, C. Biffi, A. De Marvao, L. S. Howard, J. S. R. Gibbs, M. R. Wilkins, S. A. Cook, D. Rueckert *et al.*, “Deep-learning cardiac motion analysis for human survival prediction,” *Nature machine intelligence*, vol. 1, no. 2, pp. 95–104, 2019.
- [87] T. Küstner, N. Fuim, K. Hammernik, A. Bustin, H. Qi, R. Hajhosseiny, P. G. Masci, R. Neji, D. Rueckert, R. M. Botnar *et al.*, “Cinenet: deep learning-based 3d cardiac cine mri reconstruction with multi-coil complex-valued 4d spatio-temporal convolutions,” *Scientific reports*, vol. 10, no. 1, p. 13710, 2020.
- [88] V. M. Campello, P. Gkontra, C. Izquierdo, C. Martín-Isla, A. Sojoudi, P. M. Full, K. Maier-Hein, Y. Zhang, Z. He, J. Ma *et al.*, “Multi-centre, multi-vendor and multi-disease cardiac segmentation: the m&ms challenge,” *IEEE Transactions on Medical Imaging*, vol. 40, no. 12, pp. 3543–3554, 2021.
- [89] J. Ren, Y. Li, F.-S. Liu, C. Liu, J.-X. Zhu, M. D. Nickel, X.-Y. Wang, X.-Y. Liu, J. Zhao, Y.-L. He *et al.*, “Comparison of a deep learning-accelerated t2-weighted turbo spin echo sequence and its conventional counterpart for female pelvic mri: reduced acquisition times and improved image quality,” *Insights into Imaging*, vol. 13, no. 1, p. 193, 2022.
- [90] H. Xue, R. H. Davies, L. A. Brown, K. D. Knott, T. Kotecha, M. Fontana, S. Plein, J. C. Moon, and P. Kellman, “Automated inline analysis of myocardial perfusion mri with deep learning,” *Radiology: Artificial Intelligence*, vol. 2, no. 6, p. e200009, 2020.
- [91] E. Alskaf, U. Dutta, C. M. Scannell, and A. Chiribiri, “Deep learning applications in myocardial perfusion imaging, a systematic review and meta-analysis,” *Informatics in Medicine Unlocked*, p. 101055, 2022.
- [92] T. Ueda, Y. Ohno, K. Yamamoto, K. Murayama, M. Ikedo, M. Yui, S. Hanamatsu, Y. Tanaka, Y. Obama, H. Ikeda *et al.*, “Deep learning reconstruction of diffusion-weighted mri improves image quality for prostatic imaging,” *Radiology*, vol. 303, no. 2, pp. 373–381, 2022.
- [93] H. Berhane, M. B. Scott, A. J. Barker, P. McCarthy, R. Avery, B. Allen, C. Malaisrie, J. D. Robinson, C. K. Rigsby, and M. Markl, “Deep learning-based velocity anti-aliasing of 4d-flow mri,” *Magnetic resonance in medicine*, vol. 88, no. 1, pp. 449–463, 2022.
- [94] S. E. Dilsizian and E. L. Siegel, “Artificial intelligence in medicine and cardiac imaging: harnessing big data and advanced computing to provide personalized medical diagnosis and treatment,” *Current cardiology reports*, vol. 16, pp. 1–8, 2014.
- [95] D. Dey, P. J. Slomka, P. Leeson, D. Comanicu, S. Shrestha, P. P. Sengupta, and T. H. Marwick, “Artificial intelligence in cardiovascular imaging: Jacc state-of-the-art review,” *Journal of the American College of Cardiology*, vol. 73, no. 11, pp. 1317–1335, 2019.
- [96] M. van Assen, G. Muscogiuri, D. Caruso, S. J. Lee, A. Laghi, and C. N. De Cecco, “Artificial intelligence in cardiac radiology,” *La radiologia medica*, vol. 125, pp. 1186–1199, 2020.
- [97] M. Sermesant, H. Delingette, H. Cochet, P. Jais, and N. Ayache, “Applications of artificial intelligence in cardiovascular imaging,” *Nature Reviews Cardiology*, vol. 18, no. 8, pp. 600–609, 2021.
- [98] S. Vesal, A. Maier, and N. Ravikumar, “Fully automated 3d cardiac mri localisation and segmentation using deep neural networks,” *Journal of Imaging*, vol. 6, no. 7, p. 65, 2020.
- [99] Q. Meng, C. Qin, W. Bai, T. Liu, A. de Marvao, D. P. O’Regan, and D. Rueckert, “Mulvimotion: Shape-aware 3d myocardial motion tracking from multi-view cardiac mri,” *IEEE transactions on medical imaging*, vol. 41, no. 8, pp. 1961–1974, 2022.
- [100] M. Jacobs, M. Benovoy, L.-C. Chang, D. Corcoran, C. Berry, A. E. Arai, and L.-Y. Hsu, “Automated segmental analysis of fully quantitative myocardial blood flow maps by first-pass perfusion cardiovascular magnetic resonance,” *IEEE access*, vol. 9, pp. 52 796–52 811, 2021.
- [101] C. Trentin, E. Faggiano, M. Conti, and F. Auricchio, “An automatic tool for thoracic aorta segmentation and 3d geometric analysis,” in *2015 9th International Symposium on Image and Signal Processing and Analysis (ISPA)*. IEEE, 2015, pp. 60–65.
- [102] Z. Yan, Z. Yao, W. Guo, D. Shang, R. Chen, J. Liu, X.-C. Cai, and J. Ge, “Impact of pressure wire on fractional flow reserve and hemodynamics of the coronary arteries: A computational and clinical study,” *IEEE Transactions on Biomedical Engineering*, vol. 70, no. 5, pp. 1683–1691, 2022.
- [103] H. Kirişli, M. Schaap, C. Metz, A. Dharampal, W. B. Meijboom, S.-L. Papadopoulou, A. Dedic, K. Nieman, M. A. de Graaf, M. Meijjs *et al.*, “Standardized evaluation framework for evaluating coronary artery stenosis detection, stenosis quantification and lumen segmentation algorithms in computed tomography angiography,” *Medical image analysis*, vol. 17, no. 8, pp. 859–876, 2013.
- [104] P. Righini, F. Secchi, D. Mazzaccaro, D. Giese, M. Galligani, D. Avishay, D. Capra, C. B. Monti, and G. Nano, “Four-dimensional flow mri for the evaluation of aortic endovascular graft: A pilot study,” *Diagnostics*, vol. 13, no. 12, p. 2113, 2023.
- [105] J.-R. D. Clarke, R. Kennedy, F. D. Lau, G. I. Lancaster, and S. W. Zarich, “Invasive evaluation of the microvasculature in acute myocardial infarction: coronary flow reserve versus the index of microcirculatory resistance,” *Journal of Clinical Medicine*, vol. 9, no. 1, 2020.
- [106] X. Zhuang, L. Li, C. Payer, D. Štern, M. Urschler, M. P. Heinrich, J. Oster, C. Wang, Ö. Smedby, C. Bian *et al.*, “Evaluation of algorithms for multi-modality whole heart segmentation: an open-access grand challenge,” *Medical image analysis*, vol. 58, p. 101537, 2019.
- [107] I. Cetin, M. Stephens, O. Camara, and M. A. G. Ballester, “Attribute-based interpretable representations of medical images with variational autoencoders,” *Computerized Medical Imaging and Graphics*, vol. 104, p. 102158, 2023.
- [108] P. Peng, K. Lekadir, A. Gooya, L. Shao, S. E. Petersen, and A. F. Frangi, “A review of heart chamber segmentation for structural and functional analysis using cardiac magnetic resonance imaging,” *Magnetic Resonance Materials in Physics, Biology and Medicine*, vol. 29, pp. 155–195, 2016.

- [109] Z. Fu, Z. Fu, Z. Fang, Z. Wang, J. Fei, R. Xie, and H. Han, "Prior skeleton based online deep reinforcement learning for coronary artery center-line extraction," *Proceedings of the Institution of Mechanical Engineers, Part H: Journal of Engineering in Medicine*, p. 09544119231167926, 2023.
- [110] X. Li, H. Chen, X. Qi, Q. Dou, C.-W. Fu, and P.-A. Heng, "H-denseunet: hybrid densely connected unet for liver and tumor segmentation from ct volumes," *IEEE transactions on medical imaging*, vol. 37, no. 12, pp. 2663–2674, 2018.
- [111] X. Shi, Z. Chen, H. Wang, D.-Y. Yeung, W.-K. Wong, and W.-c. Woo, "Convolutional lstm network: A machine learning approach for precipitation nowcasting," *Advances in neural information processing systems*, vol. 28, 2015.
- [112] R. Azad, M. Asadi-Aghbolaghi, M. Fathy, and S. Escalera, "Bi-directional convlstm u-net with densely connected convolutions," in *Proceedings of the IEEE/CVF international conference on computer vision workshops*, 2019, pp. 0–0.
- [113] R. Azad, E. K. Aghdam, A. Rauland, Y. Jia, A. H. Avval, A. Bozorgpour, S. Karimijafarbigloo, J. P. Cohen, E. Adeli, and D. Merhof, "Medical image segmentation review: The success of u-net," *arXiv preprint arXiv:2211.14830*, 2022.
- [114] A. Creswell, T. White, V. Dumoulin, K. Arulkumaran, B. Sengupta, and A. A. Bharath, "Generative adversarial networks: An overview," *IEEE signal processing magazine*, vol. 35, no. 1, pp. 53–65, 2018.
- [115] Y. Chen, X.-H. Yang, Z. Wei, A. A. Heidari, N. Zheng, Z. Li, H. Chen, H. Hu, Q. Zhou, and Q. Guan, "Generative adversarial networks in medical image augmentation: A review," *Computers in Biology and Medicine*, vol. 144, p. 105382, 2022.
- [116] S. Xun, D. Li, H. Zhu, M. Chen, J. Wang, J. Li, M. Chen, B. Wu, H. Zhang, X. Chai *et al.*, "Generative adversarial networks in medical image segmentation: A review," *Computers in biology and medicine*, vol. 140, p. 105063, 2022.
- [117] C. Xu, L. Xu, P. Ohorodnyk, M. Roth, B. Chen, and S. Li, "Contrast agent-free synthesis and segmentation of ischemic heart disease images using progressive sequential causal gans," *Medical image analysis*, vol. 62, p. 101668, 2020.
- [118] A. Kazerouni, E. K. Aghdam, M. Heidari, R. Azad, M. Fayyaz, I. Hacihaliloglu, and D. Merhof, "Diffusion models in medical imaging: A comprehensive survey," *Medical Image Analysis*, p. 102846, 2023.
- [119] A. Khalil, S.-C. Ng, Y. M. Liew, and K. W. Lai, "An overview on image registration techniques for cardiac diagnosis and treatment," *Cardiology research and practice*, vol. 2018, 2018.
- [120] T. Makela, P. Clarysse, O. Sipila, N. Pauna, Q. C. Pham, T. Katila, and I. E. Magnin, "A review of cardiac image registration methods," *IEEE Transactions on medical imaging*, vol. 21, no. 9, pp. 1011–1021, 2002.
- [121] D. Toth, S. Miao, T. Kurzendorfer, C. A. Rinaldi, R. Liao, T. Mansi, K. Rhode, and P. Mountney, "3d/2d model-to-image registration by imitation learning for cardiac procedures," *International journal of computer assisted radiology and surgery*, vol. 13, pp. 1141–1149, 2018.
- [122] J. Chen, Y. Liu, S. Wei, Z. Bian, S. Subramanian, A. Carass, J. L. Prince, and Y. Du, "A survey on deep learning in medical image registration: New technologies, uncertainty, evaluation metrics, and beyond," *arXiv preprint arXiv:2307.15615*, 2023.
- [123] A. Lara-Hernandez, T. Rienmüller, I. Juárez, M. Pérez, F. Reyna, D. Baumgartner, V. N. Makarenko, O. L. Bockeria, M. Maksudov, R. Rienmüller *et al.*, "Deep learning-based image registration in dynamic myocardial perfusion ct imaging," *IEEE Transactions on Medical Imaging*, vol. 42, no. 3, pp. 684–696, 2022.
- [124] L. Wang, S. Dang, S. Chen, J.-Y. Sun, R.-X. Wang, and F. Pan, "Deep-learning-based detection of paroxysmal supraventricular tachycardia using sinus-rhythm electrocardiograms," *Journal of Clinical Medicine*, vol. 11, no. 15, p. 4578, 2022.
- [125] R. M. ter Bekke, K. de Schouwer, S. Conti, G. R. Claes, J. Vanoevelen, S. Gommers, A. T. Helderma-van den Enden, and H.-P. Brunner-LaRocca, "Juvenile-onset multifocal atrial arrhythmias, atrial standstill and compound heterozygosity of genetic variants in taf1a: sentinel event for evolving dilated cardiomyopathy—a case report," *European Heart Journal-Case Reports*, p. ytd255, 2023.
- [126] V. C. Raicea, H. Suci, A. D. Raicea, G. C. Macarie, T. Mezei, and M. S. Maier, "Giant left atrial myxoma—literature review and case presentation," *Romanian Journal of Morphology and Embryology*, vol. 62, no. 2, p. 361, 2021.
- [127] Y.-C. Wang, X. Xu, A. Hajra, S. Apple, A. Kharawala, G. Duarte, W. Liaqat, Y. Fu, W. Li, Y. Chen *et al.*, "Current advancement in diagnosing atrial fibrillation by utilizing wearable devices and artificial intelligence: A review study," *Diagnostics*, vol. 12, no. 3, p. 689, 2022.
- [128] M. Mäkynen, G. A. Ng, X. Li, and F. S. Schindwein, "Wearable devices combined with artificial intelligence—a future technology for atrial fibrillation detection?" *Sensors*, vol. 22, no. 22, p. 8588, 2022.
- [129] S. Raghunath, J. M. Pfeifer, A. E. Ulloa-Cerna, A. Nemani, T. Carbonati, L. Jing, D. P. vanMaanen, D. N. Hartzel, J. A. Ruhl, B. F. Lagerman *et al.*, "Deep neural networks can predict new-onset atrial fibrillation from the 12-lead ecg and help identify those at risk of atrial fibrillation-related stroke," *Circulation*, vol. 143, no. 13, pp. 1287–1298, 2021.
- [130] F. Murat, F. Sadak, O. Yildirim, M. Talo, E. Murat, M. Karabatak, Y. Demir, R.-S. Tan, and U. R. Acharya, "Review of deep learning-based atrial fibrillation detection studies," *International journal of environmental research and public health*, vol. 18, no. 21, p. 11302, 2021.
- [131] L. Li, F. Wu, G. Yang, L. Xu, T. Wong, R. Mohiaddin, D. Firmin, J. Keegan, and X. Zhuang, "Atrial scar quantification via multi-scale cnn in the graph-cuts framework," *Medical image analysis*, vol. 60, p. 101595, 2020.
- [132] C.-Y. Hsu, P.-Y. Liu, S.-H. Liu, Y. Kwon, C. J. Lavie, and G.-M. Lin, "Machine learning for electrocardiographic features to identify left atrial enlargement in young adults: Chief heart study," *Frontiers in Cardiovascular Medicine*, vol. 9, p. 840585, 2022.
- [133] J. Jiang, H. Deng, Y. Xue, H. Liao, and S. Wu, "Detection of left atrial enlargement using a convolutional neural network-enabled electrocardiogram," *Frontiers in Cardiovascular Medicine*, vol. 7, p. 609976, 2020.
- [134] P. Kuchynka, J. Podzimekova, M. Masek, L. Lambert, V. Cerny, B. Danek, T. Palecek *et al.*, "The role of magnetic resonance imaging and cardiac computed tomography in the assessment of left atrial anatomy, size, and function," *BioMed research international*, vol. 2015, 2015.
- [135] P. Pantelidis, E. Oikonomou, N. Souvaliotis, M. Spartalis, S. Lampsas, M. Bampa, C. Bakogiannis, A. Antonopoulos, G. Siasos, M. Vavuranakis *et al.*, "Deep learning to diagnose left ventricular hypertrophy from standard, 12-lead ecg signals: a proof-of-concept study," *Europace*, vol. 25, no. Supplement\_1, pp. eua4122–534, 2023.
- [136] X. Zhao, G. Huang, L. Wu, M. Wang, X. He, J.-R. Wang, B. Zhou, Y. Liu, Y. Lin, D. Liu *et al.*, "Deep learning assessment of left ventricular hypertrophy based on electrocardiogram," *Frontiers in Cardiovascular Medicine*, vol. 9, p. 952089, 2022.
- [137] M. A. Shoaib, J. H. Chuah, R. Ali, K. Hasikin, A. Khalil, Y. C. Hum, Y. K. Tee, S. Dhanalakshmi, K. W. Lai *et al.*, "An overview of deep learning methods for left ventricle segmentation," *Computational intelligence and neuroscience*, vol. 2023, 2023.
- [138] S. Olaisen, E. Smistad, T. Espeland, J. Hu, D. Pasdeloup, A. Østvik, S. Aakhus, A. Rösner, S. Malm, M. Styliadis *et al.*, "Automatic measurements of left ventricular volumes and ejection fraction by artificial intelligence: clinical validation in real time and large databases," *European Heart Journal-Cardiovascular Imaging*, p. jead280, 2023.
- [139] P. Madan, V. Singh, D. P. Singh, M. Diwakar, B. Pant, and A. Kishor, "A hybrid deep learning approach for ecg-based arrhythmia classification," *Bioengineering*, vol. 9, no. 4, p. 152, 2022.
- [140] M. Z. Kolk, B. Deb, S. Ruipérez-Campillo, N. K. Bhatia, P. Clopton, A. A. Wilde, S. M. Narayan, R. E. Knops, and F. V. Tjong, "Machine learning of electrophysiological signals for the prediction of ventricular arrhythmias: systematic review and examination of heterogeneity between studies," *EBioMedicine*, vol. 89, 2023.
- [141] K. Kusunose, R. Zheng, H. Yamada, and M. Sata, "How to standardize the measurement of left ventricular ejection fraction," *Journal of Medical Ultrasonics*, pp. 1–9, 2021.
- [142] X. Liu, Y. Fan, S. Li, M. Chen, M. Li, W. K. Hau, H. Zhang, L. Xu, and A. P.-W. Lee, "Deep learning-based automated left ventricular ejection fraction assessment using 2-d echocardiography," *American Journal of Physiology-Heart and Circulatory Physiology*, vol. 321, no. 2, pp. H390–H399, 2021.
- [143] A. P. Akerman, M. Porumb, C. G. Scott, A. Beqiri, A. Chartsias, A. J. Ryu, W. Hawkes, G. D. Huntley, A. Z. Arystan, G. C. Kane *et al.*, "Automated echocardiographic detection of heart failure with preserved ejection fraction using artificial intelligence," *JACC: Advances*, vol. 2, no. 6, p. 100452, 2023.
- [144] M. Mokhtari, T. Tsang, P. Abolmaesumi, and R. Liao, "Echognn: Explainable ejection fraction estimation with graph neural networks," in *International Conference on Medical Image Computing and Computer-Assisted Intervention*. Springer, 2022, pp. 360–369.
- [145] R. Rinaldi, C. Salzillo, A. Caffè, and R. A. Montone, "Invasive functional coronary assessment in myocardial ischemia with non-obstructive coronary arteries: From pathophysiological mechanisms to clinical



- implications,” *Reviews in Cardiovascular Medicine*, vol. 23, no. 11, p. 371, 2022.
- [146] M. Jafari, A. Shoeibi, N. Ghassemi, J. Heras, A. Khosravi, S. H. Ling, R. Alizadehsani, A. Beheshti, Y.-D. Zhang, S.-H. Wang *et al.*, “Automatic diagnosis of myocarditis disease in cardiac mri modality using deep transformers and explainable artificial intelligence,” *arXiv preprint arXiv:2210.14611*, 2022.
- [147] Q. Zheng, H. Delingette, and N. Ayache, “Explainable cardiac pathology classification on cine mri with motion characterization by semi-supervised learning of apparent flow,” *Medical image analysis*, vol. 56, pp. 80–95, 2019.
- [148] B. Ibanez, S. James, S. Agewall, M. J. Antunes, C. Bucciarelli-Ducci, H. Bueno, A. L. Caforio, F. Crea, J. A. Goudevenos, S. Halvorsen *et al.*, “2017 esc guidelines for the management of acute myocardial infarction in patients presenting with st-segment elevation: The task force for the management of acute myocardial infarction in patients presenting with st-segment elevation of the european society of cardiology (esc),” *European heart journal*, vol. 39, no. 2, pp. 119–177, 2018.
- [149] Y. Cho, J.-m. Kwon, K.-H. Kim, J. R. Medina-Inojosa, K.-H. Jeon, S. Cho, S. Y. Lee, J. Park, and B.-H. Oh, “Artificial intelligence algorithm for detecting myocardial infarction using six-lead electrocardiography,” *Scientific reports*, vol. 10, no. 1, p. 20495, 2020.
- [150] N. Zhang, G. Yang, Z. Gao, C. Xu, Y. Zhang, R. Shi, J. Keegan, L. Xu, H. Zhang, Z. Fan *et al.*, “Deep learning for diagnosis of chronic myocardial infarction on nonenhanced cardiac cine mri,” *Radiology*, vol. 291, no. 3, pp. 606–617, 2019.
- [151] D. Doudesis, K. K. Lee, J. Boeddinghaus, A. Bularga, A. V. Ferry, C. Tuck, M. T. Lowry, P. Lopez-Ayala, T. Nestelberger, L. Koechlin *et al.*, “Machine learning for diagnosis of myocardial infarction using cardiac troponin concentrations,” *Nature Medicine*, pp. 1–10, 2023.
- [152] M. Vukadinovic, A. C. Kwan, V. Yuan, M. Salerno, D. C. Lee, C. M. Albert, S. Cheng, D. Li, D. Ouyang, and S. L. Clarke, “Deep learning-enabled analysis of medical images identifies cardiac sphericity as an early marker of cardiomyopathy and related outcomes,” *Med*, vol. 4, no. 4, pp. 252–262, 2023.
- [153] J. Guo, H. Lu, Y. Chen, M. Zeng, and H. Jin, “Artificial intelligence study on left ventricular function among normal individuals, hypertrophic cardiomyopathy and dilated cardiomyopathy patients using 1.5 t cardiac cine mr images obtained by ssfp sequence,” *The British Journal of Radiology*, vol. 95, no. 1133, p. 20201060, 2022.
- [154] Z.-C. Wang, Z.-Z. Fan, X.-Y. Liu, M.-J. Zhu, S.-S. Jiang, S. Tian, B.-H. Chen, and L.-M. Wu, “Deep learning for discrimination of hypertrophic cardiomyopathy and hypertensive heart disease on mri native t1 maps,” *Journal of Magnetic Resonance Imaging*, 2023.
- [155] A. Chandrashekar, A. Handa, P. Lapolla, N. Shivakumar, R. Uberoi, V. Grau, and R. Lee, “A deep learning approach to visualize aortic aneurysm morphology without the use of intravenous contrast agents,” *Annals of Surgery*, 2021.
- [156] D. P. Stonko, J. J. Morrison, and C. W. Hicks, “A review of mature machine learning and artificial intelligence enabled applications in aortic surgery,” *JVS-Vascular Insights*, p. 100016, 2023.
- [157] G. Holste, E. K. Oikonomou, B. J. Mortazavi, A. Coppi, K. F. Faridi, E. J. Miller, J. K. Forrest, R. L. McNamara, L. Ohno-Machado, N. Yuan *et al.*, “Severe aortic stenosis detection by deep learning applied to echocardiography,” *European Heart Journal*, vol. 44, no. 43, pp. 4592–4604, 2023.
- [158] L. B. Elvas, P. Águas, J. C. Ferreira, J. P. Oliveira, M. S. Dias, and L. B. Rosário, “Ai-based aortic stenosis classification in mri scans,” *Electronics*, vol. 12, no. 23, p. 4835, 2023.
- [159] M. J. Ramaekers, J. J. Westenberg, B. P. Adriaans, E. C. Nijssen, J. E. Wildberger, H. J. Lamb, and S. Schalla, “A clinician’s guide to understanding aortic 4d flow mri,” *Insights into Imaging*, vol. 14, no. 1, pp. 1–14, 2023.
- [160] B. Zhuang, A. Sirajuddin, S. Zhao, and M. Lu, “The role of 4d flow mri for clinical applications in cardiovascular disease: current status and future perspectives,” *Quantitative Imaging in Medicine and Surgery*, vol. 11, no. 9, p. 4193, 2021.
- [161] M. M. Bissell, F. Raimondi, L. Ait Ali, B. D. Allen, A. J. Barker, A. Bolger, N. Burris, C.-J. Carhäll, J. D. Collins, T. Ebberts *et al.*, “4d flow cardiovascular magnetic resonance consensus statement: 2023 update,” *Journal of Cardiovascular Magnetic Resonance*, vol. 25, no. 1, pp. 1–24, 2023.
- [162] J. F. Juffermans, H. C. van Assen, B. J. te Kiefte, M. J. Ramaekers, R. L. van der Palen, P. van den Boogaard, B. P. Adriaans, J. E. Wildberger, I. A. Dekkers, A. J. Scholte *et al.*, “4d flow mri in ascending aortic aneurysms: Reproducibility of hemodynamic parameters,” *Applied Sciences*, vol. 12, no. 8, p. 3912, 2022.
- [163] F. Catapano, G. Pambianchi, G. Cundari, J. Rebelo, F. Cilia, I. Carbone, C. Catalano, M. Francone, and N. Galea, “4d flow imaging of the thoracic aorta: is there an added clinical value?” *Cardiovascular Diagnosis and Therapy*, vol. 10, no. 4, p. 1068, 2020.
- [164] E. Ferdian, A. Suinesiaputra, D. J. Dubowitz, D. Zhao, A. Wang, B. Cowan, and A. A. Young, “4dflownet: super-resolution 4d flow mri using deep learning and computational fluid dynamics,” *Frontiers in Physics*, p. 138, 2020.
- [165] L. Liu, C. Zhang, G. Zhang, Y. Gao, J. Luo, W. Zhang, Y. Li, and Y. Mu, “A study of aortic dissection screening method based on multiple machine learning models,” *Journal of Thoracic Disease*, vol. 12, no. 3, p. 605, 2020.
- [166] D. Mastrodicasa, M. Codari, K. Bäumlner, V. Sandfort, J. Shen, G. Mistlebauer, L. D. Hahn, V. L. Turner, B. Desjardins, M. J. Willemink *et al.*, “Artificial intelligence applications in aortic dissection imaging,” in *Seminars in roentgenology*, vol. 57, no. 4. Elsevier, 2022, pp. 357–363.
- [167] A. Awad and H. Al-Nafisi, “Public knowledge of cardiovascular disease and its risk factors in kuwait: a cross-sectional survey,” *BMC public health*, vol. 14, no. 1, pp. 1–11, 2014.
- [168] D. Li and V. Deshpande, “Magnetic resonance imaging of coronary arteries,” *Topics in Magnetic Resonance Imaging*, vol. 12, no. 5, pp. 337–347, 2001.
- [169] D. Pennell, J. Keegan, D. Firmin, P. Gatehouse, S. Underwood, and D. Longmore, “Magnetic resonance imaging of coronary arteries: technique and preliminary results,” *British heart journal*, vol. 70, no. 4, p. 315, 1993.
- [170] L. S. F. de Carvalho, G. Alexim, A. C. C. Nogueira, M. D. Fernandez, T. B. Rezende, S. Avila, R. T. B. Reis, A. A. M. Soares, and A. C. Sposito, “The framing of time-dependent machine learning models improves risk estimation among young individuals with acute coronary syndromes,” *Scientific Reports*, vol. 13, no. 1, p. 1021, 2023.
- [171] P. A. Iannattone, X. Zhao, J. VanHouten, A. Garg, and T. Huynh, “Artificial intelligence for diagnosis of acute coronary syndromes: a meta-analysis of machine learning approaches,” *Canadian Journal of Cardiology*, vol. 36, no. 4, pp. 577–583, 2020.
- [172] A. Smirnova, F. Aliberti, C. Cavaliere, I. Gatti, V. Vilardo, C. Giorgianni, C. Cassani, A. Repetto, N. Narula, L. Giuliani *et al.*, “Spontaneous coronary artery dissection: an unpredictable event,” *European Heart Journal Supplements*, vol. 25, no. Supplement\_B, pp. B7–B11, 2023.
- [173] C. Krittanawong, H. U. H. Virk, A. Kumar, M. Aydar, Z. Wang, M. P. Stewart, and J. L. Halperin, “Machine learning and deep learning to predict mortality in patients with spontaneous coronary artery dissection,” *Scientific reports*, vol. 11, no. 1, p. 8992, 2021.
- [174] N. Lionakis, A. Briasoulis, V. Zouganeli, S. Dimopoulos, D. Kalpakos, and C. Kourek, “Spontaneous coronary artery dissection: A review of diagnostic methods and management strategies,” *World Journal of Cardiology*, vol. 14, no. 10, p. 522, 2022.
- [175] G. D’Ancona, M. Massucci, M. Savardi, A. Signoroni, L. Di Bacco, D. Farina, M. Metra, R. Maroldi, C. Muneretto, H. Ince *et al.*, “Deep learning to detect significant coronary artery disease from plain chest radiographs ai4cad,” *International Journal of Cardiology*, vol. 370, pp. 435–441, 2023.
- [176] H. Lin, K. Chen, Y. Xue, S. Zhong, L. Chen, and M. Ye, “Coronary heart disease prediction method fusing domain-adaptive transfer learning with graph convolutional networks (gcn),” *Scientific Reports*, vol. 13, no. 1, p. 14276, 2023.
- [177] K. Fukushima, Y. Matsuo, M. Nagao, A. Sakai, N. Kihara, K. Onishi, and S. Sakai, “Patient based bull’s eye map display of coronary artery and ventricles from coronary computed tomography angiography,” *Journal of computer assisted tomography*, vol. 44, no. 1, pp. 26–31, 2020.
- [178] M. Termeer, J. O. Bescós, M. Breeuwer, A. Vilanova, F. Gerritsen, M. E. Gröller, and E. Nagel, “Visualization of myocardial perfusion derived from coronary anatomy,” *IEEE transactions on visualization and computer graphics*, vol. 14, no. 6, pp. 1595–1602, 2008.
- [179] X. Gao, R. Wang, Z. Sun, H. Zhang, K. Bo, X. Xue, J. Yang, and L. Xu, “A novel ct perfusion-based fractional flow reserve algorithm for detecting coronary artery disease,” *Journal of Clinical Medicine*, vol. 12, no. 6, p. 2154, 2023.
- [180] J. A. Pan and M. Salerno, “Clinical utility and future applications of pet/ct and pet/cmr in cardiology,” *Diagnostics*, vol. 6, no. 3, p. 32, 2016.
- [181] A. R. Wahab Sait and A. K. Dutta, “Developing a deep-learning-based coronary artery disease detection technique using computer tomography images,” *Diagnostics*, vol. 13, no. 7, p. 1312, 2023.

- [182] J. Zhang, R. Han, G. Shao, B. Lv, and K. Sun, "Artificial intelligence in cardiovascular atherosclerosis imaging," *Journal of Personalized Medicine*, vol. 12, no. 3, p. 420, 2022.
- [183] N. Gautam, P. Saluja, A. Malkawi, M. G. Rabbat, M. H. Al-Mallah, G. Pontone, Y. Zhang, B. C. Lee, and S. J. Al'Aref, "Current and future applications of artificial intelligence in coronary artery disease," in *Healthcare*, vol. 10, no. 2. MDPI, 2022, p. 232.
- [184] R. Alizadehsani, A. Khosravi, M. Roshanzamir, M. Abdar, N. Sarrafzadegan, D. Shafie, F. Khozeimeh, A. Shoeibi, S. Nahavandi, M. Panahiazar *et al.*, "Coronary artery disease detection using artificial intelligence techniques: A survey of trends, geographical differences and diagnostic features 1991–2020," *Computers in Biology and Medicine*, vol. 128, p. 104095, 2021.
- [185] A. J. V. Mézquita, F. Biavati, V. Falk, H. Alkadhi, R. Hajhosseiny, P. Maurovich-Horvat, R. Manka, S. Kozerke, M. Stuber, T. Derlin *et al.*, "Clinical quantitative coronary artery stenosis and coronary atherosclerosis imaging: a consensus statement from the quantitative cardiovascular imaging study group," *Nature Reviews Cardiology*, pp. 1–19, 2023.
- [186] E. E. van der Wall, H. W. Vliegen, A. de Roos, and A. V. Brusckhe, "Magnetic resonance imaging in coronary artery disease," *Circulation*, vol. 92, no. 9, pp. 2723–2739, 1995.
- [187] D. J. Pennell, H. G. Bogren, J. Keegan, D. N. Firmin, and S. R. Underwood, "Assessment of coronary artery stenosis by magnetic resonance imaging," *Heart*, vol. 75, no. 2, p. 127, 1996.
- [188] S. Dhawan, K. C. Dharmashankar, and T. Tak, "Role of magnetic resonance imaging in visualizing coronary arteries," *Clinical medicine & research*, vol. 2, no. 3, pp. 173–179, 2004.
- [189] R. M. Botnar, M. Stuber, K. V. Kissinger, W. Y. Kim, E. Spuentrup, and W. J. Manning, "Noninvasive coronary vessel wall and plaque imaging with magnetic resonance imaging," *Circulation*, vol. 102, no. 21, pp. 2582–2587, 2000.
- [190] R. Van Geuns, H. De Bruin, B. Rensing, P. Wielopolski, M. Hulshoff, P. Van Ooijen, M. Oudkerk, and P. De Feyter, "Magnetic resonance imaging of the coronary arteries: clinical results from three dimensional evaluation of a respiratory gated technique," *Heart*, vol. 82, no. 4, pp. 515–519, 1999.
- [191] W. F. Griffin, A. D. Choi, J. S. Riess, H. Marques, H.-J. Chang, J. H. Choi, J.-H. Doh, A.-Y. Her, B.-K. Koo, C.-W. Nam *et al.*, "Ai evaluation of stenosis on coronary cta, comparison with quantitative coronary angiography and fractional flow reserve: A credence trial substudy," *Cardiovascular Imaging*, vol. 16, no. 2, pp. 193–205, 2023.
- [192] S. Fawaz, S. Khan, R. Simpson, G. Clesham, C. M. Cook, J. R. Davies, G. V. Karamasis, and T. R. Keeble, "Invasive detection of coronary microvascular dysfunction: How it began, and where we are now," *Interventional Cardiology: Reviews, Research, Resources*, vol. 18, 2023.
- [193] Y. Zheng, M. Loziczzonek, B. Georgescu, S. K. Zhou, F. Vega-Higuera, and D. Comaniciu, "Machine learning based vesselness measurement for coronary artery segmentation in cardiac ct volumes," in *Medical Imaging 2011: Image Processing*, vol. 7962. Spie, 2011, pp. 489–500.
- [194] B. Kong, X. Wang, J. Bai, Y. Lu, F. Gao, K. Cao, J. Xia, Q. Song, and Y. Yin, "Learning tree-structured representation for 3d coronary artery segmentation," *Computerized Medical Imaging and Graphics*, vol. 80, p. 101688, 2020.
- [195] A. Zeng, C. Wu, M. Huang, J. Zhuang, S. Bi, D. Pan, N. Ullah, K. N. Khan, T. Wang, Y. Shi *et al.*, "Imagecas: A large-scale dataset and benchmark for coronary artery segmentation based on computed tomography angiography images," *Computerized Medical Imaging and Graphics*, 2023.
- [196] Y. Li, M. A. Armin, S. Denman, and D. Ahmedt-Aristizabal, "Automated coronary arteries labeling via geometric deep learning," in *2023 IEEE 20th International Symposium on Biomedical Imaging (ISBI)*. IEEE, 2023, pp. 1–5.
- [197] D. Wu, X. Wang, J. Bai, X. Xu, B. Ouyang, Y. Li, H. Zhang, Q. Song, K. Cao, and Y. Yin, "Automated anatomical labeling of coronary arteries via bidirectional tree lstms," *International journal of computer assisted radiology and surgery*, vol. 14, pp. 271–280, 2019.
- [198] C. Zhao, Z. Xu, J. Jiang, M. Esposito, D. Pienta, G.-U. Hung, and W. Zhou, "Agmn: Association graph-based graph matching network for coronary artery semantic labeling on invasive coronary angiograms," *arXiv preprint arXiv:2301.04733*, 2023.
- [199] Z. Li, Q. Xia, W. Wang, Z. Yan, R. Yin, C. Pan, and D. Metaxas, "Segmentation to label: Automatic coronary artery labeling from mask parcellation," in *Machine Learning in Medical Imaging: 11th International Workshop, MLMI 2020, Held in Conjunction with MICCAI 2020, Lima, Peru, October 4, 2020, Proceedings 11*. Springer, 2020, pp. 130–138.
- [200] L. Itu, S. Rapaka, T. Passerini, B. Georgescu, C. Schwemmer, M. Schoebinger, T. Flohr, P. Sharma, and D. Comaniciu, "A machine-learning approach for computation of fractional flow reserve from coronary computed tomography," *Journal of applied physiology*, vol. 121, no. 1, pp. 42–52, 2016.
- [201] Z. Gao, X. Wang, S. Sun, D. Wu, J. Bai, Y. Yin, X. Liu, H. Zhang, and V. H. C. de Albuquerque, "Learning physical properties in complex visual scenes: An intelligent machine for perceiving blood flow dynamics from static ct angiography imaging," *Neural Networks*, vol. 123, pp. 82–93, 2020.
- [202] M. T. Ayub and D. Kalra, "Coronary microvascular dysfunction and the role of noninvasive cardiovascular imaging," *Diagnostics*, vol. 10, no. 9, p. 679, 2020.
- [203] X. Zhao, Y. Gong, J. Zhang, H. Liu, T. Huang, J. Jiang, Y. Niu, L. Xia, and J. Mao, "Early detection of coronary microvascular dysfunction using machine learning algorithm based on vectorcardiography and cardiodynamicsgram features," *IRBM*, vol. 44, no. 6, p. 100805, 2023.
- [204] B. Gao, D. Zhu, J. Xie, B. Wu, P. Xu, J. Liu, X. Tong, R. Chen, L. Zhu, L. Zhou *et al.*, "A clinical trial for computed tomography myocardial perfusion based non-invasive index of microcirculatory resistance (mpbimr): Rationale and trial design," *American Journal of Translational Research*, vol. 14, no. 8, p. 5552, 2022.
- [205] H. Ai, Y. Feng, Y. Gong, B. Zheng, Q. Jin, H.-P. Zhang, F. Sun, J. Li, Y. Chen, Y. Huo *et al.*, "Coronary angiography-derived index of microvascular resistance," *Frontiers in Physiology*, vol. 11, p. 605356, 2020.
- [206] L. Papamanolis, H. J. Kim, C. Jaquet, M. Sinclair, M. Schaap, I. Danad, P. van Diemen, P. Knaapen, L. Najman, H. Talbot *et al.*, "Myocardial perfusion simulation for coronary artery disease: A coupled patient-specific multiscale model," *Annals of biomedical engineering*, vol. 49, pp. 1432–1447, 2021.
- [207] C. F. Sing, J. H. Stengård, and S. L. Kardia, "Genes, environment, and cardiovascular disease," *Arteriosclerosis, thrombosis, and vascular biology*, vol. 23, no. 7, pp. 1190–1196, 2003.
- [208] A. Buniello, J. A. L. MacArthur, M. Cerezo, L. W. Harris, J. Hayhurst, C. Malangone, A. McMahon, J. Morales, E. Mountjoy, E. Sollis *et al.*, "The nhgri-ebi gwas catalog of published genome-wide association studies, targeted arrays and summary statistics 2019," *Nucleic acids research*, vol. 47, no. D1, pp. D1005–D1012, 2019.
- [209] I. E. Christophersen, L. S. Ravn, E. Budtz-Joergensen, A. Skytthe, S. Haunsoe, J. H. Svendsen, and K. Christensen, "Familial aggregation of atrial fibrillation: a study in danish twins," *Circulation: Arrhythmia and Electrophysiology*, vol. 2, no. 4, pp. 378–383, 2009.
- [210] K. G. Aragam, T. Jiang, A. Goel, S. Kanoni, B. N. Wolford, D. S. Atri, E. M. Weeks, M. Wang, G. Hindy, W. Zhou *et al.*, "Discovery and systematic characterization of risk variants and genes for coronary artery disease in over a million participants," *Nature Genetics*, vol. 54, no. 12, pp. 1803–1815, 2022.
- [211] C. Tcheandjieu, X. Zhu, A. T. Hilliard, S. L. Clarke, V. Napolioni, S. Ma, K. M. Lee, H. Fang, F. Chen, Y. Lu *et al.*, "Large-scale genome-wide association study of coronary artery disease in genetically diverse populations," *Nature medicine*, vol. 28, no. 8, pp. 1679–1692, 2022.
- [212] A. R. Harper, A. Goel, C. Grace, K. L. Thomson, S. E. Petersen, X. Xu, A. Waring, E. Ormondroyd, C. M. Kramer, C. Y. Ho *et al.*, "Common genetic variants and modifiable risk factors underpin hypertrophic cardiomyopathy susceptibility and expressivity," *Nature genetics*, vol. 53, no. 2, pp. 135–142, 2021.
- [213] R. Tadros, C. Francis, X. Xu, A. M. Vermeer, A. R. Harper, R. Huurman, K. Kelu Bisabu, R. Walsh, E. T. Hoorntje, W. P. Te Rijdt *et al.*, "Shared genetic pathways contribute to risk of hypertrophic and dilated cardiomyopathies with opposite directions of effect," *Nature genetics*, vol. 53, no. 2, pp. 128–134, 2021.
- [214] A. V. Khera, M. Chaffin, K. G. Aragam, M. E. Haas, C. Roselli, S. H. Choi, P. Natarajan, E. S. Lander, S. A. Lubitz, P. T. Ellinor *et al.*, "Genome-wide polygenic scores for common diseases identify individuals with risk equivalent to monogenic mutations," *Nature genetics*, vol. 50, no. 9, pp. 1219–1224, 2018.
- [215] A. De Marvao, T. J. Dawes, and D. P. O'Regan, "Artificial intelligence for cardiac imaging-genetics research," *Frontiers in Cardiovascular Medicine*, vol. 6, p. 195, 2020.
- [216] J. P. Pirruccello, M. D. Chaffin, E. L. Chou, S. J. Fleming, H. Lin, M. Nekoui, S. Khurshid, S. F. Friedman, A. G. Bick, A. Arduini *et al.*, "Deep learning enables genetic analysis of the human thoracic aorta," *Nature genetics*, vol. 54, no. 1, pp. 40–51, 2022.
- [217] C. Glinge, N. Lahrouchi, R. Jabbari, J. Tfelt-Hansen, and C. R. Bezzina, "Genome-wide association studies of cardiac electrical phenotypes," *Cardiovascular research*, vol. 116, no. 9, pp. 1620–1634, 2020.

- [218] J. van Setten, N. Verweij, H. Mbarek, M. N. Niemeijer, S. Trompet, D. E. Arking, J. A. Brody, I. Gandin, N. Grarup, L. M. Hall *et al.*, “Genome-wide association meta-analysis of 30,000 samples identifies seven novel loci for quantitative ecg traits,” *European Journal of Human Genetics*, vol. 27, no. 6, pp. 952–962, 2019.
- [219] N. Aung, J. D. Vargas, C. Yang, C. P. Cabrera, H. R. Warren, K. Fung, E. Tzanis, M. R. Barnes, J. I. Rotter, K. D. Taylor *et al.*, “Genome-wide analysis of left ventricular image-derived phenotypes identifies fourteen loci associated with cardiac morphogenesis and heart failure development,” *Circulation*, vol. 140, no. 16, pp. 1318–1330, 2019.
- [220] J. P. Pirruccello, A. Bick, M. Wang, M. Chaffin, S. Friedman, J. Yao, X. Guo, B. A. Venkatesh, K. D. Taylor, W. S. Post *et al.*, “Analysis of cardiac magnetic resonance imaging in 36,000 individuals yields genetic insights into dilated cardiomyopathy,” *Nature communications*, vol. 11, no. 1, p. 2254, 2020.
- [221] J. P. Pirruccello, P. Di Achille, S. H. Choi, S. Khurshid, M. Nekoui, S. J. Jurgens, V. Nauffal, K. Ng, S. F. Friedman, K. L. Lunetta *et al.*, “Deep learning of left atrial structure and function provides link to atrial fibrillation risk,” *MedRxiv*, pp. 2021–08, 2021.
- [222] J. P. Pirruccello, P. Di Achille, V. Nauffal, M. Nekoui, S. F. Friedman, M. D. Klarqvist, M. D. Chaffin, L.-C. Weng, J. W. Cunningham, S. Khurshid *et al.*, “Genetic analysis of right heart structure and function in 40,000 people,” *Nature genetics*, vol. 54, no. 6, pp. 792–803, 2022.
- [223] M. Ardissino, C. McCracken, A. Bard, C. Antoniadis, S. Neubauer, N. C. Harvey, S. E. Petersen, and Z. Raisi-Estabragh, “Pericardial adiposity is independently linked to adverse cardiovascular phenotypes: a cmr study of 42 598 uk biobank participants,” *European Heart Journal-Cardiovascular Imaging*, vol. 23, no. 11, pp. 1471–1481, 2022.
- [224] L. Li, V. A. Zimmer, J. A. Schnabel, and X. Zhuang, “Atrialjsqnet: A new framework for joint segmentation and quantification of left atrium and scars incorporating spatial and shape information,” *Medical image analysis*, vol. 76, p. 102303, 2022.
- [225] S. Wang, C. Qin, C. Wang, K. Wang, H. Wang, C. Chen, C. Ouyang, X. Kuang, C. Dai, Y. Mo, Z. Shi, C. Dai, X. Chen, H. Wang, and W. Bai, “The extreme cardiac mri analysis challenge under respiratory motion (cmrxmotion),” 2022.
- [226] J. Qiu, L. Li, S. Wang, K. Zhang, Y. Chen, S. Yang, and X. Zhuang, “Myops-net: Myocardial pathology segmentation with flexible combination of multi-sequence cmr images,” *Medical Image Analysis*, vol. 84, p. 102694, 2023. [Online]. Available: <https://www.sciencedirect.com/science/article/pii/S136184152200322X>
- [227] M. Antonelli, A. Reinke, S. Bakas *et al.*, “The medical segmentation decathlon,” *Nature Communications*, 2022.
- [228] “Mm-whs: Multi-modality whole heart segmentation,” <https://zmilab.github.io/zxh/0/mmwhs/>.
- [229] “2018 atria segmentation challenge,” <https://www.cardiacatlas.org/atriaseg2018-challenge/>.
- [230] “Left ventricle full quantification challenge miccai2018,” <https://lvquan18.github.io>, MICCAI 2018 in conjunction with STACOM 2018, 2018, accessed: 2023-12-01.
- [231] “Acdc dataset,” <https://www.creatis-insa-lyon.fr/Challenge/acdc/>.
- [232] D. F. Pace, A. V. Dalca, T. Geva, A. J. Powell, M. H. Moghari, and P. Golland, “Interactive whole-heart segmentation in congenital heart disease,” in *Medical Image Computing and Computer-Assisted Intervention—MICCAI 2015: 18th International Conference, Munich, Germany, October 5-9, 2015, Proceedings, Part III 18*. Springer, 2015, pp. 80–88.
- [233] O. Bernard, J. G. Bosch, B. Heyde, M. Alessandrini, D. Barbosa, S. Camarasu-Pop, F. Cervensky, S. Valette, O. Mirea, M. Bernier *et al.*, “Standardized evaluation system for left ventricular segmentation algorithms in 3d echocardiography,” *IEEE transactions on medical imaging*, vol. 35, no. 4, pp. 967–977, 2015.
- [234] C. Tobon-Gomez, A. Geers *et al.*, “Left Atrial Segmentation Challenge 2013,” 2013, available online: <https://github.com/catactg/lasc>.
- [235] R. Karim, P. Bhagiriath, P. Claus, R. J. Housden, Z. Chen, Z. Karimghaloo, H.-M. Sohn, L. L. Rodríguez, S. Vera, X. Albà *et al.*, “Evaluation of state-of-the-art segmentation algorithms for left ventricle infarct from late gadolinium enhancement mr images,” *Medical image analysis*, vol. 30, pp. 95–107, 2016.
- [236] R. Karim, “CDEMRS fibrosis scar challenge data 2012,” 2016, dataset posted on 2016-11-09, 10:43.
- [237] C. Petitjean *et al.*, “Right ventricle segmentation from cardiac mri: A collation study,” *Medical Image Analysis*, vol. 19, pp. 187–202, 2015.
- [238] Cardiac Atlas Project, “Lv segmentation challenge,” 2011, accessed: 2023-12-01.
- [239] C. G. Fonseca, M. Backhaus, D. A. Bluemke, R. D. Britten, J. D. Chung, B. R. Cowan, I. D. Dinov, J. P. Finn, P. J. Hunter, A. H. Kadish *et al.*, “The cardiac atlas project—an imaging database for computational modeling and statistical atlases of the heart,” *Bioinformatics*, vol. 27, no. 16, pp. 2288–2295, 2011.
- [240] Cardiovascular Research Grid, “Cardiovascular Research Grid (CVRG),” <https://www.cvrgrid.org/>.
- [241] “Sunnybrook Cardiac MRI Dataset,” <https://www.kaggle.com/datasets/salikhussaini49/sunnybrook-cardiac-mri>, accessed: date-of-access.
- [242] A. Andreopoulos and J. K. Tsotsos, “Efficient and generalizable statistical models of shape and appearance for analysis of cardiac mri,” *Medical image analysis*, vol. 12, no. 3, pp. 335–357, 2008.
- [243] J. Zimmermann, M. Loecher, F. O. Kolawole, K. Bäumler, K. Gifford, S. A. Dual, M. Levenston, A. L. Marsden, and D. B. Ennis, “On the impact of vessel wall stiffness on quantitative flow dynamics in a synthetic model of the thoracic aorta,” *Scientific reports*, vol. 11, no. 1, p. 6703, 2021.
- [244] M. Schaap, C. T. Metz, T. van Walsum, A. G. van der Giessen, A. C. Weustink, N. R. Mollet, C. Bauer, H. Bogunović, C. Castro, X. Deng *et al.*, “Standardized evaluation methodology and reference database for evaluating coronary artery centerline extraction algorithms,” *Medical image analysis*, vol. 13, no. 5, pp. 701–714, 2009.
- [245] M. Nekoui, J. P. Pirruccello, P. Di Achille, S. H. Choi, S. N. Friedman, V. Nauffal, K. Ng, P. Batra, J. E. Ho, A. A. Philippakis *et al.*, “Spatially distinct genetic determinants of aortic dimensions influence risks of aneurysm and stenosis,” *Journal of the American College of Cardiology*, vol. 80, no. 5, pp. 486–497, 2022.
- [246] N. Aung, J. D. Vargas, C. Yang, K. Fung, M. M. Sanghvi, S. K. Piechnik, S. Neubauer, A. Manichaikul, J. I. Rotter, K. D. Taylor *et al.*, “Genome-wide association analysis reveals insights into the genetic architecture of right ventricular structure and function,” *Nature genetics*, vol. 54, no. 6, pp. 783–791, 2022.
- [247] F. L. Bueno-Palomeque, K. A. Mountris, N. Ortigosa, R. Bailón, B. Bijmens, F. Crispi, E. Pueyo, A. Mincholé, and P. Laguna, “Qrs-t angles as markers for heart sphericity in subjects with intrauterine growth restriction: a simulation study,” *IEEE Journal of Biomedical and Health Informatics*, 2023.
- [248] T. Münzel, O. Hahad, M. Sørensen, J. Lelieveld, G. D. Duerr, M. Nieuwenhuijsen, and A. Daiber, “Environmental risk factors and cardiovascular diseases: a comprehensive expert review,” *Cardiovascular Research*, vol. 118, no. 14, pp. 2880–2902, 2022.
- [249] A. Bhatnagar, “Environmental determinants of cardiovascular disease,” *Circulation research*, vol. 121, no. 2, pp. 162–180, 2017.
- [250] T. M. Powell-Wiley, Y. Baumer, F. O. Baah, A. S. Baez, N. Farmer, C. T. Mahlobo, M. A. Pita, K. A. Potharaju, K. Tamura, and G. R. Wallen, “Social determinants of cardiovascular disease,” *Circulation research*, vol. 130, no. 5, pp. 782–799, 2022.
- [251] A. L. Barratt, Y. Li, I. Gooroodoo, A. Todd, Y. Dou, S. McAlister, and C. Semsarian, “Environmental impact of cardiovascular healthcare,” *Open Heart*, vol. 10, no. 1, p. e002279, 2023.
- [252] “Automated-cardiac-segmentation-and-disease-diagnosis,” <https://github.com/mahendrakhened/Automated-Cardiac-Segmentation-and-Disease-Diagnosis>.
- [253] V. Tran, “Cardiac-segmentation: Convolutional neural networks for cardiac segmentation,” 2017.
- [254] C. F. Baumgartner and L. M. Koch, “Public code for our submission to the 2017 acdc cardiac segmentation challenge,” 2017.
- [255] S. Vesal, “IEEE-JBHI 2020 tensorflow/keras implementation: Spatio-temporal multi-task learning for cardiac mri left ventricle quantification,” <https://github.com/sulaimanvesal/CardiacQuanNet>, 2020.
- [256] X. Xing, J. Del Ser, Y. Wu, Y. Li, J. Xia, X. Lei, D. Firmin, P. Gatehouse, and G. Yang, “Hdl: Hybrid deep learning for the synthesis of myocardial velocity maps in digital twins for cardiac analysis,” <https://github.com/ayanglab/HDL>, 2022.
- [257] Braganças, “VNet\_PyTorch-Atriaseg2018: [Short description of the repository],” [https://github.com/braganças/VNet\\_PyTorch-Atriaseg2018](https://github.com/braganças/VNet_PyTorch-Atriaseg2018), Year of the latest commit or the year of creation.
- [258] T. J. Littlejohns, J. Holliday, L. M. Gibson, S. Garratt, N. Oesingmann, F. Alfaro-Almagro, J. D. Bell, C. Boulton, R. Collins, M. C. Conroy *et al.*, “The uk biobank imaging enhancement of 100,000 participants: rationale, data collection, management and future directions,” *Nature communications*, vol. 11, no. 1, p. 2624, 2020.
- [259] “Multi-ethnic study of atherosclerosis dataset,” <https://biolincc.nhlbi.nih.gov/studies/mesa/>.
- [260] Y. Akutsu, Y. Hamazaki, T. Sekimoto, K. Kaneko, Y. Kodama, H.-L. Li, J. Suyama, T. Gokan, K. Sakai, R. Kosaki *et al.*, “Dataset of calcified plaque condition in the stenotic coronary artery lesion obtained using multidetector computed tomography to indicate the addition



- of rotational atherectomy during percutaneous coronary intervention,” *Data in Brief*, vol. 7, pp. 376–380, 2016.
- [261] “Cardiac Atlas Project,” <https://www.cardiacatlas.org/>.
- [262] M. Stephen Granite, M. Andrew Post, R. Madduri, T. Ratnanather, J. Larkin, and S. Ardekani, “The cardiovascular research grid (cvrg) project.”
- [263] C. Krittanawong, H. Zhang, Z. Wang, M. Aydar, and T. Kitai, “Artificial intelligence in precision cardiovascular medicine,” *Journal of the American College of Cardiology*, vol. 69, no. 21, pp. 2657–2664, 2017.
- [264] E. M. Antman and J. Loscalzo, “Precision medicine in cardiology,” *Nature Reviews Cardiology*, vol. 13, no. 10, pp. 591–602, 2016.
- [265] C. Martin-Isla, V. M. Campello, C. Izquierdo, Z. Raisi-Estabragh, B. Baeßler, S. E. Petersen, and K. Lekadir, “Image-based cardiac diagnosis with machine learning: a review,” *Frontiers in cardiovascular medicine*, vol. 7, p. 1, 2020.
- [266] J. Corral-Acero, F. Margara, M. Marciniak, C. Rodero, F. Loncaric, Y. Feng, A. Gilbert, J. F. Fernandes, H. A. Bukhari, A. Wajdan *et al.*, “The ‘digital twin’ to enable the vision of precision cardiology,” *European heart journal*, vol. 41, no. 48, pp. 4556–4564, 2020.
- [267] F. Tao, H. Zhang, A. Liu, and A. Y. Nee, “Digital twin in industry: State-of-the-art,” *IEEE Transactions on industrial informatics*, vol. 15, no. 4, pp. 2405–2415, 2018.
- [268] F. Viola, G. Del Corso, R. De Paulis, and R. Verzicco, “Gpu accelerated digital twins of the human heart open new routes for cardiovascular research, 2022,” *Research Square Preprint*.
- [269] G. Coorey, G. A. Figtree, D. F. Fletcher, V. J. Snelson, S. T. Vernon, D. Winlaw, S. M. Grieve, A. McEwan, J. Y. H. Yang, P. Qian *et al.*, “The health digital twin to tackle cardiovascular disease—a review of an emerging interdisciplinary field,” *NPJ digital medicine*, vol. 5, no. 1, p. 126, 2022.
- [270] S. Ghatti, L. A. Yurish, H. Shen, K. Rheuban, K. B. Enfield, N. R. Fecteau, G. Engel, and K. Dowdell, “Digital twins in healthcare: A survey of current methods,” *Archives of Clinical and Biomedical Research*, vol. 7, no. 3, pp. 365–381, 2023.
- [271] P. Lo, B. Van Ginneken, J. M. Reinhardt *et al.*, “Extraction of airways from ct (exact’09),” *IEEE Transactions on Medical Imaging*, vol. 31, no. 11, 2012.
- [272] D. P. Kingma, M. Welling *et al.*, “An introduction to variational autoencoders,” *Foundations and Trends® in Machine Learning*, vol. 12, no. 4, pp. 307–392, 2019.
- [273] X. He, C. Tan, L. Han, B. Liu, L. Axel, K. Li, and D. N. Metaxas, “Dmvr: Morphology-guided diffusion model for 3d cardiac volume reconstruction,” in *International Conference on Medical Image Computing and Computer-Assisted Intervention*. Springer, 2023, pp. 132–142.
- [274] P. Maken and A. Gupta, “2d-to-3d: A review for computational 3d image reconstruction from x-ray images,” *Archives of Computational Methods in Engineering*, 2023.
- [275] B. Mildenhall, P. P. Srinivasan, M. Tancik, J. T. Barron, R. Ramamoorthi, and R. Ng, “Nerf: Representing scenes as neural radiance fields for view synthesis,” vol. 65, no. 1. ACM New York, NY, USA, 2021.
- [276] A. Corona-Figueroa, J. Frawley *et al.*, “Mednerf: Medical neural radiance fields for reconstructing 3d-aware ct-projections from a single x-ray,” in *EMBC*. IEEE, 2022.
- [277] J. Hu, Q. Fan, S. Hu, S. Lyu, X. Wu, and X. Wang, “Umednerf: Uncertainty-aware single view volumetric rendering for medical neural radiance fields,” *arXiv e-prints*, pp. arXiv–2311, 2023.
- [278] M. Hu, S. Pan, Y. Li, and X. Yang, “Advancing medical imaging with language models: A journey from n-grams to chatgpt,” *arXiv preprint arXiv:2304.04920*, 2023.
- [279] W. X. Zhao, K. Zhou, J. Li, T. Tang, X. Wang, Y. Hou, Y. Min, B. Zhang, J. Zhang, Z. Dong *et al.*, “A survey of large language models,” *arXiv preprint arXiv:2303.18223*, 2023.
- [280] D. Umerenkov, G. Zubkova, and A. Nesterov, “Deciphering diagnoses: How large language models explanations influence clinical decision making,” *arXiv preprint arXiv:2310.01708*, 2023.
- [281] Q. Teng, Z. Liu, Y. Song, K. Han, and Y. Lu, “A survey on the interpretability of deep learning in medical diagnosis,” *Multimedia Systems*, vol. 28, no. 6, pp. 2335–2355, 2022.
- [282] H. Zhao, H. Chen, F. Yang, N. Liu, H. Deng, H. Cai, S. Wang, D. Yin, and M. Du, “Explainability for large language models: A survey,” *ACM Transactions on Intelligent Systems and Technology*, 2023.
- [283] Z. Ma, X. Wu, X. Wang, Q. Song, Y. Yin, K. Cao, Y. Wang, and J. Zhou, “An iterative multi-path fully convolutional neural network for automatic cardiac segmentation in cine mr images,” *Medical Physics*, vol. 46, no. 12, pp. 5652–5665, 2019.
- [284] C. Zhou, Q. Li, C. Li, J. Yu, Y. Liu, G. Wang, K. Zhang, C. Ji, Q. Yan, L. He *et al.*, “A comprehensive survey on pretrained foundation models: A history from bert to chatgpt,” *arXiv preprint arXiv:2302.09419*, 2023.
- [285] J. Sun, C. Zheng, E. Xie, Z. Liu, R. Chu, J. Qiu, J. Xu, M. Ding, H. Li, M. Geng *et al.*, “A survey of reasoning with foundation models,” *arXiv preprint arXiv:2312.11562*, 2023.
- [286] R. Bommasani, D. A. Hudson, E. Adeli, R. Altman, S. Arora, S. von Arx, M. S. Bernstein, J. Bohg, A. Bosselut, E. Brunskill *et al.*, “On the opportunities and risks of foundation models,” *arXiv preprint arXiv:2108.07258*, 2021.
- [287] Y. Zhou, M. A. Chia, S. K. Wagner, M. S. Ayhan, D. J. Williamson, R. R. Struyven, T. Liu, M. Xu, M. G. Lozano, P. Woodward-Court *et al.*, “A foundation model for generalizable disease detection from retinal images,” *Nature*, pp. 1–8, 2023.
- [288] C. Li, Z. Gan, Z. Yang, J. Yang, L. Li, L. Wang, and J. Gao, “Multimodal foundation models: From specialists to general-purpose assistants,” *arXiv preprint arXiv:2309.10020*, vol. 1, no. 2, p. 2, 2023.
- [289] A. Radford, K. Narasimhan, T. Salimans, I. Sutskever *et al.*, “Improving language understanding by generative pre-training,” 2018.
- [290] D. M. Nguyen, H. Nguyen, N. T. Diep, T. N. Pham, T. Cao, B. T. Nguyen, P. Swoboda, N. Ho, S. Albarqouni, P. Xie *et al.*, “Lvm-med: Learning large-scale self-supervised vision models for medical imaging via second-order graph matching,” *arXiv preprint arXiv:2306.11925*, 2023.
- [291] D. Wang, X. Wang, L. Wang, M. Li, Q. Da, X. Liu, X. Gao, J. Shen, J. He, T. Shen *et al.*, “Medfmc: A real-world dataset and benchmark for foundation model adaptation in medical image classification,” *arXiv preprint arXiv:2306.09579*, 2023.
- [292] Z. Wang, C. Liu, S. Zhang, and Q. Dou, “Foundation model for endoscopy video analysis via large-scale self-supervised pre-train,” in *International Conference on Medical Image Computing and Computer-Assisted Intervention*. Springer, 2023, pp. 101–111.
- [293] B. Azad, R. Azad, S. Eskandari, A. Bozorgpour, A. Kazerouni, I. Rekik, and D. Merhof, “Foundational models in medical imaging: A comprehensive survey and future vision,” *arXiv preprint arXiv:2310.18689*, 2023.
- [294] S. Zhang and D. Metaxas, “On the challenges and perspectives of foundation models for medical image analysis,” *arXiv preprint arXiv:2306.05705*, 2023.
- [295] C. Li, C. Wong, S. Zhang, N. Usuyama, H. Liu, J. Yang, T. Naumann, H. Poon, and J. Gao, “Llava-med: Training a large language-and-vision assistant for biomedicine in one day,” *arXiv preprint arXiv:2306.00890*, 2023.
- [296] J. Ma, Y. He, F. Li, L. Han, C. You, and B. Wang, “Segment anything in medical images,” *Nature Communications*, vol. 15, no. 1, p. 654, 2024.
- [297] Y. Zhang, J. Gao, Z. Tan, L. Zhou, K. Ding, M. Zhou, S. Zhang, and D. Wang, “Data-centric foundation models in computational healthcare: A survey,” *arXiv preprint arXiv:2401.02458*, 2024.
- [298] A. Gu and T. Dao, “Mamba: Linear-time sequence modeling with selective state spaces,” *arXiv preprint arXiv:2312.00752*, 2023.
- [299] Z. Xing, T. Ye, Y. Yang, G. Liu, and L. Zhu, “Segmamba: Long-range sequential modeling mamba for 3d medical image segmentation,” *arXiv preprint arXiv:2401.13560*, 2024.
- [300] J. Ma, F. Li, and B. Wang, “U-mamba: Enhancing long-range dependency for biomedical image segmentation,” *arXiv preprint arXiv:2401.04722*, 2024.