
FROM TEXT TO IMAGE: EXPLORING GPT-4VISION'S POTENTIAL IN ADVANCED RADIOLOGICAL ANALYSIS ACROSS SUBSPECIALTIES

Felix Busch

Department of Radiology
Charité – Universitätsmedizin Berlin
Berlin, Germany

Tianyu Han

Department of Radiology
University Hospital Aachen
Aachen, Germany

Marcus Makowski

Department of Diagnostic and Interventional Radiology
Technical University of Munich
Munich, Germany

Daniel Truhn

Department of Radiology
University Hospital Aachen
Aachen, Germany

Keno Bressemer*

Department of Radiology
Charité – Universitätsmedizin Berlin
Berlin, Germany
keno-kyrill.bressemer@charite.de

Lisa Adams*

Department of Diagnostic and Interventional Radiology
Technical University of Munich
Munich, Germany

***contributed equally**

1 Introduction

The launch of GPT-4 (Generative Pre-trained Transformers) has generated significant interest in the scientific and medical communities. Its capabilities have been demonstrated in various medical fields, with notable achievements such as reaching 83.76% zero-shot accuracy on the United States Medical Licensing Examination (USMLE) [1]. In radiology, GPT has been used for a variety of text-based applications, ranging from evaluation of board exam questions to data mining and report structuring [2, 3]. The recent release of GPT-4's visual capabilities (GPT-4V) now allows a first evaluation in the imaging domain [4]. GPT-4V is a multimodal system that allows users to input both textual descriptions and visual data, opening new avenues for advanced radiological analysis. This study aims to evaluate the diagnostic ability of both GPT-4 and GPT-4V in advanced radiological tasks.

2 Materials and Methods

We sourced 207 cases with 1312 images from the Radiological Society of North America (RSNA) Case Collection, accessible at <https://cases.rsna.org/>, to obtain a representative sample from each subspecialty. Each model's evaluation comprised two tasks repeated three times to assess consistency and reliability and to increase the robustness of our findings. First, the model was asked to recognize the diagnosis and offer two differential diagnoses; second, it was asked to select the appropriate answer from a set of multiple-choice questions. The mean accuracy across the three iterations was calculated, with bootstrapped 95% confidence intervals (CI) to provide a measure of precision. The McNemar test was used to test for statistical significance, with a p-value of $<.001$ considered significant. For the evaluation of GPT-4V, we used a 'chain-of-thought' style prompting approach. The 'chain-of-thought' prompting technique involves guiding the AI model through a step-by-step reasoning process, much like how a human would approach a problem-solving

task. The model was first instructed to describe the images and then to make a diagnostic assessment. An illustrative dialog is shown in Figure 1. For comparison, the GPT-4 model was assessed using case descriptions only.

3 Results

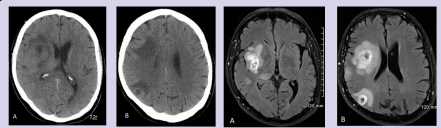
GPT-4 accurately identified the primary diagnosis in 18% (95% CI: 12%-25%) of cases (first task). When including differential diagnoses, this accuracy increased to 28% (95% CI: 22%-33%). In contrast, GPT-4V achieved a 27% (95% CI: 21%-34%) accuracy rate for primary diagnosis, which increased to 35% (95% CI: 29%-40%) when differential diagnoses were accounted for. After being presented with multiple choice questions, including clinical history and presentation (second task), GPT-4 achieved an accuracy of 47% (95% CI: 42%-56%). Again, GPT-4V demonstrated a higher accuracy of 64% (95% CI: 59%-72%). The observed difference in performance was statistically significant with a p-value < 0.0001. Across 15 subspecialties, GPT-4V outperformed GPT-4, with the sole exception being in cardiac imaging. Figure 2 summarizes the accuracies across all subspecialties.

4 Discussion

Our study suggests that GPT-4V, a multimodal AI model, outperforms GPT-4 in handling complex radiology questions, hinting at its ability to identify pathological features in medical images. The complexity of the RSNA cases, tailored for professional radiologists, sets a high standard for accuracy and highlights GPT-4V’s potential in advanced medical contexts. While the performance of the GPT-4V is promising, it should be viewed as a potential adjunct tool that may in the future augment, but not replace, the nuanced analysis provided by trained medical professionals. This study extends the preliminary work on GPT-4V’s medical image analysis capabilities, as explored by Yang et al. [5], into more complex scenarios and a broader case range. The development of other multimodal models like Med-Flamingo [6], geared towards medical applications, also illustrates the growing interest in this area. A key challenge in this field is the lack of robust, specialized medical datasets. The exclusive access of RSNA members to the cases used in our study reduces the risk of data contamination, making it unlikely that these cases were included in GPT-4V’s training data. A limitation of our study is the selective nature of the images presented to the models, chosen specifically to highlight certain pathologies. This approach does not mirror the comprehensive analysis required in clinical practice, where a full examination of all image slices is standard. This task is currently more effectively managed by specialized deep learning models rather than GPT-4V. While GPT-4V demonstrates adaptability to specialized domains, the variability in sample sizes across subspecialties calls for further, more extensive research. Our results, which show the advantage of GPT-4V over GPT-4, underscore the need for a broader exploration with large datasets to fully determine their role in radiology.

References

- [1] Harsha Nori, Nicholas King, Scott Mayer McKinney, Dean Carignan, and Eric Horvitz. Capabilities of GPT-4 on medical challenge problems. March 2023.
- [2] Lisa C Adams, Daniel Truhn, Felix Busch, Avan Kader, Stefan M Niehues, Marcus R Makowski, and Keno K Bressemer. Leveraging GPT-4 for post hoc transformation of free-text radiology reports into structured reporting: A multilingual feasibility study. *Radiology*, 307(4):e230725, May 2023.
- [3] Rajesh Bhayana, Satheesh Krishna, and Robert R Bleakney. Performance of ChatGPT on a radiology board-style examination: Insights into current strengths and limitations. *Radiology*, May 2023.
- [4] GPT-4V(ision) system card. <https://openai.com/research/gpt-4v-system-card>. Accessed: 2023-10-14.
- [5] Zhengyuan Yang, Linjie Li, Kevin Lin, Jianfeng Wang, Chung-Ching Lin, Zicheng Liu, and Lijuan Wang. The dawn of LMMs: Preliminary explorations with GPT-4V(ision). September 2023.
- [6] Michael Moor, Qian Huang, Shirley Wu, Michihiro Yasunaga, Cyril Zakka, Yash Dalmia, Eduardo Pontes Reis, Pranav Rajpurkar, and Jure Leskovec. Med-Flamingo: a multimodal medical few-shot learner. July 2023.



You are an AI assistant from now on. Pretend you are a radiologist.
Further information: I will provide 11 radiological images of a single patient over 3 prompts, counted from the 4 images attached now. This is the corresponding clinical history of the patient: "Clinical history & presentation: 72-year-old man presented to the emergency department with a 2 day history of left foot drop and speech disturbance. There was no relevant prior medical history. The patient was a non-smoker and had a family history of colon and breast cancer. The patient was admitted to neurosurgery, and underwent surgical resection, followed by chemoradiation."
Your task: After I have provided you with all 11 images, proceed as follows, considering all images and the clinical history provided:
1) Summarize the radiological findings for all 11 images provided.
2) State the most probable diagnosis and two other probable differential diagnoses

Alright, based on the images provided and the clinical history:

Radiological Findings:

- Axial T1-Weighted MRI:** The provided images demonstrate an irregularly shaped, non-homogeneous mass lesion in the right cerebral hemisphere. The lesion is hypointense in comparison to the surrounding brain tissue.
- Axial T2-Weighted MRI:** The lesion shows a mix of hyperintense and hypointense regions, indicative of heterogeneous content, possibly suggesting areas of necrosis, hemorrhage, or calcification.
- Axial FLAIR MRI:** The mass displays hyperintense signal with surrounding edema, causing a mass effect on the adjacent structures and leading to the effacement of the sulci and gyri.
- Post-Contrast Axial MRI:** There's an enhancement of the lesion after the administration of contrast, especially at its periphery, suggesting an active and possibly aggressive lesion.
- Functional MRI (fMRI) Images:** The color-coded images indicate areas of increased brain activity or blood flow. The lesion disrupts the usual pattern of activity in the right cerebral hemisphere.
- MRS (Magnetic Resonance Spectroscopy):** The spectrum reveals an elevated peak of choline (Cho), decreased N-acetylaspartate (NAA), and presence of creatine (Cr). This pattern is often indicative of increased cellular turnover and decreased neuronal integrity.

Diagnosis:

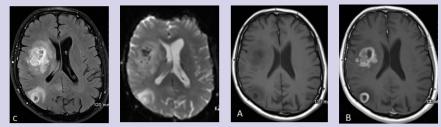
Most Probable Diagnosis:
Glioblastoma multiforme (GBM): Given the age of the patient, the appearance of the lesion on MRI, the pattern on MRS, and the rapid onset of symptoms, GBM is the most probable diagnosis. It's a highly malignant primary brain tumor known for its aggressive nature, necrosis, and vascular proliferation.

Differential Diagnoses:

- Metastatic Brain Tumor:** Considering the patient's family history of colon and breast cancer, a metastatic lesion from another primary site could be possible. Metastases can sometimes resemble primary brain tumors on imaging.
- Primary CNS Lymphoma:** Given the patient's age and the appearance of the lesion (especially post-contrast), a primary central nervous system lymphoma could also be a consideration. It often presents as a homogeneously enhancing mass.

It's essential to correlate these findings with histopathological results post-surgery for a definitive diagnosis. Always consult with a neuroradiologist and neurosurgeon for expert opinions.

Understood. Please provide the remaining images, and I will proceed as instructed after reviewing all 11 images and considering the clinical history provided.

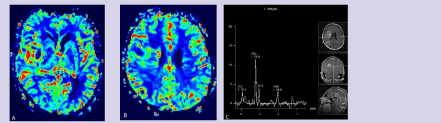


Attached are an additional 4 radiological images of the same patient. Here is again the corresponding clinical history: "Clinical history & presentation: 72-year-old man presented to the emergency department with a 2 day history of left foot drop and speech disturbance. There was no relevant prior medical history. The patient was a non-smoker and had a family history of colon and breast cancer. The patient was admitted to neurosurgery, and underwent surgical resection, followed by chemoradiation."
Three out of 11 images are remaining until proceed with the task: After I have provided you with all 11 images, proceed as follows, considering all images and the clinical history provided:
1) Summarize the radiological findings for all 11 images provided.
2) State the most probable diagnosis and two other probable differential diagnoses.

Now, considering all 11 radiological images provided throughout my last three prompts and the corresponding clinical history ("Clinical history & presentation: 72-year-old man presented to the emergency department with a 2 day history of left foot drop and speech disturbance. There was no relevant prior medical history. The patient was a non-smoker and had a family history of colon and breast cancer. The patient was admitted to neurosurgery, and underwent surgical resection, followed by chemoradiation."), select the correct response out of the following for the patient: 72-year-old man with left foot drop. What is the diagnosis?

- Multifocal Glioblastoma
- Anaplastic astrocytoma
- Metastasis
- Primary CNS lymphoma

Understood. Please continue to provide the remaining images, and I will analyze and summarize the findings once all 11 images are received, considering the clinical history provided.



Attached are the remaining 3 of 11 total radiological images. The other 8 were provided in my last two prompts. Here is again the corresponding clinical history: "Clinical history & presentation: 72-year-old man presented to the emergency department with a 2 day history of left foot drop and speech disturbance. There was no relevant prior medical history. The patient was a non-smoker and had a family history of colon and breast cancer. The patient was admitted to neurosurgery, and underwent surgical resection, followed by chemoradiation."
Now, considering all 11 images and the clinical history provided, proceed with the task:
1) Summarize the radiological findings for all 11 images provided.
2) State the most probable diagnosis and two other probable differential diagnoses.

Considering the provided clinical history, the rapid onset of symptoms, and the radiological findings from all 11 images, the most probable diagnosis for the 72-year-old man with left foot drop is:
a) Multifocal Glioblastoma.

Figure 1: Example conversation with GPT4-V showcasing the prompting style if the question contained more than four images. Notably, GPT4-V often disregards the initial textual case description when additional image prompts are introduced, necessitating its repetition for accurate responses. As the context window of the model running in the web application is unknown, as well as the image resolution and embedding size, definitive conclusions regarding the cause of this forgetfulness were not possible. Nevertheless, the model's consistent ability to recognize and recall images from the initial prompt (e.g., axial FLAIR images) suggests that running out of context length is an unlikely explanation. The models were accessed between November 6th, 2023, and November 17th, 2024. Our team utilized an API account, which allowed us to employ the models programmatically and ensure a consistent environment for each test. This access level is crucial as it provides a stable and repeatable interaction with the models, unlike what might be experienced with fluctuating conditions of regular account usage. The ground truth for each case was established based on the final diagnosis as stated in the RSNA case entries.

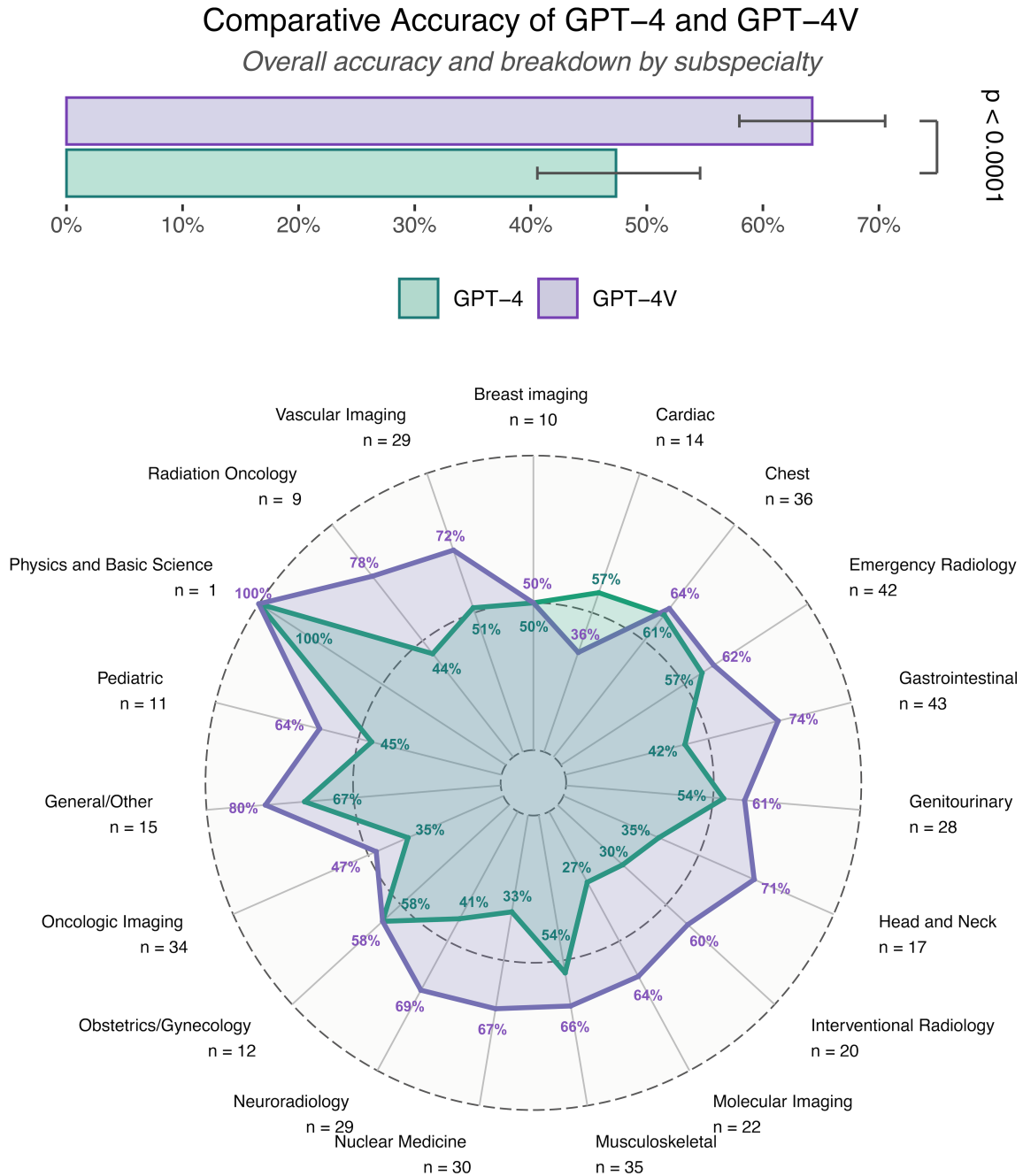


Figure 2: Comparison of GPT-4 and GPT-4V in various radiology subspecialties. Many cases spanned multiple subspecialties, and some subspecialties had very few cases. Individual cases ranged from 2 to 30 images, and the overall accuracy across all subspecialties, as shown in the bar plot, showed a significantly better performance of GPT-4 Vision over GPT-4. Error bars represent the 95% confidence interval. The radar plot shows the accuracy of GPT-4 (green line) and GPT-4V (purple line) across different radiology subspecialties. Each axis represents a specific radiology subspecialty, with the value indicating the accuracy of the model in that domain. Both models show varying levels of performance across subspecialties, with GPT-4V consistently performing better than GPT-4, except for cardiac imaging (n=14; GPT-4V: 36% versus GPT-4: 57%). This finding warrants cautious interpretation due to the relatively small number of cases in this subgroup. For physics and basic science (n=1), breast imaging (n=10), and obstetrics/gynecology (n=12), GPT-4V and GPT4 showed on-par performance (100%, 50% and 58%, respectively). The small sample sizes in these categories limit the statistical robustness of our findings. Therefore, these results should primarily be viewed as indicative trends rather than definitive conclusions about the models’ performance in these specific areas. For the category physics and basic science, no assessment is possible, as only one case was included in this category.