

Artificial Intelligence in Assessing Cardiovascular Diseases and Risk Factors via Retinal Fundus Images: A Review of the Last Decade

Mirsaeed Abdollahi¹, Ali Jafarizadeh^{1, *}, Amirhosein Ghafouri Asbagh², Navid Sobhi¹, Keysan Pourmoghtader³, Siamak Pedrammehr⁴, Houshyar Asadi⁵, Roohallah Alizadehsani^{5, *}, Ru-San Tan^{6, 7}, U. Rajendra Acharya^{8, 9}

¹*Nikookari Eye Hospital, Tabriz University of Medical Sciences, Tabriz, Iran.*

²*Cardiovascular Research Center, Tabriz University of Medical Sciences, Tabriz, Iran*

³*Research Center for Evidence-Based Medicine, Iranian EBM Centre: A Joanna Briggs Institute Affiliated Group, Tabriz University of Medical Sciences, Tabriz, Iran*

⁴*Faculty of Design, Tabriz Islamic Art University, Tabriz, Iran*

⁵*Institute for Intelligent Systems Research and Innovation (IISRI), Deakin University, VIC 3216, Australia*

⁶*National Heart Centre Singapore, Singapore.*

⁷*Duke-NUS Medical School, Singapore.*

⁸*School of Mathematics, Physics and Computing, University of Southern Queensland, Springfield, Australia*

⁹*Centre for Health Research, University of Southern Queensland, Australia*

***Corresponding Authors:**

1- Roohallah Alizadehsani, PhD

Institute for Intelligent Systems Research and Innovation (IISRI), Deakin University, VIC 3216, Australia

Tel: +61 3 524 79394

Postal: 75 Pigdons Rd, Waurin Ponds VIC 3216, Australia

Email: r.alizadehsani@deakin.edu.au

<https://orcid.org/0000-0003-0898-5054>

2- Ali Jafarizadeh, MD, MPH

Nikookari Eye Center, Tabriz University of Medical Sciences, Tabriz, Iran

Tel: +98 901 098 0062

Postal code: 51666/14766

Email: Jafarizadeha@tbzmed.ac.ir, Ali.jafarizadeh.md@gmail.com

<https://orcid.org/0000-0003-4922-1923>

Abstract

Background: Cardiovascular diseases (CVDs) continue to be the leading cause of mortality on a global scale. In recent years, the application of artificial intelligence (AI) techniques, particularly deep learning (DL), has gained considerable popularity for evaluating the various aspects of CVDs. Moreover, using fundus images and optical coherence tomography angiography (OCTA) to diagnose retinal diseases has been extensively studied. To better understand heart function and anticipate changes based on microvascular characteristics and function, researchers are currently exploring the integration of AI with non-invasive retinal scanning. Leveraging AI-assisted early detection and prediction of cardiovascular diseases on a large scale holds excellent potential to mitigate cardiovascular events and alleviate the economic burden on healthcare systems.

Method: A comprehensive search was conducted across various databases, including PubMed, Medline, Google Scholar, Scopus, Web of Sciences, IEEE Xplore, and ACM Digital Library, using specific keywords related to cardiovascular diseases and artificial intelligence.

Results: A total of 87 English-language publications, selected for relevance were included in the study, and additional references were considered. This study presents an overview of the current advancements and challenges in employing retinal imaging and artificial intelligence to identify cardiovascular disorders and provides insights for further exploration in this field.

Conclusion: Researchers aim to develop precise disease prognosis patterns as the aging population and global CVD burden increase. AI and deep learning are transforming healthcare, offering the potential for single retinal image-based diagnosis of various CVDs, albeit with the need for accelerated adoption in healthcare systems.

Keywords: Cardiovascular Disease, Artificial intelligence, Retinal Images, Fundus Images, Deep Learning, Early Detection, Non-invasive Approach, Review

1. Introduction

Cardiovascular diseases (CVDs) constitute a leading cause of death, accounting for approximately 18.6 million deaths in 2019 [1] and 17.9 million deaths in 2016, which represented 32% of global deaths and 40% of the deaths of people below 70 years of age; two-thirds of total deaths occur in developing countries [2, 3]. The annual cost of CVD management in the United States was estimated at \$351.3 billion in 2015 and accounted for the highest cost in all age and sex groups [4]. Age, sex, smoking, obesity, diabetes, hypertension, hypercholesterolemia, and low physical activity are known risk factors for CVD [5]. Imaging modalities such as echocardiography, ultrasonography, magnetic resonance imaging, cardiac computed tomography, and single-photon emission computerized tomography are used to diagnose CVDs; the clinical uptake has seen rapid growth [6]. In recent years, non-invasive modality retinal imaging, which allows direct visualization of the retina and retinal vasculature, has emerged as a method for evaluating cardiovascular health, with several studies showing associations between CVDs and altered retinal vascular and non-vascular regions [7, 8]. Interpretation of these images requires expertise and timing. Further, CVD may induce subtle local and global changes in image features that may not be clinically apparent. The use of artificial intelligence (AI) can potentially automate retinal image analysis and uncover patterns associated with disease. Of note, the fundal image of the retina is easy to acquire, cheap, and eminently suited for artificial intelligence (AI)-assisted interpretation [9].

AI tools include machine learning (ML), which predicts datasets using features handcrafted by domain experts, and deep learning (DL), which enables end-to-end learning on large annotated datasets without the need for manual intervention [10, 11]. While conventional ML must rely on pre-defined extraction functions to learn from the input data, DL employs multi-layer

computational networks that can learn from data in the original form. DL networks encompass diverse types, each designed to fit unique purposes. In feedforward neural networks (FNNs), information flows only in one direction from the input layer, through the hidden layers, to the output layer. Recurrent neural networks (RNNs) retain memory from preceding inputs and are suited for processing sequential data like time series or natural language. Convolutional neural networks (CNNs) exploit spatial hierarchies in data and are adept at image recognition tasks, including medical image analysis [12-14]. Various CNN architectures have evolved to target specific problems, e.g., Xception, U-Net, DenseNet, residual networks (ResNet), GoogLeNet/Inception, Visual Geometry Group (VGG) network, and AlexNet [15, 16].

In this study, we reviewed the AI methods and architectures used for analyzing retinal images to predict the presence of CVD and risk factors for CVD. The results, importance, and application of these methods are discussed, as well as current challenges and prospects.

2. Material and methods

We performed a comprehensive review of the existing literature using multiple academic databases, such as PubMed, Medline, Google Scholar, Scopus, Web of Sciences, and IEEE Xplore [17]. The scope of the investigation was restricted to scholarly publications that were published exclusively in the English language up to July 1, 2023. By reviewing the reference sections of the screened papers, more articles were gathered. For this comprehensive review, an elaborate search strategy was built using various combinations of the following keywords: "cardiovascular diseases," "cardiovascular abnormality," "heart," "retina," "fundus image," "retinal image," "diagnosis," "prognosis," "risk factor," "artificial intelligence," "deep learning," "machine learning," "prediction," "neural network" and "machine vision".

3. Results

The initial search identified 2056 research papers. 1219 duplicate papers were removed. A review of the titles and abstracts was then conducted by study authors [MA, AJ, AGA, NS], which led to the exclusion of 698 articles that did not meet the specified criteria. A comprehensive review of the full-text articles was conducted by study authors [MA, AJ, AGA, NS], which excluded another 52 publications deemed unsuitable. A final total of 87 papers were included in this review (Figure 1).

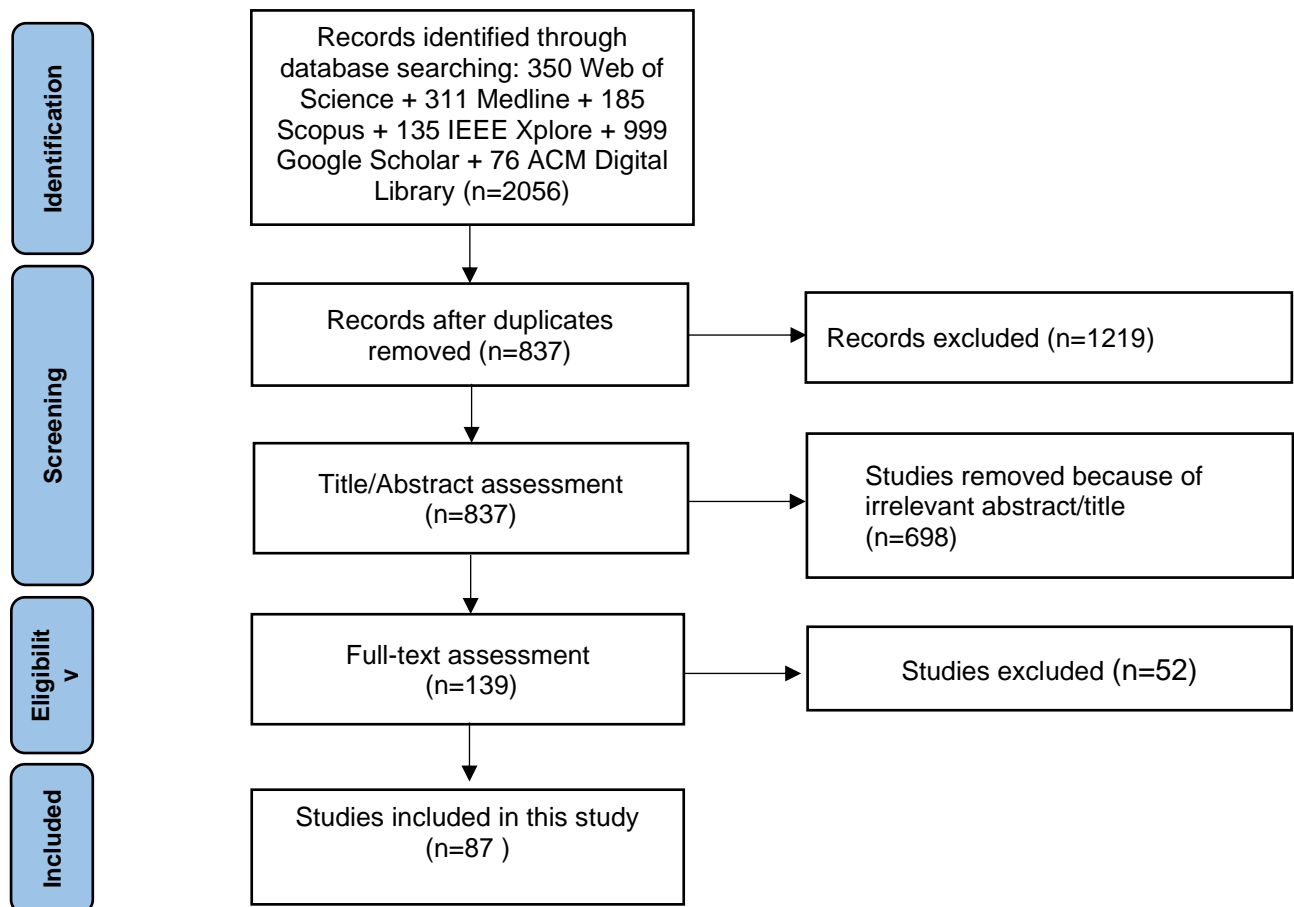


Figure 1 The Preferred Reporting Items for Systematic Reviews and Meta-Analyses (PRISMA) flow diagram.

4. Discussion

4.1 Predicting CVD Risk Factors from Fundal Retinal Images Using AI

Identifying individuals without CVD who are most at risk during CVD is an important remit of preventive population health programs [18]. Framingham risk score [19], pooled cohort equation (PCE), QRESEARCH risk estimator version 3 (QRISK3), systematic coronary risk evaluation-2 (SCORE2) [20], and atherosclerotic cardiovascular disease (ASCVD) risk estimator plus [21] are established risk for predicting the 10-year risk of developing CVD, i.e., experiencing cardiovascular event or fatality. The accuracy of the risk-stratification algorithms is generally constrained to populations in which they have been developed and requires external validation if they were to be applied to other groups. The generation of the scores requires typical input of multiple clinical parameters and laboratory results, including common variables like age, sex, ethnicity, blood pressure, smoking status, blood glucose and cholesterol levels [22, 23].

The fundus is the only place in the body where blood vessels (retinal arteries) can be directly visualized, offering a unique window into vascular health. A single non-invasive "eye check" is an attractive proposition for population screening of CVD risk. The general public is more likely to participate in eye screening than medical visits for cardiovascular assessment [24]. Between 2009 and 2013 in the United Kingdom (UK), only 12.8% of persons over 40 attended CVD screening, whereas more than 50% attended regular eye check-ups [25].

Fundal examination is traditionally conducted by doctors using either ophthalmoscopes or slit lamps. However, digital fundal photography has emerged as an essential tool for the screening of eye diseases. Significantly, fundal retinal images have also been associated with CVD and CVD

risks [26]. Retinal images require expertise and time to interpret manually but are fortunately, amenable to AI-assisted analysis. Arnould et al. [27] employed a supervised ML method to predict cardiovascular parameters using fundal images of 144 patients without known vascular occlusive disease, diabetic retinopathy, or macular degeneration. Inputting microvascular network geometrical features extracted from fundal photographs, as well as optical coherence tomography angiography, using the Singapore "I" Vessel Assessment software to naïve Bayes classification algorithm, the model was able to predict CVD risks with varying accuracies: American Heart Association risk score, 81.25%; SCORE, 75.64%; and Syntax score, 96.53%. Poplin et al. [28] used an Inception-v3-based DL model to evaluate 48,101 and 236,234 fundus images from UK Biobank and the open-access EyePACS diabetic retinopathy dataset, respectively. They demonstrated that retinal images alone were sufficient to predict age (accuracy 78%, ± 5 years error margin) and sex (area-under-curve [AUC] 0.97). For the prediction of glycated hemoglobin (HbA1c) and index of blood sugar control in diabetic patients, the accuracy was 79% ($\pm 2\%$ error margin) with a low coefficient of determination (R^2) of 0.09. A potential explanation for the latter is the higher average HbA1c (with broader distribution) and age, which attenuates the accuracy of the HbA1c prediction in the EyePACS population. For the prediction of smoking status, the AUC was 0.71. Kim et al. [29] studied 412,026 fundus images and health data (hypertension, diabetes, and smoking status) of 155,449 subjects who visited a South Korean health center between 2003 and 2016 and developed a ResNet-152-based DL predictive model. Model accuracies for age prediction (± 5 years error margin) were 82.8%, 77.6%, 77.0%, and 85.6% in the normal (without hypertension, diabetes, or smoking), hypertension, diabetes, and smoker groups, respectively, and for age prediction (± 3 years error margin), $>55\%$ in all groups. Age prediction was the highest in the third and fourth decades without significant sex differences; above 60 years of age, the

accuracy of age prediction gradually decreased. Nusinovici et al. [30] trained a DL algorithm with multilayer VGG architecture on 129,236 fundus images from 40,480 participants in the “RetiAGE” Korean Health Screening study to identify age-related retinal patterns without using any other information. The achieved area under the receiver operating characteristic curve of 0.968 (95% CI 0.96 to 0.97) and area under the precision-recall curve of 0.83 (95% CI 0.83 to 0.84) for correctly identifying individuals aged 65 years and older. Gerrits et al. [31] trained their MobileNet-V2-based model on 3,000 Qatar Biobank retinal fundus images and made predictions for age and sex using statistical measures. For age prediction, the model attained a high coefficient of determination (R^2) of 0.85 (95% CI 0.83 to 0.87) with a mean absolute error of 3.21 years. For sex prediction, they achieved a high accuracy of 0.90 (95% CI 0.89 to 0.91), with an AUC of 0.96 (95% CI 0.95 to 0.97). For HbA1c prediction, the R^2 value was lower at 0.34. For smoking status prediction, the AUC was 0.78. The authors noted that differences in dataset size, demographics, image quality, and model architecture could impact the model’s performance and generalizability.

Zhang et al. [32] developed transfer learning with the Inception-v3 CNN model to predict hyperglycemia and dyslipidemia from fundus images of 625 patients with chronic diseases in China. Trained on 1222 high-quality retinal images and over 50 anthropometry and biochemical parameter measurements, the model attained 78.7% accuracy and 0.880 AUC for detecting fasting hyperglycemia, 66.7% accuracy, and 0.703 AUC for detecting hypertriglyceridemia. Zekavat et al. [33] developed a U-Net architecture to analyze retinal vasculature in relation to phenome-wide and genome-wide studies. The model was trained on 97,895 fundus images of UK Biobank 54,813 participants. They observed that one standard deviation increments in glucose and HbA1c levels were linked to decreases in retinal vascular density (β_{Glucose} , -0.03; β_{HbA1c} , -0.01) and fractals dimensions (β_{Glucose} , -0.02; β_{HbA1c} , -0.02), which signified structural vascular deteriorations.

Vaghefi et al. [34] analyzed 165,104 fundus images from the Auckland Diabetic Eye Screening Database using a CNN-based DL model with five convolution layers, five pooling layers, and three fully-connected layers. The model predicted smoking status with AUC 0.86, which outperformed Gerrits et al. [31], in which smoking status was assessed differently, and Poplin et al. [28]. Dai et al. [35] developed a U-Net architecture for segmenting retinal blood vessels, which was trained on the Digital Retinal Images for Vessel Extraction dataset comprising 2012 fundus images sourced from 1007 and 1005 hypertensive and normotensive subjects, respectively, in China. For training and classification, a concise CNN structure was employed that contained five convolution layers, five pooling layers, and two fully connected layers. The model predicted hypertension with an AUC of 0.65.

Beyond the standard cardiovascular risk factors, the AI model can also predict other CVD-related parameters using fundus images, e.g., body mass index (57% accuracy, $\pm 3 \text{ kg/m}^2$ error margin) in Poplin et al. [28] and drinking status, salty taste, BMI, waist-to-hip ratio, and hematocrit with AUCs >0.70 in Zhang et al. [32].

Table 1 *Recent Advancements in CVD Risk Prediction.*

Study	Dataset	Training method	Results
Arnould et al. (2021) [27]	144 patients; microvascular network geometrical features extracted using Singapore "I" Vessel Assessment Software	Supervised ML; classification (k-nearest neighbors, discriminant analysis, and naïve Bayes) and regression (decision trees).	Predicted AHA, SCORE, and Syntax risk scores with 81.25%, 75.64%, and 96.53% accuracy, respectively.
Poplin et al. (2018) [28]	284,335 subjects; pooled UK Biobank and EyePACS datasets	Inception-v3 deep neural network, various training techniques.	Predicted age (78% accuracy), body mass index (57% accuracy), HbA1c (79% accuracy), sex (AUC 0.97), smoking status (AUC 0.71), and major adverse cardiovascular events within five years (AUC 0.70).
Kim et al. (2020) [29]	155,449 patients.	DL using CNNs based on ResNet-152, transfer learning using pre-trained weights from ImageNet, specific loss functions and optimization schemes.	Predicted age (82.8% accuracy, normal group; 77.6%, hypertension group; 77%, diabetes group; 85.6%, smoker group; $>55\%$, all groups).
Nusinovici et al. (2022) [30]	40,480 subjects; Korean health screening study, "RetiAGE"	DL-based on multilayer VGG architecture.	Predicted age > 65 years (AUROC 0.968, 95% CI: 0.96 – 0.97; AUPRC 0.83, 95% CI: 0.83 – 0.84).

Gerrits et al. (2020) [31]	3,000 patients; fundus images from Qatar Biobank (data augmentation were applied, including horizontal flipping, random rotation, and random shifting)	DL based on MobileNet-V2 architecture.	Predicted age ($R^2 = 0.85$), sex (and smoking status prediction with an accuracy of 0.90 and 0.81, respectively).
Zhang et al. (2020) [32]	625 patients	Transfer Learning with the Inception-v3 CNN model. The training process involved retraining the fully-connected and SoftMax layers while keeping the convolutional layers of Inception-v3 fixed /	The accuracy in detecting hyperglycemia and dyslipidemia was reported at 78.7% and 66.7%, respectively.
Zekavat et al. (2022) [33]	97,895 retinal fundus images from 54,813 UK Biobank participants	DL based on the U-Net architecture	one standard deviation increments in glucose and HbA1c levels were linked to decreases in retinal vascular density (β_{Glucose} , -0.03; β_{HbA1c} , -0.01) and fractals dimensions (β_{Glucose} , -0.02; β_{HbA1c} , -0.02).
Vaghefi et al. (2019) [34]	165,104 retinal fundus images were utilized from the Auckland Diabetic Eye Screening Database	DL uses the CNN model with five convolution layers, five pooling layers, and three fully-connected layers.	The model predicted smoking status with an AUC of 0.86
Dai et al. (2020) [35]	2012 fundus images from 1007 hypertensive and 1005 normotensive subjects of the Digital Retinal Images for Vessel Extraction dataset	With CNNs based on U-Net-based segmentation of retinal vessels	The model predicted hypertension with an AUC of 0.65.

4.2 Application of AI in fundus images.

Some areas of the fundus are more informative for detecting the presence of specific risk factors and CVDs (**Figure 2**). Researchers employ a DL technique called soft attention to locate anatomical regions the model uses to make predictions, i.e., a heatmap of the most predictive pixels within the image. Vaghefi et al. (36) demonstrated that in the attention maps from contrast-enhanced fundus images, the retinal vessels, perivascular region, and fovea consistently provided the most information for predicting an individual's smoking status. In Poplin et al. [28], the predictive models designed to estimate HbA1c levels generally focused on perivascular regions, whereas models for sex prediction primarily concentrated on the optic disc, vessels, and macula. For other predictions, including systolic blood pressure and body mass index, the attention was less specific, manifesting as either uniform attention across the image or focusing on the image's

border, suggesting that the indicators for these particular predictions were more broadly dispersed. In contrast, in Dai et al. [35], arterial/venous bifurcation regions were highlighted in the heat maps generated by their model for predicting hypertension. This disparity may be attributed to ethnic differences in the study populations. Kim et al. [29] demonstrated the significance of the fovea and retinal vessels in sex determination in an experiment. They first created modified retinal fundus images in which the fovea or retinal vessels were removed. Then they observed that the AUCs for sex prediction were 0.881 (95% CI: 0.877 - 0.885) and 0.682 (95% CI: 0.676 - 0.688) for images without the fovea and without the retinal vessels, respectively, compared to AUC of 0.97 (95% CI: 0.96 - 0.98) for the original images. Additionally, the model's class activation maps highlighted varying activation levels in different areas, such as the fovea, optic disc, and retinal artery, with significant activation in the region near the blood vessels among female subjects.

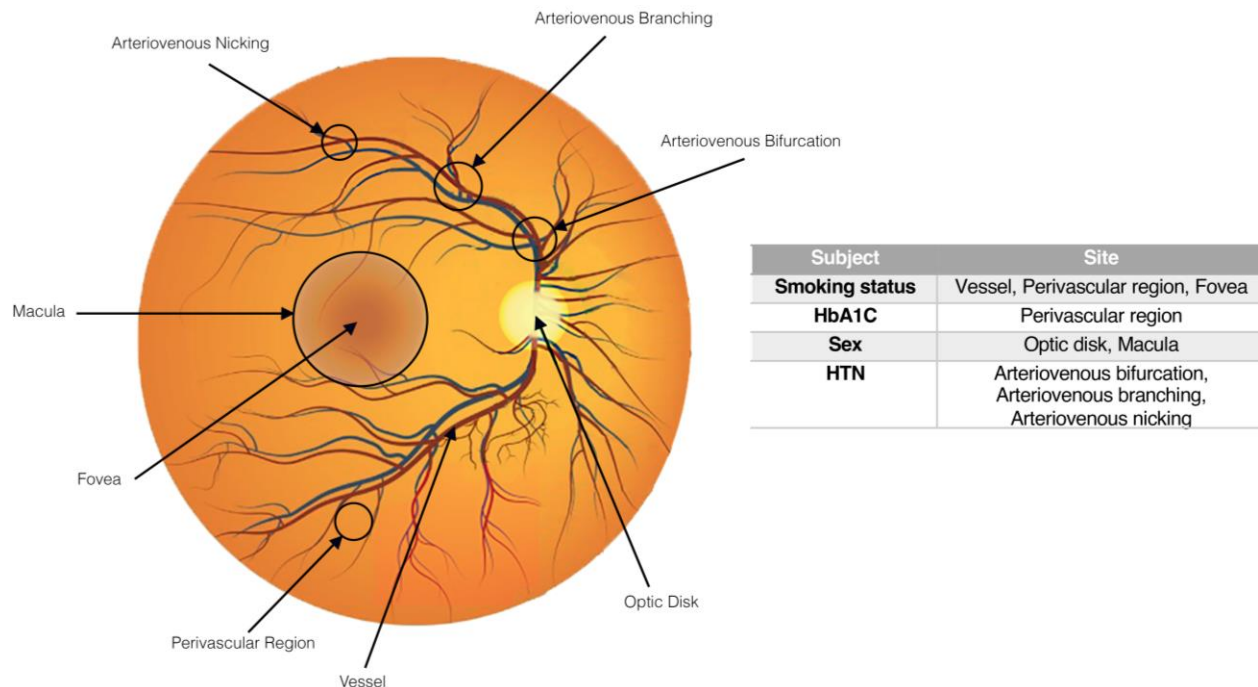


Figure 2 - Schematic fundoscopic image of the retina show the optic disc, fovea, macula, retinal vessels, and perivascular regions. Specific regions predictive of CVD risk factors are listed. HTN, hypertension.

4.3 Application of AI in predicting hypertension with fundus images

Hypertension and its associated complications are responsible for more than half of the mortality due to CVDs [36]. It causes structural and functional damage to blood vessels over time [37], altering small arteries and microcirculation, leading to end-organ damage in various systems: the heart, kidneys, brain, eyes, and peripheral vessels [38, 39]. Hypertension-induced retinal microcirculatory abnormalities include generalized or focal narrowing of retinal arterioles, arteriovenous nicking, retinal infarction (seen as white “cotton wool spots”), retinal hemorrhage, microaneurysms, as well as altered retinal geometry: tortuosity, fractal dimension, and vessel branching angle [40-42]. By evaluating these changes in the retinal microcirculation, we can predict the presence of systemic hypertension.

From the fundus images of 12,026 participants in the UK biobank dataset, Poplin et al. [28] reported accuracies of 72% (± 15 mmHg error margin) and 79% (± 10 mmHg error margin) for model prediction of systolic and diastolic blood pressures, respectively. There was a linear correlation between the predicted and actual systolic blood pressures as the latter increased to approximately 150 mmHg. In Dai et al. [35], fundus images were divided into two groups: segmented (blood vessels) and enhanced. The model predicted hypertension with an accuracy of 60.94% and an AUC of 0.65. In another study on Chinese patients, Zhang et al. [32] reported 68.8% accuracy and 0.766 AUC for predicting hypertension using their transfer learning Inception-v3-based DL model.

4.4 Atherosclerosis in retinal vessels and coronary artery diseases

Systemic arteriosclerosis—commonly caused by atherosclerotic cholesterol plaque build-up in arterial endothelium—often manifests in the retinal arteries and can be visualized as wall

thickening, lumen narrowing, and eventual occlusion [43]. These alterations mirror systemic diseases like hypertension and hyperlipidemia, the severity, onset (acute or chronic), and duration, which can influence the extent and degree of vascular changes. Hypertension not only causes retinal arteriosclerosis but can also induce vasoconstriction. Population studies have demonstrated that retinal vasculature perturbations, ranging from relatively subtle retinal arteriolar constriction to overt retinal vascular damage, are indicators of preclinical CVD and are predictive of major adverse severe cardiovascular outcomes events and mortality [44, 45].

Gao et al. [46] proposed a four-channel CNN-based DL model that could grade arteriosclerotic retinopathy using contour augmentation and image merging, yielding an accuracy of 65.354%. Chang et al. [47] developed a DL funduscopy atherosclerosis score (DL-FAS) by training their DL model on 15,408 fundus images of patients with or without atherosclerosis, as confirmed by carotid artery sonography. The fundus images were input into the model to produce scores predicted for carotid atherosclerosis. The model's weights were also adjusted to optimize the prediction. The model attained 0.583, 0.891, and 0.404 accuracy, sensitivity, and specificity, respectively, for predicting carotid atherosclerosis in a retrospective cohort of 32,227 participants aged 30 to 80 years and followed up a median of 7.6 years, DL-FAS outperformed the established Framingham risk score for prediction of cardiovascular mortality.

A preclinical indicator of coronary atherosclerosis, the coronary artery calcium score measured during coronary artery computed tomography is highly correlated with the likelihood of developing CVD and is widely used to stratify cardiovascular risk in conjunction with clinical risk factors [48]. Rim et al. [49] developed a DL algorithm, RetiCAC, for predicting coronary artery calcium scores using retinal photographs. Trained on 216,152 fundus images from five datasets sourced from centers in Singapore, South Korea, and the UK, their model attained an AUC of

0.742 (95% CI: 0.732–0.753) for binary classification of the presence of coronary artery calcium using only retinal images, which was superior to models based on clinical parameters. Son et al. [50] developed an Inception-v3 architecture for predicting coronary artery calcium based on retinal fundus images. The study subjects underwent same-day coronary artery calcium assessment and bilateral fundus photography. Using both unilateral and bilateral fundus images, the AUCs for detecting absent coronary calcium and coronary artery calcium scores greater than 100 were 82.3% and 83.2%, respectively. In addition, the authors were able to improve model performance by incorporating clinical risk factors, like age, gender, and hypertension, into their DL algorithm, as well as other fundal image inputs, like fovea-inpainted, vessels-inpainted, unilateral, and bilateral fundus images. For binary classification of coronary artery calcium score below and above 400, Barriada et al. [51] built a hybrid model encompassing VGG16 and conventional ML trained on fundus images and clinical data (e.g., age, presence of diabetic retinopathy), respectively. They proposed two practical applications from the combined analysis of fundal image and clinical data: the first application for clinical diagnosis yielded 75% recall, and the second, for image-based diagnosis, had 91% precision.

Retinal vessel caliber has been associated with the presence of cardiovascular disorders, such as carotid atherosclerosis, aortic stiffness, coronary heart disease, and stroke [52, 53]. Cheung et al. [54] trained a DL model to measure the caliber of retinal arteriolar and venular on normalized and cropped fundus images derived from a dataset comprising more than 70,000 samples. The connected layer of their DL model outputs vessel caliber measurements of input images. There were strong consensus on retinal vessel caliber measurements between the models and human experts, with correlation values ranging from 0.82 to 0.95. On a prospective dataset, retinal vessel

caliber measurements were associated with CVD risk variables like systolic blood pressure, body mass index, cholesterol, and glycated hemoglobin levels.

4.5 Fundus Images in Predicting Left Ventricular Changes

Left ventricular (LV) remodeling is the change in LV shape and function induced by myocardial injury, e.g., myocardial infarction or hemodynamic overload, mediated by molecular, cellular, and interstitial structural alterations [55-57]. These changes may lead to LV hypertrophy, impaired LV systolic and diastolic function, which manifests as heart failure (HF) [58], as well as arrhythmias like atrial fibrillation and life-threatening ventricular tachycardia/fibrillation [59, 60].

Studies have shown that retinal microvascular changes, such as retinal arteriolar narrowing or retinal venular widening, are associated with subclinical macrovascular disease, which shares the same pathophysiological pathways with and may be linked to LV remodeling, LV hypertrophy, and HF [52, 61-64]. In a study with 4,593 patients without any previous cardiac disease, Cheung et al. [62] showed that narrower retinal arterioles were associated with concentric LV remodeling (OR: 2.06; 95% CI: 1.57 - 2.70). Hondur et al. [65] showed that congestive HF causes structural changes in the choroid by altering the blood flow, with slow blood flow in large vessels causing venous blood pooling in the Haller layer and subsequent compression of the inner choroid. In a prospective cohort study involving four medical centers in the United States, Chandra et al. [66] observed associations between reduced Central retinal artery equivalent and increased central retinal vein equivalent with echocardiography-assessed LV systolic and diastolic dysfunction. To date, there is no publication on using AI to predict LV alterations or HF using fundus images, which represent an unmet clinical need.

Table 2 summarizes the performance metrics of various models and architectures employed to detect cardiovascular disease and risk factors. The metrics include accuracy, area under the curve (AUC), R-squared values, and P-values reported in different studies.

The choice of the best-performing model or architecture in the context of CVD and its risk factor prediction is contingent upon the specific risk factor and the most pertinent performance metric under consideration. In the domain of CVD risk factor prediction, the MobileNet-V2 model emerges as the top performer for predicting smoking status, while comprehensive summaries of the best-performing architectures for other factors like age and sex are detailed in **Table 2**. Furthermore, for predicting smoking status in the fundus area, the CNN models introduced in Vaghefi et al.'s study exhibit superior performance. Lastly, regarding the prediction of HTN and RetiCAC in atherosclerosis assessment, the Inception-V3 architecture stands out as the leading performer.

Table 2. *Performance Metrics of Models and Architectures for Cardiovascular Disease and Risk Factors.*

Study (year)	AI model and	Architecture	Investigation parameters	Results
<i>CVD's risk factors</i>				
Arnould et al. (2021) [27]	Supervised ML	k-nearest neighbors, discriminant analysis, and naïve Bayes	Predicted AHA, SCORE, and Syntax risk scores	81.25%, 75.64%, and 96.53% accuracy, respectively.
Poplin et al. (2018) [28]	Deep neural network	Inception-v3	Age	78% accuracy
			Body mass index	57% accuracy
			Sex	AUC 0.97
			Smoking status	AUC 0.71
			Major adverse cardiovascular events within five years	AUC 0.70
			HbA1c	79% accuracy
Kim et al. (2020) [29]	DL & transfer learning (using pre-trained weights from ImageNet) & specific loss functions and optimization schemes.	CNNs based on ResNet-152	Age	normal group=82.8%, hypertensive group=77.6%, diabetes group=77%, smoker group=85.6%, all groups >55% accuracy.
Nusinovici et al. (2022) [30]	DL	Multilayer VGG	Predicted age > 65 years	AUROC 0.968, 95% CI: 0.96 – 0.97; AUPRC 0.83, 95% CI: 0.83 – 0.84
Gerrits et al. (2020) [31]	DL	MobileNet-V2	Age prediction	$R^2 = 0.85$ (95% CI 0.83 to 0.87)
			sex prediction	$R^2 = 0.90$ (95% CI 0.89 to 0.91)

				AUC=0.96 (95% CI 0.95 to 0.97)
			HbA1c prediction	$R^2 = 0.34$
			smoking status prediction	AUC=0.78
Zhang et al. (2020) [32]	Transfer Learning and DL	Inception-v3	Hyperglycemia detection	78.7% accuracy and AUC of 0.880
			Dyslipidemia detection	66.7% accuracy and AUC of 0.703
Vaghefi et al. (2019) [34]	CNN	–	smoking status prediction	AUC of 0.86
Dai et al. (2020) [35]	CNN	U-Net	Hypertension prediction	AUC of 0.65
<i>Fundus Area</i>				
Vaghefi et al. (2019) [34]	CNN	–	smoking status prediction	AUC of 0.86
Poplin et al. (2018) [28]	Deep neural network	Inception-v3	Age	78% accuracy
			Body mass index	57% accuracy
			Sex	AUC 0.97
			Smoking status	AUC 0.71
			Major adverse cardiovascular events within five years	AUC 0.70
Dai et al. (2020) [35]	CNN	U-Net	Hypertension prediction	accuracy of 60.94% and AUC of 0.65
Kim et al. (2020) [29]	DL & transfer learning (using pre-trained weights from ImageNet) & specific	CNNs based on ResNet-152	significance of the fovea and retinal vessels in sex determination	AUC=0.881 (95% CI: 0.877 - 0.885) for images without the fovea

	loss functions and optimization schemes.			AUC=0.682 (95% CI: 0.676 - 0.688) for images without the retinal vessels, Both compared to AUC of 0.97 (95% CI: 0.96 - 0.98) for the original images.
Hypertension				
Poplin et al. (2018) [28]	Deep neural network	Inception-v3	Systolic blood pressure prediction	Accuracies=72% (± 15 mmHg error margin)
			Diastolic blood pressure prediction	Accuracies=79% (± 10 mmHg error margin)
Dai et al. (2020) [35]	CNN	U-Net	Hypertension prediction	accuracy of 60.94% and AUC of 0.65
Zhang et al. (2020) [32]	Transfer Learning and DL	Inception-v3	Hypertension prediction	68.8% accuracy and AUC of 0.766
Atherosclerosis				
Gao et al. (2021) [46]	CNN-based DL	-	arteriosclerotic retinopathy grading	Accuracy of 65.354%
Chang et al. (2020) [47]	DL	-	Carotid atherosclerosis prediction	Accuracy=0.583 Sensitivity= 0.891 Specificity=0.404
Rim et al. (2021) [49]	DL	-	RetiCAC prediction (coronary artery calcium scores using retinal photographs)	AUC of 0.742 (95% CI: 0.732–0.753)
Son et al. (2020) [50]	DL	Inception-v3	RetiCAC prediction	AUC=82.3% for detecting absent coronary calcium AUC=83.2% for coronary artery calcium scores greater than 100
Barriada et al. (2022) [51]	CNN-based DL	VGG 16	RetiCAC prediction	Accuracy=0.68 (95% CI: 0.64, 0.72)
		VGG 19		Accuracy=0.67(95% CI: 0.59, 0.75)
		ResNet		Accuracy= 0.64(95% CI: 0.53, 0.75)

Cheung et al. (2021) [54]	CNN-based DL	-	Associations between measurements of retinal-vessel caliber and cardiovascular disease.	correlation coefficients of between 0.82 and 0.95
<i>Left ventricle changes</i>				
Cheung et al. (2007) [62]	-	-	Association between concentric LV remodeling and retinal arteriole narrowing	OR: 2.06; 95% CI: 1.57 - 2.70
Hondur et al. (2020) [65]	-	-	choroid thickness in patients with CHF	In CHF=231 mm versus in control group=254 mm, p value=0.29)
			choroidal vascularity index (CVI: choroidal vessels/total choroidal area in patients with CHF	In CHF=0.53 vs in control group=0.60, P value=0.004
			the ratio of Haller's layer to total choroidal thickness (Haller/choroid ratio) in patients with CHF	In CHF=0.67 vs in control group=0.64, p value=0.01
Chandra et al. (2019) [66]	-	-	Association between central retinal venular equivalent (CRVE), central retinal arteriolar equivalent (CRAE) and incidence of HF	P value < 0.001

4.6 Databases used for AI model training

For training AI, an extensive training data volume is important to ensure model accuracy and reliability. High information load forms the foundation on which AI systems improve their learning, allowing them to recognize patterns and details across diverse situations, thereby facilitating generalizability to real-world scenarios. The UK Biobank, which encompasses 22 centers throughout England, Wales, and Scotland, is a pioneering biomedical research initiative launched in the early 2000s to enhance understanding of health conditions and diseases. It has amassed an extensive dataset of clinical, imaging, and genetic information from around 500,000 UK residents. The collected data, including medical records such as retinal images, genetic analyses, lifestyle surveys, and biospecimens, offer an unprecedented opportunity for large-scale, data-centric investigations. This information is accessible to authorized researchers, fostering collaborative efforts that have the potential to drive groundbreaking discoveries in healthcare innovation, thus solidifying the UK Biobank's role in advancing global medical science and improving healthcare outcomes [67]. Similarly, the Qatar Biobank was conceived as a pivotal platform for gathering health-related samples and lifestyle data from the Qatari population. This initiative targets the exploration of risk factors associated with prevalent health issues in the country, i.e., obesity, heart disease, diabetes, and cancers. Of note, the Qatar Biobank has actively engaged in the collection and utilization of retinal images for research purposes, which have proven invaluable in the development of DL for medical applications, including the screening of diabetic retinopathy and CVD [3, 68]. The EyePACS is an open-access diabetic retinopathy image dataset sourced from a telemedicine service provider that connects primary care practitioners with eye care experts across diverse geographies. Streamlined procedures for capturing, transmitting, and evaluating medical images are instrumental in facilitating prompt identification and

management of eye disease, as well as data mining for AI research [69, 70]. The Singapore Epidemiology of Eye Diseases Study is a multi-ethnic longitudinal population-based research investigating age-related eye diseases among Singaporean adults of Malay, Indian, and Chinese descent. Notably, it involves retinal images, making it a valuable resource for researchers in ophthalmology and epidemiology. By providing insights into the incidence, prevalence, risk factors, and novel biomarkers of eye diseases, the study allows researchers to dive deeply into the complexities of eye health within diverse populations [71]. The Cardiovascular Risk Prediction with Retinal Data amalgamates clinical data and retinal photographs from diverse data sources, which has enabled productive interdisciplinary collaborations, including cardiovascular risk prediction using fundus images. [49]. The Age-Related Eye Disease Study 1 database primarily focuses on eye diseases, particularly age-related macular degeneration (ARMD) and cataracts. However, there are potential secondary uses of this database in the field of CVD [72]. The Fundus Image Vessel Segmentation is a specialized dataset tailored for AI development in ophthalmology. With its focus on vessel segmentation of fundus images, it empowers researchers to explore AI applications for retinal image analysis. It has catalyzed advancements in computer vision and medical imaging, bridging the gap between technology and healthcare [73]. Initiated in 1975 and funded by the U.S. National Institutes of Health, Structured Analysis of the Retina is a pioneering cornerstone for retinal image analysis research [74]. Kaggle often hosts retinal image datasets as part of its data science competitions. Researchers and data scientists can search for relevant competitions and datasets related to retinal image analysis on Kaggle [75].

4.7 AI models utilized in retinal images evaluation

Studies indicate that various models and architectures have been employed to examine and analyze retinal images and their associated vasculature. Each model possesses unique

characteristics and applications beneficial to advancements in this field. Figure 3 shows the various architectures for evaluating specific CVD and its risk factors. However, each model has limitations restricting its operations.

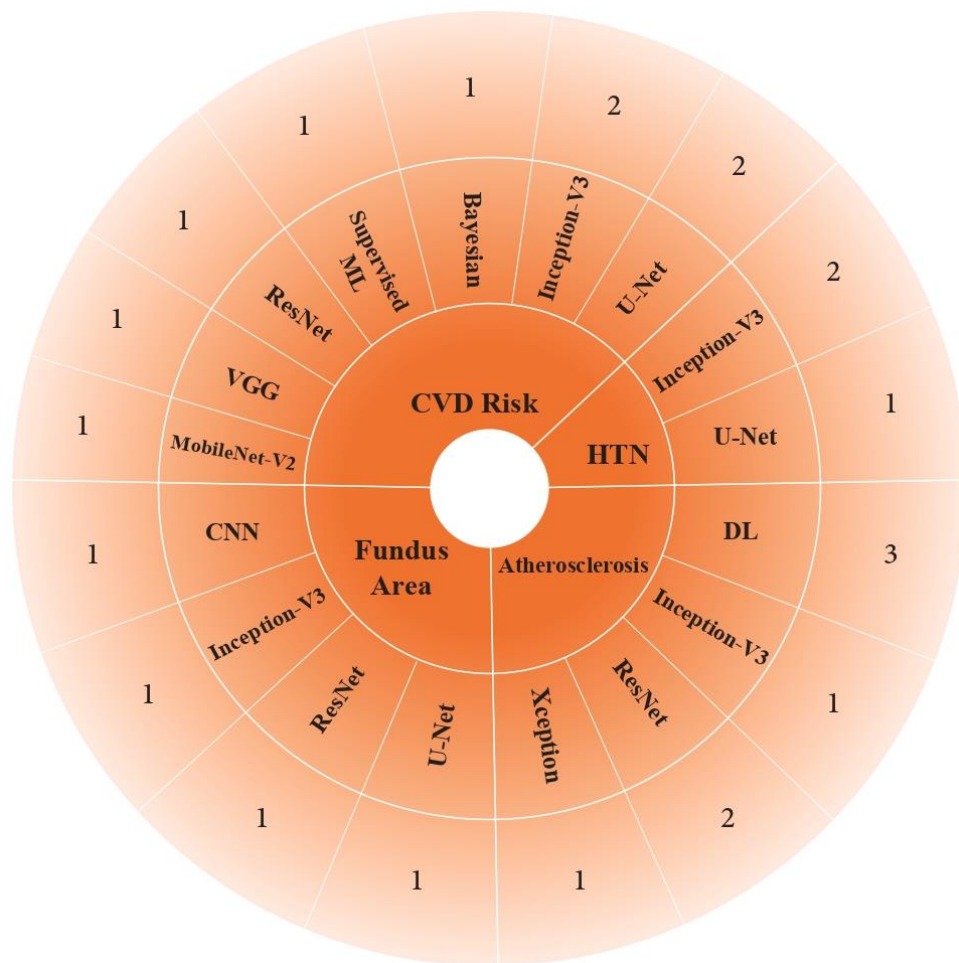


Figure 3 - Radial tree map illustrating the diversity of deep learning models employed across four predominant AI applications in our study. Each sector represents a distinct field of AI application, subdivided to portray the specific models implemented within.

ResNet and Inception-v3 are the two most commonly used advanced CNN architectures, prominently used for image analysis, including retinal images. ResNet is a groundbreaking type

of CNN that tackles a common challenge in deep learning called the "vanishing gradient problem." It does so by introducing an innovative approach called "residual learning." In simpler terms, ResNet uses building blocks called "residual blocks" that include convolutional layers and skip connections [76]. These skip connections allow the network to pass gradients without changes during training, which helps prevent the vanishing gradient issue. This architecture has significant benefits. It enables the creation of more profound, more adaptable, and scalable neural networks. As a result, ResNet has demonstrated superior performance in various computer vision tasks like image classification, object detection, and segmentation [77]. On the other hand, Inception-v3, from the GoogLeNet family, is explicitly designed for image classification, focusing on optimizing the network's performance by having complex and multi-level feature extraction mechanisms to handle large-scale image recognition tasks. Inception-v3 is characterized by its 42-layer depth and complexity [78]. Its use of factorization minimizes parameters and enhances computational efficiency by decomposing more extensive convolutions into smaller ones. It maintains a low top-5 error rate and proves robust for image classification tasks [79]. For retinal image analysis specifically, both architectures can be applied effectively, with ResNet potentially offering deeper insight due to its ability to train deeper models and Inception-v3 providing an efficient alternative with comparable proficiency [76].

Some other neural network architectures, such as MobileNet, VGG, and U-Net, are used for retinal image analysis but fundamentally differ in their structures and applications, especially in retinal image analysis (Figure 4). MobileNet, designed for mobile and embedded vision applications, is notable for its computational efficiency and compactness, making it suitable for resource-constrained devices through depth-wise separable convolutions [80]. VGG-16, recognized for its deep and straightforward architecture, excels in capturing intricate features from

images and is well-regarded for its performance in image classification. In contrast, U-Net is primarily employed for biomedical image segmentation, leveraging its unique U-shaped architecture to deliver high precision in segmentation tasks, even with limited training data [81, 82]. While MobileNet is optimized for quick classifications in constrained environments, VGG-16 is best suited for tasks requiring the extraction of detailed features due to its more profound architecture. U-Net is ideal for segmentation tasks, particularly in biomedical imaging. The choice among these models should align with the specific computational efficiency, task orientation, and application requirements of the project.

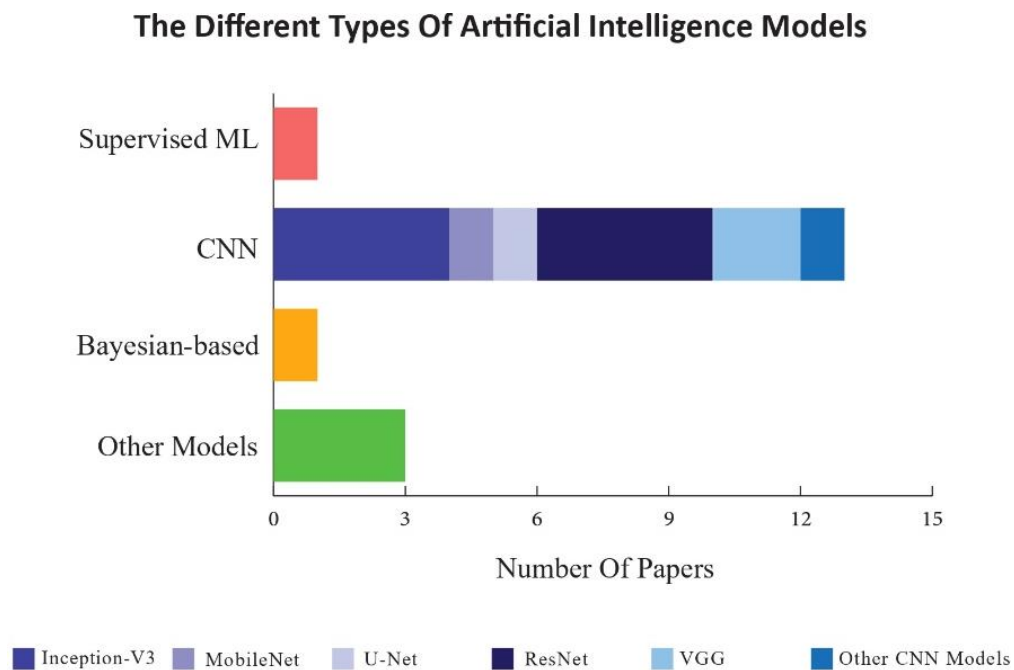


Figure 4 - The stacked bar chart depicts the diverse deep-learning models employed to assess CVD risk factors based on fundus images. Each segment within a bar represents a specific CNN model.

Furthermore, in retinal image analysis, Bayesian models use Bayesian statistics to interpret predictive uncertainty, improving robustness and reliability, and can utilize pre-trained models like VGG16 and DenseNet201 for classifying various retinal diseases [83]. In contrast, CNN-based models, a form of deep learning, employ convolutional layers to process and analyze image data efficiently and are particularly effective in tasks [84]. While the structure of CNN models is typically more straightforward and inherently optimized for image data, Bayesian models offer important insights into the reliability of predictions, a critical aspect in medical diagnoses where interpretability and uncertainty are vital.

5. Current challenges and prospects

Overall, while there is a positive perspective regarding the use of AI-based prediction for CVDs, practical implementation still faces several challenges, including:

5.1 Uncertainty in AI

In AI, uncertainty refers to situations where we lack information or struggle to accurately predict outcomes due to missing data, noisy inputs, or ambiguous circumstances. When AI systems make decisions, they often encounter uncertainty, which calls for mechanisms to handle and manage this ambiguity [85, 86]. There are various types of uncertainty, including epistemic uncertainty, which arises when we do not know about the model parameters or data. Another is aleatoric uncertainty, which comes from randomness or variability in the data. Managing uncertainty plays a role in improving decision-making processes, fortifying AI models against challenges, and ensuring performance in real-world scenarios. Techniques such as modeling Bayesian inference and quantifying uncertainty are crucial in addressing uncertainty within AI

systems. These techniques empower them to make reliable decisions even when dealing with complex and unpredictable environments [87, 88].

5.2. Concurrent disease

In retinal imaging, the coexistence of multiple retinal diseases may influence the efficacy of AI-driven CVD prediction through varied correlation effects. In clinical environments, it is common for patients to manifest with numerous disorders concurrently. AI systems' inability to make decisions independent of different retinal illnesses may severely limit their application in the general population. Multitask DL algorithms may be more valuable since they can yield many outcomes from a single retinal image, such as CVDs and retinal disorders.

5.3. Data collection and ethical issues

AI methods for detecting eye disease need many high-quality and more diverse photos. The apparent solution to expanding the number of input data for network training is to share data from multiple centers, which may require considerable financial support. However, increasing the number does not always improve network performance. To effectively predict and classify ocular and systemic diseases using retinal pictures, it is imperative to establish a precise guideline regarding the optimal number of instances required for training. When data is shared across multiple centers, international, national, and state rules, such as patients' privacy, must be considered. Furthermore, all stakeholders should work together, including regulators, insurance companies, hospital administrators, IT teams, physicians, and patients. AI must be simple and free of significant administrative obstacles to be acceptable, so the rapid distribution of results is critical.

Future studies can explore architectures like ResNet, DenseNet, or custom-designed models and incorporate more extensive datasets from a wide range of fundus images from different populations, races, or societies, employing advanced training techniques and conducting thorough external validations to improve accuracy and AUC values in this field.

5.4. Data Privacy

Utilizing medical data for AI applications raises concerns about patient privacy. Robust measures such as data encryption and informed consent can protect sensitive information.

5.5. High dimensionality of data

Medical datasets often have numerous variables, making data processing computationally demanding. Techniques like relevant variable selection and data preprocessing can reduce dimensionality.

5.6. Interpretability of AI models

Gaining trust and acceptance in medical applications requires understanding the decision-making process. Visualization techniques can enhance interpretability.

5.7. Financial support

Funding and grants are crucial for the research, development, and deployment of AI solutions. Supportive organizations and cost-sharing models can promote sustainable development.

5.8. Multidisciplinary collaboration

Collaboration across various disciplines, including medical professionals, data scientists, and AI experts, guarantees the advancement of efficient and morally sound AI resolutions.

Centralized platforms and multidisciplinary teams facilitate communication and knowledge sharing.

5.9. Adherence to rules and regulations

Compliance with relevant laws and regulations is crucial. Legal experts can provide guidance, and harmonized frameworks and guidelines specific to medical AI can ensure ethical implementation.

The challenges of AI in the context of CVD risk assessment are succinctly summarized in Figure 5.

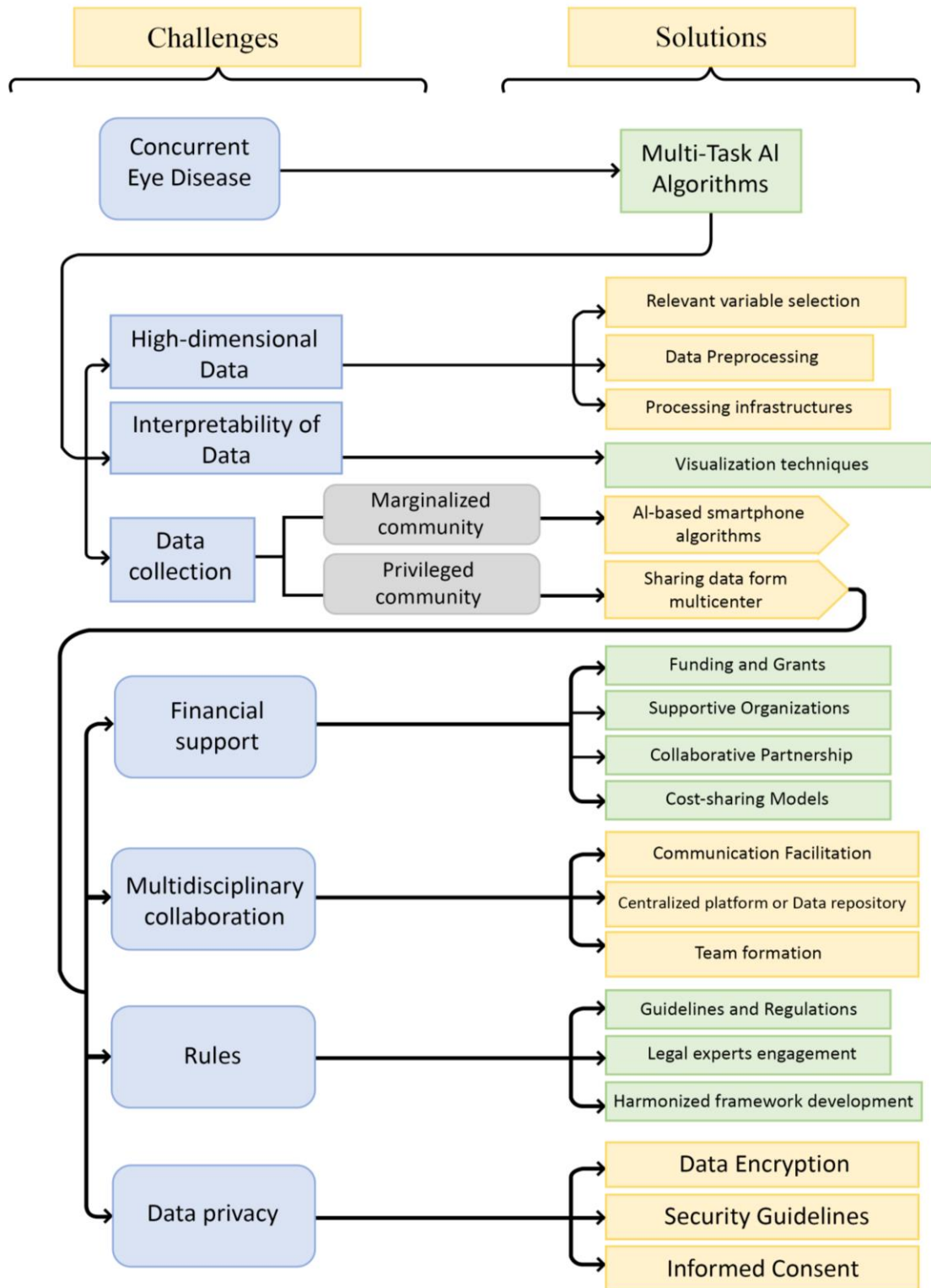


Figure 5 - An overview of the challenges in applying AI to CVD risk assessment and corresponding solutions to overcome these challenges.

6. New horizon

AI algorithms can analyze large datasets containing individual patient's genetic information, lifestyle habits, environmental factors, and medical history. By recognizing patterns and correlations in this data, AI can predict an individual's risk of developing CVD. However, it is important to remember that the successful application of AI in personalized medicine requires overcoming several challenges, such as ensuring data privacy, managing the high dimensionality of data, and improving the interpretability of AI models. Furthermore, the potential DL should not be conflated with the proficiency of a specialist. While these DL networks can excel when tasked with specific objectives, they cannot replace the expert judgment of trained retina specialists. That said, the advent of AI-based smartphone algorithms enables even those without expert training to capture and analyze images that could be significant in predicting CVD risks. With the integration of AI-based analytical tools on smartphones and through teleophthalmology, the prospect of screening for CVD risks among the general population and marginalized communities appears increasingly feasible. To validate the practical effectiveness of this technology in primary healthcare environments, conducting surveys involving both healthcare providers and patients would be advantageous. The integration of fundus eye images and the analysis of human genetic profiles holds significant promise in advancing our understanding of cardiovascular disease risk factors. Zekavat et al. [33] performed a Genome-Wide Association Study (GWAS) on retinal vascular density and fractal dimension. The study used a sample of 38,932 unrelated. The researchers analyzed 15,580,782 variants with a minor allele frequency greater than 0.001. Through their analysis, they identified 13 loci that were significantly associated with retinal vascular density and seven loci that were significantly associated with retinal fractal dimension at a genome-wide level. Encouraging further research endeavors in this domain will not only

facilitate the creation of a specialized gene mapping framework but also enable a more comprehensive assessment of cardiovascular disease susceptibility through precise genetic matching. Therefore, researchers must embark on further studies in this field, as they have the potential to uncover invaluable insights that may revolutionize the way we approach cardiovascular disease prevention and management.

Explainable AI (XAI) allows humans to understand and trust AI algorithm output. It tries to make AI models more visible and interpretable, revealing how they make decisions. Explainable AI tackles the "black-box" character of many machine learning models, which are difficult to comprehend [89]. It clarifies AI model predictions, helping people trust the algorithm's output. XAI can help identify and mitigate errors in healthcare processes, explaining recommendations and ensuring safer patient care. XAI models can analyze medical data, such as retinal images, electronic health records, and genetic information, to identify early signs of diseases. XAI can improve images by assisting radiologists in interpreting medical images. It can highlight regions of interest and explain findings, reducing diagnostic errors [90, 91].

7. Conclusion

Researchers are looking for a new and precise series of patterns to address how to detect the prognosis and severity of diseases as the global population ages and life expectancy rises. Almost always, CVDs are one of the top three reasons for mortality worldwide. As a result, early diagnosis and risk stratification significantly reduce healthcare costs and raise society's standard of health. The changes in the retina's structure and blood vessels have reflected changes in certain parts of the cardiovascular system, which has medical significance. Recently, the way we live and practice medicine has altered due to the increased usage of AI and deep learning systems. The

sector will continue to change over the next few years, but more needs to be done to accelerate the adoption of AI in healthcare systems. The idea of a machine that can scan various types of CVDs only from a single retinal image could become a reality as scientists continue to develop novel methods with greater learning capacities.

Statements and Declarations

Ethics approval and consent to participate

N/A

Consent for publication

N/A

Availability of data and materials

This review contains each and every piece of information that was gathered or investigated during the course of the study that was carried out.

Competing interests

No author states to have any conflicts of interest.

Funding

None.

Authors' contributions

AJ and RA conceptualized the manuscript. MA, AJ, NS, SP, HA, and AGA conducted a literature review and drafted the manuscript. AJ, MA, KP, RA, RST, and URA provided comments and revised the manuscript. NS and AJ created and designed all the figures. All authors read and approved the final version of the manuscript.

Acknowledgments

None.

References

- [1] Liu H, Liu X, Zhou J, Li T. Mitochondrial DNA Is a Vital Driving Force in Ischemia-Reperfusion Injury in Cardiovascular Diseases. *Oxid Med Cell Longev* 2022;2022:6235747.
- [2] Organization WH. Cardiovascular Diseases (CVDs) World Health Organization. Geneva, Switzerland 2017.
- [3] Al-Absi HR, Islam MT, Refaee MA, Chowdhury ME, Alam T. Cardiovascular Disease Diagnosis from DXA Scan and Retinal Images Using Deep Learning. *Sensors* 2022;22(12):4310.
- [4] Virani SS, Alonso A, Benjamin EJ, Bittencourt MS, Callaway CW, Carson AP, et al. Heart disease and stroke statistics—2020 update: a report from the American Heart Association. *Circulation* 2020;141(9):e139-e596.
- [5] Ghantous CM, Kamareddine L, Farhat R, Zouein FA, Mondello S, Kobeissy F, et al. Advances in cardiovascular biomarker discovery. *Biomedicines* 2020;8(12):552.
- [6] Seetharam K, Min JK. Artificial intelligence and machine learning in cardiovascular imaging. *Methodist DeBaakey Cardiovascular Journal* 2020;16(4):263.
- [7] Wang J, Jiang J, Zhang Y, Qian Y, Zhang J, Wang Z. Retinal and choroidal vascular changes in coronary heart disease: an optical coherence tomography angiography study. *Biomedical optics express* 2019;10(4):1532-44.
- [8] Farrah TE, Dhillon B, Keane PA, Webb DJ, Dhaun N. The eye, the kidney, and cardiovascular disease: old concepts, better tools, and new horizons. *Kidney international* 2020;98(2):323-42.
- [9] Mayya V, Kulkarni U, Surya DK, Acharya UR. An empirical study of preprocessing techniques with convolutional neural networks for accurate detection of chronic ocular diseases using fundus images. *Applied Intelligence* 2023;53(2):1548-66.
- [10] Tsoi K, Yiu K, Lee H, Cheng HM, Wang TD, Tay JC, et al. Applications of artificial intelligence for hypertension management. *The Journal of Clinical Hypertension* 2021;23(3):568-74.
- [11] Rauschert S, Raubenheimer K, Melton P, Huang R. Machine learning and clinical epigenetics: a review of challenges for diagnosis and classification. *Clinical epigenetics* 2020;12(1):1-11.
- [12] Chauhan NK, Singh K. A review on conventional machine learning vs deep learning. *2018 International conference on computing, power and communication technologies (GUCON)*. IEEE; 2018:347-52.
- [13] Setiowati S, Franita EL, Ardiyanto I. A review of optimization method in face recognition: Comparison deep learning and non-deep learning methods. *2017 9th International Conference on Information Technology and Electrical Engineering (ICITEE)*. IEEE; 2017:1-6.

- [14] Schmidhuber J. Deep learning in neural networks: An overview. *Neural Networks* 2015;61:85-117.
- [15] Hosseini M-P, Lu S, Kamaraj K, Slowikowski A, Venkatesh HC. Deep learning architectures. *Deep learning: concepts and architectures* 2020:1-24.
- [16] Dhillon A, Verma GK. Convolutional neural network: a review of models, methodologies and applications to object detection. *Progress in Artificial Intelligence* 2020;9(2):85-112.
- [17] Page MJ, McKenzie JE, Bossuyt PM, Boutron I, Hoffmann TC, Mulrow CD, et al. The PRISMA 2020 statement: an updated guideline for reporting systematic reviews. *Systematic Reviews* 2021;10(1):89.
- [18] Weintraub WS, Daniels SR, Burke LE, Franklin BA, Goff Jr DC, Hayman LL, et al. Value of primordial and primary prevention for cardiovascular disease: a policy statement from the American Heart Association. *Circulation* 2011;124(8):967-90.
- [19] Wilson PW, D'Agostino RB, Levy D, Belanger AM, Silbershatz H, Kannel WB. Prediction of coronary heart disease using risk factor categories. *Circulation* 1998;97(18):1837-47.
- [20] SCORE2 risk prediction algorithms: new models to estimate 10-year risk of cardiovascular disease in Europe. *European heart journal* 2021;42(25):2439-54.
- [21] American College of Cardiology. ASCVD Risk Estimator; American College of Cardiology: Washington, DC, USA, 2022.; 2022. Available from: <https://tools.acc.org/ascvd-risk-estimator-plus>.
- [22] Arnett DK, Blumenthal RS, Albert MA, Buroker AB, Goldberger ZD, Hahn EJ, et al. 2019 ACC/AHA guideline on the primary prevention of cardiovascular disease: a report of the American College of Cardiology/American Heart Association Task Force on Clinical Practice Guidelines. *Circulation* 2019;140(11):e596-e646.
- [23] Francula-Zaninovic S, Nola IA. Management of measurable variable cardiovascular disease'risk factors. *Current cardiology reviews* 2018;14(3):153-63.
- [24] Wagner SK, Fu DJ, Faes L, Liu X, Huemer J, Khalid H, et al. Insights into systemic disease through retinal imaging-based oculomics. *Translational vision science & technology* 2020;9(2):6-.
- [25] The State of the National Eye Health 2017: A Year
in Review. RNB (2018). ; 2018. Available from:
<https://www.rnib.org.uk/sites/default/files/APDF%20The%20State%20of%20the%20Nation%20Eye%20Health%202017%20A%20Year%20in%20Review.pdf>.
- [26] Sinhababu M. Procedure of Fundus Examination; 2022. Available from:
<https://optography.org/procedure-of-fundus-examination/>.
- [27] Arnould L, Guenancia C, Bourredjem A, Binquet C, Gabrielle P-H, Eid P, et al. Prediction of Cardiovascular Parameters With Supervised Machine Learning From Singapore "I" Vessel Assessment and OCT-Angiography: A Pilot Study. *Translational vision science & technology* 2021;10(13):20-.
- [28] Poplin R, Varadarajan AV, Blumer K, Liu Y, McConnell MV, Corrado GS, et al. Prediction of cardiovascular risk factors from retinal fundus photographs via deep learning. *Nature Biomedical Engineering* 2018;2(3):158-64.
- [29] Kim YD, Noh KJ, Byun SJ, Lee S, Kim T, Sunwoo L, et al. Effects of hypertension, diabetes, and smoking on age and sex prediction from retinal fundus images. *Scientific reports* 2020;10(1):1-14.
- [30] Nusinovi S, Rim TH, Yu M, Lee G, Tham Y-C, Cheung N, et al. Retinal photograph-based deep learning predicts biological age, and stratifies morbidity and mortality risk. *Age and ageing* 2022;51(4):afac065.
- [31] Gerrits N, Elen B, Craenendonck TV, Triantafyllidou D, Petropoulos IN, Malik RA, et al. Age and sex affect deep learning prediction of cardiometabolic risk factors from retinal images. *Scientific reports* 2020;10(1):9432.

- [32] Zhang L, Yuan M, An Z, Zhao X, Wu H, Li H, et al. Prediction of hypertension, hyperglycemia and dyslipidemia from retinal fundus photographs via deep learning: A cross-sectional study of chronic diseases in central China. *PloS one* 2020;15(5):e0233166.
- [33] Zekavat SM, Raghu VK, Trinder M, Ye Y, Koyama S, Honigberg MC, et al. Deep learning of the retina enables phenome-and genome-wide analyses of the microvasculature. *Circulation* 2022;145(2):134-50.
- [34] Vaghefi E, Yang S, Hill S, Humphrey G, Walker N, Squirrell D. Detection of smoking status from retinal images; a Convolutional Neural Network study. *Scientific reports* 2019;9(1):1-9.
- [35] Dai G, He W, Xu L, Pazo EE, Lin T, Liu S, et al. Exploring the effect of hypertension on retinal microvasculature using deep learning on East Asian population. *PloS one* 2020;15(3):e0230111.
- [36] Virani SS, Alonso A, Benjamin EJ, Bittencourt MS, Callaway CW, Carson AP, et al. American heart association council on epidemiology and prevention statistics committee and stroke statistics subcommittee. Heart disease and stroke statistics-2020 update: a report from the American Heart Association *Circulation* 2020;141(9):e139-e596.
- [37] Houben AJ, Martens RJ, Stehouwer CD. Assessing microvascular function in humans from a chronic disease perspective. *Journal of the American Society of Nephrology* 2017;28(12):3461-72.
- [38] HA SB, Le Noble J, Messing M, Huijberts M, Le Noble F, van Essen H. The microcirculation and hypertension. *Journal of hypertension Supplement: official journal of the International Society of Hypertension* 1992;10(7):S147-56.
- [39] Rizzoni D, Porteri E, Boari GE, De Ciuceis C, Sleiman I, Muiesan ML, et al. Prognostic significance of small-artery structure in hypertension. *Circulation* 2003;108(18):2230-5.
- [40] Smith W, Wang JJ, Wong TY, Rochtchina E, Klein R, Leeder SR, et al. Retinal arteriolar narrowing is associated with 5-year incident severe hypertension: the Blue Mountains Eye Study. *Hypertension* 2004;44(4):442-7.
- [41] Wong TY, Shankar A, Klein R, Klein BE, Hubbard LD. Prospective cohort study of retinal vessel diameters and risk of hypertension. *bmj* 2004;329(7457):79.
- [42] Wang JJ, Rochtchina E, Liew G, Tan AG, Wong TY, Leeder SR, et al. The long-term relation among retinal arteriolar narrowing, blood pressure, and incident severe hypertension. *American journal of epidemiology* 2008;168(1):80-8.
- [43] Wong TY, Shankar A, Klein R, Klein BE, Hubbard LD. Retinal arteriolar narrowing, hypertension, and subsequent risk of diabetes mellitus. *Archives of internal medicine* 2005;165(9):1060-5.
- [44] Wong TY, Cheung N, Islam FA, Klein R, Ciqui MH, Cotch MF, et al. Relation of retinopathy to coronary artery calcification: the multi-ethnic study of atherosclerosis. *American journal of epidemiology* 2008;167(1):51-8.
- [45] Seidemann SB, Claggett B, Bravo PE, Gupta A, Farhad H, Klein BE, et al. Retinal vessel calibers in predicting long-term cardiovascular outcomes: the atherosclerosis risk in communities study. *Circulation* 2016;134(18):1328-38.
- [46] Gao S, Gao L, Quan X, Zhang H, Bai H, Kang C. Automatic arteriosclerotic retinopathy grading using four-channel with image merging. *Computer Methods and Programs in Biomedicine* 2021;208:106274.
- [47] Chang J, Ko A, Park SM, Choi S, Kim K, Kim SM, et al. Association of cardiovascular mortality and deep learning-funduscopy atherosclerosis score derived from retinal fundus images. *American Journal of Ophthalmology* 2020;217:121-30.
- [48] Goff D, Lloyd-Jones D, Bennett G, Coady S, Agostino R, Gibbons R, et al. ACC/AHA Prevention Guideline: 2013 ACC/AHA Guideline on the Assessment of Cardiovascular Risk: A Report of the American College of Cardiology/American Heart Association Task Force on Practice Guidelines. *Circulation* 2014;129(25 Suppl 2):49-73.

- [49] Rim TH, Lee CJ, Tham Y-C, Cheung N, Yu M, Lee G, et al. Deep-learning-based cardiovascular risk stratification using coronary artery calcium scores predicted from retinal photographs. *The Lancet Digital Health* 2021;3(5):e306-e16.
- [50] Son J, Shin JY, Chun EJ, Jung K-H, Park KH, Park SJ. Predicting high coronary artery calcium score from retinal fundus images with deep learning algorithms. *Translational Vision Science & Technology* 2020;9(2):28-.
- [51] Barriada RG, Simó-Servat O, Planas A, Hernández C, Simó R, Masip D. Deep learning of retinal imaging: a useful tool for coronary artery calcium score prediction in diabetic patients. *Applied Sciences* 2022;12(3):1401.
- [52] Wong TY, Rosamond W, Chang PP, Couper DJ, Sharrett AR, Hubbard LD, et al. Retinopathy and risk of congestive heart failure. *Jama* 2005;293(1):63-9.
- [53] Wong TY, Klein R, Couper DJ, Cooper LS, Shahar E, Hubbard LD, et al. Retinal microvascular abnormalities and incident stroke: the Atherosclerosis Risk in Communities Study. *The Lancet* 2001;358(9288):1134-40.
- [54] Cheung CY, Xu D, Cheng C-Y, Sabanayagam C, Tham Y-C, Yu M, et al. A deep-learning system for the assessment of cardiovascular disease risk via the measurement of retinal-vessel calibre. *Nature biomedical engineering* 2021;5(6):498-508.
- [55] Udelson JE, Konstam MA. Ventricular remodeling: fundamental to the progression (and regression) of heart failure. 57. American College of Cardiology Foundation Washington, DC; 2011:1477-9.
- [56] Zeng D, Chen H, Jiang CL, Wu J. Usefulness of three-dimensional spherical index to assess different types of left ventricular remodeling: A meta-analysis. *Medicine* 2017;96(36).
- [57] Opie LH, Commerford PJ, Gersh BJ, Pfeffer MA. Controversies in ventricular remodelling. *The Lancet* 2006;367(9507):356-67.
- [58] Heidenreich PA, Bozkurt B, Aguilar D, Allen LA, Byun JJ, Colvin MM, et al. 2022 AHA/ACC/HFSA guideline for the management of heart failure: a report of the American College of Cardiology/American Heart Association Joint Committee on Clinical Practice Guidelines. *Journal of the American College of Cardiology* 2022;79(17):e263-e421.
- [59] Tsai C-H, Pan C-T, Chang Y-Y, Chen Z-W, Wu V-C, Hung C-S, et al. Left ventricular remodeling and dysfunction in primary aldosteronism. *Journal of Human Hypertension* 2021;35(2):131-47.
- [60] Ravassa S, López B, Querejeta R, Echegaray K, San José G, Moreno MU, et al. Phenotyping of myocardial fibrosis in hypertensive patients with heart failure. Influence on clinical outcome. *Journal of hypertension* 2017;35(4):853-61.
- [61] Gupta K, Reddy S. Heart, Eye, and Artificial Intelligence: A Review. *Cardiology research* 2021;12(3):132.
- [62] Cheung N, Bluemke David A, Klein R, Sharrett AR, Islam FMA, Cotch Mary F, et al. Retinal Arteriolar Narrowing and Left Ventricular Remodeling. *Journal of the American College of Cardiology* 2007;50(1):48-55.
- [63] Tikellis G, Arnett DK, Skelton TN, Taylor HW, Klein R, Couper DJ, et al. Retinal arteriolar narrowing and left ventricular hypertrophy in African Americans. the Atherosclerosis Risk in Communities (ARIC) study. *American journal of hypertension* 2008;21(3):352-9.
- [64] Chaikijurajai T, Ehlers JP, Tang WW. Retinal Microvasculature: A Potential Window Into Heart Failure Prevention. *Heart Failure* 2022;10(11):785-91.
- [65] Hondur AM, Ertop M, Topal S, Sezenoz B, Tezel TH. Optical Coherence Tomography and Angiography of Choroidal Vascular Changes in Congestive Heart Failure. *Investigative Ophthalmology & Visual Science* 2020;61(7):3204-.
- [66] Chandra A, Seidemann SB, Claggett BL, Klein BE, Klein R, Shah AM, et al. The association of retinal vessel calibres with heart failure and long-term alterations in cardiac structure and function: the

- Atherosclerosis Risk in Communities (ARIC) Study. *European Journal of Heart Failure* 2019;21(10):1207-15.
- [67] The UK Biobank; 2023. Available from: <http://www.ukbiobank.ac.uk/>.
- [68] The Qatar Biobank; 2023. Available from: <https://www.qatarbiobank.org.qa/>.
- [69] EyePACS; 2023. Available from: <https://www.eyepacs.com/>.
- [70] Cuadros J, Sim I. EyePACS: an open source clinical communication system for eye care. *MEDINFO 2004*. IOS Press; 2004:207-11.
- [71] Majithia S, Tham Y-C, Chee M-L, Nusinovič S, Teo CL, Chee M-L, et al. Cohort Profile: The Singapore Epidemiology of Eye Diseases study (SEED). *International Journal of Epidemiology* 2021;50(1):41-52.
- [72] Age-Related Eye Disease Studies (AREDS/AREDS2); 2023. Available from: <https://www.nei.nih.gov/research/clinical-trials/age-related-eye-disease-studies-aredsareds2>.
- [73] Jin K, Huang X, Zhou J, Li Y, Yan Y, Sun Y, et al. FIVES: A Fundus Image Dataset for Artificial Intelligence based Vessel Segmentation. *Scientific Data* 2022;9(1):475.
- [74] STstructured Analysis of the Retina; 2023. Available from: <https://cecas.clemson.edu/~ahoover/stare/>.
- [75] Kaggle; 2023. Available from: <https://www.kaggle.com/>.
- [76] Kurama V. A review of popular deep learning architectures: Resnet, inceptionv3, and squeezeNet. Consult August 2020;30.
- [77] Reguant R, Brunak S, Saha S. Understanding inherent image features in CNN-based assessment of diabetic retinopathy. *Scientific Reports* 2021;11(1):9704.
- [78] Patel K. Architecture comparison of alexnet, vggnet, resnet, inception, densenet. Prieiga per internetą: [https://towardsdatascience.com/architecture ...](https://towardsdatascience.com/architecture-...); 2020.
- [79] Yang Y, Zhang L, Du M, Bo J, Liu H, Ren L, et al. A comparative analysis of eleven neural networks architectures for small datasets of lung images of COVID-19 patients toward improved clinical decisions. *Comput Biol Med* 2021;139:104887.
- [80] Sarkar A. Understanding Depthwise Separable Convolutions and the efficiency of MobileNets. *Towards Data Science* 2021.
- [81] Hasal M, Pecha M, Nowaková J, Hernández-Sosa D, Snášel V, Timkovič J. Retinal Vessel Segmentation by U-Net with VGG-16 Backbone on Patched Images with Smooth Blending. *International Conference on Intelligent Networking and Collaborative Systems*. Springer; 2023:465-74.
- [82] Kugelman J, Allman J, Read SA, Vincent SJ, Tong J, Kalloniatis M, et al. A comparison of deep learning U-Net architectures for posterior segment OCT retinal layer segmentation. *Scientific reports* 2022;12(1):14888.
- [83] Subramanian M, Kumar MS, Sathishkumar VE, Prabhu J, Karthick A, Ganesh SS, et al. Diagnosis of Retinal Diseases Based on Bayesian Optimization Deep Learning Network Using Optical Coherence Tomography Images. *Comput Intell Neurosci* 2022;2022:8014979.
- [84] Alyoubi WL, Shalash WM, Abulkhair MF. Diabetic retinopathy detection through deep learning techniques: A review. *Informatics in Medicine Unlocked* 2020;20:100377.
- [85] Seoni S, Jahmunah V, Salvi M, Barua PD, Molinari F, Acharya UR. Application of uncertainty quantification to artificial intelligence in healthcare: A review of last decade (2013-2023). *Comput Biol Med* 2023;165:107441.
- [86] Nordström M. AI under great uncertainty: implications and decision strategies for public policy. *AI & SOCIETY* 2022;37(4):1703-14.
- [87] Jahmunah V, Ng EYK, Tan R-S, Oh SL, Acharya UR. Uncertainty quantification in DenseNet model using myocardial infarction ECG signals. *Computer Methods and Programs in Biomedicine* 2023;229:107308.

- [88] Gillies D. Handling uncertainty in artificial intelligence, and the Bayesian controversy. *Induction and Deduction in the Sciences* 2004:199-216.
- [89] Hulsén T. Explainable Artificial Intelligence (XAI): Concepts and Challenges in Healthcare. *AI* 2023;4(3):652-66.
- [90] Loh HW, Ooi CP, Seoni S, Barua PD, Molinari F, Acharya UR. Application of explainable artificial intelligence for healthcare: A systematic review of the last decade (2011-2022). *Comput Methods Programs Biomed* 2022;226:107161.
- [91] Jafari M, Shoeibi A, Ghassemi N, Heras J, Khosravi A, Ling S, et al. Automatic Diagnosis of Myocarditis Disease in Cardiac MRI Modality using Deep Transformers and Explainable Artificial Intelligence. 2022.