

ERCPMP: An Endoscopic Image and Video Dataset for Colorectal Polyps Morphology and Pathology

Mojgan Forootan¹, Mohsen Rajabnia², Ahmad R Mafi¹, Hamed Azhdari Tehrani³, Erfan Ghadirzadeh¹, Mahziar Setayeshfar⁴, Zahra Ghaffari¹, Mohammad Tashakoripour¹, Mohammad Reza Zali¹, Hamidreza Bolhasani^{5*}

Abstract— In the recent years, artificial intelligence (AI) and its leading subtypes, machine learning (ML) and deep learning (DL) and their applications are spreading very fast in various aspects such as medicine. Today the most important challenge of developing accurate algorithms for medical prediction, detection, diagnosis, treatment and prognosis is data. ERCPMP is an Endoscopic Image and Video Dataset for Recognition of Colorectal Polyps Morphology and Pathology. This dataset contains demographic, morphological and pathological data, endoscopic images and videos of 191 patients with colorectal polyps. Morphological data is included based on the latest international gastroenterology classification references such as Paris, Pit and JNET classification. Pathological data includes the diagnosis of the polyps including Tubular, Villous, Tubulovillous, Hyperplastic, Serrated, Inflammatory and Adenocarcinoma with Dysplasia Grade & Differentiation. The current version of this dataset is published and available on Elsevier Mendeley Dataverse and since it is under development, the latest version is accessible via: <https://databio.com>.

Keywords- Colorectal Polyps, Dataset, Endoscopy, Colonoscopy, Morphology, Surface Pattern, Pathology, Artificial Intelligence

I. INTRODUCTION

Colorectal cancer (CRC) is a significant cause of mortality worldwide, responsible for an estimated 1.9 million new cases and 935,000 deaths globally among 5.2 million diagnosed cases in 2020 as shown in Fig. 1 [1]. It is the third most prevalent malignancy worldwide and the second major cause of cancer-related mortality [1]. Detecting CRC early through screening methods like colonoscopy, fecal occult blood tests, and sigmoidoscopy is crucial for improving patient outcomes, which can detect polyps and early-stage malignancies that can be excised before they progress [2, 3].

Colorectal polyps are atypical growths found in the colon or rectum, often discovered during routine colonoscopy exams [4]. Most CRCs develop from precancerous adenomatous polyps [4, 5]. It has been demonstrated that early diagnosis and excision of precancerous colorectal polyps dramatically reduces the risk of colorectal cancer. The excision of such polyps during colonoscopy can prevent the development of cancer from these lesions [3].

Determining if a polyp is cancerous or not relies on the pathological report of histological slides obtained from it; however, certain characteristics observed during colonoscopy can suggest the invasiveness of the polyps [6]. Accurate diagnosis and characterization of these polyps are critical for optimal therapeutic care, as certain endoscopic morphological characteristics of colorectal polyps may point to a greater risk for advanced pathology, such as dysplasia or neoplasia [6, 7]. The neoplastic and benign characteristics of polyps can be viewed and evaluated during a colonoscopy [8]. Neoplastic polyps have the potential to

¹ Gastroenterology and Liver Disease Research Center, Research Institute for Gastroenterology and Liver Diseases, Shahid Beheshti University of Medical Sciences, Tehran, Iran.

² Alborz University of Medical Sciences, Alborz, Iran.

³ Department of Hematology and Medical Oncology, Shahid Beheshti University of Medical Sciences, Tehran, Iran.

⁴ Iran University of Medical Sciences

⁵ Department of Computer Engineering, Science and Research Branch, Islamic Azad University, Tehran, Iran.

* Corresponding Author: hamidreza.bolhasani@srbiau.ac.ir

develop into cancer, whereas benign polyps do not [5, 9]. The polyp's size, form, and position might also be crucial in deciding whether it should be removed or monitored [9]. Polyps can be categorized according to their morphological features and based on latest international gastroenterology classification references such as Paris, Pit, and JNET [9].

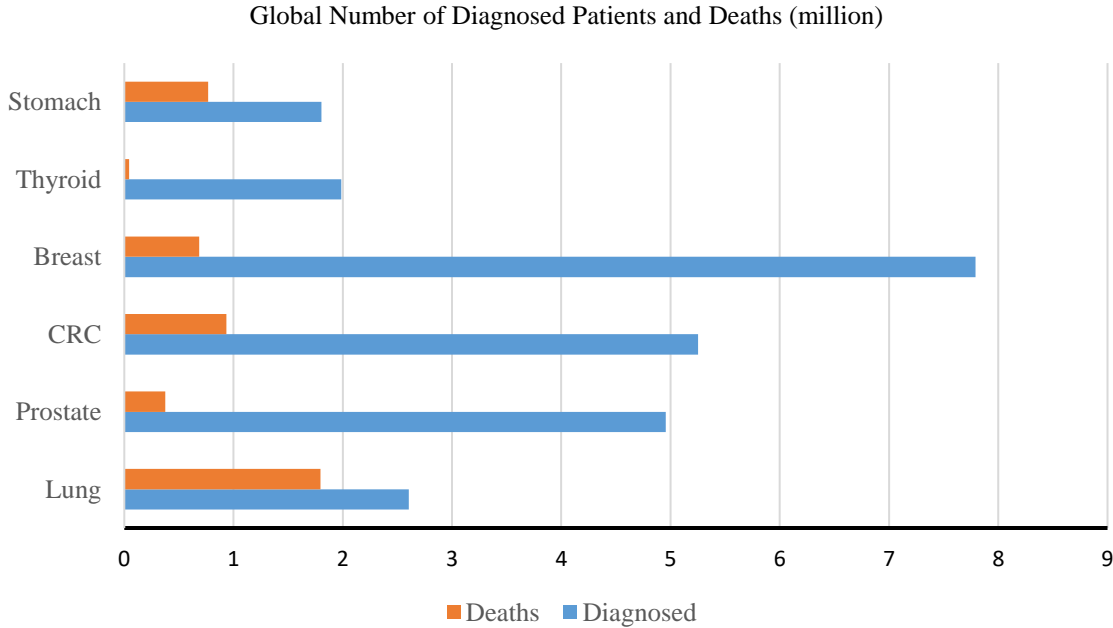


Fig. 1. Diagnosed patients and deaths of five most common cancers based on GLOBOCAN 2020.

In recent times, considerable endeavors have been undertaken to anticipate and identify various forms of cancer by utilizing artificial intelligence (AI) and its subfields, such as machine learning and deep learning [10-12]. The initial crucial phase towards accomplishing this objective involves obtaining an appropriate dataset. Consequently, this study sought to create a meticulously structured collection of images and videos encompassing demographic information, histopathological attributes (including grading, differentiation, and diagnosis), and morphological characteristics (such as size, circumference, Paris class, Pit pattern, JNET classification, and LST type) of colorectal polyps.

II. RELATED WORKS

The ERCPMP is a unique dataset that offers a valuable resource for researchers and medical professionals. The novelty of this dataset lies in its presentation of both videos and images of colorectal polyps, which allows for a more comprehensive understanding of the polyps' nature. Furthermore, the dataset also presents both morphological and pathological features of the polyps, providing a comprehensive representation of these growths. The combination of these features makes the ERCPMP dataset an essential tool for researchers and medical professionals seeking to better understand colorectal polyps and develop more effective treatments. Additionally, the dataset is well organized, making it easy to use and navigate, further enhancing its value as a research tool. In addition to the aforementioned features, it's worth noting that ERCPMP is unique in that no datasets with high similarity were found in the literature. This further underscores the novelty and importance of your work in providing a comprehensive and well-organized dataset for studying the morphological and pathological features of colorectal polyps. The absence of similar datasets highlights the need for this work and the potential impact it can have on the field of gastroenterology (Fig 1, and 2).

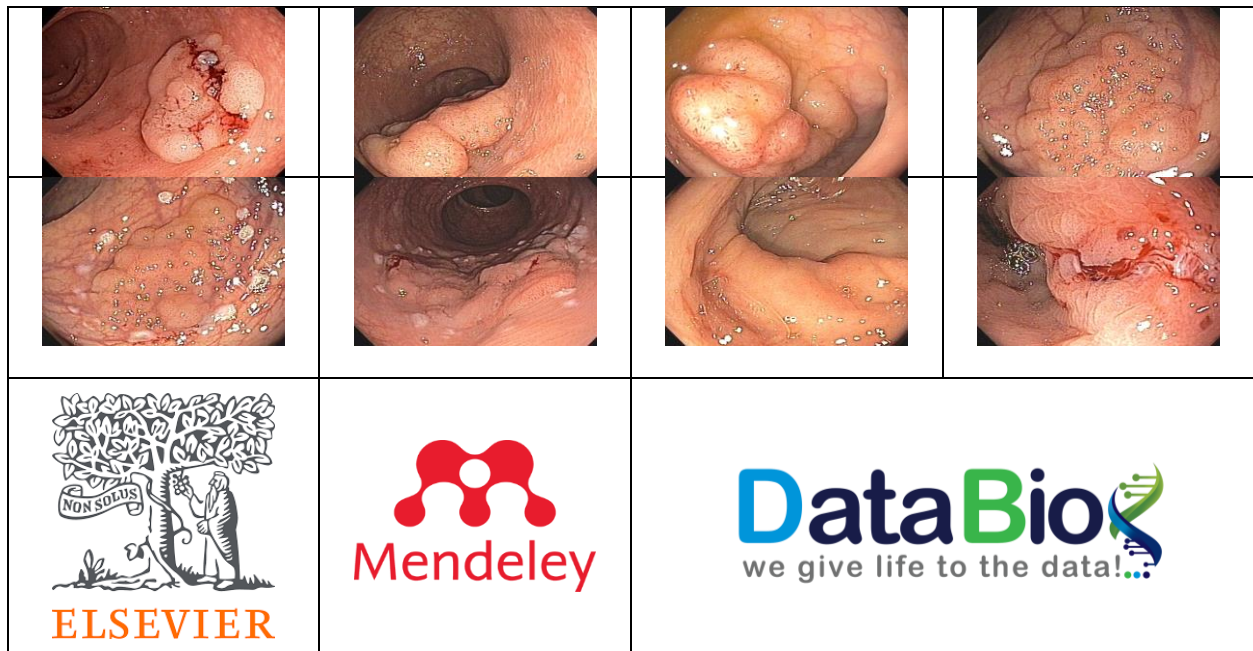


Fig. 1. Some image samples from ERCMP dataset

Some dataset such as “CVC-ClinicDB”, “ACU-Mayo Clinic Colonoscopy Video Database”, and “Kvasir-SEG” are publicly available which contain polyp images or videos (or both) [13]. These datasets are similar to ERCMP in terms of morphological assessment; however, some of them lack labeling of morphologic features and some lack the exclusivity of including histopathology. “CVC-ClinicDB” was organized by Bernal et al. [14] and contains 612 images from 29 various sequences of colonoscopy videos. “ACU-Mayo Clinic Colonoscopy Video Database” was established by Tajbakhsh et al. [15], which is a video dataset containing 20 colonoscopy videos (10 videos with colorectal polyps and 10 without).

Picon et al. [16] represented a dataset named “PICCOLO HE/MPM Image Collection” for colorectal polyps’ histopathological classification using hematoxylin-eosin and multi-photon microscopy images. The authors organized a dataset of 50 colorectal polyp samples. Images are presented in several resolutions and classified based on both pathologic classes (healthy, hyperplastic/adenoma, and adenocarcinoma) and dysplasia grade (low or high).

Chattree et al. [17] provided a 23-parameter dataset named “the ACPGIB/BSG Complex Colorectal Polyp Minimum Dataset” which includes demographic details, morphological description and polyp surface features, and histopathologic slides only in a total of 40 patients with large non-pedunculated colorectal polyps.

Borgli et al. [18] developed a general dataset for gastrointestinal (GI) endoscopy named “HyperKvasir”. This dataset comprises 10,662 labeled and 99,417 unlabeled images, and 374 videos, and shares many normal and abnormal finding during a GI endoscopy. HyperKvasir is a large and general dataset for GI endoscopy; however, the ERCMP dataset offers more specific images and videos regarding colorectal polyps morphology and histopathology.

The BioBank foundation released a public dataset named “PICCOLO RGB/NBI (Widefield) Image Collection” which is comprised of 3433 images in the PNG format, including narrow band and wight light, from 76 polyps in 48 different patients. The dataset also provides information of a polyp’s size and paris classification, as well as histological diagnosis. The ERCMP dataset offers more morphological and histological information compared to this dataset [19].

III. ERCPMP DATASET

ERCPMP is the name of the prepared image and video dataset of this research. This is a histopathological and morphological image and video dataset of 191 patients diagnosed with colorectal polyps including 796 images and 21 videos in total. These numbers are related to the current version, but it is under development to bring more data in the next versions. Images were captured with Olympus colonoscope and are presented in RGB format, JPG type with the resolution of 368 * 256 pixels and 96 dpi. Videos were captured with the same device and are presented in MP4 type. A summary of abbreviations and definitions of terms that were used in this dataset is presented in Table 1 and technical information of the dataset is presented in Table 2. File names in the dataset are based on patient codes provided in the accompanied excel file. The excel file contains information on each patient's demographic data in addition to each polyp morphological and histopathological labeling. Table 3 demonstrates what information was included for each polyp.

Patient Demographic				Anatomical Features				Morphology		Surface Pattern		Pathology	
Patient Code	Image & Video	Sex	Age	Polyp Location	Size (mm)	Circum	Cross Two Folds	Paris	LST Type	Pit	JNET	Diagnosis	Dysplasia Grade & Differentiation
23001	+	F	35	Rectum	2*2	<1/3	Neg	0-IIa	LST-G HT	III	2A	Tubular	LGD
23002	+	M	76	Rectum	3*3	<1/3	Pos	0-IIa	LST-G HT	III, IV	2A	T + V	LGD
23003	+	F	66	Rectum	4*3	<1/3	Pos	0-IIa	LST-G HT	IV, V	2B	Villous	HGD
23004	-	F	50	Rectum	3.5*1.5	<1/3	Pos	0-IIa + Is	LST-G MN	III, IV, V	2B	T + V	HGD
23005	+	F	73	Rectum	4*3	<1/3	Pos	0-IIa + Is	LST-G MN	IV, V	2B	Villous	HGD
23006	+	M	82	Rectum	4*3	<1/3	Pos	0-IIa + Ilc	LST-NG PD	III, IV	2A	T + V	LGD
23007	+	F	42	Rectum	3.5*2	<1/3	Pos	0-IIa + Is	LST-G MN	IV	2A	Villous	LGD
23008	+	F	48	Rectosigmoid	4*4	<1/3	Pos	0-IIa	LST-G HT	III, IV	2A	Serrated	T + V
23009	Image	M	68	Rectosigmoid	5*3	>1/3	Pos	0-IIa	LST-G HT	III, IV, V	3	T + V	HGD
23010	Image	F	64	Rectum	2*1.5	<1/3	Neg	0-Ips	-	III, V	2B	Tubular	HGD
23011	-	F	53	Rectum	1.5*1	<1/3	Neg	0-Is	-	III	2A	Tubular	LGD
23012	Image	M	47	Rectum	1.5*1	<1/3	Neg	0-Ips	-	III, IV	2A	T + V	LGD
23013	Image	F	73	Rectum	2*2	<1/3	Neg	0-IIa	LST-G HT	III, IV, V	2B	T + V	HGD
23014	Image	F	60	Rectum		<1/3	Neg	-	-	-	-	Adenocarcinoma	N/A
23015	Image	F	44	Rectum	2.5*2	<1/3	Neg	0-IIa + Is	LST-G HT	III, IV, V	2B	T + V	HGD
23016	+	F	57	Rectum	1	<1/3	Neg	0-Is	-	I	1	Hyperplastic	-
23017	Image	F	43	Rectum	1	<1/3	Neg	0-Is	-	I	1	Hyperplastic	-
23018	Image	M	67	Rectum	1*1	<1/3	Neg	0-Is	-	I	1	Hyperplastic	-
23019	+	F	34	Rectum	1*1	<1/3	Neg	0-Is	-	III	2A	Tubular	LGD
23020	Image	M	69	Rectum	1.5*1	<1/3	Neg	0-Ip	-	III	2A	Tubular	LGD
23021	Image	F	64	Rectum	1*1	<1/3	Neg	0-Is	-	I	1	Hyperplastic	-
23022	-	M	44	Rectum	1*1	<1/3	Neg	0-Is	-	I	1	Hyperplastic	-
23023	Image	F	32	Rectum	3*3	<1/3	Pos	0-IIa	-	III, IV, V	2B	T + V	HGD
23024	-	F	37	Rectum	1.5*2	<1/3	Neg	0-IIa	-	-	-	Inflammatory	-

Fig. 2. Scheme of ERCPMP dataset including patient demographic, anatomical features, morphology and pathology results

The ERCPMP dataset is distinct from similar datasets due to the presence of both morphological and histopathological characteristics of colorectal polyps in addition to including more polyp samples with various features. Generally, six necessary steps were implemented to arrange this dataset as listed:

1. Patients with colorectal polyps were diagnosed and their demographics were recorded
2. Polyp anatomical features, morphology features, and surface pattern were assessed and classified
3. Polyp samples were referred for histopathologic assessment
4. Histologic diagnosis and grading were recorded
5. A written informed consent was obtained from patients to include their clinical details
6. The dataset was organized

Thorough information regarding the quantity of different data in the ERCPMP dataset based on morphological and histopathologic characteristics are presented in Table 4.

IV. ANATOMICAL, MORPHOLOGICAL FEATURES AND SURFACE PATTERN

Anatomical features (location, size, circumference, cross two folds), morphological features (Paris classification, LST), and surface pattern (Kudo pit pattern, JNET) play a pivotal role in determining the clinical management and prognosis of colorectal polyps and includes many different classifications systems. Morphological features and surface pattern (Paris classification, LST, and JNET) were the basis

for selecting the lesion resection method (Endoscopic Polypectomy, EMR, ESD, FTRD).

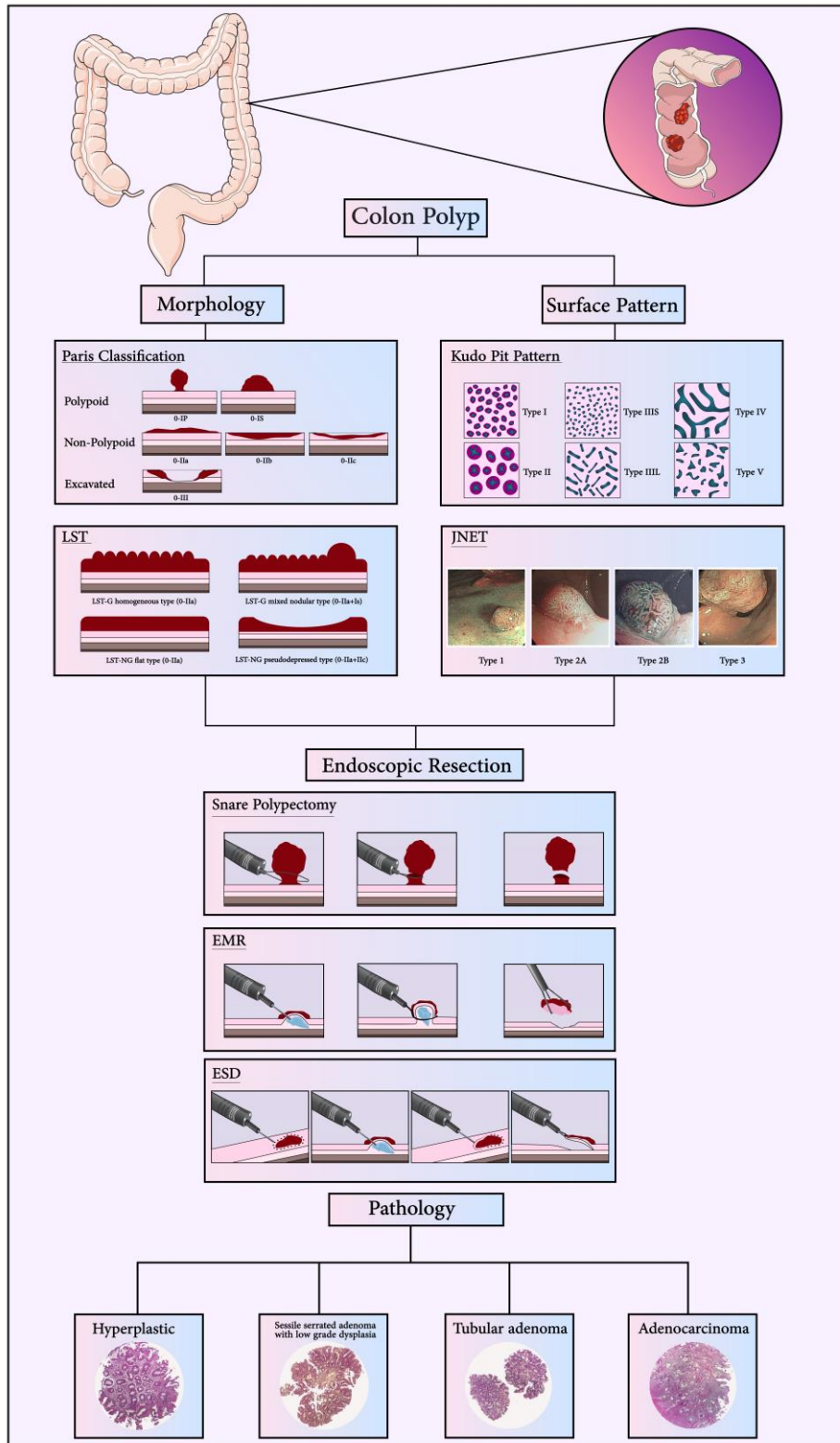


Fig. 3. Comprehensive algorithm used in preparing ERCMP

- **Paris Classification**

The Paris classification is an endoscopic classification system that focuses on the macroscopic appearance of colorectal polyps. It categorizes polyps into four types based on their morphology: polypoid (0-I and 0-IIa), non-polypoid (0-IIb and 0-IIc), and depressed (0-III and 0-Is) (Fig 3). This classification system is a standardized terminology that aids various medical specialists to communicate with each other, and assists endoscopists in determining the appropriate resection technique and predicting the risk of submucosal invasion [20, 21].

- **LST**

The LST classification system recognizes two major categories of LSTs which are lesions that grow laterally instead of upward or downward [20, 26]:

- i. LST-G:
 - LST-G
 - LST-G-H (Paris 0-IIa)
 - LST-G-NM (Paris 0-IIa and 0-Is)
- ii. LST-NG:
 - LST-NG
 - LST-NG-FE (Paris 0-IIa)
 - LST-NG-PD (Paris 0-IIa and 0-IIc)

- **Pit pattern**

Pit pattern refers to the microscopic appearance of the glandular structures within a colorectal polyp observed during magnifying endoscopy. It helps to distinguish between different histological types of polyps, aiding in risk stratification and treatment decision-making. There are several pit pattern classification systems; however, the Kudo classification is one of the most widely used. It categorizes pit patterns into five main types (from I to V) (Fig 3) [20, 24, 25].

- **JNET**

JNET classification system is a comprehensive and widely used endoscopic classification specifically designed for colorectal polyps. It incorporates the use of magnifying endoscopy with narrow-band imaging and provides a standardized framework for assessing the morphological characteristics of polyps. The classification is based on the evaluation of surface pattern, color, vessel pattern, and microsurface structure [22, 23].

The JNET classification includes three surface pattern categories; type 1 (homogeneously colored), type 2A (heterogeneously colored), and type 2B (excavated appearance). The JNET classification incorporates three color categories; light blue which indicates the presence of a superficial layer of epithelial cells, light blue-white which suggests the absence of the superficial layer and exposure of the lamina propria, and dark blue which indicates the presence of submucosal vessels. Also, the JNET classification system identifies four vessel pattern categories; type 1 (well-organized and regularly distributed vessels), type 2A (slightly distorted), type 2B (clearly distorted), type 3 (absence of any visible vessels); and two microsurface structures including open (visible crypts openings) and closed (absence of visible crypt openings). The combination of surface pattern, color, vessel pattern, and microsurface structure in JNET system provides valuable information for predicting histological characteristics of polyps and the risk of submucosal invasion, aiding in determining the need for resection or surveillance (Fig 3) [20, 22, 23].

V. HISTOPATHOLOGIC FEATURES

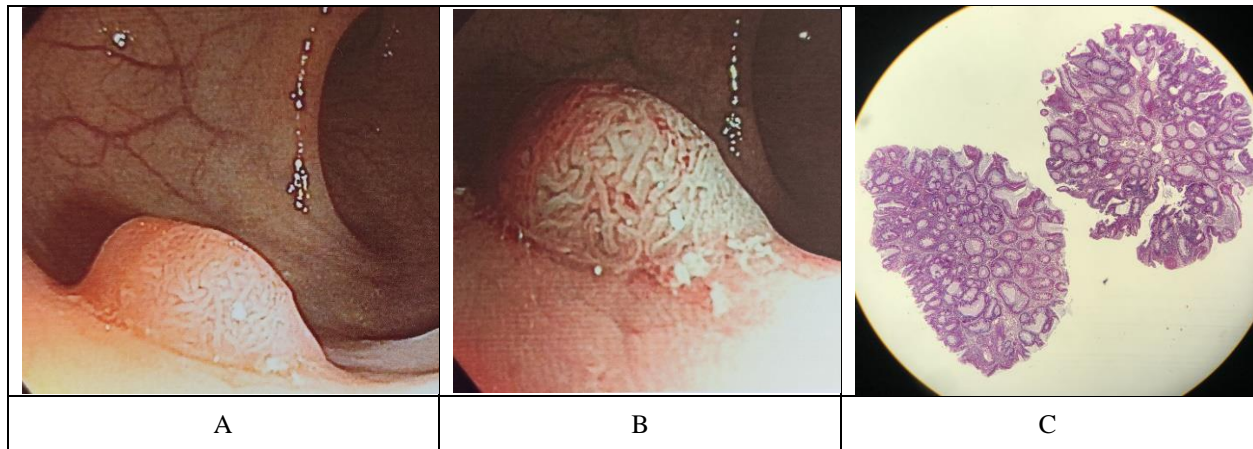
Pathological evaluation plays a crucial role in the diagnosis, differentiation, and grading of colorectal polyps. Accurate classification and characterization of polyps with a proper pathological assessment provides essential information for patient management and includes both macroscopic and microscopic evaluations. Macroscopic evaluation is the initial step in the pathological examination of colorectal polyps. It involves the assessment of polyp size, shape, color, surface characteristics (smooth or granular), and presence of features such as ulceration or depression. Microscopic evaluation involves the examination of histological features of colorectal polyps under a microscope and includes mainly of the two following aspects; histology, and differentiation and grading [20, 27-29].

Histological classification

1. Hyperplastic Polyps: Characterized by normal glandular architecture with minimal cytological abnormalities. These polyps typically show serrated epithelium and elongated crypts.
2. Adenomatous Polyps: Represented by dysplastic glandular structures, which are further classified into:
 - Tubular Adenoma: Predominantly composed of tubular structures with uniform glandular features.
 - Villous Adenoma: Composed of long, slender finger-like projections (villi).
 - Tubulovillous Adenoma: Exhibit a combination of tubular and villous architecture.

Differentiation and Grading

1. Dysplasia: Refers to the presence of abnormal cellular changes within the epithelial layer. Dysplasia is classified as:
 - Low-grade dysplasia: Mildly disordered glandular architecture with minimal cytological abnormalities.
 - High-grade dysplasia: Marked disordered glandular architecture with prominent cytological abnormalities.
2. Carcinoma: Carcinoma in Situ (CIS): Malignant cells confined to the epithelial layer without invasion into the underlying tissue.
 - Invasive Carcinoma: Malignant cells invading beyond the epithelial layer into the submucosa or deeper layers.



- A. White-light colonoscopy showing a sessile (Paris classification Is) polyp with Kudo pit pattern IIII.
 B. Magnified NBI pattern showing JNET classification 2A.
 C. Pathology photo with $\times 20$ magnification showing tubular adenoma.

Anatomical Features				Morphologic Classification		Surface Classification		Pathology
Location	Size	Circumference	Cross Two Folds	Paris Classification	LST	JNET Classification	Kudo Pit Pattern Classification	
Rectum	12mm	<1/3	Negative	Is	No	2A	IIII	Tubular Adenoma

Fig. 4. A sample of anatomical features, morphologic, surface classification and pathology described in the dataset

VI. VALUE OF THE DATA

- ERCMPMP is a comprehensive dataset with high quality images and videos of colorectal polyps.
- ERCMPMP dataset images and videos are labeled according to both morphological and histopathological features.
- ERCMPMP dataset can be utilized as a training dataset in the development of artificial intelligence algorithms.
- ERCMPMP dataset could be a valuable source for investigational and educational purposes of medical health professionals.

VII. DISCUSSION

Recently, significant efforts have been devoted to utilizing AI and its subsets such as machine learning and deep learning to predict and identify various types of neoplasms, with a particular focus on colorectal cancer. Obtaining a well-structured dataset plays a vital role in training machine learning algorithms and is among the initial steps in this matter. Histologic grading and morphological classifications are among the important factors for prognosis and determining the response to treatments like chemotherapy, radiotherapy, and surgery. Examining several notable studies conducted between 2010 and 2023 revealed the absence of a comprehensive histopathological and morphological image and video dataset specifically

for colorectal polyps [13-19]. This research gap prompted the development of the ERCPMP dataset. The current version of this dataset is available on Elsevier Mendeley dataset portal at <https://data.mendeley.com/datasets/7grhw5tv7n/2> and since it is under development, the latest version is available via: <https://data.biox.com>. The current version of ERCPMP comprises a collection of 796 RGB colonoscopy images in JPG format and 21 colonoscopy videos in MP4. These images and videos were captured from 191 patients diagnosed with colorectal polyps at the Gastroenterology and Hepatology Research Center of Shahid Beheshti University of Medical Sciences in Iran between 2014 and 2019. Each image in the dataset is annotated with its corresponding diagnosed grade, enabling the training of machine learning algorithms for polyp detection.

Table 1. Abbreviations and Definitions.

Abbreviation	Definition	Abbreviation	Definition
CRC	Colorectal Carcinoma	LST-G-H	Laterally Spreading Tumor, Granular-Homogenous
EMR	Endoscopic Mucosal Resection	LST-G-NM	Laterally Spreading Tumor, Granular-Nodular Mixed
ESD	Endoscopic Submucosal Dissection	LST-NG	Laterally Spreading Tumor, Non-Granular
FTRD	Full-Thickness Resection Device	LST-NG-FE	Laterally Spreading Tumor, Non-Granular-Flat Elevated
JNET	Japanese Narrow Band Imaging Expert Team	LST-NG-PD	Laterally Spreading Tumor, Non-Granular-Pseudo Depressed
LST	Laterally Spreading Tumor	NBI	Narrow-Band Imaging
LST-G	Laterally Spreading Tumor, Granular		

Table 2. ERCPMP dataset technical specifications.

	Value		Value
Number of Images	796	Number of Videos	21
Image Format	RGB	Video Frame Rate	30 fps
Image File Type	JPG	Video File Type	MP4
Image Resolution	96 dpi	Video Resolution	480 * 288
Size (Pixels)	368 * 256		

Table 4. Data quantity in the ERCPMP dataset for each characteristic.

		Numbers			Numbers			Numbers
Patients		191	Circumference	> 1/3	10	JNET	1	34
Gender	Male	71		<= 1/3	181		2A	87
	Female	120	Cross Two Folds	Positive	22		2B	20
Location	Ileocecal valve	2		Negative	169		3	7
	Cecum	4	Paris Class	0-Is	70	LST-Type	GMN	7
	Ascending	55		0-Ip	10		GHT	12
	Hepatic flexure	4		0-Ips	38		NGFT	7
	Transverse	15		0-IIa	30		NGPD	3
	Splenic Flexure	13		0-IIb	3	Diagnosis	Tubular	68
	Descending	23		0-IIc	0		Villous	6
				Mix	0			
	Sigmoid	39	Pit Pattern	I	32		Tubulovillous	31
	Rectosigmoid	7		II	2		Serrated	4
	Rectum	28		III	63		Hyperplastic	31
	Other	-		IV	5	Grading	Low	81
				V	3		Moderate	-
				Mix	41		High	23

VIII. DECLARATIONS

AVAILABILITY OF DATA AND MATERIALS

Available.

FUNDING

Not Applicable.

ACKNOWLEDGEMENTS

Not Applicable.

CONFLICT OF INTEREST

- All authors have participated in (a) conception and design, or analysis and interpretation of the data; (b) drafting the article or revising it critically for important intellectual content; and (c) approval of the final version.
- This manuscript has not been submitted to, nor is under review at, another journal or other publishing venue.
- The authors have no affiliation with any organization with a direct or indirect financial interest in the subject matter discussed in the manuscript
- The following authors have affiliations with organizations with direct or indirect financial interest in the subject matter discussed in the manuscript:

IX. REFERENCES

- [1] Sung H, Ferlay J, Siegel RL, Laversanne M, Soerjomataram I, Jemal A, et al. Global cancer statistics 2020: GLOBOCAN estimates of incidence and mortality worldwide for 36 cancers in 185 countries. *CA: a cancer journal for clinicians*. 2021;71(3):209-49.
- [2] Ladabaum U, Dornitz JA, Kahi C, Schoen RE. Strategies for colorectal cancer screening. *Gastroenterology*. 2020;158(2):418-32.
- [3] Petimar J, Smith-Warner SA, Rosner B, Chan AT, Giovannucci EL, Tabung FK. Adherence to the World Cancer Research Fund/American Institute for Cancer Research 2018 Recommendations for Cancer Prevention and Risk of Colorectal Cancer WCRF/AICR Recommendations and Colorectal Cancer Risk. *Cancer Epidemiology, Biomarkers & Prevention*. 2019;28(9):1469-79.
- [4] Sawicki T, Ruskowska M, Danielewicz A, Niedźwiedzka E, Arłukowicz T, Przybyłowicz KE. A review of colorectal cancer in terms of epidemiology, risk factors, development, symptoms and diagnosis. *Cancers*. 2021;13(9):2025.
- [5] Poudineh M, Poudineh S, Hosseini Z, Pouramini S, Fard SS, Fadavian H, et al. Risk Factors for the Development of Cancers. *Kindle*. 2023;3(1):1-118.
- [6] Cronin O, Sidhu M, Shahidi N, Gupta S, O'Sullivan T, Whitfield A, et al. Comparison of the morphology and histopathology of large nonpedunculated colorectal polyps in the rectum and colon: implications for endoscopic treatment. *Gastrointest Endosc*. 2022;96(1):118-24.
- [7] Ozgur I, Sapci I, Sengun B, Valente MA, Steele SR, Liska D, et al. Do surface morphology and pit pattern have a role in predicting cancer for colon polyps in North America? *Surg Endosc*. 2023;37(3):2354-8.

- [8] Safiyeva AK, Bayramov NY. The importance of colonoscopy in the treatment of colorectal polyps and colorectal cancer screening. *Ann Ital Chir.* 2019;90:311-7.
- [9] Shaukat A, Kaltenbach T, Dominitz JA, Robertson DJ, Anderson JC, Cruise M, et al. Endoscopic Recognition and Management Strategies for Malignant Colorectal Polyps: Recommendations of the US Multi-Society Task Force on Colorectal Cancer. *Gastrointest Endosc.* 2020;92(5):997-1015.e1.
- [10] Viscaino M, Bustos JT, Muñoz P, Cheein CA, Cheein FA. Artificial intelligence for the early detection of colorectal cancer: A comprehensive review of its advantages and misconceptions. *World Journal of Gastroenterology.* 2021;27(38):6399.
- [11] Wang P, Xiao X, Glissen Brown JR, Berzin TM, Tu M, Xiong F, et al. Development and validation of a deep-learning algorithm for the detection of polyps during colonoscopy. *Nature Biomedical Engineering.* 2018;2(10):741-8.
- [12] Hassan C, Wallace MB, Sharma P, Maselli R, Craviotto V, Spadaccini M, et al. New artificial intelligence system: first validation study versus experienced endoscopists for colorectal polyp detection. *Gut.* 2020;69(5):799-800.
- [13] Jha D, Smedsrud PH, Riegler MA, Halvorsen P, de Lange T, Johansen D, et al., editors. *Kvasir-SEG: A Segmented Polyp Dataset2020*; Cham: Springer International Publishing.
- [14] Bernal J, Sánchez FJ, Fernández-Esparrach G, Gil D, Rodríguez C, Vilariño F. WM-DOVA maps for accurate polyp highlighting in colonoscopy: Validation vs. saliency maps from physicians. *Computerized medical imaging and graphics.* 2015;43:99-111.
- [15] Tajbakhsh N, Gurudu SR, Liang J. Automated polyp detection in colonoscopy videos using shape and context information. *IEEE transactions on medical imaging.* 2015;35(2):630-44.
- [16] Picon A, Terradillos E, Sánchez-Peralta LF, Mattana S, Cicchi R, Blover BJ, et al. Novel Pixelwise Co-Registered Hematoxylin-Eosin and Multiphoton Microscopy Image Dataset for Human Colon Lesion Diagnosis. *J Pathol Inform.* 2022;13:100012.
- [17] Chattree A, Barbour JA, Thomas-Gibson S, Bhandari P, Saunders BP, Veitch AM, et al. Report of the Association of Coloproctology of Great Britain and Ireland/British Society of Gastroenterology Colorectal Polyp Working Group: the development of a complex colorectal polyp minimum dataset. *Colorectal Dis.* 2017;19(1):67-75.
- [18] Borgli H, Thambawita V, Smedsrud PH, Hicks S, Jha D, Eskeland SL, et al. HyperKvasir, a comprehensive multi-class image and video dataset for gastrointestinal endoscopy. *Scientific Data.* 2020;7(1):283.
- [19] Available from: <https://www.biobancovasco.org/en/Sample-and-data-e-catalog/Databases/PD178-PICCOLO-EN1.html>.
- [20] Kaltenbach T, Anderson JC, Burke CA, Dominitz JA, Gupta S, Lieberman D, et al. Endoscopic Removal of Colorectal Lesions: Recommendations by the US Multi-Society Task Force on Colorectal Cancer. *Am J Gastroenterol.* 2020;115(3):435-64.
- [21] Update on the paris classification of superficial neoplastic lesions in the digestive tract. *Endoscopy.* 2005;37(6):570-8.
- [22] Sano Y, Tanaka S, Kudo SE, Saito S, Matsuda T, Wada Y, et al. Narrow-band imaging (NBI) magnifying endoscopic classification of colorectal tumors proposed by the Japan NBI Expert Team. *Dig Endosc.* 2016;28(5):526-33.
- [23] Iwatate M, Sano Y, Tanaka S, Kudo SE, Saito S, Matsuda T, et al. Validation study for development of the Japan NBI Expert Team classification of colorectal lesions. *Dig Endosc.* 2018;30(5):642-51.
- [24] Pamudurthy V, Lodhia N, Konda VJA. Advances in endoscopy for colorectal polyp detection and classification. *Proc (Bayl Univ Med Cent).* 2020;33(1):28-35.
- [25] Banerjee AK, Longcroft-Wheaton G, Beable R, Conti J, Khan J, Bhandari P. The role of imaging and biopsy in the management and staging of large non-pedunculated rectal polyps. *Expert Rev Gastroenterol Hepatol.* 2018;12(8):749-55.

- [26] Lambert R, Tanaka S. Laterally spreading tumors in the colon and rectum. *Eur J Gastroenterol Hepatol.* 2012;24(10):1123-34.
- [27] Gibson JA, Odze RD. Pathology of premalignant colorectal neoplasia. *Dig Endosc.* 2016;28(3):312-23.
- [28] Miller Q, Saeed O, Mesa H. Clinical, Pathologic, and Molecular-Genetic Aspects of Colorectal Polyps. *Gastrointest Endosc Clin N Am.* 2022;32(2):313-28.
- [29] Tanaka S, Saitoh Y, Matsuda T, Igarashi M, Matsumoto T, Iwao Y, et al. Evidence-based clinical practice guidelines for management of colorectal polyps. *J Gastroenterol.* 2015;50(3):252-60.

Authors Biography

<p>Mojgan Forootan, MD</p> <p>Professor of Gastroenterology</p> <p>Shahid Beheshti University of Medical Sciences</p> <p>Gastroenterology and Liver Disease Research Center, Research Institute for Gastroenterology and Liver Diseases, Shahid Beheshti University of Medical Sciences, Tehran, Iran</p>	 A portrait of Mojgan Forootan, MD, a woman with dark hair wearing a black headscarf with a pink and white floral pattern. She is smiling and has her hand near her chin. The background shows some indoor plants and a lamp.
<p>Mohammad Reza Zali, MD</p> <p>Distinguished Professor of Gastroenterology</p> <p>Head of Gastroenterology and Liver Disease Research Center, Research Institute for Gastroenterology and Liver Diseases, Shahid Beheshti University of Medical Sciences, Tehran, Iran</p>	 A portrait of Mohammad Reza Zali, MD, an older man with grey hair and a beard, wearing a white lab coat over a light blue shirt. He is sitting at a desk with his hands clasped in front of him. The background is an office with blinds.
<p>Hamidreza Bolhasani, PhD</p> <p>AI/ML Researcher / Visiting Professor</p> <p>Founder and Chief Data Scientist at DataBiox</p> <p>Ph.D. Computer Engineering from Science and Research Branch, Islamic Azad University, Tehran, Iran. 2018-2023.</p> <p>Fields of Interest: Machine Learning, Deep Learning, Neural Networks, Computer Architecture, Bioinformatics</p>	 A portrait of Hamidreza Bolhasani, PhD, a young man with dark hair, wearing a light blue short-sleeved shirt and dark trousers. He is sitting in a red armchair, smiling, with his hands clasped. The background is a modern interior with green plants.

Mohsen Rajabnia, MD

Assistant Professor of Gastroenterology

Alborz University of Medical Sciences

Gastroenterology and Liver Disease Research Center,
Research Institute for Gastroenterology and Liver Diseases,
Shahid Beheshti University of Medical Sciences, Tehran, Iran



Ahmad R. Mafi, MD

Assistant Professor of Radiation Oncology

Shahid Beheshti University of Medical Sciences

Gastroenterology and Liver Disease Research Center,
Research Institute for Gastroenterology and Liver Diseases,
Shahid Beheshti University of Medical Sciences, Tehran, Iran



Hamed Azhdari Tehrani, MD

Hematologist – Medical Oncologist

Department of Hematology and Medical Oncology,

Shahid Beheshti University of Medical Sciences,

Tehran, Iran



Erfan Ghadirzadeh, MD

Mazandaran University of Medical Sciences

Gastroenterology and Liver Disease Research Center,
Research Institute for Gastroenterology and Liver Diseases,
Shahid Beheshti University of Medical Sciences, Tehran, Iran



Mahziar Setayeshfar, Medical Student

Iran University of Medical Sciences

Gastroenterology and Liver Disease Research Center,
Research Institute for Gastroenterology and Liver Diseases,
Shahid Beheshti University of Medical Sciences, Tehran, Iran



Zahra Ghaffari, Medical Student

Shahid Beheshti University of Medical Sciences

Gastroenterology and Liver Disease Research Center,
Research Institute for Gastroenterology and Liver Diseases,
Shahid Beheshti University of Medical Sciences, Tehran, Iran



Mohammad Tashakoripour

Researcher, Tehran University of Medical Sciences

Gastroenterology Department, Amiralam Hospital, Tehran
University of Medical Sciences, Tehran, Iran

Gastroenterology and Liver Disease Research Center,
Research Institute for Gastroenterology and Liver Diseases,
Shahid Beheshti University of Medical Sciences, Tehran, Iran

