

# OphGLM: Training an Ophthalmology Large Language-and-Vision Assistant based on Instructions and Dialogue

Weihao Gao<sup>1,\*</sup>, Zhuo Deng<sup>1,\*</sup>, Zhiyuan Niu<sup>1</sup>, Fujun Rong<sup>1</sup>, Chucheng Chen<sup>1</sup>, Zheng Gong<sup>1</sup>, Wenze Zhang<sup>1</sup>, Daimin Xiao<sup>1</sup>, Fang Li<sup>1</sup>, Zhenjie Cao<sup>1</sup>, Zhaoyi Ma<sup>2,†</sup>, Wenbin Wei<sup>3,†</sup>, Lan Ma<sup>1,†</sup>

<sup>1</sup>Shenzhen International Graduate School, Tsinghua University

<sup>2</sup>National Health Commission Capacity Building and Continuing Education Center

<sup>3</sup>Beijing Tongren Eye Center, Beijing Tongren Hospital

## Abstract

*Large multimodal language models (LMMs) have achieved significant success in general domains. However, due to the significant differences between medical images and text and general web content, the performance of LMMs in medical scenarios is limited. In ophthalmology, clinical diagnosis relies on multiple modalities of medical images, but unfortunately, multimodal ophthalmic large language models have not been explored to date. In this paper, we study and construct an ophthalmic large multimodal model. Firstly, we use fundus images as an entry point to build a disease assessment and diagnosis pipeline to achieve common ophthalmic disease diagnosis and lesion segmentation. Then, we establish a new ophthalmic multimodal instruction-following and dialogue fine-tuning dataset based on disease-related knowledge data and publicly available real-world medical dialogue. We introduce visual ability into the large language model to complete the ophthalmic large language and vision assistant (OphGLM). Our experimental results demonstrate that the OphGLM model performs exceptionally well, and it has the potential to revolutionize clinical applications in ophthalmology. The dataset, code, and models will be made publicly available at <https://github.com/ML-AILab/OphGLM>.*

## 1. Introduction

The web sources data like web images and their associated captions are abundantly available in recent years. This kind of parallel image-text data is of great potential to be applied in self-supervised vision-language modeling. As demonstrated by multimodal GPT-4 [15] and open-sourced efforts such as LLaVA [11], generative pretraining has effectively leveraged their performance. In attempting to improve the model’s knowledge of general facts based on

multimodal input, several large-scale multimodal models (LMMs) successfully show strong zero-shot task completion performance. The application of LLMs in various user-oriented visual-language tasks (such as image understanding and reasoning) has shown their great potential of developing universal multimodal conversation assistants.

Although LLMs have succeeded in the general domain, their performance is limited in biomedical scenarios. Since biomedical image-text pairs are quite different from general web content, the LLMs trained with web source data may have problems dealing with professional conversations. Therefore, a visual assistant in the general domain may behave like a non-specialist and be able to answer biomedical questions precisely or produce totally incorrect answers or false facts. Though much progress has been made in biomedical visual question answering (VQA), previous methods often formalize questions into classification (e.g., their answers are limited to ones observed in the training set) and are not suitable for open-ended guidance following. Meanwhile, current research is often based on single-modal text data rather than multimodal image-text data. Therefore, although conversational AI has demonstrated great potential in biomedical applications [6, 7, 14], more effort is required in this field.

Ophthalmology is a discipline that relies on multimodal diagnosis with various ophthalmology images, including fundus images, OCT, ultra-widefield fundus images, and fundus fluorescence angiography (FFA) images. However, currently, it lacks an available multimodal medical dialogue system constructed based on large-scale language models to assist the diagnosis progress. In this study, we attempt to construct a ophthalmology large language-and-vision assistant (OphGLM) with fundus images as the entry point. With this LLM, we can further explore the possibility of developing universal multimodal conversation assistants of good performance for biomedical and other scenarios.

Our contributions can be summarized as follows:

\* = equal contribution, † = corresponding author

- We use knowledge graphs and real-world medical dialogues to build an instructions and dialogue fine-tuning dataset for ophthalmic diseases using ChatGPT. This improves the authenticity and usability of LLM in medical question-answering in the healthcare field.
- Based on fundus images from public datasets, we construct a computer vision model for common disease diagnosis, which classifies diabetic retinopathy, age-related macular degeneration, pathological myopia, and glaucoma. In addition, we also develop a diabetic retinopathy grading model, a diabetic retinopathy lesion segmentation model, and an ophthalmic rare disease fundus diagnosis model, which serve as disease diagnosis models.
- We propose a novel ophthalmology large language-and-vision assistant (OphGLM). To the best of our knowledge, it is the first attempt to combine visual models with large language models in ophthalmology. The experimental results demonstrate our OphGLM has the great potential in ophthalmology clinical applications.

## 2. Related Work

### 2.1. Biomedical Chatbots

Large Language Models (LLMs) have achieved immense success in the general domain, with ChatGPT [15] being one of the most representative instances. Moreover, certain advancements have been made in research concerning the open-source fine-tuning of these large language models. Inspired by these successful cases in LLMs, a series of biomedical large language models have been successively introduced, including ChatDoctor [24], Med-Alpaca [4], PMC-LLaMA [22], DoctorGLM [23], and Huatuo [21]. Typically, these models start with pre-trained open-source LLMs and are then fine-tuned on domain-specific biomedical instruction-following datasets. The fine-tuned LLMs exhibit considerable application potential within specific biomedical fields, as they are able to perform a variety of tasks including patient dialogue, provision of diagnostic and treatment recommendations, and explanation of medical knowledge.

HuatuoGPT is a biomedical chatbot, incorporating distilled data generated by ChatGPT along with real-world physician response data. Its consistency and reliability have been validated both in automatic and human evaluations. However, HuatuoGPT only accepts text inputs, significantly limiting its application scenarios. Currently, multimodal biomedical chatbots capable of accepting image inputs are scarce, with Visual Med-Alpaca [17] and LLaVA-Med [8] being the only two known. Visual Med-Alpaca can accept image inputs and generate text dialogue out-

puts. Specifically, Visual Med-Alpaca processes input images through various image recognition models, combining the obtained visual information with textual prompts, enabling the model to generate appropriate responses. However, Visual Med-Alpaca’s training on a limited biomedical dataset presents certain restrictions. Recently, Microsoft introduced LLaVA-Med, an end-to-end neural network model that processes images directly without the need for separate medical visual models. Furthermore, LLaVA-Med conducts experiments on a more diverse and larger dataset, demonstrating superior generalization and effectiveness.

### 2.2. Biomedical Visual Question Answering

The development of large models capable of autonomously generating answers to questions based on biomedical image inputs would greatly benefit physicians and patients alike, bearing significant implications for the enhancement of clinical diagnostic and treatment efficiency. Existing approaches to biomedical visual question answering principally fall into two categories: discriminative and generative methods. For discriminative methods, Visual Question Answering (VQA) is treated as a classification problem where the model seeks an answer from a predefined answer set [3, 5, 9, 26]. Although this method can yield satisfactory performance, it operates within the constraints of a finite predefined answer dataset, thus requires adjustments or retraining when presented with a new or custom set of answers. Consequently, discriminative methods are not suited to the development of a biomedical chatbot capable of addressing open-ended queries. To counter this limitation, researchers have pioneered generative methods that predict answers in the form of unrestricted text sequences [1, 12, 19]. Generative methods not only accommodate custom answer sets, but also offer increased flexibility and yield more accurate responses. A novel data generation method was proposed in [8], where GPT-4 was employed to generate multimodal instruction-following data pairs using medical image-text pairs from the publicly available dataset in PubMed Central [26].

### 2.3. Model Architecture

There are mainly two methods for fine-tuning Large Language Models (LLMs) through biomedical visual question-answering dialogues. One approach involves individually fine-tuning the LLM on a medical dialogue dataset. The other method is the prefix tuning of language models (LMs), where a new trainable module connects the frozen image encoder and the causal LM, allowing for standard supervised fine-tuning of the entire model [8, 19]. In [19], a three-layer MLP network is employed to map visual features to the visual prefix. Furthermore, [19] incorporates a variety of pretrained LMs including GPT2-XL [16], BioMedLM [20], and BioGPT [13], with sizes ranging from 1.5B to

2.7B. Conversely, [8] employs linear projection alongside a 7B LM [18]. In our model, ChatGLM [25] was used as the LLM and was fine-tuned on an ophthalmology dialogue dataset. ChatGLM is an open-source dialogue language model that supports both English and Chinese conversations, boasting 6.2 billion parameters.

### 3. Ophthalmology Dataset

Based on fundus medical imaging, the diagnosis of diseases can be obtained. In this study, we are currently able to provide diagnostic results for diabetic retinopathy, age-related macular degeneration, pathological myopia, glaucoma, and intraocular tumors, as well as lesion segmentation and staging for diabetic retinopathy. In order to maximize LLM’s question-answering performance in specific diseases, we have devised two strategies to improve its performance.

#### 3.1. Instruction Data Construction

Based on the open database crawler technology, we have constructed a large-scale medical knowledge graph with more than 100,000 nodes from Wikipedia, Dingxiangyuan and other sources. At the downstream of the Knowledge graph, we build the api parameters based on medical scenarios. Specifically, we construct instruction fine-tuning datasets based on five different scenarios, as is shown in Fig.1. The knowledge based prompt example to create instructions is shown in appendix Fig.4.

**Medical Imaging Description:** About the basic description of disease classification, grading, and lesion based on medical imaging.

**Causes and symptoms:** Information about the symptoms of a disease.

**Diagnosis and examination:** How to diagnose and examine a particular disease, including common examination and testing methods.

**Treatment and prevention:** How to treat and prevent a particular disease, including medication, surgical treatment, rehabilitation, and other aspects of treatment.

**Prognosis and lifestyle:** The prognosis of a disease and how to alleviate symptoms or prevent a disease by changing lifestyle.

#### 3.2. Medical Conversation Construction

Instructions based on disease diagnosis and knowledge graph construction can be built around various scenarios of specific diseases using ChatGPT, leveraging additional knowledge to enable smaller LLMs to provide more realistic and robust medical Q&A. However, the actual situation may be more complex.

The construction of knowledge instructions based on knowledge graphs cannot reflect the true concerns of patients. For example, patients generally have concerns about

the heritability of the disease, medical costs, and efficacy. Instruction based fine-tuning can improve the authenticity of specific problems, but it cannot provide a better interactive experience.

In order to provide a dataset that is closer to real Q&A scenarios and to create a better interactive experience, we proposed a dialogue prompt strategy based on real doctor-patient conversations. First, we extracted real conversations about ophthalmic diseases from the MedDialog dataset [2], which contains genuine doctor-patient dialogues, as material. Then, we designed a set of prompts to enable ChatGPT to play the role of a medical expert, extracting patients’ intentions from publicly available real doctor-patient dialogues and providing as professional and detailed medical explanations as possible. This approach not only enables the extraction of patients’ intentions from real conversations, but also creates a more suitable dialogue dataset for patients.

Our process for building the fine-tuned fundus dialog dataset is illustrated in Fig.2. In step 1, prompts are created using both real-world medical-patient conversations and knowledge graphs. In step 2, medical knowledge based instructions and conversation are created using the ChatGPT interface. In step 3, data cleaning is performed to create instances. In step 4, duplicate data is removed by validating against existing datasets. In step 5, instance quality is evaluated using both manual review and GPT4. Finally, new instruction and conversation are added to fundus dialog pool. The construction of such a fine-tuned dataset not only enhances the authenticity and accuracy of LLM in medical knowledge but also creates a more friendly doctor-patient dialogue mechanism. The conversation based prompt example to create patient friendly conversation is shown in appendix Fig.5.

Using these two strategies, we have constructed a Fundus Dialog Dataset consisting of over 20k instances related to ophthalmic diseases. Our experiments have shown that fine-tuning this dataset with ChatGLM can effectively improve the authenticity of disease-related Q&A downstream from fundus medical imaging diagnosis. The fine-tuned OphGLM model possesses medical knowledge richness close to that of ChatGPT and can provide a more patient-friendly experience. Although the relevant data volume is not large, significant improvement has been achieved in LLM’s factual answering ability.

## 4. Methodology

### 4.1. Overview

Our model, OphGLM, is a multimodal biomedical chatbot capable of accepting fundus images as input. OphGLM consists of two modules: the fundus diagnosis pipeline and the OphGLM pipeline. The overall pipeline of our proposed

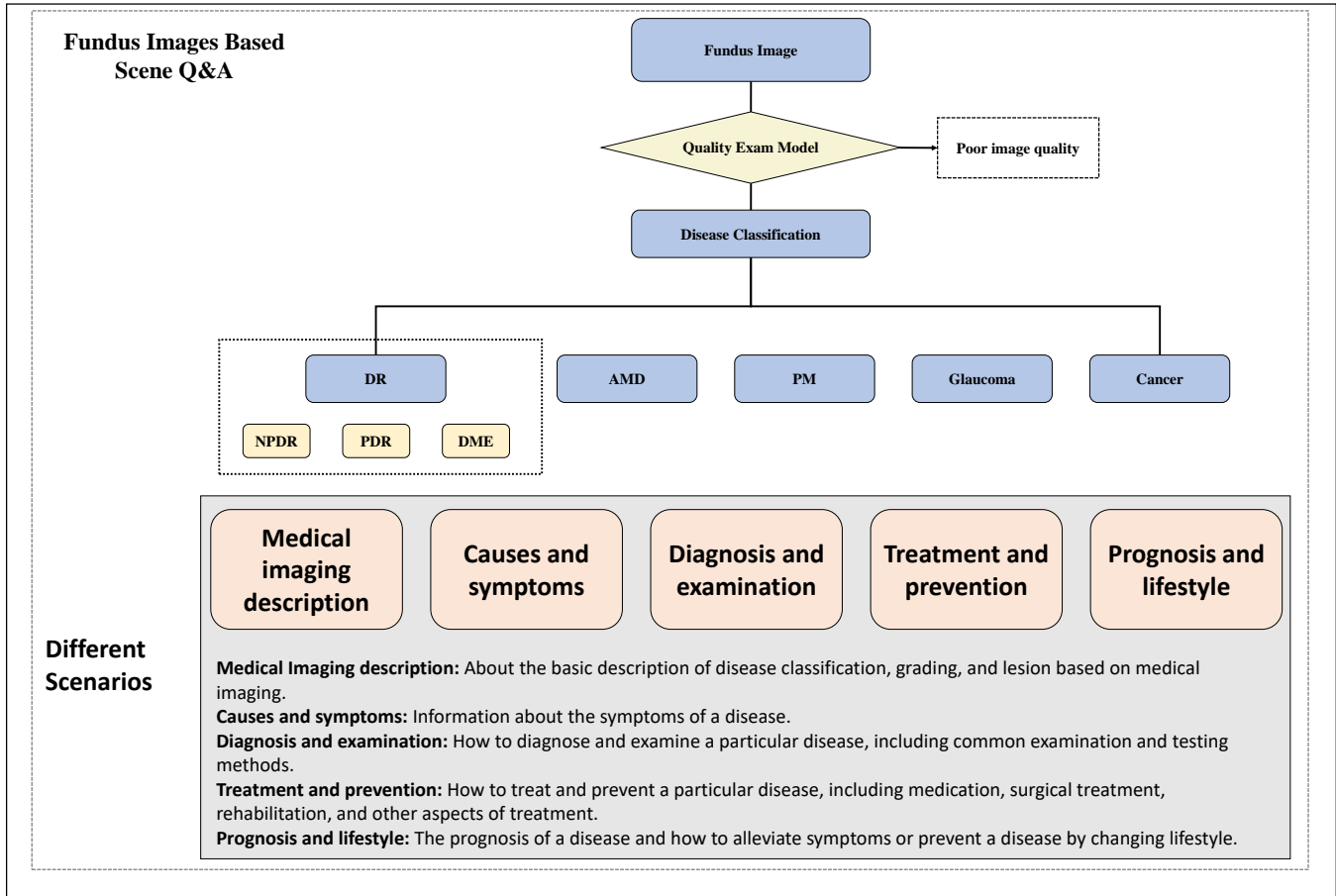


Figure 1. Instruction fine-tuning datasets based on five different scenarios.

method is illustrated in Fig.3. Within the fundus diagnosis pipeline, there are two primary components: the fundus image classification segment and the fundus image segmentation segment. These segments work together to extract information from the input fundus images. The extracted visual information is integrated into structured text templates, forming diagnostic reports based on the input fundus images. As for the OphGLM pipeline, it merges the fundus image diagnostic report with the fundus dialogue through a process of text concatenation. This forms a prompt that is then input into the OphGLM, ultimately generating a high-quality response.

#### 4.2. Fundus Diagnosis Pipeline

In the fundus diagnosis pipeline of our model, the input fundus images are processed via a disease diagnosis module and a lesion segmentation module. Within the fundus image disease diagnosis module, we employ five different disease classification models, including a grading model for diabetic retinopathy (DR), an age-related macular degeneration (AMD) classification model, a glaucoma classification

model, a pathological myopia classification model, and a fundus tumor classification model. The specific functionalities of each disease classification model are as follows: The DR grading model can classify fundus images into normal, mild, non-proliferative, moderate non-proliferative, severe non-proliferative, and proliferative DR. The AMD classification model can classify fundus images into normal and AMD categories. The glaucoma classification model can classify fundus images into normal and glaucoma categories. The pathological myopia classification model can classify fundus images into normal and pathological myopia categories. The fundus tumor classification model can classify fundus images into normal and fundus tumor categories. In the fundus image lesion segmentation module, we implemented segmentation of common fundus lesions, including hard exudates (EX), soft exudates (SE), microaneurysms (MA), and hemorrhages (HE). Our visual models, based on Convolutional Neural Networks (CNN) and transformer architectures, simultaneously boast high accuracy and inference speeds. Once we have obtained the structured classification and segmentation results from these models,

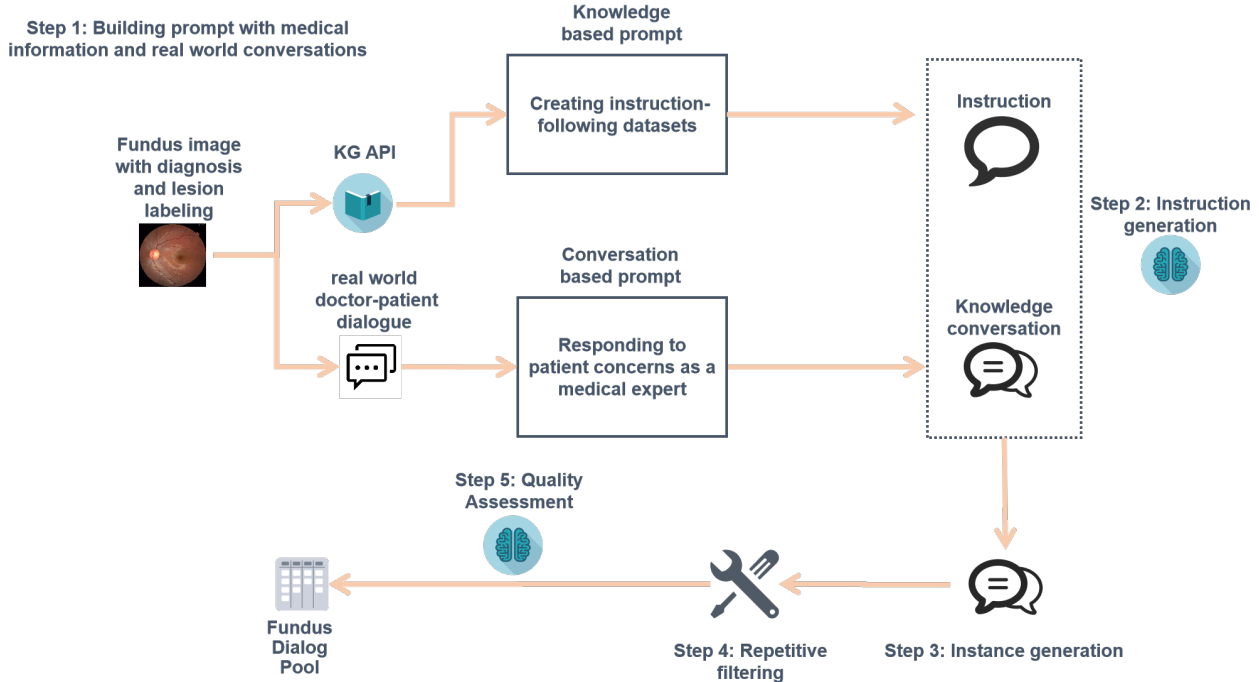


Figure 2. The process of building the fine-tuned Fundus dialog dataset.

they are integrated into our predetermined text template, thus forming the diagnostic report for the fundus images.

### 4.3. OphGLM Pipeline

During the training process of OphGLM, we fine-tuned the base model, ChatGLM [25], using a dataset consisting of over 20k fundus dialogues related to retinal diseases. As a result, we obtained OphGLM, which demonstrated a stronger capability in both disease diagnosis and question-answering. Within the OphGLM pipeline, the fundus image diagnostic report and the user’s input of fundus dialogue undergo text concatenation. By employing our strategically designed method, a dialogue prompt is generated and fed into OphGLM, which ultimately yields a high-quality response.

## 5. Experiments

### 5.1. Implement Details

We provide a detailed overview of the training details for the fundus diagnosis pipeline. Our fundus diagnosis pipeline includes diabetic retinopathy classification, glaucoma classification, pathological myopia classification, age-related macular degeneration classification, fundus tumor detection, and diabetic retinopathy lesion segmentation. The segmentation model for diabetic retinopathy lesions enables the segmentation of four types of lesions: hard exudates, soft exudates, microaneurysms, and hemorrhages.

During the model training process, we utilized both publicly available datasets and private datasets to train and fine-tune the fundus diagnosis models. Specifically, the training dataset for the diabetic retinopathy lesion classification model is sourced from the Diabetic Retinopathy Detection dataset and DDR dataset [10]. The training dataset for glaucoma classification model is obtained from REFUGE and ORIGA650. The training dataset for pathological myopia classification model is from BAIDU\_PALM. The training dataset for age-related macular degeneration classification model is IChallenge\_AMD400. The training dataset for fundus tumor classification is from a private dataset of Beijing Tongren Hospital. The diabetic retinopathy lesion segmentation dataset is sourced from DDR, IDRID, and ADAM. The detailed information of the datasets is provided in Table 1. In this experiment, the evaluation metric for classification tasks is accuracy(ACC), and for segmentation tasks, it is dice coefficient(DSC).The equations of ACC and DSC are as follows:

$$ACC = \frac{TP + TN}{TP + TN + FP + FN} \quad (1)$$

$$DSC = \frac{2 \times |X \cap Y|}{|X| + |Y|} \quad (2)$$

For ACC equation, TP(True Positive) is the number of positive samples correctly classified as positive, TN(True Negative) is the number of negative samples correctly classified as negative, FP(False Positive) is the number of nega-



Table 1. The datasets, number of images, and evaluation metrics used for the tasks in fundus image diagnosis model

Task	Dataset	Number of images	Evaluation Index
DR classification	DRD(Kaggle)	88702	Acc
	DDR	13673	Acc
glaucoma classification	REFUGE	1200	Acc
	ORIGA650	650	Acc
PALM classification	BAIDU_PALM	800	Acc
AMD classification	ICchallenge_AMD400	400	Acc
tumor classification	Private Dataset	—	Acc
lesion segmentation	DDR	757	Dice
	IDRID	81	Dice
	ADAM	400	Dice

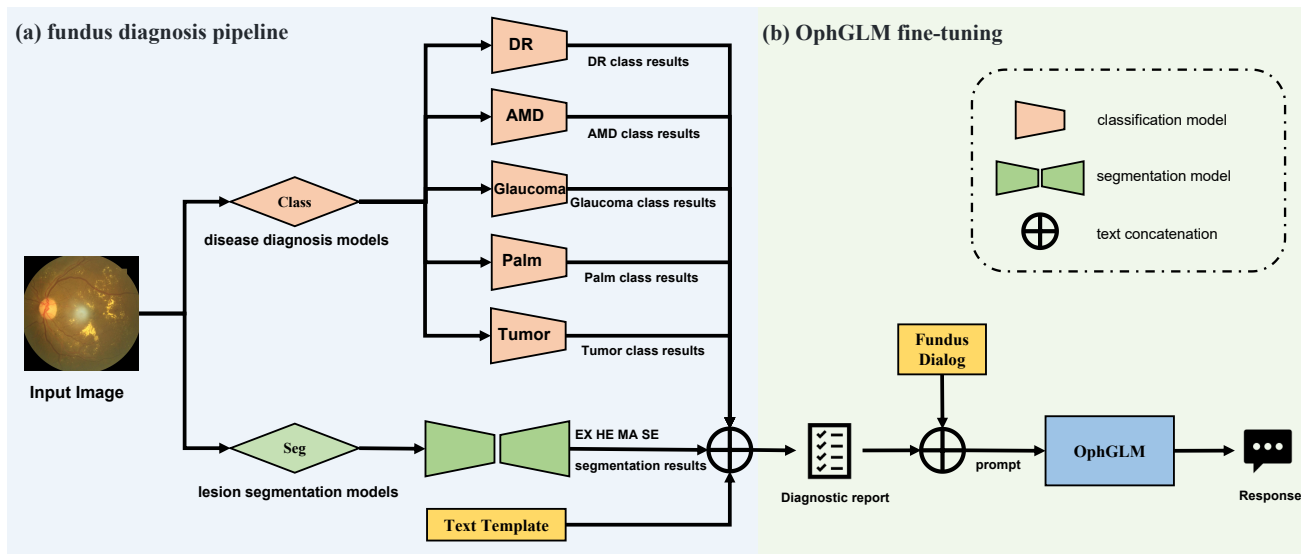


Figure 3. Overall architecture of the proposed OphGLM. (a) Fundus diagnosis pipeline. (b) OphGLM fine-tuning pipeline.

tive samples incorrectly classified as positive, and FN(False Negative) is the number of positive samples incorrectly classified as negative. For DSC equation,  $|X \cap Y|$  represents the size of the intersection between the prediction results (typically the segmented image) and the actual results (typically the manually annotated image).  $|X|$  and  $|Y|$  represent the sizes of the prediction and actual results, respectively.

## 5.2. Performance

The performance of each model in our fundus diagnosis pipeline is shown in Table 2. The visual input example of a DR fundus image is shown in appendix Fig.6 and some medical knowledge based Q&A examples are shown in appendix Table 3 and Table 4.

## 6. Conclusions

We have developed OphGLM, a large-scale language and vision assistant for ophthalmology based on instructions and dialogue. Our model was fine-tuned on a dataset

Table 2. The performance of models in fundus diagnosis pipeline.

Algorithm Type	Algorithm	Acc	Dice
classification	DR_class_model	0.970	—
	Glaucoma_class_model	0.940	—
	PALM_calss_model	0.998	—
	AMD_class_model	0.984	—
	Tumor_class_model	0.999	—
segmentation	EX_seg_model	—	0.854
	HE_seg_model	—	0.805
	MA_seg_model	—	0.699
	SE_seg_model	—	0.812

of over 20k instructional fine-tuning and dialogue dataset, carefully crafted based on real-world conversations and medical knowledge. This process provided OphGLM with powerful question answering abilities tailored specifically for ophthalmology.

Despite significant progress in ophthalmic visual dialogue, there is still room for improvement in our model. We will continue to conduct research and generate more high-quality image-language data to enhance the overall capabilities of the model. In addition, we plan to enrich and strengthen the upstream diagnostic models, providing multi-label disease classification and lesion annotation capabilities. Finally, we plan to incorporate other medical imaging modalities in ophthalmology, such as OCT, into the model to create a comprehensive medical-assistant system.

## References

- [1] Yakoub Bazi, Mohamad Mahmoud Al Rahhal, Laila Bashmal, and Mansour Zuair. Vision-language model for visual question answering in medical imagery. *Bioengineering*, 10(3):380, 2023. 2
- [2] Shu Chen, Zeqian Ju, Xiangyu Dong, Hongchao Fang, Sicheng Wang, Yue Yang, Jiaqi Zeng, Ruisi Zhang, Ruoyu Zhang, Meng Zhou, Penghui Zhu, and Pengtao Xie. Meddialog: a large-scale medical dialogue dataset. *arXiv preprint arXiv:2004.03329*, 2020. 3
- [3] Sedigheh Eslami, Christoph Meinel, and Gerard De Melo. Pubmedclip: How much does clip benefit visual question answering in the medical domain? In *Findings of the Association for Computational Linguistics: EACL 2023*, pages 1151–1163, 2023. 2
- [4] Tianyu Han, Lisa C Adams, Jens-Michalis Papaioannou, Paul Grundmann, Tom Oberhauser, Alexander Löser, Daniel Truhn, and Keno K Bressen. Medalpaca—an open-source collection of medical conversational ai models and training data. *arXiv preprint arXiv:2304.08247*, 2023. 2
- [5] Xuehai He, Yichen Zhang, Luntian Mou, Eric Xing, and Pengtao Xie. Pathvqa: 30000+ questions for medical visual question answering. *arXiv preprint arXiv:2003.10286*, 2020. 2
- [6] Peter Lee, Sebastien Bubeck, and Joseph Petro. Benefits, limits, and risks of gpt-4 as an ai chatbot for medicine. *New England Journal of Medicine*, 388(13):1233–1239, 2023. PMID: 36988602. 1
- [7] Peter Lee, Carey Goldberg, and Isaac Kohane. *The ai revolution in medicine: Gpt-4 and beyond*, volume 2. The name of the publisher, 2023. 1
- [8] Chunyuan Li, Cliff Wong, Sheng Zhang, Naoto Usuyama, Haotian Liu, Jianwei Yang, Tristan Naumann, Hoifung Poon, and Jianfeng Gao. Llava-med: Training a large language-and-vision assistant for biomedicine in one day. *arXiv preprint arXiv:2306.00890*, 2023. 2, 3
- [9] Pengfei Li, Gang Liu, Lin Tan, Jinying Liao, and Shenjun Zhong. Self-supervised vision-language pretraining for medical visual question answering. *arXiv preprint arXiv:2211.13594*, 2022. 2
- [10] Tao Li, Yingqi Gao, Kai Wang, Song Guo, Hanruo Liu, and Hong Kang. Diagnostic assessment of deep learning algorithms for diabetic retinopathy screening. *Information Sciences*, 501:511–522, 2019. 5
- [11] Haotian Liu, Chunyuan Li, Qingyang Wu, and Yong Jae Lee. Visual instruction tuning, 2023. 1
- [12] Yunyi Liu, Zhanyu Wang, Dong Xu, and Luping Zhou. Q2atransformer: Improving medical vqa via an answer querying decoder. In *International Conference on Information Processing in Medical Imaging*, pages 445–456. Springer, 2023. 2
- [13] Renqian Luo, Liai Sun, Yingce Xia, Tao Qin, Sheng Zhang, Hoifung Poon, and Tie-Yan Liu. Biogpt: generative pre-trained transformer for biomedical text generation and mining. *Briefings in Bioinformatics*, 23(6), 2022. 2
- [14] Harsha Nori, Nicholas King, Scott Mayer McKinney, Dean Carignan, and Eric Horvitz. Capabilities of gpt-4 on medical challenge problems, 2023. 1
- [15] OpenAI. Gpt-4 technical report, 2023. 1, 2
- [16] Alec Radford, Jeffrey Wu, Rewon Child, David Luan, Dario Amodei, Ilya Sutskever, et al. Language models are unsupervised multitask learners. *OpenAI blog*, 1(8):9, 2019. 2
- [17] Chang Shu, Baian Chen, Fangyu Liu, Zihao Fu, Ehsan Shareghi, and Nigel Collier. Visual med-alpaca: A parameter-efficient biomedical llm with visual capabilities, 2023. 2
- [18] Hugo Touvron, Thibaut Lavril, Gautier Izacard, Xavier Martinet, Marie-Anne Lachaux, Timothée Lacroix, Baptiste Rozière, Naman Goyal, Eric Hambro, Faisal Azhar, et al. Llama: Open and efficient foundation language models. *arXiv preprint arXiv:2302.13971*, 2023. 3
- [19] Tom van Sonsbeek, Mohammad Mahdi Derakhshani, Ivona Najdenkoska, Cees GM Snoek, and Marcel Worring. Open-ended medical visual question answering through prefix tuning of language models. *arXiv preprint arXiv:2303.05977*, 2023. 2
- [20] A Venigalla, J Frankle, and M Carbin. Biomedllm: a domain-specific large language model for biomedical text. *MosaicML. Accessed: Dec, 23:3*, 2022. 2
- [21] Haochun Wang, Chi Liu, Nuwa Xi, Zewen Qiang, Sendong Zhao, Bing Qin, and Ting Liu. Huatuo: Tuning llama model with chinese medical knowledge. *arXiv preprint arXiv:2304.06975*, 2023. 2
- [22] Chaoyi Wu, Xiaoman Zhang, Ya Zhang, Yanfeng Wang, and Weidi Xie. Pmc-llama: Further finetuning llama on medical papers. *arXiv preprint arXiv:2304.14454*, 2023. 2
- [23] Honglin Xiong, Sheng Wang, Yitao Zhu, Zihao Zhao, Yuxiao Liu, Qian Wang, and Dinggang Shen. Doctorglm: Fine-tuning your chinese doctor is not a herculean task. *arXiv preprint arXiv:2304.01097*, 2023. 2
- [24] Li Yunxiang, Li Zihan, Zhang Kai, Dan Ruilong, and Zhang You. Chatdoctor: A medical chat model fine-tuned on llama model using medical domain knowledge. *arXiv preprint arXiv:2303.14070*, 2023. 2
- [25] Aohan Zeng, Xiao Liu, Zhengxiao Du, Zihan Wang, Hanyu Lai, Ming Ding, Zhuoyi Yang, Yifan Xu, Wendi Zheng, Xiao Xia, et al. Glm-130b: An open bilingual pre-trained model. *arXiv preprint arXiv:2210.02414*, 2022. 3, 5
- [26] Sheng Zhang, Yanbo Xu, Naoto Usuyama, Jaspreet Bagga, Robert Tinn, Sam Preston, Rajesh Rao, Mu Wei, Naveen

Valluri, Cliff Wong, et al. Large-scale domain-specific pre-training for biomedical vision-language processing. *arXiv preprint arXiv:2303.00915*, 2023. [2](#)

## **7. Appendix**



### **Knowledge Based Prompt:**

You are an ophthalmologist who hopes to provide high-quality medical guidance to patients as much as possible and provide feedback on their concerns.

You are asked to come up with a set of 5 diverse task instructions.

You will receive a fundus image diagnosed as <Specific disease & lesions description>

Additional knowledge can be used to such as: <Knowledge graph additional information>

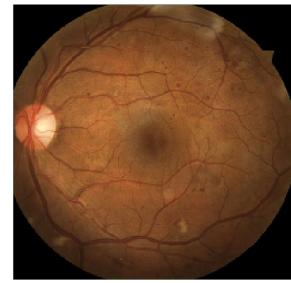Unfortunately, you are unable to access the actual fundus image.

These task will be related to medical dialogue under <Specific scenario> scenario.

Here are the requirements:

1. Try not to repeat the verb for each instruction to maximize diversity.
2. The language used for the instruction also should be diverse. For example, you should combine questions with imperative instructions.
3. The type of instructions should be diverse. The list should include diverse types of tasks like open-ended generation, classification, editing, etc.
2. A GPT language model should be able to complete the instruction. For example, do not ask the assistant to create any visual or audio output. For another example, do not ask the assistant to wake you up at 5pm or set a reminder because it cannot perform any action.
3. The instructions should be in English.
4. The instructions should be 1 to 2 sentences long. Either an imperative sentence or a question is permitted.
5. You should generate an appropriate input to the instruction. The input field should contain a specific example provided for the instruction. It should involve realistic data and should not contain simple placeholders. The input should provide substantial content to make the instruction challenging but should ideally not exceed 100 words.
6. Not all instructions require input. For example, when a instruction asks about some general information, "what is the highest peak in the world", it is not necessary to provide a specific context. In this case, we simply put "<noinput>" in the input field.
7. The output should be an appropriate response to the instruction and the input. Make sure the output is less than 100 words.
8. Do not provide any URL links, including internet image links, in the instruction.

Here is one example:



<Specific disease & lesions description>  
Diabetic retinopathy phase II, Multiple bleeding points, hard exudation, and soft exudation were found.

<Knowledge graph additional information>  
Laser photocoagulation, Anti-VEGF therapy, Intravitreal injections, Panretinal photocoagulation

<Specific scenario>  
Treatment and prevention

Figure 4. Knowledge Based Prompt.

### **Conversation based prompt:**

You are an ophthalmologist who hopes to provide high-quality medical guidance to patients as much as possible and provide feedback on their concerns.

Use the following doctor-patient dialogues as materials, create one sets conversations, initiated by the patient. Provide as deep a medical explanation as possible:

<Real-world doctor-patient conversation>

Here are the requirements:

1. All names for doctors are uniformly referred to as doctors.
2. All hospital names and personnel names should be replaced with XXXX, without the presence of doctor names or hospital names.
3. The patient first describes their past medical history and their own needs. Leave a blank line in each role-changing situation.

.....

<Real-world doctor-patient conversation>

病人: 您好; 我是一个一型糖尿病患者, 患病18年, 现在右眼视力模糊, 在已XXXX做玻切手术, 未取硅油, 医生说需补激光。左眼视力0.1, 一月前做激光五次, 现在医生建议打黄斑。请问, 先取硅油好呢还是先补激光好, 心里没底。左眼打黄斑后的效果如何, 主要是不知道打黄斑的目的。谢谢! 切盼谢谢!

医生: 是指黄斑部视网膜格栅样光凝, 医生建议黄斑打激光就是因为有黄斑水肿, 格栅样光凝是治疗糖尿病黄斑水肿的方法之一。可尝试, 如果效果不理想的话, 还可以眼内用抗-VEGF药物或眼科注射长效激素。

病人: 谢谢你! 如果打了黄斑效果如何, 视力会不会恢复, 如果不恢复, 会不会发展 谢谢!

医生: 基线是保住现有的视力, 或稍微牺牲一点视力, 也有很多人激光后视力提高。否则, 现在的视力是临时的, 还会继续下降。

**Translation**

**Patient:** Hello, I am a type 1 diabetes patient, I have been suffering from the disease for 18 years. Currently, my right eye has blurry vision, and I have had vitrectomy surgery but the silicone oil was not removed. The doctor said that I need laser treatment. My left eye has a visual acuity of 0.1, and I had five laser treatments a month ago. Now the doctor suggests injecting the macula with yellow dye. I am not sure whether to remove the silicone oil first or receive laser treatment first. I am also not sure about the purpose of injecting the macula. Thank you very much!

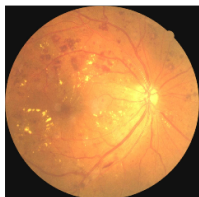**Doctor:** The purpose of injecting the macula is to treat diabetic macular edema by performing a grid-like photocoagulation of the macular retina. The reason why the doctor suggests laser treatment for the macula is because there is macular edema. If the effect is not ideal, you can also try using anti-VEGF drugs or long-acting steroids for intraocular injection.

**Patient:** Thank you! If the macula is injected, will my vision recover? If not, will it worsen? Thank you!

**Doctor:** The baseline is to maintain the current vision or sacrifice a little bit of vision. Many people's vision can improve after laser treatment. Otherwise, the current vision is temporary and will continue to decline.

Figure 5. Conversation Based Prompt.

### Visual input examples:

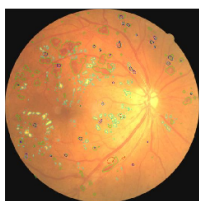


User: 请问患者眼底图像有什么诊断结果和病灶

OphGLM: 基于患者的眼底图像诊断为糖尿病视网膜病变3期, 基本排除眼部肿瘤和病理性近视。眼底图像上出现硬性渗出, 出血, 微血管瘤, 软性渗出。

User: 请将这张眼底图像进行糖尿病视网膜病变病灶分割。

OphGLM:



User: 患者的情况严重么?

OphGLM: 糖尿病视网膜病变第3期可以导致视力受损。因此, 糖尿病视网膜病变3期需要引起足够重视, 及时治疗以避免视力受损的风险。

User: 我应当如何预防糖网进一步进展?

OphGLM: 您可以在日常生活中采取以下措施来预防糖网: 1. 进行规律的眼部检查: 如果您患有糖尿病, 请按照医生的要求进行定期的眼部检查, 以便及早发现和治疗糖网。2. 控制血糖水平: 保持稳定的血糖水平可以减少糖尿病并发症的风险, 包括糖网。请遵循医生的治疗方案, 如规律用药、适当的运动和饮食等来控制血糖。3. 控制高血压和高胆固醇: 高血压和高胆固醇也会加速糖网的发展, 因此请遵循医生的建议, 积极控制这些病情。4. 戒烟和限制饮酒: 吸烟和饮酒都可能加重糖尿病并发症的风险, 包括糖网。戒烟和限制饮酒可以帮助降低这些风险。

### Translation:

User: <Fundus Image Input> What are the diagnostic results and lesions of the patient's fundus image?

OphGLM: Based on the patient's fundus image, the diagnosis is diabetic retinopathy at stage 3, with the possibility of excluding ocular tumors and pathologic myopia. Hard exudates, hemorrhage, microaneurysms, and soft exudates were found on the fundus image.

User: Please segment the diabetic retinopathy lesion on this fundus image.

OphGLM: <Lesion Segmentation Output>

User: Is the patient's condition severe?

OphGLM: Diabetic retinopathy at stage 3 can cause vision loss. Therefore, diabetic retinopathy at stage 3 should be taken seriously and treated promptly to avoid the risk of vision loss.

User: How can I prevent further progression of diabetic retinopathy?

OphGLM: You can take the following measures in daily life to prevent diabetic retinopathy: 1. Regular eye examinations: If you have diabetes, please follow the doctor's instructions for regular eye examinations to detect and treat diabetic retinopathy early. 2. Control blood sugar levels: Maintaining stable blood sugar levels can reduce the risk of diabetes complications, including diabetic retinopathy. Please follow the doctor's treatment plan, such as regular medication, appropriate exercise, and healthy diet to control blood sugar. 3. Control hypertension and hyperlipidemia: Hypertension and hyperlipidemia can also accelerate the development of diabetic retinopathy. Therefore, please follow the doctor's advice and actively control these conditions. 4. Quit smoking and limit alcohol consumption: Smoking and alcohol consumption may increase the risk of diabetes complications, including diabetic retinopathy. Quitting smoking and limiting alcohol consumption can help reduce these risks.

Figure 6. Visual Input Example.

Table 3. Improving the ability to answer medical basic questions

	example 1	example 2	example 3
Related Disease	AMD	AMD	DR
Question	What kind of disease is AMD?	Is age-related macular degeneration a common disease? What is the incidence rate among people over 50 years old?	What are the lesions in the fundus of diabetic retinopathy?
ChatGLM	AMD is a variant of AMD, also known as Houssay-Holopigian syndrome.	The prevalence of age-related macular degeneration in people over the age of 50 is approximately 10% according to data from the American Heart Association.	The following retinal lesions may appear in the fundus images of diabetic retinopathy: retinal neovascularization, retinal detachment, retinal nerve fiber degeneration, and retinal nerve fiber inflammation.
OphGLM	AMD(Age-related Macular Degeneration) is a type of retinal disease which mainly manifests as lesions in the macular region of the retina. It is a chronic and progressive disease that usually occurs with increasing age, and is more common in people over 60 years old.	Age-related Macular Degeneration (AMD) is a common macular disease that typically affects people over the age of 50. According to the World Health Organization, the global prevalence of AMD significantly increases with age, particularly in Asia and South America. According to the International Age-Related Macular Degeneration Foundation's data in 2019, the global prevalence of AMD is around 20.6%, with a rate of about 30% for those aged over 50. However, the prevalence may vary in different countries and regions depending on factors such as population structure, lifestyle habits, and medical conditions. AMD is a common macular disease that can lead to vision loss and visual impairment. To prevent AMD, people over the age of 50 are advised to take active measures such as regular physical examinations, maintaining a healthy lifestyle, and protecting their eyes.	Diabetic retinopathy is a disease caused by damage to the retinal blood vessels due to diabetes, and is common in people with diabetes. Diabetic retinopathy mainly includes the following lesions: <ol style="list-style-type: none"> <li>1. Microvascular abnormalities, including microaneurysms, narrowing, and abnormal tortuosity.</li> <li>2. Hard exudates: due to damage to the retinal capillaries and neurons, fluid, protein, and other substances in the blood will penetrate into the retinal area, forming hard exudates.</li> <li>3. Non-proliferative diabetic retinopathy: including microvascular embolism, punctate hemorrhage, exudation and crystalline exudation.</li> <li>4. Proliferative diabetic retinopathy: including neovascularization and scar tissue, these lesions may extend into the vitreous cavity and may cause retinal detachment.</li> </ol> Diabetic retinopathy has various types of lesions and degrees of severity.If you have diabetes, please pay close attention to eye health, undergo regular eye exams, and follow your doctor's advice for treatment and preventive measures, such as controlling blood sugar, blood pressure, and lipids. Early detection and treatment of lesions can prevent or slow down their progression and reduce the risk of eye complications.

Table 4. Improving the ability to answer medical basic questions

	example 4	example 5	example 6
Related Disease	DR	Glaucoma	PM
Question	How can I prevent further progression of diabetic retinopathy if I already have diabetes?	What medications can be used to treat or slow the progression of glaucoma?	What are the lesions of pathologic myopia in fundus images?
ChatGLM	To prevent diabetic retinopathy, it is necessary to control diet and exercise, and regularly monitor blood sugar levels.	Medications used to treat glaucoma include Kaiyipin and other drugs, which can reduce the accumulation of aqueous humor and lower the risk of glaucoma by lowering intraocular pressure (IOP) and promoting the outflow of aqueous humor.	The fundus images of pathological myopia may show retinal detachment, choroidal detachment, and retinal neovascularization.
OphGLM	<p>Diabetes is one of the main risk factors for developing diabetic retinopathy. If you have been diagnosed with diabetes, you can take the following measures in your daily life to prevent diabetic retinopathy:</p> <ol style="list-style-type: none"> <li>1. Undergo regular eye exams: if you have diabetes, please undergo regular eye exams as required by your doctor to detect and treat diabetic retinopathy early.</li> <li>2. Control blood sugar levels: maintaining stable blood sugar levels can reduce the risk of diabetes complications, including diabetic retinopathy. Please follow your doctor's treatment plan, such as taking medication regularly, appropriate exercise, and a healthy diet to control blood sugar.</li> <li>3. Control high blood pressure and high cholesterol: high blood pressure and high cholesterol can also accelerate the development of diabetic retinopathy, so please follow your doctor's advice and actively control these conditions.</li> <li>4. Quit smoking and limit alcohol consumption: smoking and alcohol consumption can both increase the risk of diabetes complications, including diabetic retinopathy. Quitting smoking and limiting alcohol consumption can help reduce these risks.</li> </ol>	<p>Glaucoma is a disease characterized by elevated intraocular pressure, which cannot be cured on its own and typically requires medication to control eye pressure and prevent further vision damage. Here is a list of some drugs used to treat glaucoma:</p> <ol style="list-style-type: none"> <li>1. Intraocular pressure inhibitors such as Reye (latanoprost) can reduce intraocular pressure by inhibiting bacterial growth and are suitable for glaucoma patients.</li> <li>2. Anti-glaucoma drugs such as AstraZeneca (brinzolamide) and Novartis (brimonidine) and other brands can slow down the progression of glaucoma and loss of vision by reducing intraocular pressure.</li> <li>3. Over-the-counter eye pressure-lowering drugs such as 0.1% atropine eye drops can relax the retinal nerve fibers and vascular bundles to lower intraocular pressure and are suitable for glaucoma patients.</li> <li>4. Combination therapy of intraocular pressure inhibitors and anti-glaucoma drugs can increase treatment efficacy and reduce the risk of complications. These medications should be used under the guidance of a doctor, as different medications may have different side effects and adverse reactions.</li> </ol> <p>Additionally, glaucoma medication is just one method of controlling intraocular pressure and patients need to take other measures, such as avoiding eye strain, undergoing regular vision checks, and following their doctor's recommendations.</p>	<p>Pathological myopia, also known as high myopia or degenerative myopia, is a common type of myopia characterized by an excessively elongated eyeball that causes light to not focus fully on the retina, leading to retinal damage. Here are some common retinal lesions that can be seen in pathological myopia:</p> <ol style="list-style-type: none"> <li>1. Retinal detachment: In pathological myopia, the retina may become detached due to excessive stretching and pressure, which can lead to vision loss.</li> <li>2. Neovascularization: Due to the elongated eyeball in pathological myopia, new blood vessels may grow in the retina, causing malnutrition and bleeding.</li> <li>3. Fissures: The elongated eyeball in pathological myopia can cause fissures in the retina, which can lead to retinal rupture and vision loss.</li> <li>4. Choroidal neovascularization: Excessive stretching and pressure on the retina in pathological myopia can lead to choroidal neovascularization, a common retinal disease that can result in vision loss.</li> <li>5. Leopard-spot-like vision: Due to retinal damage caused by excessive stretching and pressure in pathological myopia, leopard-spot-like vision patterns may appear in the retina.</li> </ol> <p>These are common retinal lesions associated with pathological myopia, and if you have any questions, it is recommended to consult a doctor for more detailed advice and diagnosis.</p>