

Free-Breathing Myocardial T_1 Mapping using Inversion-Recovery Radial FLASH and Motion-Resolved Model-Based Reconstruction

Xiaoqing Wang^{*2,3}, Sebastian Rosenzweig^{2,3}, Volkert Roeloffs²,
Moritz Blumenthal², Zhengguo Tan^{2,3}, Nick Scholand^{2,3}, H.
Christian M. Holme^{2,3}, and Martin Uecker^{1,2,3,4}

¹Institute of Biomedical Imaging, Graz University of Technology,
Graz, Austria

²Institute for Diagnostic and Interventional Radiology of the
University Medical Center Göttingen, Germany

³German Centre for Cardiovascular Research (DZHK), Partner
Site Göttingen, Germany

⁴Cluster of Excellence “Multiscale Bioimaging: from Molecular
Machines to Networks of Excitable Cells” (MBExC), University of
Göttingen, Germany

November 22, 2021

Abstract

Purpose: To develop a free-breathing myocardial T_1 mapping technique using free-running inversion-recovery (IR) radial fast low-angle shot (FLASH) and calibrationless motion-resolved model-based reconstruction.

Methods: A free-running inversion-recovery radial FLASH sequence is used for data acquisition at 3T. To reduce the waiting time between inversions, a new analytical formula is derived that takes the incomplete T_1 recovery into account to achieve an accurate T_1 calculation. The respiratory motion signal is estimated from the filtered k-space center using an adapted singular spectrum analysis (SSA-FARY) technique. The cardiac motion signal is recorded using electrocardiography. A motion-resolved model-based reconstruction is used to estimate both parameter and coil sensitivity maps directly from the sorted k-space data. Spatial-temporal total variation, in addition to the spatial sparsity constraints, is applied

*Xiaoqing Wang, University Medical Center Göttingen, Institute for Diagnostic and Interventional Radiology, Robert-Koch-Str. 40, 37075 Göttingen, Germany
xiaoqing.wang@med.uni-goettingen.de

to the parameter maps to improve T_1 accuracy and precision. Validations are performed on an experimental T_1 phantom and five human subjects.

Results: In comparison to a reference method, phantom results confirm good T_1 accuracy when reducing the waiting time from five seconds to one second using the new T_1 correction. The motion-resolved model-based reconstruction further improves T_1 precision. Aside from showing that a reliable respiratory motion signal can be estimated using modified SSA-FARY, in vivo studies with five healthy subjects demonstrate that high-resolution dynamic myocardial T_1 maps ($1.0 \times 1.0 \times 6 \text{ mm}^3$) can be obtained within two minutes with good T_1 precision and repeatability.

Conclusion: High-resolution motion-resolved T_1 mapping during free breathing with good T_1 accuracy, precision and repeatability can be achieved by combining inversion-recovery radial FLASH, self-gating and a calibrationless motion-resolved model-based reconstruction.

Keywords: myocardial T_1 mapping, model-based reconstruction, radial FLASH, spatial-temporal total variation

1 Introduction

Quantitative myocardial T_1 mapping is becoming more and more important in clinical cardiovascular magnetic resonance (CMR) imaging [1, 2]. For example, both native and post-contrast T_1 mapping can be used to assess diffuse myocardial fibrosis [3]. Commonly used T_1 mapping techniques are modified Look-Locker inversion recovery (MOLLI) [4], saturation recovery single-shot acquisition (SASHA) [5], and saturation pulse prepared heart rate independent inversion recovery (SAPPHIRE) [6]. These techniques normally utilize a breathhold to mitigate respiratory motion and use an external electrocardiogram (ECG) device to synchronize data acquisition to a certain cardiac phase (e.g., end-diastolic), reducing the influence of cardiac motion. Although widely used, the need of a breathhold time of around 11 to 17 heartbeats may cause discomfort for patients (such as heart failure patients) and limits the achievable spatial resolution. Substantial efforts were made to shorten the breathhold period by optimized sampling [7] or by using non-Cartesian acquisition for single-shot myocardial T_1 mapping [8, 9, 10, 11]. More recently, free-breathing strategies [12, 13, 14, 15, 16] were investigated. These approaches acquire data continuously without the need for breath-holding and extract motion (respiration and/or cardiac) signals from the measured data itself using self-gating techniques. Following motion-resolved image reconstruction and pixel-wise fitting/matching, cardiac T_1 maps states can then be obtained for certain motion states.

Model-based reconstruction [17, 18, 19] is an alternative approach to quantitative MRI. These methods directly reconstruct parameter maps from k-space, substantially reducing the number of unknowns to the number of actual physical parameters by not first reconstructing contrast-weighted images. They also offer a flexible choice of temporal footprint for parameter quantification as no intermediate image reconstruction is needed. Furthermore, sparsity constraints

can be applied directly to the parameter maps to improve precision [20, 21, 22]. Model-based approaches have been used to accelerate myocardial T_1 mapping at high spatial resolution [23, 24], but still require breath-holding.

Combining idea from all these strategies, we aim to develop a free-breathing myocardial T_1 mapping technique by combining a free-running inversion-prepared radial FLASH sequence, an adapted self-gating technique and a calibrationless motion-resolved model-based reconstruction. In particular, we acquire data using free-running IR radial FLASH with a delay between inversions. Instead of setting the delay long enough to allow for a full T_1 recovery (> 5 s), we have derived an analytical formula for accurate T_1 calculation even when the T_1 recovery is incomplete, i.e., ≤ 3 s. We then use an extended technique based on SSA-FARY [25] to extract the respiratory motion signal from the k-space center. Trajectory-dependent oscillations and inversion contrast is eliminated in a pre-processing step. Finally, after sorting raw data into a number of respiration and cardiac bins based on the estimated respiration signal and the recorded ECG signal, we estimate both parameter maps and coil sensitivity maps of the desired motion bins directly from k-space using a calibrationless motion-resolved model-based reconstruction. The latter is an extension of a previously developed model-based reconstruction [21, 24] to the motion-resolved case which enables the application of sparsity constraints along all motion dimensions, in addition to the spatial regularization, to further improve T_1 accuracy and precision. Validation of the proposed method was performed on an experimental phantom and five healthy subjects.

2 Theory

Sequence Design and T_1 Estimation from Incomplete Recovery

The free-running T_1 mapping sequence is shown in Figure 1 (A). It consists of three repeated blocks: (1) non-selective inversion (2) a continuous radial FLASH readout using a tiny golden-angle ($\approx 23.63^\circ$) [26] with a 3-s duration (3) and a time delay (T_1 recovery) before the inversion in the next repetition. In previous studies using multiple inversions [27, 28], the delay time was set long enough to ensure a full recovery of longitudinal magnetization so that T_1 can still be calculated using the conventional Look-Locker formula [29, 30]. However, a full recovery may need as long as 5 seconds for cardiac T_1 mapping, which prolongs the total acquisition time. In this work, we treat this delay as a period that encodes T_1 information in the data. We use an analytical formula based on T_1 , T_1^* , the steady-state signal M_{ss} , and the new start magnetization signal M_0 (i.e., in the case that the T_1 recovery is not complete: $M_0' < M_0$, with M_0 the equilibrium magnetization):

$$M_0' = \frac{R_1 M_{ss} R_1^* (1 - E_1) + E_1 M_{ss} (1 - E_1^*)}{1 + E_1 \cdot E_1^*} \quad (1)$$

where $E_1 = e^{-R_1 \cdot t_1}$, $E_1^* = e^{-R_1^* \cdot t_{1s}}$, $R_1 = 1/T_1$, $R_1^* = 1/T_1^*$ and t_1, t_{1s} are the time periods for T_1 and T_1^* relaxation, respectively. Thus, T_1 can be estimated even from partial T_1 recoveries after reconstruction of the parameter maps $(M_{ss}, M_0', R_1^*)^T$ according to Equation (1). Here, we adopt a bisection root-finding algorithm to solve Equation (1). A full derivation of the above equation can be found in the Supporting Information File.

Respiratory Motion Estimation

The main steps of the respiratory motion estimation process is demonstrated in the flowchart in Figure 1 (B). In the following, we explain all these steps in detail. Similar to [31, 25], we construct an auto-calibration (AC) region for self-gating using the central k-space samples of a radial acquisition, resulting in a time-series $X(t)$ of size $[N_C \times N_T]$, with N_C and N_T the total number of channels (phased array coils) and central k-space points, respectively. $N_T = N_S \cdot N_I$, with N_S the number of sampling points per IR and N_I the total number of inversions. The AC data is usually corrupted by a trajectory-dependent signal due to eddy currents. Therefore, we first remove such oscillations by extending the method of orthogonal projections (with higher-order harmonics) from the steady-state case [25] to the contrast-change case (inversion recovery). Details of this procedure can be found in the Appendix I.

Following removal of the oscillations, the new k-space center signal $\tilde{X}(t)$ can be modeled as

$$\tilde{X}(t) = s(t) \cdot m_1(t) + m_2(t) \quad (2)$$

with $s(t)$ the steady-state signal which contains motion information (ideally without contrast change), and $m_1(t)$ and $m_2(t)$ the multiplicative and additive signals which model the contrast change due to inversion [32]. Here we propose the following procedure to remove the main effects from the changing contrast and to extract the signal component that is most relevant for respiratory motion:

- Step 1. Estimating $m_2(t)$: Perform the singular spectrum analysis (SSA) on $\tilde{X}(t)$, remove the components that are mostly related to the inversion-recovery contrast in the spectrum domain and transfer the processed signal back to the time domain. In SSA [25], this step largely removes the additive contrast-changing component of Equation (2), resulting in a new signal $\tilde{X}_1(t) = \tilde{X}(t) - \tilde{m}_2(t)$, with $\tilde{m}_2(t)$ the estimated additive contrast-changing signal.
- Step 2. Estimating $m_1(t)$: Since the multiplicative component is mainly left in Equation (2), the singular value decomposition (SVD) is then performed on $\tilde{X}_1(t)$ and the corresponding rank-one approximation is taken, generating an estimate of the multiplicative component $\tilde{m}_1(t)$. Next, the magnitude of $\tilde{m}_1(t)$ was utilized for the calculation, leading to a new signal $\tilde{s}(t) = \frac{\tilde{X}_1(t)}{|\tilde{m}_1(t)|}$. Due to the 180° phase difference before and after zero-crossing caused by inversion, the phase of $\tilde{s}(t)$ before zero-crossing needs to be inverted. This was done by first detecting the minimum points of

the absolute value of signal $\tilde{X}(t)$ (zero-crossing) for each coil and inversion and then correcting using:

$$\tilde{s}_1(t) = \begin{cases} -\tilde{s}(t), & \text{if } t \leq \text{zero-crossing} \\ \tilde{s}(t), & \text{otherwise.} \end{cases} \quad (3)$$

- Step 3. Zero-padding: To account for the missing temporal information due to the delay time between inversions, $\tilde{s}_1(t)$ was zero-padded, generating a new signal $\tilde{s}_2(t) \in C^{[N_C \times (N_I \cdot (N_S + N_Z))]}$ with N_Z calculated by $N_Z = \frac{\text{Delay Time}}{\text{Repetition Time (TR)}}$.
- Step 4. SSA-FARY: Perform SSA-FARY on $\tilde{s}_2(t)$ with the window size tuned to estimate the signal component that is most relevant for the respiratory motion.

Motion-Resolved Model-Based Reconstruction

The acquired k-space data is then sorted into 6 respiration and 20 cardiac bins using amplitude binning [33] based on the estimated respiratory signal and the recorded ECG signal. The MR physical parameter maps in Equation (1) for the selected motion states are estimated directly from k-space using a calibrationless model-based reconstruction [21, 24]. Here, to further exploit sparsity along the motion dimensions, the previous model-based reconstruction is extended to the motion-resolved case by formulating the estimation of parameter maps and coil sensitivity maps from the selected motion states as a single regularized nonlinear inverse problem:

$$\hat{x} = \arg \min_{x \in Q} \sum_{r=1}^{N_R} \sum_{a=1}^{N_A} \|F_{r,a}(x) - Y_{r,a}\|_2^2 + \alpha R(x_m) + \beta U(x_c) \quad (4)$$

where F is a nonlinear operator [24] mapping all unknowns x to the sorted k-space data Y . N_R , N_A are the numbers of respiration and cardiac bins, respectively. $x = (x_m, x_c)^T$ where x_m contains MR physical parameter maps in Equation (1), i.e., $(M_{ss}, M'_0, R_1^*)^T$ of all the selected motion states and x_c represents coil sensitivity maps $(c_1, \dots, c_{N_C})^T$ for the corresponding motion states. Q is a convex set ensuring non-negativity of the relaxation rate R_1^* . For the regularization $R(\cdot)$, we first adopt the joint ℓ_1 -Wavelet spatial constraints [21]. Second, we add the temporal total variation (TV) regularization to explore sparsity along the motion dimensions [34]. Furthermore, as a pure TV may favor straight lines if applied along the motion dimension only, we utilize a joint TV regularization along spatial and temporal dimensions to better preserve the spatial-temporal information. Thus, $R(\cdot)$ reads:

$$R(x_m) = \lambda_1 \|W x_m\|_1 + \sqrt{\lambda_2 \|D_x x_m\|^2 + \lambda_3 \|D_y x_m\|^2 + \lambda_4 \|D_a x_m\|^2 + \lambda_5 \|D_r x_m\|^2} \quad (5)$$

with $\|Wx_m\|_1$ the joint ℓ_1 -Wavelet spatial regularization and D_x, D_y, D_a and D_r the gradient operators along the x, y , cardiac and respiratory dimensions, respectively. $\lambda_1, \lambda_2, \lambda_3, \lambda_4$ and λ_5 are the corresponding weighting parameters, balancing the effects of different regularization terms. α is a global regularization parameter on $R(\cdot)$. $U(\cdot)$ represents the Sobolev regularization term [35] on the coil sensitivity maps with β the regularization parameter. Similar to [21, 24], the above nonlinear inverse problem is solved by the iteratively regularized Gauss-Newton method (IRGNM) algorithm [36] where the nonlinear problem in Equation (4) is linearizedly solved in each Gauss-Newton step, i.e.,

$$\hat{x}_{n+1} = \arg \min_{x \in Q} \sum_{r=1}^{N_R} \sum_{a=1}^{N_A} \|DF_{r,a}(x_n)(x-x_n) + F_{r,a}(x_n) - Y_{r,a}\|_2^2 + \alpha_n R(x_m) + \beta_n U(x_c) \quad (6)$$

with $DF_{r,a}(x_n)$ the Fréchet derivative of $F_{r,a}$ at the point x_n for the n th Gauss-Newton step. Here, the regularized least-squares subproblem (6) is solved by the ADMM algorithm [37] which enables the use of multiple regularizations. The IRGNM-ADMM algorithm follows a similar structure as IRGNM-FISTA in [21]. For the sake of completeness, we include the pseudocode for the IRGNM-ADMM algorithm in Appendix II.

3 Methods

Data Acquisition

All MRI experiments were performed on a Magnetom Skyra 3T (Siemens Healthineers, Erlangen, Germany) with approval of the local ethics committee. Validations were first performed on a commercial reference phantom (Diagnostic Sonar LTD, Scotland, UK) consisting of 6 compartments with defined T_1 values surrounded by water. Phantom scans employed a 20-channel head/neck coil, while in vivo measurements used a combined thorax and spine coils with 26 channels. Five young subjects (4 females and 1 male, 22 ± 3 years old) with no known illness were recruited. In the phantom study, the delay time TD in the sequence was varied from 5 s to 1 s (with a step size of 1 s) to study T_1 accuracy and precision when using the proposed T_1 estimation procedure. An optimal value of TD was then chosen for subsequent in vivo studies. In vivo scans were performed during free-breathing and synchronized with the ECG. To access repeatability of the proposed method, the free-running sequence was repeated twice for each subject. For FLASH readout, spoiling of the residual transverse magnetization was achieved using random radiofrequency (RF) phases [38]. The other acquisition parameters were: field of view (FOV) = 256×256 mm², slice thickness = 6 mm, matrix size = 256×256 , TR / echo time (TE) = 3.27/1.98 ms, RF-pulse time-bandwidth product = 4.5, nominal flip angle = 6° , receiver bandwidth = 810 Hz/pixel and a total acquisition time of 21 inversions, i.e., around 2 min with 915 radial spokes per inversion. A window size of 21 frames was chosen for the adapted SSA-FARY technique [25].

For reference, the gold standard T_1 mapping was performed on the phantom using an IR spin-echo method [39] with 9 IR scans (TI = 30, 530, 1030, 1530, 2030, 2530, 3030, 3530, 4030 ms), TR/TE = 4050/12 ms, FOV = 192×192 mm², slice thickness = 5 mm, matrix size = 192×192 , and a total acquisition time of 2.4 h. For in vivo studies, a 5(3)3 MOLLI reference sequence provided by the vendor was applied for end-diastolic T_1 mapping using a FOV of 360×306.6 mm², in-plane resolution = $1.41 \times 1.41 \times 8$ mm³, TR/TE = 2.7/1.12 ms, nominal flip angle = 35°, receiver bandwidth = 1085 Hz/pixel and an acquisition period of 11 heart beats during a single breathhold.

Iterative Reconstruction

The motion-resolved model-based reconstruction algorithm was implemented using the nonlinear operator and optimization framework in Berkeley Advanced Reconstruction Toolbox (BART) [40]. To reduce computational demand, we selected three respiratory motion bins (out of 6) close to the end-respiratory state and all cardiac bins for the motion-resolved quantitative reconstruction. Similar to [21], we initialized the parameter maps $(M_{ss}, M'_0, R_1^*)^T$ with $(1.0, 1.0, 1.5)^T$ and all coil sensitivities with zeros in the IRGNM-ADMM algorithm. Moreover, as a high accuracy is usually not necessary during the first Gauss-Newton steps, we set the number of ADMM iteration steps to be $N_n = \min(100, 2N_{n-1})$ at the n -th Gauss-Newton step with $N_0 = 10$. This setting resulted in stable reconstructions for all cases tested.

Regularization parameters were tuned to balance the preservation of image details versus reduction of noise. The regularization parameters α and β were initialized with 1.0 and subsequently reduced by a factor of three in each Gauss-Newton step. A minimum value of α was used to control the noise of the estimated parameter maps even with a large number of Gauss-Newton steps, i.e., $\alpha_{n+1} = \max(\alpha_{\min}, (1/3)^n \cdot \alpha_n)$. The optimal value α_{\min} as well as the weighting parameters λ s were chosen manually to optimize the signal-to-noise ratio (SNR) without compromising the quantitative accuracy or delineation of structural details. Particularly, the choice of α_{\min} is demonstrated in Figure 5, while λ_1 was set to be 0.2 and parameters $(\lambda_2, \lambda_3, \lambda_4, \lambda_5)^T$ in the weighted spatial-temporal TV regularization term in Equation (5) were set to be $(0.4, 0.4, 1.0, 0.2)^T$. For comparison, the other types of regularization, such as the spatial-only (ℓ_1 -Wavelet) regularization ($R(x_{\mathbf{m}}) = \lambda_1 \|Wx_{\mathbf{m}}\|_1$), temporal TV regularization ($R(x_{\mathbf{m}}) = \lambda_4 \|D_c x_{\mathbf{m}}\|_1 + \lambda_5 \|D_r x_{\mathbf{m}}\|_1$) and the combination of the above two ($R(x_{\mathbf{m}}) = \lambda_1 \|Wx_{\mathbf{m}}\|_1 + \lambda_4 \|D_c x_{\mathbf{m}}\|_1 + \lambda_5 \|D_r x_{\mathbf{m}}\|_1$) were also implemented and first evaluated on a simulated dynamic phantom using the parallel imaging and compressed sensing (PICS) tool in BART, followed by the evaluation on the data of one subject with the proposed motion-resolved model-based reconstruction. More details regarding the simulated dynamic phantom can be found in the Supporting Information File.

With the above parameter settings, all image reconstruction was done offline using a 40-core 2.3 GHz Intel Xeon E5-2650 server with a RAM size of 512 GB. After gradient-delay correction [41] and channel compression to six principal

components, the multi-coil radial data were gridded onto a Cartesian grid, where all successive iterations were then performed using FFT-based convolutions with the point-spread function [42]. To reduce memory demand during iterations, 15 spokes were binned into one k-space frame prior to model-based reconstruction, resulting in a nominal temporal resolution of around 49 ms. It then took around 12 hours to reconstruct one in vivo data set using the above reconstruction parameters.

T_1 Analysis

All quantitative T_1 results are reported as mean \pm standard deviation (SD). For the in vivo studies, T_1 maps from the end-diastolic and end-respiratory phase were selected for quantitative assessment of the proposed method. Regions-of-interest (ROIs) were carefully drawn into the myocardial septal regions to minimize partial volume errors using the arrayShow [43] tool in MATLAB (MathWorks, Natick, MA). The repeatability error was calculated using

$\sqrt{(\sum_{i=1}^{n_s} T_{1\text{diff}}^2(i))/n_s}$, with $T_{1\text{diff}}(i)$ the T_1 difference between two repeated measurements and n_s the number of subjects. The precision of T_1 estimation was computed using the coefficient of variation ($\text{CoV} = \text{SD}_{\text{ROI}} / \text{Mean}_{\text{ROI}} \times 100\%$). Further, the two-tailed Student’s t-tests were utilized for comparison, and a p value ≤ 0.05 was considered significant.

4 Results

Phantom Validation

We first validated the proposed T_1 correction procedure for phantom T_1 mapping when using different delay times in the multi-shot acquisition in comparison to an IR spin-echo reference. Figure 2 presents the estimated T_1 maps for acquisitions with a delay time ranging from five seconds to one second (step size one second) when using the conventional Look-Locker formula and the proposed procedure. Prior to T_1 correction, all the physical parameters $(M_{ss}, M'_0, R_1^*)^T$ were estimated by the single-slice model-based reconstruction [21] using the data from the second inversion, where the initial magnetization is affected by the incomplete recovery. Both quantitative T_1 maps and T_1 values of a ROI reveal that the conventional Look-Locker correction underestimates T_1 : the less the delay time, the higher the bias. On the other hand, the proposed procedure could achieve good T_1 accuracy regardless of the delay time, but at the expense of increased noise (i.e., lower precision) for short delays and large T_1 times. This is mainly due to the fact that there is less T_1 information encoded in the data for shorter delays. In the extreme case where there is no delay, it is impossible to recover T_1 (i.e., decouple T_1 and B_1^+ from T_1^*) as no explicit T_1 is encoded in the data. According to these results, a delay time of two seconds or three seconds is a good compromise between short acquisition time and good T_1 precision. We choose three seconds for the other acquisitions in this study.

Subsequently, we evaluated the proposed motion-resolved model-based reconstruction on the same phantom using the multi-shot data with the delay time of three seconds. The data has been sorted into 6 respiratory and 20 cardiac motion states based on the motion signals estimated from one human subject (subject #3, scan #1). Figure 3 (top) shows the estimated phantom T_1 maps (selected at the end-expiration and end-diastolic phase) with the spatial-only regularization using two different regularization parameters $\alpha_{\min} = 0.005$ and $\alpha_{\min} = 0.02$, and its combination with the spatial-temporal TV regularization with $\alpha_{\min} = 0.005$. Figure 3 (bottom) plots the corresponding quantitative T_1 values of the ROI against the IR spin-echo reference. The quantitative results show that all reconstructions could achieve a good T_1 accuracy. The increase of the regularization strength in the spatial-only regularization or the use of an additional spatial-temporal TV with the same regularization parameter is helpful for reducing noise (improving T_1 precision) in the quantitative phantom T_1 maps.

In Vivo Studies

Respiratory Motion Estimation

Figure 4 shows the DC component for one inversion recovery before and after data correction using the extended orthogonal projection with the order of harmonics N_H set to be five. Some coils exhibit strong oscillations. The oscillation period in the AC data is linked to the period of the projection angle used in the radial acquisition [25]. By removing this frequency and the higher-order harmonics, these oscillations can be largely eliminated. The filtered DC component is then used for self-gating.

The background of Figure 5 (A) represents the temporal evolution of a line profile extracted from a real-time image reconstruction [42] of the free-running IR radial FLASH with 12 inversions. The line was placed in the vertical direction of the real-time image series where the diaphragmatic motion can be observed, as demonstrated by the white vertical line in Figure 5 (B). On top of the line profiles, the estimated respiratory signal and the signal provided by the respiratory belt are plotted. All motion signals have been scaled for better visual comparison. The estimated respiratory signal coincides well with the motion of the diaphragm in the real-time images. The adapted SSA-FARY technique could also provide reliable motion signal in the region where the respiratory belt failed to produce a signal (pointed out by a white arrow). Figure 4 (B) shows the corresponding steady-state images reconstructed with the non-uniform fast Fourier transform (nuFFT) after binning the data into 6 respiratory motion states using the estimated respiration signal. As indicated by the dashed lines, the different inspiration and expiration phases are well resolved.

Model-Based Myocardial T_1 Mapping

We validated the effects of different regularization types used in the model-based reconstruction. Figure 6 shows myocardial T_1 maps (at the selected end-

expiration and end-diastolic phase) for one subject and the corresponding T_1 line profiles (as indicated by the dashed black line) through all cardiac phases with various regularization types. The regularization parameter α_{\min} has been optimized for each type of reconstruction individually. In particular, α_{\min} was set to be 0.02, 0.02, 0.007 and 0.005 for spatial (ℓ_1 -Wavelet) only, temporal TV only, combined spatial (ℓ_1 -Wavelet) and temporal TV, and the proposed regularization that combines spatial (ℓ_1 -Wavelet) and a spatial-temporal TV, respectively. The spatial (ℓ_1 -Wavelet) only regularization creates noisy and degraded myocardial T_1 maps. The temporal TV regularization could improve the image quality significantly by exploiting the temporal sparsity. However, this kind of regularization also favors straight lines and thus creates "line"-like artifacts along the time/motion dimension (as seen the line profile images). The combination of spatial (ℓ_1 -Wavelet) and temporal TV regularization could reduce these "line"-like effects as a weaker temporal TV regularization is needed to achieve a similar denoising effect. Finally, the spatial-temporal TV regularization that combined both spatial and temporal information in a single multi-dimensional TV regularization, and its combination with the spatial (ℓ_1 -Wavelet) regularization, could achieve an even better compromise between denoising and the preservation of subtle motion in the line profiles (indicated by the black arrows) than the other types of regularization. Noteworthy, the myocardial T_1 map from the spatial-only regularization is noisier than our previous single-shot results [24]. This is mainly due to the fact that there is much less data in one motion state in the motion-resolved reconstruction than the one in [24] which combines data from several diastolic phases (e.g., ~ 285 spokes vs ~ 800 spokes). The Supporting Information Figure S1 shows a similar comparison of the effects of various regularization types on a simulated dynamic phantom. Here, all reconstructions were done with the same regularization parameter. In line with the in vivo results presented here, the spatial-temporal TV combined with the spatial (ℓ_1 -Wavelet) regularization has the best performance in denoising and preservation of structure details in the line profile images.

Figure 7(A) shows the effects of the minimum regularization parameter α_{\min} on myocardial T_1 maps and the line profiles through the cardiac phases using the combination of the spatial-temporal TV and the spatial (ℓ_1 -Wavelet) regularization. Figure 7 (B) presents the corresponding quantitative myocardial septal T_1 values for the ROI. As expected, both qualitative and quantitative results reveal that low values of α_{\min} result in noisy maps (higher standard deviation) while high values may introduce blurring in the images. $\alpha_{\min} = 0.005$ was then chosen to balance noise reduction and preservation of anatomical details.

With the above settings, Figure 8 shows a MOLLI T_1 map and two myocardial T_1 maps at the end-diastolic and end-systolic phases (the same respiratory motion state) as well as the T_1 line profile through the cardiac phase using the proposed method for two representative subjects. Although the breathing conditions are different, diastolic myocardial T_1 maps are visually comparable between MOLLI and the free-breathing technique. Besides the diastolic T_1 map, the proposed method could also provide myocardial T_1 maps at other cardiac phases. The Supporting Information Figure S2 then presents two repetitive my-

ocardial T_1 maps (end-expiration and end-diastolic) of the proposed method and a MOLLI T_1 map for all subjects. Despite differences in breathing conditions between scans, the free-breathing T_1 maps are visually comparable between the two repetitive scans for all subjects. The quantitative septal T_1 results in Figure 9 confirm our findings. The repeatability error is 11 ms (0.8% of the mean) for all scans and all subjects for the proposed method, which is comparable to the MOLLI technique (11 ms, 0.9% of the mean). Further, Figure 9 and the Supporting Information Table S1 shows the proposed method achieves a slightly higher myocardial septal T_1 values (1261 ± 29 ms vs 1232 ± 26 ms, $p < 0.04$) with a slightly lower T_1 precision (CoV values: $3.4\% \pm 0.6\%$ vs $2.7\% \pm 0.6\%$, $p < 0.03$) than the MOLLI reference for all subjects. Moreover, quantitative results in the Supporting Information Table S1 reveal that the proposed correction method generates higher T_1 values than the conventional Look-Locker correction technique (1261 ± 29 ms vs 1231 ± 30 ms, $p < 0.04$).

In addition to the quantitative myocardial T_1 maps, Figure 10 presents synthesized T_1 -weighted cardiac images (bright blood and dark blood) at the two cardiac phases for the same subjects shown in Figure 8. Both the bright-blood and dark-blood-weighted images clearly resolve the contrast between myocardium and blood pool. The synthetic images and myocardial T_1 maps at all cardiac phases were then converted into movies which are available as Supporting Information Videos S1 and S2. Similarly, a synthetic image series for all inversion times and all cardiac phases of one subject can be found in the Supporting Information Video S3.

5 Discussion

In this work, we have developed a free-breathing high-resolution myocardial T_1 mapping technique using a free-running inversion-recovery radial FLASH sequence and a calibrationless motion-resolved model-based reconstruction. Instead of continuous acquisitions, we adopt a delay time between inversions to encode T_1 information and have derived a correction procedure for accurate T_1 estimation without the need of full T_1 recovery or additional B_1^+ mapping. We further adapted the SSA-FARY strategy for robust respiratory motion signal estimation from the zero-padded AC region where the trajectory-dependent oscillations and contrast changing signal (due to inversion) have been eliminated in preprocessing. Following self-gating and data sorting, we propose to estimate both parameter maps and coil sensitivity maps of the desired motion states directly from k-space using an extended motion-resolved model-based reconstruction. The latter avoids any coil calibration and can employ high-dimensional spatial-temporal TV regularization, in addition to the spatial regularization, to improve precision in T_1 while preserving the spatial-temporal information. Both studies on an experimental phantom and 5 healthy subjects demonstrate high-resolution T_1 mapping ($1.0 \times 1.0 \times 6$ mm³) can be achieved within two minutes and with good accuracy, precision and repeatability.

Continuous acquisitions with constant flip angles [13, 14] have been used

in several inversion-prepared free-running T_1 mapping techniques attributed to the scan efficiency. I.e., there is no waiting time between inversions. However, as pointed out by [16], continuous acquisition with the same flip angle only encodes T_1^* information in the data [29]. Since T_1^* is a function of flip angle and T_1 , additional information about B_1^+ is therefore necessary for accurate T_1 estimation. However, the additional estimation of B_1^+ at the same motion state might be difficult to achieve in free-breathing, self-gated acquisitions. In [16], Zhou et al. propose to solve this issue by introducing a dual flip-angle strategy which acquires data continuously with two flip angles consecutively applied. Following self-gated data sorting, image reconstruction and dictionary matching, two different T_1^* maps from the same motion state can be extracted and subsequently be used to calculate both T_1 and B_1^+ maps in an iterative manner. Most recently, a similar idea has been proposed in the MR multitasking technique for more accurate T_1 mapping [44]. Alternatively, in this work, we propose to resolve this problem by adopting a delay time between inversions, using this period for encoding T_1 information in the data. Different from studies which set the delay time long enough to ensure a full recovery of longitudinal magnetization, we are capable of estimating accurate T_1 even with an incomplete T_1 recovery, shortening the acquisition time. Moreover, the proposed approach requires neither additional B_1^+ mapping nor the explicit calculation of B_1^+ from the data.

Self-gating constitutes another key component for free-breathing imaging. Although a few self-gating techniques have been successfully developed for steady-state imaging, estimation of reliable motion signals from the contrast-modulated k-space is challenging. In this work, following removal of signal oscillations in the k-space center signal, we model the additive and multiplicative effects caused by inversion in the data following [32] and propose to reduce such effects prior to the application of the SSA-FARY-based self-gating techniques. From our experience, the above step is crucial for reliable motion estimation using SSA-FRAY. Although the proposed method could achieve robust respiration signal estimation, the determination of reliable cardiac signals from the filtered k-space remained challenging.

Inspired by the high-dimensional imaging techniques [34, 45, 46, 12], we have sorted the data into multiple cardiac and respiratory motion states, and applied high-dimensional regularization along these motion dimensions to improve T_1 accuracy and precision. In contrast, several other studies [14, 16] combined data from multiple respiratory motion states into one using rigid image registration, following respiratory motion field being estimated from low-resolution images. The latter strategy has the advantage that more data is available for each cardiac phase than the one that sorts the data into multiple respiratory and cardiac motion states within the same amount of time. However, as motion between respiratory states is usually considered to be nonlinear [47] for cardiac imaging, a linear model may cause data mismatch in the cost function, resulting in reconstruction errors. Most recently, advanced nonlinear motion estimation methods have been developed for whole-heart coronary MR imaging [48]. Integration of such a nonlinear motion model into the model-based reconstruction framework

would also be of great interest as it has the potential to shorten the total acquisition time of the proposed method while preserving good T_1 accuracy and precision.

The proposed method takes around two minutes for reliable T_1 estimation, which compares well to alternative techniques when considering the relatively high resolution of the T_1 maps ($1.0 \times 1.0 \times 6 \text{ mm}^3$). The acquisition time could be shortened by further reducing the delay time. Here, we adopted the three-second delay to achieve a good compromise of T_1 accuracy and precision. However, in principle, a delay time of one second could be used (at a cost of lower precision), resulting in an acquisition time of around 80 s.

There are also other limitations of the present work need to be mentioned. First, the blood T_1 estimated by methods using continuous acquisition may not be reliable as the in-flow effects make the blood violate the assumed signal model, a problem which also affects other methods based on continuous acquisition [16, 14]. Thus, the proposed method may not be ideal for the estimating the extracellular volume (ECV), although a recent study suggest that there is no significant difference of ECV values between MOLLI and one of the continuous acquisition techniques [49]. Second, evaluation of the proposed method has so far only been done on healthy volunteers. Application of the proposed free-breathing method to patient studies with both native and post-contrast T_1 mapping would be of great interest and will be subject of a future study. Another limitation of the proposed method is the long computation time. The large size of the high dimensional data currently prevents the use of graphics processing unit (GPU) for the motion-resolved model-based reconstruction, which needs to hold all the data from all motion states in memory simultaneously. Past experience shows that such problems can be overcome using a combination of improved implementation techniques [50] and newer hardware.

6 Conclusion

The proposed free-breathing method enables high-resolution T_1 mapping with good T_1 accuracy, precision and repeatability by combing inversion-recovery radial FLASH, self-gating and a calibrationless motion-resolved model-based reconstruction.

7 Acknowledgement

We thank Dr. Haikun Qi from ShanghaiTech University for insightful discussions.

A Appendix

Appendix I: Oscillation Removal

As described in [25], for the steady-state AC signal \mathbf{X} , we want to remove an oscillation which can be described by the basis:

$$\mathbf{n}^t = \begin{pmatrix} e^{+i\psi_0 \cdot t} \\ e^{-i\psi_0 \cdot t} \\ e^{+2i\psi_0 \cdot t} \\ e^{-2i\psi_0 \cdot t} \\ \vdots \\ e^{+N_H i\psi_0 \cdot t} \\ e^{-N_H i\psi_0 \cdot t} \end{pmatrix},$$

with $\psi_0 \cdot t$ the projection angle at time t , ψ_0 the incremental projection angle and N_H the highest order of the harmonic in the basis. Therefore, the corrected signal is $\mathbf{X}_{\text{cor}} = \mathbf{X} - \mathbf{n}(\mathbf{n}^\dagger \mathbf{X})$ with † denoting the pseudo-inverse. $\mathbf{n}(\mathbf{n}^\dagger \mathbf{X})$ is the projection of \mathbf{X} onto the basis \mathbf{n} .

For inversion prepared acquisitions, the contrast changes along time. The new centered k-space signal $\tilde{\mathbf{X}}$ can then be modeled by a global modulation for each channel c , i.e., $\tilde{X}_c(t) = \phi_c(t)X_c(t)$, where $\phi_c(t)$ describes the contrast change, and $\tilde{X}_c(t)$, $X_c(t)$ are the c th components of $\tilde{\mathbf{X}}$ and \mathbf{X} , respectively. As $X_c(t) = \sum_i n_i w_i + \eta$ with w_i the weighting factor and η the noise [25], $\tilde{X}_c(t) = \phi_c(t)X_c(t) = \sum_i \phi_c(t)n_i w_i + \phi_c(t)\eta$. Thus, our new basis for each channel becomes:

$$\tilde{\mathbf{n}}_c = \phi_c(t) \cdot \mathbf{n}_c$$

$\phi_c(t)$ can be determined using a moving average filter: $\phi_c(t) = \text{movavg}(\tilde{X}_c(t))$. The newly corrected signal is then: $\tilde{\mathbf{X}}_{\text{cor}} = \tilde{\mathbf{X}} - \tilde{\mathbf{n}}(\tilde{\mathbf{n}}^\dagger \tilde{\mathbf{X}})$.

Appendix II: IRGNM-ADMM algorithm

OUTPUTS: $(M_{ss}, M'_0, R_1^*)^T$ and $(c_1, \dots, c_{N_C})^T$ for all motion states

INPUTS:

$Y \leftarrow$ Gridded and sorted k-space data;

$P \leftarrow$ Sampling pattern;

$(t_1, \dots, t_{n_{TI}})^T \leftarrow$ Vector of inversion times for each motion state;

% Initialization for IRGNM:

$n = 0, \alpha_0 = \beta_0 = 1, \text{MaxIter} = 10, x_0 = (1, 1, 1.5, 0, \dots, 0)^T$

Let

$$A := \sum_{r=1}^{N_R} \sum_{a=1}^{N_A} DF_{r,a}(x_n)$$

$$b := \sum_{r=1}^{N_R} \sum_{a=1}^{N_A} \left(DF_{r,a}(x_n)x_n - F_{r,a}(x_n) + Y_{r,a} \right)$$

% Gauss-Newton Iterations:

while $n < \text{MaxIter}$ **do**

 % Solve the following subproblem with ADMM:

 % $x_{n+1} = \arg \min_{x \in Q} \|Ax - b\|_2^2 + \alpha_n R(x_m) + \beta_n U(x_c)$,
 with $x = (x_m, x_c)^T$.

 % Initialization for ADMM:

$k = 0, K = \min(100, 10 \cdot 2^n), \rho = 0.01, z^k = y^k = x_n$.

 % ADMM Iterations:

for $k < K$ **do**

$x^{k+1} \leftarrow (A^H A + \rho I)^{-1} (A^H b + \rho z^k - y^k)$

 % solved by conjugate gradient;

$z_m^{k+1} \leftarrow \mathbf{prox}_{\alpha_n/\rho}^m(x_m^{k+1} + y_m^k/\rho)$

 % proximal operators for parameter maps x_m ;

$z_c^{k+1} \leftarrow \mathbf{prox}_{\beta_n/\rho}^c(x_c^{k+1} + y_c^k/\rho)$

 % proximal operators for coil sensitivity maps x_c ;

$y^{k+1} \leftarrow y^k + \rho(x^{k+1} - z^{k+1})$;

end

$x_{n+1} = y^{k+1}$;

$\alpha_{n+1} = \max(\alpha_{\min}, (\frac{1}{3})^n \cdot \alpha_0)$;

$\beta_{n+1} = (\frac{1}{3})^n \cdot \beta_0$;

$n = n + 1$;

end

Algorithm 1: IRGNM-ADMM algorithm

In the above algorithm, $\mathbf{prox}_{\alpha_n/\rho}^m$ contains the following three proximal op-

erators:

$$\begin{aligned} Z_{\mathbf{m}}^{k+1} &:= W^H S_{\alpha_n/\rho}(W Z_{\mathbf{m}}^k) \quad (\text{Wavelet-domain joint soft-thresholding}) \\ Z_{\mathbf{m}}^{k+1} &:= P_Q(Z_{\mathbf{m}}^k) \quad (\text{projection of } Z_{\mathbf{m}}^k \text{ onto domain } Q) \\ Z_{\mathbf{m}}^{k+1} &:= D^H S_{\alpha_n/\rho} D Z_{\mathbf{m}}^k \quad (\text{Total variation gradient-domain soft-thresholding}) \end{aligned}$$

and $\text{prox}_{\alpha_n/\rho}^c$ is the least-square proximal operator, i.e.,

$$Z_{\mathbf{c}}^{k+1} := \frac{1}{2} Z_{\mathbf{c}}^k.$$

References

- [1] Moon JC, Messroghli DR, Kellman P, Piechnik SK, Robson MD, Ugander M, Gatehouse PD, Arai AE, Friedrich MG, Neubauer S et al. Myocardial T1 mapping and extracellular volume quantification: a Society for Cardiovascular Magnetic Resonance (SCMR) and CMR Working Group of the European Society of Cardiology consensus statement. *J. Cardiovasc. Magn. Reson.* 2013; 15:92.
- [2] Kellman P, Hansen MS. T1-mapping in the heart: accuracy and precision. *J. Cardiovasc. Magn. Reson.* 2014; 16:2.
- [3] Puntmann VO, Voigt T, Chen Z, Mayr M, Karim R, Rhode K, Pastor A, CarrWhite G, Razavi R, Schaeffter T et al. Native T1 mapping in differentiation of normal myocardium from diffuse disease in hypertrophic and dilated cardiomyopathy. *JACC: Cardiovascular Imaging* 2013; 6:475–484.
- [4] Messroghli DR, Radjenovic A, Kozerke S, Higgins DM, Sivananthan MU, Ridgway JP. Modified Look-Locker Inversion recovery (MOLLI) for high-resolution T1 mapping of the heart. *Magn. Reson. Med.* 2004; 52:141–146.
- [5] Chow K, Flewitt JA, Green JD, Pagano JJ, Friedrich MG, Thompson RB. Saturation recovery single-shot acquisition (SASHA) for myocardial T1 mapping. *Magn. Reson. Med.* 2014; 71:2082–2095.
- [6] Weingärtner S, Akçakaya M, Basha T, Kissinger KV, Goddu B, Berg S, Manning WJ, Nezafat R. Combined saturation/inversion recovery sequences for improved evaluation of scar and diffuse fibrosis in patients with arrhythmia or heart rate variability. *Magn. Reson. Med.* 2014; 71:1024–1034.
- [7] Piechnik SK, Ferreira VM, Dall’Armellina E, Cochlin LE, Greiser A, Neubauer S, Robson MD. Shortened Modified Look-Locker Inversion recovery (ShMOLLI) for clinical myocardial T1-mapping at 1.5 and 3 T within a 9 heartbeat breathhold. *J. Cardiovasc. Magn. Reson.* 2010; 12:1.

- [8] Gensler D, Mörchel P, Fidler F, Ritter O, Quick HH, Ladd ME, Bauer WR, Ertl G, Jakob PM, Nordbeck P. Myocardial T1 quantification by using an ECG-triggered radial single-shot inversion-recovery MR imaging sequence. *Radiology* 2014; 274:879–887.
- [9] Wang X, Joseph AA, Kalentev O, Merboldt KD, Voit D, Roeloffs VB, van Zalk M, Frahm J. High-resolution myocardial T1 mapping using single-shot inversion recovery fast low-angle shot MRI with radial undersampling and iterative reconstruction. *Brit. J. Radiol.* 2016; 89:20160255.
- [10] Hamilton JI, Jiang Y, Chen Y, Ma D, Lo WC, Griswold M, Seiberlich N. MR fingerprinting for rapid quantification of myocardial T1, T2, and proton spin density. *Magn. Reson. Med.* 2017; 77:1446–1458.
- [11] Marty B, Coppa B, Carlier PG. Fast, precise, and accurate myocardial T1 mapping using a radial MOLLI sequence with FLASH readout. *Magn. Reson. Med.* 2018; 79:1387–1398.
- [12] Christodoulou AG, Shaw JL, Nguyen C, Yang Q, Xie Y, Wang N, Li D. Magnetic resonance multitasking for motion-resolved quantitative cardiovascular imaging. *Nat. Biomed. Eng.* 2018; 2:215.
- [13] Shaw JL, Yang Q, Zhou Z, Deng Z, Nguyen C, Li D, Christodoulou AG. Free-breathing, non-ECG, continuous myocardial T1 mapping with cardiovascular magnetic resonance multitasking. *Magn. Reson. Med.* 2019; 81:2450–2463.
- [14] Qi H, Jaubert O, Bustin A, Cruz G, Chen H, Botnar R, Prieto C. Free-running 3D whole heart myocardial T1 mapping with isotropic spatial resolution. *Magn. Reson. Med.* 2019; 82:1331–1342.
- [15] Guo R, Cai X, Kucukseymen S, Rodriguez J, Paskavitz A, Pierce P, Goddu B, Nezafat R. Free-breathing whole-heart multi-slice myocardial T1 mapping in 2 minutes. *Magn. Reson. Med.* 2021; 85:89–102.
- [16] Zhou R, Weller DS, Yang Y, Wang J, Jeelani H, MuglerIII JP, Salerno M. Dual-excitation flip-angle simultaneous cine and T1 mapping using spiral acquisition with respiratory and cardiac self-gating. *Magn. Reson. Med.* 2021; 86:82–96.
- [17] Block KT, Uecker M, Frahm J. Model-Based Iterative Reconstruction for Radial Fast Spin-Echo MRI. *IEEE Trans. Med. Imaging* 2009; 28:1759–1769.
- [18] Fessler JA. Model-based image reconstruction for MRI. *IEEE Signal Process. Mag.* 2010; 27:81–89.
- [19] Wang X, Tan Z, Scholand N, Roeloffs V, Uecker M. Physics-based reconstruction methods for magnetic resonance imaging. *Philos. Trans. R. Soc. A* 2021; 379:20200196.

- [20] Zhao B, Lam F, Liang Z. Model-Based MR Parameter Mapping With Sparsity Constraints: Parameter Estimation and Performance Bounds. *IEEE Trans. Med. Imaging* 2014; 33:1832–1844.
- [21] Wang X, Roeloffs V, Klosowski J, Tan Z, Voit D, Uecker M, Frahm J. Model-based T1 mapping with sparsity constraints using single-shot inversion-recovery radial FLASH. *Magn. Reson. Med.* 2018; 79:730–740.
- [22] Maier O, Schoormans J, Schloegl M, Strijkers GJ, Lesch A, Benkert T, Block T, Coolen BF, Bredies K, Stollberger R. Rapid T1 quantification from high resolution 3D data with model-based reconstruction. *Magn. Reson. Med.* 2019; 81:2072–2089.
- [23] Becker KM, SchulzMenger J, Schaeffter T, Kolbitsch C. Simultaneous high-resolution cardiac T1 mapping and cine imaging using model-based iterative image reconstruction. *Magn. Reson. Med.* 2019; 81:1080–1091.
- [24] Wang X, Kohler F, UnterbergBuchwald C, Lotz J, Frahm J, Uecker M. Model-based myocardial T1 mapping with sparsity constraints using single-shot inversion-recovery radial FLASH cardiovascular magnetic resonance. *J. Cardiovasc. Magn. Reson.* 2019; 21:60.
- [25] Rosenzweig S, Scholand N, Holme HCM, Uecker M. Cardiac and Respiratory Self-Gating in Radial MRI using an Adapted Singular Spectrum Analysis (SSA-FARY). *IEEE Trans. Med. Imaging* 2020; 39:3029–3041.
- [26] Wundrak S, Paul J, Ulrici J, Hell E, Geibel MA, Bernhardt P, Rottbauer W, Rasche V. Golden ratio sparse MRI using tiny golden angles. *Magn. Reson. Med.* 2016; 75:2372–2378.
- [27] Wang X, Rosenzweig S, Scholand N, Holme HCM, Uecker M. Model-based Reconstruction for Simultaneous Multi-slice T1 Mapping using Single-shot Inversion-recovery Radial FLASH. *Magn. Reson. Med.* 2021; 85:1258–1271.
- [28] Feng L, Liu F, Soultanidis G, Liu C, Benkert T, Block KT, Fayad ZA, Yang Y. Magnetization-prepared GRASP MRI for rapid 3D T1 mapping and fat/water-separated T1 mapping. *Magn. Reson. Med.* 2021; 86:97–114.
- [29] Look DC, Locker DR. Time saving in measurement of NMR and EPR relaxation times. *Rev. Sci. Instrum.* 1970; 41:250–251.
- [30] Deichmann R, Haase A. Quantification of T1 values by SNAPSHOT-FLASH NMR imaging. *J. Magn. Reson.* (1969) 1992; 96:608–612.
- [31] Larson AC, White RD, Laub G, McVeigh ER, Li D, Simonetti OP. Self-gated cardiac cine MRI. *Magn. Reson. Med.* 2004; 51:93–102.
- [32] Winter P, Kampf T, Helluy X, Gutjahr FT, Meyer CB, Bauer WR, Jakob PM, Herold V. Self-navigation under non-steady-state conditions: Cardiac and respiratory self-gating of inversion recovery snapshot FLASH acquisitions in mice. *Magn. Reson. Med.* 2016; 76:1887–1894.

- [33] Rosenzweig S, Uecker M. Novel insights on SSA-FARY: Amplitude-based respiratory binning in self-gated cardiac MRI. In: Proc. Intl. Soc. Mag. Reson. Med., Virtual, 2021. p. 1956.
- [34] Feng L, Axel L, Chandarana H, Block KT, Sodickson DK, Otazo R. XD-GRASP: Golden-angle radial MRI with reconstruction of extra motion-state dimensions using compressed sensing. *Magn. Reson. Med.* 2016; 75:775–788.
- [35] Uecker M, Hohage T, Block KT, Frahm J. Image reconstruction by regularized nonlinear inversion-joint estimation of coil sensitivities and image content. *Magn. Reson. Med.* 2008; 60:674–682.
- [36] Bakushinsky AB, Kokurin MY, “Iterative Methods for Approximate Solution of Inverse Problems”, Mathematics and Its Applications. Springer Science & Business Media, 2005.
- [37] Boyd S, Parikh N, Chu E, Peleato B, Eckstein J. Distributed Optimization and Statistical Learning via the Alternating Direction Method of Multipliers. *Found. Trends Mach. Learn.* 2011; 3:1–122.
- [38] Roeloffs V, Voit D, Frahm J. Spoiling without additional gradients: Radial FLASH MRI with randomized radiofrequency phases. *Magn. Reson. Med.* 2016; 75:2094–2099.
- [39] Barral JK, Gudmundson E, Stikov N, EtezadiAmoli M, Stoica P, Nishimura DG. A robust methodology for in vivo T1 mapping. *Magn. Reson. Med.* 2010; 64:1057–1067.
- [40] Uecker M, Ong F, Tamir JI, Bahri D, Virtue P, Cheng JY, Zhang T, Lustig M. Berkeley advanced reconstruction toolbox. In: Proc. Intl. Soc. Mag. Reson. Med., Toronto, 2015. p. 2486.
- [41] Rosenzweig S, Holme HCM, Uecker M. Simple auto-calibrated gradient delay estimation from few spokes using Radial Intersections (RING). *Magn. Reson. Med.* 2019; 81:1898–1906.
- [42] Uecker M, Zhang S, Frahm J. Nonlinear inverse reconstruction for real-time MRI of the human heart using undersampled radial FLASH. *Magn. Reson. Med.* 2010; 63:1456–1462.
- [43] Sumpf T, Unterberger M. arrayshow: a guide to an open source matlab tool for complex MRI data analysis. In: Proc. Intl. Soc. Mag. Reson. Med., Salt Lake City, 2013. p. 2719.
- [44] Serry FM, Ma S, Mao X, Han F, Xie Y, Han H, Li D, Christodoulou AG. Dual flip-angle IR-FLASH with spin history mapping for B1+ corrected T1 mapping: Application to T1 cardiovascular magnetic resonance multi-tasking. *Magn. Reson. Med.* 2021; DOI: 10.1002/mrm.28935.

- [45] Cheng JY, Hanneman K, Zhang T, Alley MT, Lai P, Tamir JI, Uecker M, Pauly JM, Lustig M, Vasanawala SS. Comprehensive motion-compensated highly accelerated 4D flow MRI with ferumoxytol enhancement for pediatric congenital heart disease. *J. Magn. Reson. Imaging* 2016; 43:1355–1368.
- [46] Cheng JY, Zhang T, Alley MT, Uecker M, Lustig M, Pauly JM, Vasanawala SS. Comprehensive Multi-Dimensional MRI for the Simultaneous Assessment of Cardiopulmonary Anatomy and Physiology. *Sci. Rep.* 2017; 7:5330.
- [47] Hansen MS, Sørensen TS, Arai AE, Kellman P. Retrospective reconstruction of high temporal resolution cine images from real-time MRI using iterative motion correction. *Magn. Reson. Med.* 2012; 68:741–750.
- [48] Qi H, Fuin N, Cruz G, Pan J, Kuestner T, Bustin A, Botnar RM, Prieto C. Non-rigid respiratory motion estimation of whole-heart coronary MR images using unsupervised deep learning. *IEEE Trans. Med. Imaging* 2020; 40:444–454.
- [49] Backhaus SJ, Lange T, Beuthner BE, Topci R, Wang X, Kowallick JT, Lotz J, Seidler T, Toischer K, Zeisberg EM et al. Real-time cardiovascular magnetic resonance T1 and extracellular volume fraction mapping for tissue characterisation in aortic stenosis. *J. Cardiovasc. Magn. Reson.* 2020; 22:1–10.
- [50] Maier O, Schloegl M, Bredies K, Stollberger R. 3D model-based parameter quantification on resource constrained hardware using double-buffering. In: *Proc. Intl. Soc. Mag. Reson. Med.*, Montréal, 2019. p. 4839.

Figures

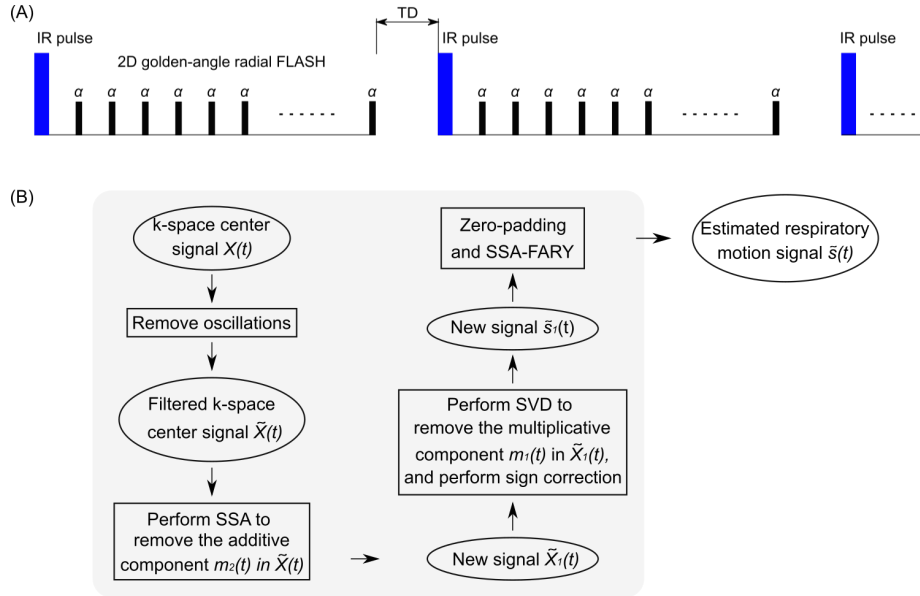


Figure 1: A. Schematic diagram of the free-running inversion-recovery radial FLASH sequence. Note TD is the delay time between inversions and this period encodes pure T_1 information in the data. B. Flowchart of the main steps in the adapted SSA-FARY technique for the respiratory motion signal estimation from the k-space center.

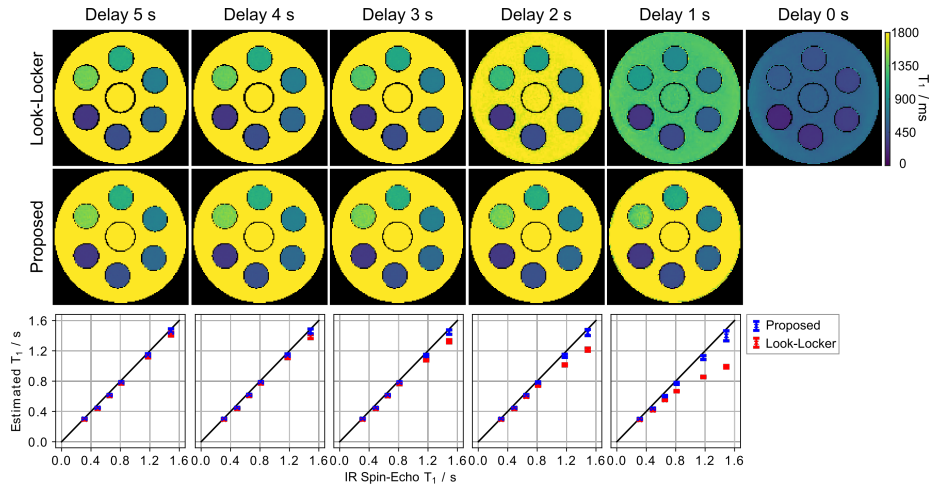


Figure 2: Quantitative phantom T_1 maps with various delay times from 5 s to 1 s (step size 1 s) using (top) the conventional Look-Locker correction and (middle) the proposed formula. (Bottom) Quantitative T_1 values (mean and standard deviation) within ROIs of the 6 phantom tubes in comparison to an IR spin-echo reference.

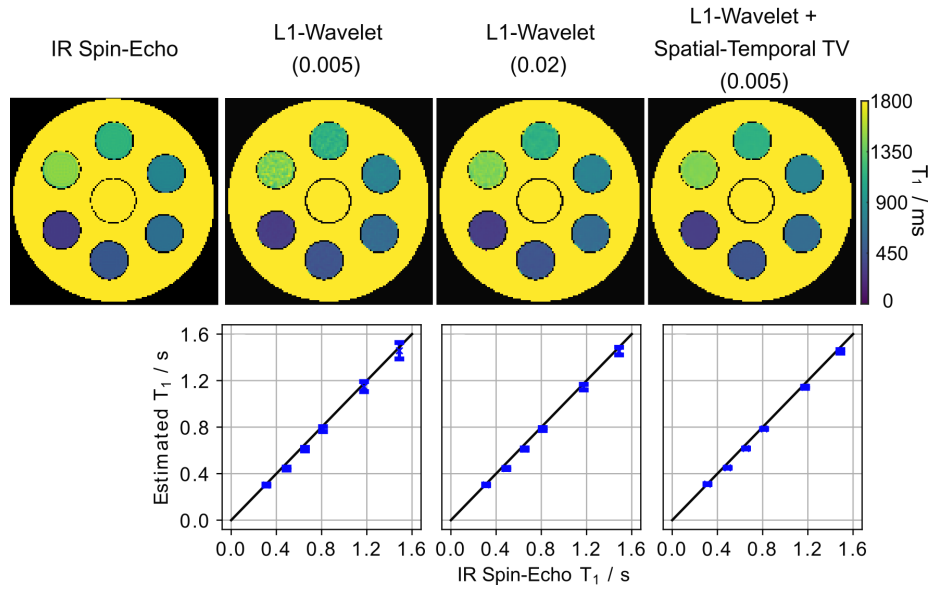


Figure 3: (Top) Phantom T_1 maps reconstructed with different regularization using the motion-resolved model-based reconstruction in comparison to an IR spin-echo reference. (Bottom) Quantitative T_1 values (mean and standard deviation) within ROIs of the 6 phantom tubes. The value in the bracket (top) indicates the regularization parameter α_{\min} used for each reconstruction.

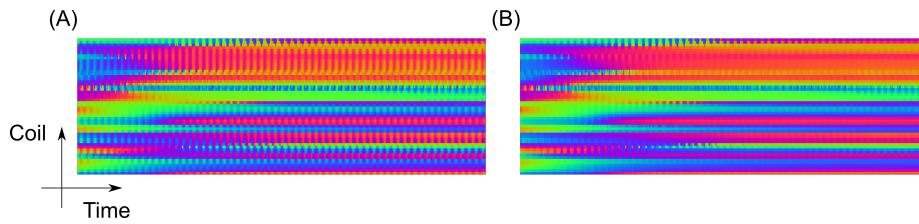


Figure 4: Snippet of the complex plot with color-coded phase of the DC samples used for auto-calibration before (A) and after (B) data correction with the extended orthogonal projection. Notably less disturbing oscillations are observed in B. The above snippet corresponds to one complete inversion recovery (3 s).

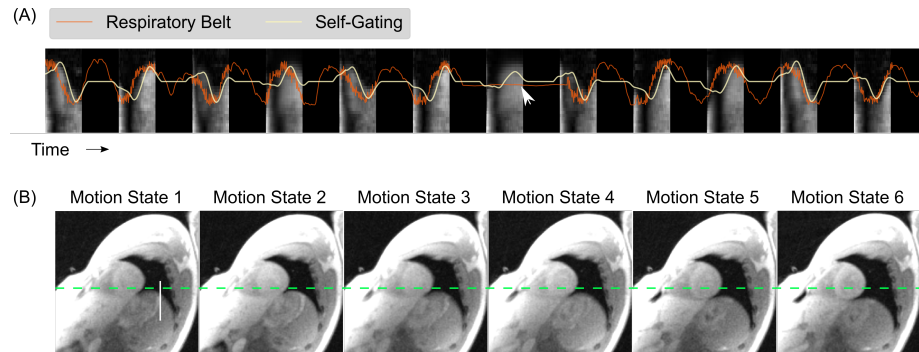


Figure 5: A. Comparison of the estimated respiratory signal with that obtained from the respiratory belt for 12 inversions. The background image represents the temporal evolution of a vertical line profile (white line in B) extracted from a real-time image reconstruction [42] of the data acquired with free-running IR radial FLASH. The dark regions represent the time delay between inversions. The white arrow indicates a time point where the respiration belt failed to provide a signal. B. Steady-state images reconstructed by the non-uniform fast Fourier transform after binning the data into 6 respiratory motion states. The dashed green line serves as a baseline for the end-respiration motion state.

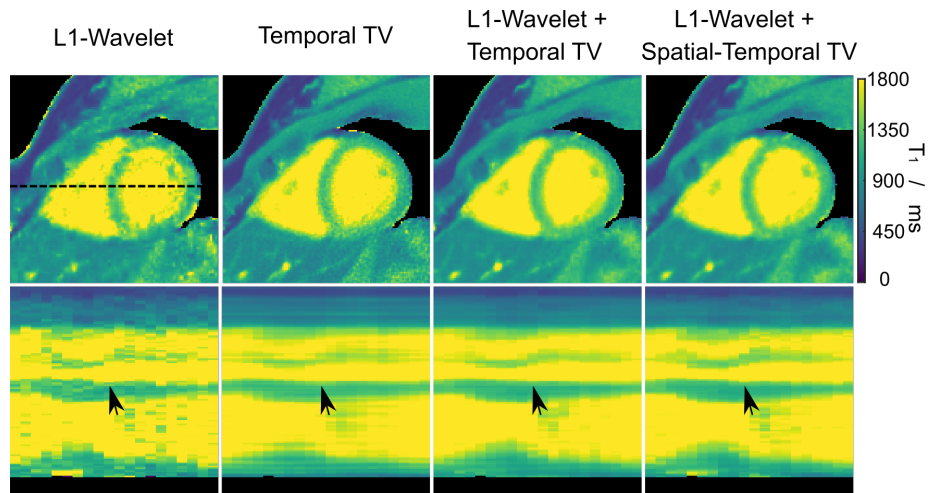


Figure 6: (Top) Myocardial T_1 maps (end-expiration and end-diastolic) with different types of regularization using the proposed motion-resolved model-based reconstruction. (Bottom) Horizontal profiles (dashed black line in the top) through all cardiac phases. The black arrows indicate subtle wall motion that is preserved best with the spatial-temporal TV regularization. Note that the regularization parameter α_{\min} for each regularization type was tuned individually to achieve a fair comparison.

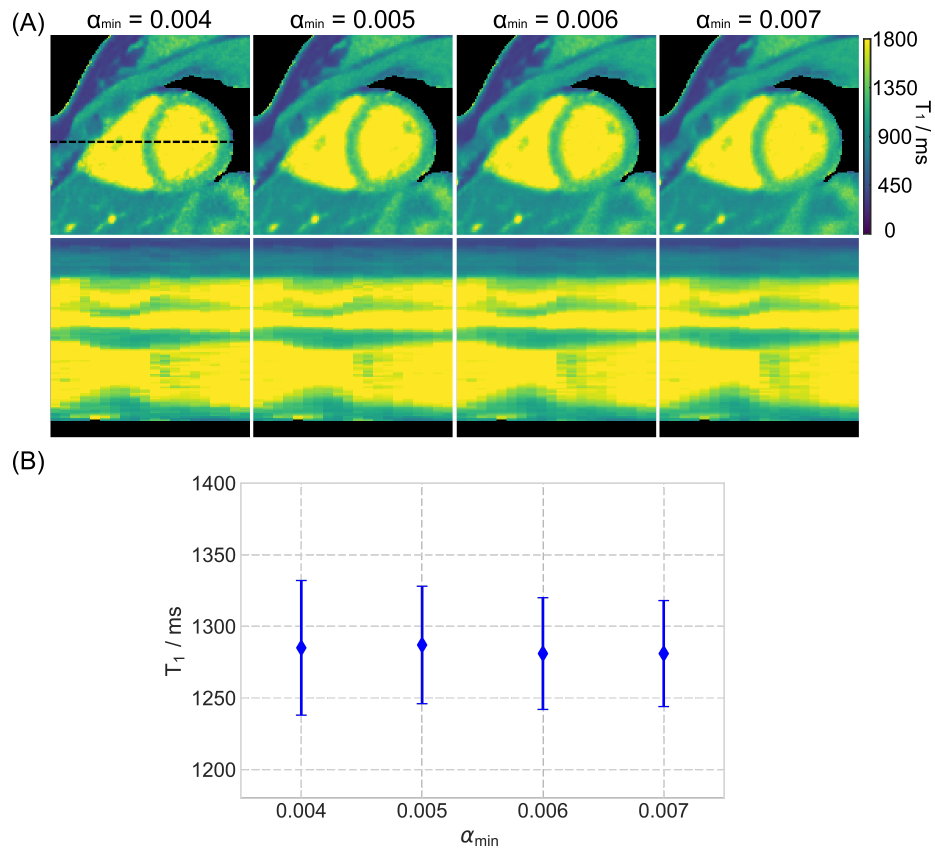


Figure 7: A. (Top) Myocardial T_1 maps (end-expiration and end-diastolic) estimated with motion-resolved model-based reconstruction with different choices of the minimum regularization parameter α_{\min} . (Bottom) Horizontal profiles (dashed black line in the top) through all cardiac phases. B. Quantitative T_1 values (mean and standard deviation) within a ROI in the septal region.

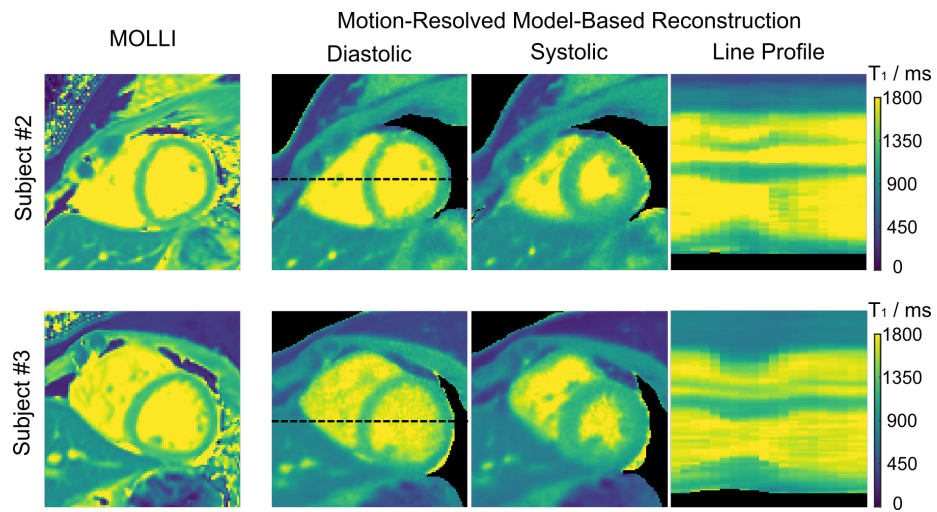


Figure 8: Diastolic and systolic myocardial T_1 maps (end-expiration) and line profiles (dashed black lines) through the cardiac phase of the motion-resolved model-based reconstruction acquired during free breathing in comparison to MOLLI acquired in a breathhold for two representative subjects.

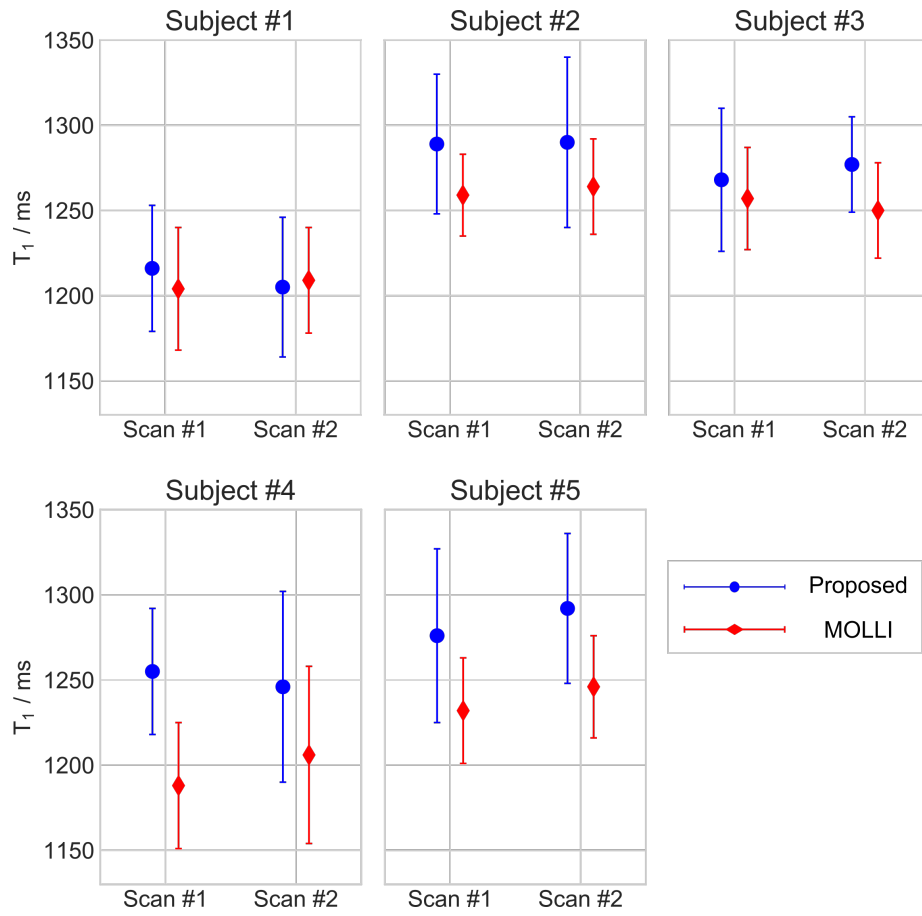


Figure 9: Quantitative septal T_1 values (ms) for the end-expiration and end-diastolic myocardial T_1 maps using the motion-resolved model-based reconstruction in comparison to MOLLI for all five subjects and two repetitive scans.

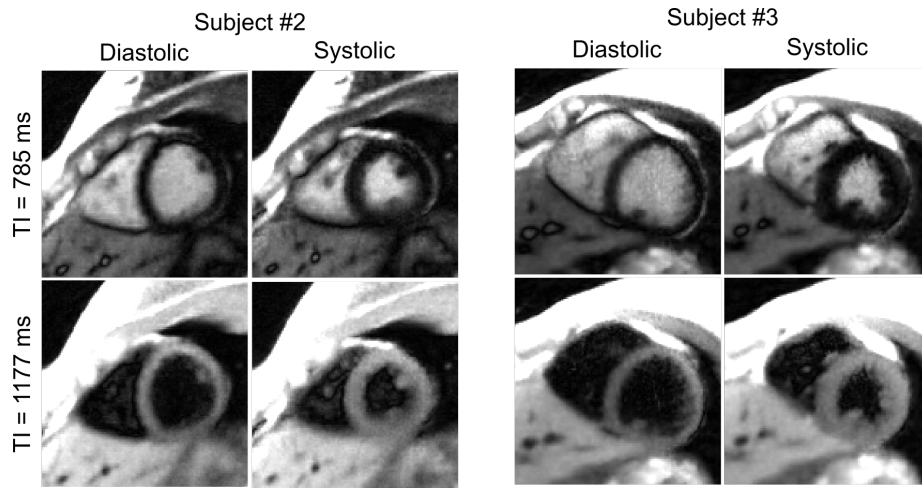


Figure 10: Synthesized T_1 -weighted images at two representative inversion times (bright blood and dark blood) for the end-diastolic and end-systolic cardiac phases for the same subjects shown in Figure 8.

Supporting Information File

1 Derivation of T_1 Estimation Formula From Incomplete (Partial) Recovery

To describe the effect of partial recovery, we split the recovery curve into two parts: The imaging part (subject to R_1^* relaxation) with a time period of t_{1s} and the free recovery part (subject to R_1 relaxation) with a period of t_1 . The dynamics of each part is then governed by:

$$\begin{aligned} \text{Imaging : } & M_{ss} - (M_{ss} - M_{ini}) \cdot e^{-R_1^* \cdot t_{1s}} =: A_1 + B_1 M_{ini} \\ \text{Free relaxation : } & M_0 - (M_0 - M_{ini}) \cdot e^{-R_1 \cdot t_1} =: A_2 + B_2 M_{ini} \end{aligned}$$

where t_{1s} and t_1 are the time periods for imaging and free relaxation parts, respectively.

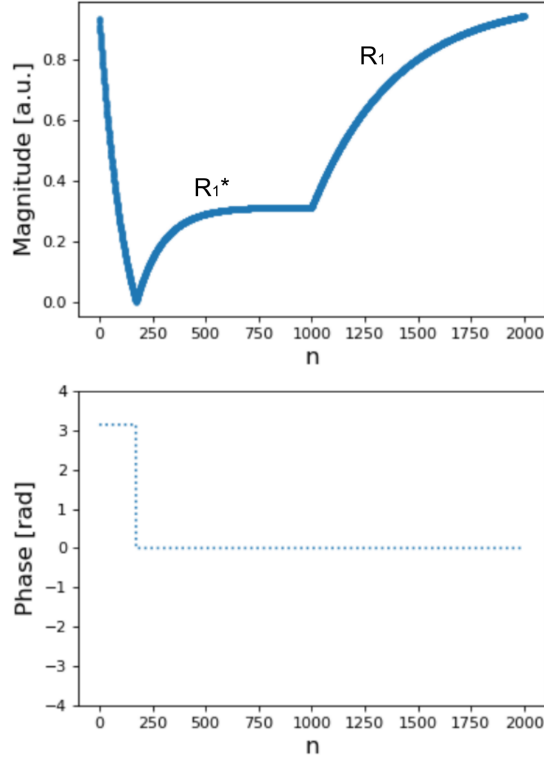


Figure 1: Demonstration of IR look-locker signal with partial recovery: 3 s imaging followed by 3 s free (but incomplete) recovery. n is the index for RF excitation.

The joint effects of these two blocks can then be written as:
 free relaxation after imaging: $A_2 + B_2(A_1 + B_1 M_{ini}) =: A_3 + B_3 M_{ini}$
 where $A_3 = A_2 + B_2 A_1$ and $B_3 = B_2 B_1$

For the new signal model, we simply have to find the fix point which gets mapped to itself by both

relaxation parts and the inversion:

$$\begin{aligned}
M'_0 &= A_3 + B_3 \cdot (-M'_0) \\
\Rightarrow M'_0 &= \frac{A_3}{1 + B_3} \\
&= \frac{A_2 + B_2 A_1}{1 + B_2 B_1} \\
&= \frac{M_0(1 - e^{-R_1 \cdot t_1}) + e^{-R_1 \cdot t_1} M_{ss}(1 - e^{-R_1^* \cdot t_{1s}})}{1 + e^{-R_1 \cdot t_1} \cdot e^{-R_1^* \cdot t_{1s}}}
\end{aligned}$$

By substituting $M_0 = R_1^{-1} M_{ss} R_1^*$, we obtain the formula of equation (1) in the main manuscript.

Therefore, the key idea is that even with partial recovery, the signal is still mono-exponential and can be fitted with a 3-parameter model

$$s(t) = M_{ss} - (M_{ss} + M'_0) \cdot e^{-t \cdot R_1^*}$$

Following parameter estimation, accurate T_1 can be achieved using equation (1) in the main manuscript in a post-processing step.

2 Study of High-Dimensional Regularization on Simulated Dynamic Phantoms

To study the effects of various regularization types (explained in the Iterative Reconstruction part of the Methods section) in the motion-resolved reconstruction in general, a numerical motion phantom consisting of three elliptical objects was simulated. The diameters of the centered two objects were designed to change along time, mimicking the cardiac contraction motion, moving from diastolic to systolic phase. The corresponding k-space data was then derived from the analytical Fourier representation of ellipses assuming an array of eight circular receiver coils surrounding the phantom without overlap. The simulation employed a continuous radial FLASH acquisition with a tiny golden-angle ($\approx 23, 63^\circ$) between successive spokes, base resolution of 256 pixels covering a field of view of 192 mm, 15 spokes per frame and a total of 32 time frames.

The effects of different regularizations were tested on the simulated dynamic phantom using motion-resolved image reconstruction ("PICS" command) in BART. The Supporting Information Figure S1 presents such a comparison where all reconstructions have employed the same regularization parameter. Certain streaking artifacts appear in the images when only the ℓ_1 -Wavelet-based spatial regularization is applied. Such artifacts can be largely removed with the use of temporal TV regularization. However, the pure TV regularization also introduced the "line"-like artifacts along the time dimension, as shown in the line profile images. The joint ℓ_1 -Wavelet and temporal TV regularization helps to reduce such artifacts but still has some "line"-like artifacts presented in the line profiles. The spatial-temporal TV regularization, which takes account of both spatial and temporal information into the TV regularization, plus the ℓ_1 -Wavelet spatial regularization largely eliminate all the above artifacts, resulting in both smooth images and line profiles.

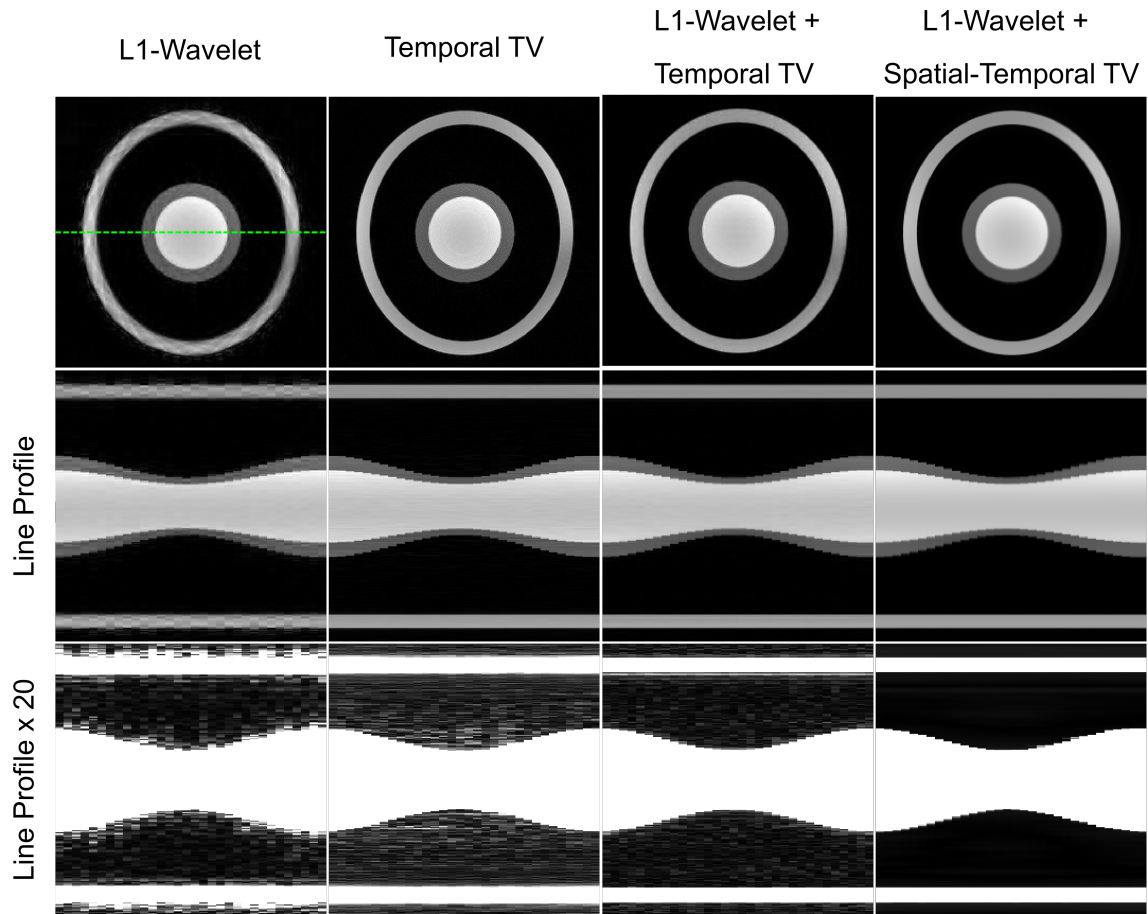


Figure 2: **Supporting Information Figure S1.** (Top) One of the "end-diastolic" images (28th of 32) of a simulated dynamic image series and (middle and bottom) the corresponding horizontal profiles (dashed green line in the top) through the motion dimension. The image series were reconstructed using the the motion-resolved image reconstruction with different regularization type.

3 Supporting Information for In Vivo Studies

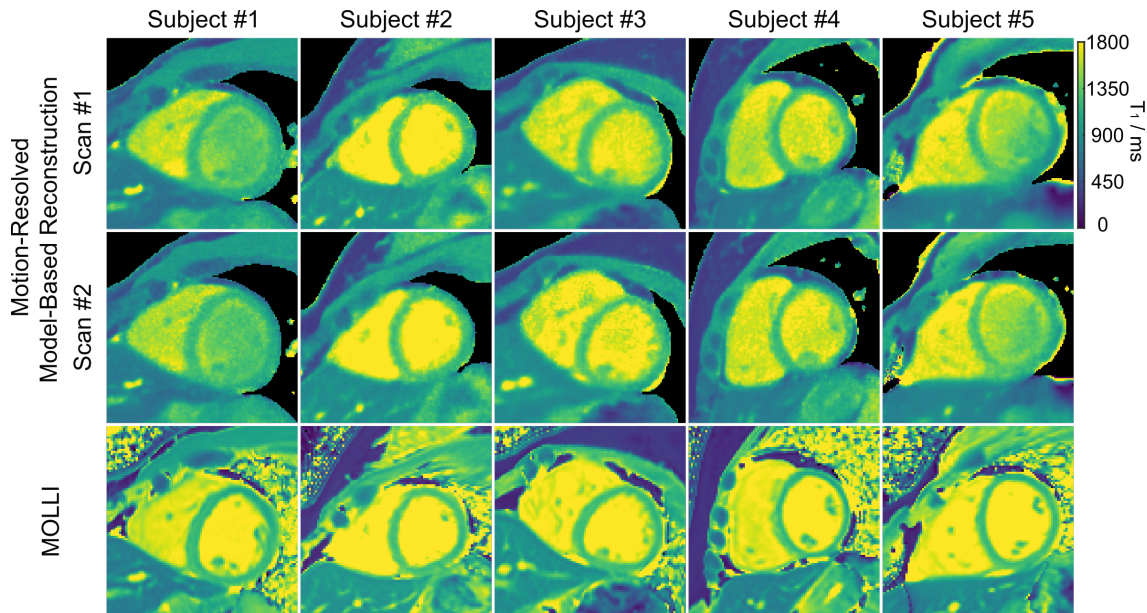


Figure 3: **Supporting Information Figure S2.** Two repeated myocardial T_1 maps (end-expiration, end-diastolic) of the motion-resolved model-based reconstruction acquired during free breathing in comparison to MOLLI acquired in a breathhold for five subjects.

Table 1: **Supporting Information Table S1.** Quantitative septal T_1 values (mean \pm standard deviation, ms) using the Look-Locker correction and the proposed correction, and their comparison to MOLLI for all subjects and scans.

	Subject #1		Subject #2		Subject #3		Subject #4		Subject #5	
	Scan #1	Scan #2	Scan #1	Scan #2	Scan #1	Scan #2	Scan #1	Scan #2	Scan #1	Scan #2
Look-Locker	1191 \pm 33	1181 \pm 38	1257 \pm 34	1258 \pm 41	1230 \pm 36	1252 \pm 24	1205 \pm 30	1212 \pm 37	1255 \pm 41	1265 \pm 34
Proposed	1216 \pm 37	1205 \pm 41	1289 \pm 41	1290 \pm 50	1268 \pm 42	1277 \pm 28	1224 \pm 35	1230 \pm 42	1276 \pm 51	1292 \pm 44
MOLLI	1204 \pm 36	1209 \pm 31	1259 \pm 24	1264 \pm 28	1250 \pm 28	1257 \pm 30	1188 \pm 37	1175 \pm 52	1232 \pm 31	1246 \pm 30

Supporting Information Video S1. Synthesized T_1 -weighted image series (bright blood and dark blood) and the corresponding myocardial T_1 maps through the cardiac phase dimension for subject #2.

Supporting Information Video S2. Synthesized T_1 -weighted image series (bright blood and dark blood) and the corresponding myocardial T_1 maps through the cardiac phase dimension for subject #3.

Supporting Information Video S3. Synthesized T_1 -weighted image series at temporal resolution of 49 ms for all inversion times and all cardiac phases of subject #2.