

Deep Learning Based Computer-Aided Systems for Breast Cancer Imaging : A Critical Review

Yuliana Jiménez-Gaona^{a,b,c*}, María José Rodríguez-Álvarez^b, Vasudevan Lakshminarayanan^{c,d}

^aDepartment of Chemical and Exact Sciences, Physicochemistry and Mathematics Section, Universidad Técnica Particular de Loja, Ecuador. ^bInstituto de Instrumentacion para la Imagen Molecular I3M, Universitat Politècnica de Valencia, Spain ^cTheoretical and Experimental Epistemology Lab, School of Optometry and Vision Science, University of Waterloo, Ontario, Canada ^dDepartment of Systems Design Engineering, Physics, and Electrical and Computer Engineering, University of Waterloo, Ontario, Canada
ydjimenez@utpl.edu.ec, mjrodri@i3m.upv.es, vengulak@uwaterloo.ca

*Corresponding author at: Department of Chemical and Exact Sciences. Universidad Técnica Particular de Loja, Ap. 11-01-608, Loja- Ecuador. *E-mail address:* ydjimenez@utpl.edu.ec

Abstract

This paper provides a critical review of the literature on deep learning applications in breast tumor diagnosis using ultrasound and mammography images. It also summarizes recent advances in computer-aided diagnosis (CAD) systems, which make use of new deep learning methods to automatically recognize images and improve the accuracy of diagnosis made by radiologists. This review is based upon published literature in the past decade (January 2010 - January 2020). The main findings in the classification process reveal that new DL-CAD methods are useful and effective screening tools for breast cancer, thus reducing the need for manual feature extraction. The breast tumor research community can utilize this survey as a basis for their current and future studies.

Key words

breast cancer, Computer Aided Diagnosis (CAD), deep learning, mammography, ultrasound, convolutional neural networks,

1. Introduction

Due to the anatomy of the human body, women are more vulnerable to breast cancer than men. Breast cancer is one of the leading causes of death for women globally [1-4] and is a significant public health problem. It occurs due to the uncontrolled growth of breast cells. These cells usually form tumors that can be seen from the breast area via different imaging modalities.

To understand breast cancer, some basic knowledge about the normal structure of the breast is important. Women's breasts are constructed by lobules, ducts, nipples, and fatty tissues (**Fig 1**) [5]. Normally, epithelial tumors grow inside the lobes, as well as in the ducts, and later form a lump [6] generating breast cancer.

Breast abnormalities that can indicate breast cancer are masses and calcifications [7]. Masses are benign or malignant lumps and can be described by their shape (round, lobular, oval, and irregular) or their margin (obscured, indistinct, and spiculated) characteristics. The spiculated masses are the particular kind of masses that have high

probability of malignancy. A spiculated mass is a lump of tissue with spikes or points on the surface. It is suggestive but not diagnostic of malignancy. It's a common mammography finding in the carcinoma breast [8].

On the other hand, microcalcifications are small granular deposits of calcium and may show up in clusters or patterns (like circles or lines) and appear as bright spots in a mammogram. Benign calcifications are usually larger and coarser with round and smooth contours. Malignant calcifications tend to be numerous, clustered, small, varying in size and shape, angular, irregularly shaped, and branching in orientation [7, 9].

Breast cancer screening aims to detect benign or malignant tumors before the symptoms appear, and hence reduce mortality through early intervention [2]. Currently, there are different screening methods such as mammography [10], magnetic resonance imaging (MRI) [11], ultrasound (US) [12], and computed tomography (CT) [13]. That helps to visualize hidden diagnostic features. Out of these modalities, ultrasound and mammograms are the most common screening methods for detecting tumors before they become palpable and invasive [2,14,15,16]. Also, they may be utilized effectively to reduce unnecessary biopsies [17]. These two are the modalities that are reviewed in this article.

A drawback in mammography is that the results depend upon the lesion type, the age of the patient, and the breast density [18-24]. In particular dense breasts that are “radiographically” hard to see exhibit low contrast among the cancerous lesions and the background [25, 26].

Due to limitations of this modality such as low sensitivity especially in dense breasts, other modalities are used also, e.g., US [12]. The US is a non-invasive, non-radioactive, real-time imaging, and provides high image resolution images [27]. However, all these techniques are operator-dependent, and the interpretation of the images requires expertise in radiology. Normally, the radiologists try to do a manual interpretation of the medical image by double mammogram reading to enhance the accuracy of the results [28]. But it is time-consuming and is highly prone to mistakes [3, 29].

Because of these limitations, different artificial intelligence algorithms are gaining attention, due to their excellent performance in image-recognition tasks. Different breast image classification methods have been used to assist doctors in reading and interpreting medical images, such as Machine learning (ML), Deep learning (DL), and Computer-aided diagnosis/detection (CAD) systems [8, 30-32]. The CAD goal is to increase the accuracy of breast cancer detection rates by increasing sensitivity, which will support radiologists in their diagnosis decisions [33-35]. Recently, Gao et al., [36] developed a CAD system for screening mammography readings demonstrating about 92% accuracy in the classification. Likewise, other studies [37, 38] used convolutional neural networks (CNN) for mass detection in mammography and ultrasounds [39-41].

In general, the DL-CAD system (DL-CAD) focuses on CNNs which is the most popular model used for intelligent image analysis and for detecting cancer provide good performance [42-44]. With CNNs, it is possible to automate the feature extraction process as an internal part of the network [40], thus minimizing human interference

[36]. DL-CAD systems have added broader meaning with this approach, distinguishing it from traditional CAD methods [36].

The next-generation technologies based on the DL-CAD system solve problems that are hard to solve with traditional CAD [45]. These problems including learning from complex data [46], image recognition [47], medical diagnosis [48,49], image enhancement [50]. In using such techniques, the analysis images include preprocessing, segmentation (selection of Region of Interest -ROI), feature extraction, selection, and classification.

In this review, we summarize recent advancements and developments in new DL-CAD systems for breast cancer detection/ diagnosis using mammograms and ultrasound imaging and then describe the principal findings in the classification process. The following research questions were used as the guidelines for this article:

- ¿How the new DL-CAD systems provide breast imaging classification-related concerning the traditional CAD system?
- ¿Which artificial neural networks inside the DL-CAD systems give better performance in breast tumor classification?
- ¿What are the main DL-CAD architectures used for breast tumor diagnosis/detection?
- ¿What are the performance metrics used for evaluating DL-CAD systems?

2.Methodology

2.1 Flowchart of the review

The systematic review process is following the flow diagram and protocol (Fig 2) given in [51].

We identified appropriate studies in PubMed, Medline, Google Scholar, and Web of Science databases; as well as conference proceedings for IEEE, MICCAI, and SPIE published between January 2010 and January 2020. The search was designed to identify all studies in which Digital Mammography (DM) and the US were evaluated as a primary detection modality for breast cancer, and were both used for screening and diagnosis. A comprehensive search strategy included free text and MeSH terms, such as: “breast cancer,” “breast tumor,” “breast ultrasound,” “breast diagnostic,” “diagnostic imaging,” “deep learning,” “CAD system,” “convolutional neural network,” “computer-aided detection,” “computer-aided diagnoses,” “digital databases,” “mammography,” “mammary ultrasound,” “radiology information” and “screening” was utilized.

2.1.1 Inclusion criteria

Articles were included if they assessed Computer-Aided Diagnosis (CADx) or Detection (CADE) for breast cancer, DL in breast imaging, Deep convolutional neural networks (CNNs), DL in mass segmentation and classification in both DM and US, Deep Neural Network architecture, transfer learning and feature-based method in the automated mammography breast density. From a review of the abstracts, we manually selected the relevant papers.

2.1.2 Exclusion criteria

Articles were excluded if the study population included other screening methods such as MRI, CT, PET (positron emission tomography), or if other machine learning techniques were used.

2.2 Study Design

There are four sections in the design diagram (**Fig 3**). Firstly, different mammography and ultrasound public digital databases were analyzed as input data of the DL-CAD system. The second section includes the preprocessing and postprocessing in the traditional and next-generation DL-CAD.

In the third part, full articles were analyzed to compile the successful CNNs used in DL architectures. Furthermore, the best evaluation metrics were analyzed to measure the accuracy of these algorithms. Finally, a discussion and conclusions about these classifiers are presented.

2.2.1 Public Databases

Normally, the DL models are tested using private clinical images or public available digital databases, used by researchers in the breast cancer area. Public medical images are increasing because most of the DL-CAD systems require a large amount of data. Thus, DL algorithms are applied on available digitized mammograms such as MIAS (Mammographic Image Analysis Society Digital Mammogram Database) [52], DDSM (Digital Database for Screening Mammography), IRMA (Image Retrieval In Medical Application) [53, 54] INbreast [55] and BCDR (Breast Cancer Digital Repository) [36, 56] as well as ultrasound (US) public databases BUSI (Breast Ultrasound Image dataset), DDBUI (Digital database for breast ultrasound image), OASBUD (Open Access Series of Breast Ultrasonic Data) from Oncology Institute in Warsaw-Poland and the private US collected datasets SNUH (Seoul National University Hospital, Korean) [40], Dataset A (collected in 2001 from a professional didactic media file for breast imaging specialists) [57] and Dataset B (collected from the UDIAT Diagnostic Centre of the Parc Taulí Corporation, Sabadell- Spain). These widely used datasets are listed in **Table 1**.

2.2.2 DL-CAD focused on DM and US

The CAD systems are divided into two categories. One is the traditional CAD system and the other is the DL-CAD system. In traditional CAD system, the radiologist or clinician defines features in the image, and there can be problems in recognizing the shape and density information of the cancerous area. DL-CAD systems on the other hand create such features by itself through the learning process [67].

Further, CAD systems can be broken down into two main groups: computer-aided detection (CADe) and computer-aided diagnosis (CADx). The main difference between CADe and CADx is that the first refers to a software tool that assists in ROI segmentation within an image [68], identifying possible abnormalities and leaving the interpretation to the radiologist [8]. On the other hand, CADx serves as a decision aid for radiologists to characterize findings from medical images identified by either a radiologist or a CADe system.

2.2.3 Preprocessing

It is known that the database characteristics can affect significantly the performance of a CAD scheme, or even of a particular processing technique. Also, it can develop a scheme yielding erroneous or confusing results [69] since radiological images contain noise, artifacts, and other factors that can affect medical and computer interpretations. Thus, the first step in preprocessing is to improve image quality, contrast, and removal noises.

2.2.3.1 Image Enhancement

The main purpose of image preprocessing is to enhance the image and suppress noise while preserving important diagnostic features [70, 71]. Preprocessing in breast cancer also consists of delineation of tumors from the background, breast border extraction, and pectoral muscle suppression. The pectoral muscles are a challenge in mammogram image analysis depending on the standard view used during mammography. Generally, mediolateral oblique (MLO) and craniocaudal (CC) views are used [72].

As noted, DM includes many sources of noise, which are classified as a high-intensity rectangular label, low-intensity label, and tape artifacts. The principal noise models observed in mammography are Salt and pepper, Gaussian, Speckle, and Poisson noise.

In the same way, US images suffer from noise such as intensity inhomogeneity, low signal-to-noise ratio, high speckle noise [78, 79], blurry boundaries, shadow, attenuation, speckle interference, and low contrast. Speckle noise reduction techniques are categorized in filtering, wavelet, and compound methods [12].

Thus, many traditional filters can be applied for removal noise, including Wavelet transform, Median filter, Mean filter, Adaptive median filter, Gaussian filter, and Adaptive Wiener filter [3,73-77]. Also, different traditional methods: Histogram equalization (HE) [151,152], Adaptive Histogram Equalization (AHE)[153] and Contrast limited adaptive Histogram Equalization (CLAHE) [154] can be used to enhance the image.

Actually, Deep-CNNs [155] are gaining attention for improving the super resolution image (SRCNN): Multi-image super-resolution, Example-based super-resolution and (iii) Single-image super-resolution [161-162]. Among the most used algorithms for generating high-resolution (HR) imaging [156,157] are: nearest-neighbor interpolation [158], bilinear interpolation [159], bicubic interpolation [160].

2.2.3.2 Image Augmentation

Deep CNN depends on large datasets to avoid overfitting and is necessary for good DL model performance [80]. Thus, limited datasets are a major challenge in medical image analysis [81], and it is necessary to implement data augmentation techniques. There are two common techniques for increasing the data in DL, data augmentation and transfer learning/fine-tuning [82, 83]. As an example, a DL model that has been trained with data augmentation is Imagenet [67]. Another effective example of transfer learning can be found in Huynh et al. [38].

The image augmentation algorithms include basic image manipulations (flipping, rotations, geometric transformations, color space augmentations, kernel, mixing images, random erasing [84]) and DL (feature space augmentation, adversarial training, generative adversarial networks (GAN) [85], neural style transfer [86] and meta-learning [81]). These techniques increase the amount of data by pre-processing input image data by operations such as rotation, contrast enhancement, and noise addition and has been implemented by many studies [189-196].

2.2.3.3 Image Segmentation

Its processing step plays an important role in image classification. Segmentation is the separation of ROI (pectoral muscle [87], lesions, masses, microcalcifications) from the background of the image. In the case of cancerous images, we need the lesion part and from it extracts its features.

In traditional CAD systems, the tasks of specifying ROI such as an initial boundary or lesions, are accomplished with the expertise of radiologists. The traditional segmentation task in DM can be divided into four main classes: (i) threshold-based segmentation; (ii) region-based segmentation; (iii) pixel-based segmentation; and (iv) model-based segmentation [3,72]. Otherwise, US image segmentation includes several techniques: threshold-based, region-based, edge-based, water-based, active contour and neural network learning- based techniques [89, 90].

The accuracy of segmentation affects the results of CAD systems because numerous features are used for distinguishing malignant and benign tumors (texture, contour, and shape of lesions). Thus, the features may only be effectively extracted if the segmentation of tumors is performed with great accuracy [70, 88]. That is why, researchers are using DL methods especially CNNs, because its methods have excellent results on segmentation task. Also, DL-CAD systems are independent of human involvement and are capable of modeling breast US and DM knowledge using constraints autonomously. Two strategies have been utilized to use full image size for training CNN on DM and US instead of ROIs. 1) High resolution[182] images and 2) patch-level [183]. As for example recent network architectures used as a segmentator region are YOLO [163], SegNet[164], UNet[165-166], GAN[180] and ERFNet[181].

2.2.4 Post -Processing

2.2.4.1 Image feature extraction and selection

After segmentation, feature extraction and selection are the next steps to remove the irrelevant and redundant information of the data being processed. Features are characteristics of the ROI taken from the shape and margin of lesions, masses, and calcifications. These features can be categorized into texture and morphologic features [12, 91], descriptor, and model-based features [92], and help to discriminate benign and malignant lesions. Most of the texture features are calculated from the entire image or ROIs using the gray level value and the morphologic features focus on some local characteristics of the lesion.

The high numbers of features increase the computational cost and slow down the classification process. Feature selection techniques reduce the number of feature space

for developing process accuracy and minimizing computation time by eliminating redundant, irrelevant, and noisy features [93].

There are some traditional techniques used for feature selection like searching algorithms, chi-square test, gain ratio, information gain, recursive feature elimination, and random forest [94]. In addition, other traditional techniques used for the feature extraction include principal component analysis (PCA), wavelet packet transform (WPT) [95, 96], grey level co-occurrence matrix (GLCM) [97], Fourier power spectrum (FPS) [98], Gaussian derivative kernels [99], and decision boundary features [100].

However, in some advanced classification methods, such as an artificial neural network (ANN) and support vector machine (SVM), the dimension of feature vectors not only highly affect the performance of the classification but also determines the training time of the algorithm [91]. Thus, DL models produce a set of transformation functions and image features directly from the data [92], whose main advantage is to carry the burden of designing the specific features and the classification. Extracting useful features and make a good selection of the features is a crucial task for DL-CAD systems. As for example some CNNs capable of to extract features have been presented by different authors [184-188].

2.2.5 Classification

After the features have been extracted and selected, they are input into a classifier to categorize the ROI into malignant and benign classes. The commonly used classifiers include linear, ANN, Bayesian neural networks, Decision tree, SVM, Template matching [70] and CNNs.

Recently, the deep CNNs, which are hierarchical architectures trained on large-scale datasets, have shown stunning performance in object recognition and detection [101], which suggests that these could also improve breast lesion detection in both US and DM methods. Some researchers are interested in lesion [178,196-198], microcalcifications [199-200] and masses [201-202] classification in DM and US [64, 120-124, 170,173,175] based on CNN models.

2.2.5.1 Deep Learning Models

DL in medical imaging is mostly represented by a basic structure called CNNs [64, 102]. There are different DL techniques such as Generative Adversarial Models (GANs), Deep Autoencoders (DANs), Restricted Boltzmann Machine (RBM), Stacked Autoencoders (SAE), Convolutional Autoencoders (CAE), Recurrent Neural Networks (RNNs), Long Short-term Memory (LSTM), Multi-scale Convolutional Neural Network (M-CNN), multi-instance learning convolutional neural network (MIL-CNN) [3]. DL techniques have been implemented to train neural networks in breast lesions detection, include an ensemble of CNN [68] and transfer learning [68, 83, 101, 103]. The ensemble method combines multiple models to get a better and more comprehensive generalized model [104], and transfer learning is an effective method to deal with relatively small datasets as in the case of medical images.

ANNs are composed of an input and output layer, plus one or more hidden layers as shown in **Fig 4**. In the field of breast cancer, three types of ANN are frequently used: Back-propagation neural network, Self-organizing map (SOM), and hierarchical ANNs.

To train an ANN with a back-propagation algorithm the flow in the forward direction is used. Then, the generated output is matched with the desired output and the error signal is generated in the case the outputs do not match. This error propagates in the backward direction, and weights are adjusted for error reduction. This processing is repeated until the error becomes zero or is a minimum [105].

2.2.5.2 Convolutional Neural Networks

Convolutional neural networks (CNN) are the most widely used when it comes to DL and medical image analysis. The CNN structure has three types of layers, convolution, pooling, and full connection layer, stacked in multiple layers [67]. Thus, CNNs structure is determined by different parameters such as number of hidden layers, learning rate, activation function (RELU), pooling layer for feature map extraction, loss function (Softmax) and the fully connected layers for classification. As shown in **Fig 5**.

2.2.5.2.1 CNN architectures

The model's performance depends on the architecture and the size of the data. There are different CNN architectures that have been proposed: AlexNet [106], VGG-16 [107], ResNet [108], Inception (GoogleNet) [109] and DenseNet [110]. They are briefly described in **Table 2**. These networks have shown promising performance in recent work for image classification.

Also, there are some techniques for improving the CNNs performance such as Dropout, Batch normalization and Cross-validation. Dropout is a regularization method to prevent a CNN model from overfitting. Batch normalization layer speeds up training of CNNs and reduce the sensitivity to network initialization and Cross-validation is a statistical technique to evaluate predictive models by partitioning the original samples into a training, validation and testing sets. There are three types of validation: 1. Hold-out splits (training 80% and testing 20%) 2. Three-way data splits (training 60%, validation 20% and testing 20%) and 3. K-fold cross-validation (3-5 k-fold for large data set; 10 k-fold for small dataset), where data is split into k different subsets depending on their size [176].

2.2.6 Evaluation Metrics

Different quantitative metrics are used to evaluate the classifier performance of a DL-CAD system. These include accuracy (Acc), sensitivity (Sen), specificity (Spe), the area under the curve (AUC), F1 score and confusion matrix (**Table 3 and Table 4**) that are shown for different architectures used in breast cancer (**Table 5** for DM and **Table 6** for the US) [39, 125].

The Receiver Operating Characteristic Curve (ROC): The ROC curve is a graph of operating points, which can be considered as a plotting of the true positive rate (TPR) versus a false-positive rate (FPR), derived from AUC. The TPR and the FPR are also called sensitivity (recall) and specificity, respectively. As defined in **Fig 6**.

AUC: Provides the area under the ROC-curve and a perfect score has a range from 0.5 to 1. It gives the aggregate measure of all possible classification thresholds. A 100% correct classified version will have the AUC value 1 and it will be 0 if there is a 100% wrong classification [126].

Accuracy: It indicator determines how many *TP*, *TN*, *FP*, and *FN* were correctly classified. In detail, Acc is the proportion of cases correctly classified into the benign or malignant state. Thus, TP: when a positive sample is classified correctly; FP: when a positive sample is classified incorrectly; TN: when a negative sample is classified correctly; FN: when a negative sample is classified incorrectly [68]

Sensitivity or TPR: Is the correct identification of true positive benign cases.

Specificity or TNR: Is the correct identification of true negative cases.

Additionally, some other frequently used statistical performance evaluation measures.

Precision: how precise is the model based on the true positive predicted correctly from the predicted ones.

F1 score: is the harmonic mean of the precision and recall, and;

Matthew's correlation coefficient (MCC): are also calculated to provide an efficient assessment of a classifier. Statistical equations are shown in **table 4**.

3. Discussion and Conclusions

Considering that the breast tumor screening using DM has some consequences (higher number of unnecessary biopsies and ionizing radiation exposure endangers the patient's health [12]) and limitations (low specificity, high FP results, which imply higher recall rates and higher FN results [132]) the US is used as the second choice for DM. Thus, US imaging is one of the most effective tools in breast cancer detection, because it has been shown to achieve high accuracy in mass detection, classification [133], and diagnosis of abnormalities in dense breasts [12].

For the aboved mentioned reasons, we have considered addressed this review using the both kind of images (DM and US), focus on different DL architectures applied in breast tumor processing. Offering a general overview of CNNs, including their relation and efficacy in performing segmentation, feature extraction, selection and classification tasks [134].

Thus, in **Table 2** various DL architectures and their training strategies for detection and classification tasks have been discussed. Based on the most popular datasets, CNN seems to perform rather well as demonstrated by Samala et al. [113], Cao et al., Chiao et al., and Yap et al. [63, 120, 121]. Also, the studies [111-121] used several preprocessing and processing techniques for high resolution [203], data augmentation, segmentation and classification. According to the most commonly CNNs used are AlexNet, VGG, ResNet, DenseNet, Inception (GoogleNet), LeNet and UNet, which employ recently python libraries for implementing CNNs such us Tensorflow, Caffe and Keras with diferente hyper-parameters to training the network [176].

Most of these network architectures use a large data set, thus it is required to apply an augmentation technique to avoid overfitting and to have better performance in classification. In this sense the researchers mentioned in Table 2 [167,170] used transfer learning and esemble methods as data augmentation to improving the performance of

the CNN network, reaching 89.86% of accuracy and 0.9578% of AUC in DM, and AUC of 0.68% in US images. Furthermore, Singh, V. K. et al. [173] shows that the results obtained with GAN for breast tumor segmentation outperform the UNet model, and the SegNet and ERFNet models yield the worst segmentation results on BUS images.

In addition, according to Cheng J. et al. [175] the DL techniques could potentially change the design paradigm of the CADx systems for several profits over the traditional CAD. The profits are: First, DL can directly extract features from the training data. Second, the feature selection process will be significantly simplified. Third, the three steps of feature extraction, selection and classification can be realized within the optimization of the same deep architecture. Thus, SDAE architecture can potentially address the issues of high variation in either shape or appearance of lesions/tumors. Besides, the studies [176-179] show that CNN methods can compare images from CC and MLO views and can improve the accuracy of detection and reduce the FPR.

Besides, different evaluation metrics are described in Tables 3 and 4 as performance corroboration of these techniques. As a result, Tables 5 and 6 describe different research where their authors have used a variety of datasets (**Table 1**), approaches, and performance metrics to evaluate CNN techniques in DM and US imaging. For example, better results were achieved in DM analysis by Al-Masni [127] with YOLO5 using DDSM data augmentation, Chougrad et al. [129] used Deep CNN (Inception V3) with DDSM and MIAS datasets. On the other hand, Kyung et al [86] introduced a DenseNet model to analyze private (BUSI and SNUH) US datasets. Byra et al. [130] achieve high accuracy with the VGG19 Deep CNN model using the ImageNet database. Similarly, Cao et al [120] attained accuracy the 96.89% with SSD+ZFNet and Han et al. [53] with GoogleNet reached 91.23% using a private dataset.

Thus, according to the Springer (<http://www.springer.com>), Elsevier (<https://www.elsevier.com>), and IEEE (<http://www.ieeexplore.ieee.org>) web sites, researchers have mostly utilized the MIAS and DDSM databases for the breast image classification research. The number of conference papers published for the DDSM and MIAS databases is 110 and 168, respectively, with 82 journal papers published on DDSM databases and 136 journal papers published using the MIAS database [5]. Some details about the strengths and limitations of these databases are discussed in Abdelhafiz, D. [176].

Furthermore, **Table 7** gives a brief overview of the new DL-CAD system approach and traditional methods for CAD diagnosis. Even though Deheeba et al. [135] present a good traditional wavelet neural network CAD system with high accuracy (93.67%), Debelee et al. [136] exceed this percentage using CNN + SVM DL-CAD system in DDSM (99%) and MIAS (97.18%) datasets. These works demonstrate that in most of the cases DL architectures outperformed traditional methodologies.

To conclude, the use of DL could be a promising new technique to obtain the main features for automatic breast tumor classification especially in dense breasts. Also, in medical image analysis using DL has proven to be better for researchers compared to conventional ML approach [149, 150]. It appears as though DL provides a mechanism to extract features automatically through a self-learning network, thus boosting classification accuracy. However, there is a continuing need for better architectures,

more extensive datasets that overcome class imbalance problems and better optimization methods.

Acknowledgments: VL would like to acknowledge support by a Discovery grant from the Natural Sciences and Engineering Research Council of Canada.

References

- [1] LA. Torre, F. Bray, R.L. Siegel, J. Ferlay, J. Lortet-Tieulent, A. Jemal. Global cancer statistics, 2012. *CA Cancer J. Clin.* **2015**, *65*, 87–108.
- [2] Mathew J, Sibbering M. Breast cancer screening. In: Wyld L, Markopoulos C, Leidenius M, Senkus-Konefka E, editors. *Breast Cancer Management for Surgeons*. Cham, Switzerland: Springer; 2018. pp. 147–156.
- [3] K. Munir, H. Elahi, A. Ayub, F. Frezza, & A. Rizzi (2019). Cancer Diagnosis Using Deep Learning: A Bibliographic Review. *Cancers*, *11*(9), 1235. doi:10.3390/cancers11091235
- [4] American Cancer Society, *Breast Cancer Facts and Figures 2019*, American Cancer Society, Atlanta, GA, USA, 2019.
- [5] A. Nahid, and Y. Kong. Involvement of Machine Learning for Breast Cancer Image Classification: A Survey. 2017, 1748-670X, <https://doi.org/10.1155/2017/3781951>. *Computational and Mathematical Methods in Medicine*. Hindawi
- [6] J.E. Skandalakis. "Embryology and anatomy of the breast." In *Breast Augmentation*, pp. 3-24. Springer, Berlin, Heidelberg, 2009.
- [7] J. Dheeba, N. Albert Singh (2015) Computer Aided Intelligent Breast Cancer Detection: Second Opinion for Radiologists—A Prospective Study. In: Azar A., Vaidyanathan S. (eds) *Computational Intelligence Applications in Modeling and Control*. Studies in Computational Intelligence, vol 575. Springer, Cham
- [8] S. Ramadan, (2020). Methods Used in Computer-Aided Diagnosis for Breast Cancer Detection Using Mammograms: A Review. Hindawi. *Journal of Healthcare Engineering*. Volume 2020, Article ID 9162464, 21 pages <https://doi.org/10.1155/2020/9162464>
- [9] H.P. Chan, K. Doi, C.J. Vyborny, R.A. Schmidt, C.E. Metz, K.L. Lam, T. Ogura, Y. Wu, MacMahon, H.: Improvement in radiologists' detection of clustered microcalcifications on mammograms. The potential of computer-aided diagnosis. *Invest. Radiol.* *25*, 102–1110 (1990)
- [10] O. Olsen, and C. P. Gøtzsche. "Cochrane review on screening for breast cancer with mammography." *The Lancet* *358*.9290 (2001): 1340-1342.
- [11] R. M. Mann, C. K. Kuhl, K. Kinkel, & C. Boetes. "Breast MRI: guidelines from the European society of breast imaging." *European Radiology* *18*.7 (2008): 1307-1318.
- [12] A. Jalalian, S. B. Mashohor, H. R. Mahmud, M. I. B. Saripan, A. R. B. Ramli, & B. Karasfi. "Computer-aided detection/diagnosis of breast cancer in mammography and ultrasound: a review." *Clinical imaging* *37*.3 (2013): 420-426. DOI: <https://doi.org/10.1016/j.clinimag.2012.09.024>

- [13] A Sarno, G Mettivier, P Russo. Dedicated breast computed tomography: Basic aspects. *Med Phys* 2015;42:2786–804. <https://doi.org/10.1118/1.4919441>.
- [14] S. Njor, L. Nystro'm, S. Mossetal. "Breast cancer mortality in mammographic screening in Europe: a review of incidence- based mortality studies," *Journal of Medical Screening*, vol. 19, no. 1_suppl, pp. 33–41, 2012.
- [15] S. Morrell, R. Taylor, D. Roder, and A. Dobson, "Mammography screening and breast cancer mortality in Australia: an aggregate cohort study," *Journal of Medical Screening*, vol. 19, no. 1, pp. 26–34, 2012.
- [16] MG Marmot, DG Altman, DA Cameron, JA Dewar, SG Thompson, M Wilcox. The benefits and harms of breast cancer screening: an independent review. *British Journal of Cancer* 2013;108:2205–40. <https://doi.org/10.1038/bjc.2013.177>.
- [17] C-Y. Liu, C-Y. Hsu, Y-H. Chou, and C-M. Chen, "A multi-scale tumor detection algorithm in whole breast sonography incorporating breast anatomy and tissue morphological information," in 2014 IEEE Healthcare Innovation Conference (HIC), 2014, pp. 193-196.
- [18] E. D. Pisano, C. Gatsonis, E. Hendrick et al., "Diagnostic performance of digital versus film mammography for breast- cancer screening," *New England Journal of Medicine*, vol. 353, no. 17, pp. 1773–1783, 2005.
- [19] P. A. Carney, D. L. Miglioretti, B. C. Yankaskas et al., "Individual and combined effects of age, breast density, and hormone replacement therapy use on the accuracy of screening mammography," *Annals of Internal Medicine*, vol. 138, no. 3, pp. 168–175, 2003.
- [20] D. B. Woodard, A. E. Gelfand, W. E. Barlow, and J. G. Elmore, "Performance assessment for radiologists interpreting screening mammography," *Statistics in Medicine*, vol. 26, no. 7, pp. 1532–1551, 2007.
- [21] E. B. Cole, E. D. Pisano, E. O. Kistner et al., "Diagnostic accuracy of digital mammography in patients with dense breasts who underwent problem-solving mammography: effects of image processing and lesion type," *Radiology*, vol. 226, pp. 153–160, 2003.
- [22] N. F. Boyd, H. Guo, L. J. Martin et al., "Mammographic density and the risk and detection of breast cancer," *New England Journal of Medicine*, vol. 356, no. 3, pp. 227–236, 2007.
- [23] R. E. Bird, T. W. Wallace, and B. C. Yankaskas, "Analysis of cancers missed at screening mammography," *Radiology*, vol. 184, no. 3, pp. 613–617, 1992.
- [24] K. Kerlikowske, P. A. Carney, B. Geller et al., "Performance of screening mammography among women with and without a first-degree relative with breast cancer," *Annals of Internal Medicine*, vol. 133, no. 11, pp. 855–863, 2000.
- [25] M. G. Ertosun and D. L. Rubin, "Probabilistic visual search for masses within mammography images using deep learning," in *Proceedings of the IEEE International Conference on Bioinformatics and Biomedicine (BIBM)*, Washington, DC, USA, November 2015.
- [26] F. L. Nunes, H. Schiabel, and C. E. Goes, "Contrast enhancement in dense breast images to aid clustered micro- calcifications detection," *Journal of Digital Imaging*, vol. 20, no. 1, pp. 53–66, 2007.
- [27] C. Szegedy, V. Vanhoucke, S. Ioffe, J. Shlens, and Z. Wojna. Rethinking the inception architecture for computer vision. In CVPR, 2016.

- [28] J. Dinnes, S. Moss, J. Melia, R. Blanks, F. Song, and J. Kleijnen, "Effectiveness and cost-effectiveness of double reading of mammograms in breast cancer screening: findings of a systematic review," *e Breast*, vol. 10, no. 6, pp. 455–463, 2009.
- [29] P.J. Robinson. Radiology's Achilles' heel: error and variation in the interpretation of the Röntgen image. *Br J Radiol* 1997 Nov;70(839):1085-1098. [doi: 10.1259/bjr.70.839.9536897] [Medline: 9536897]
- [30] R. M. Rangayyan, F. J. Ayres, and J. E. Leo Desautels, "A review of computer-aided diagnosis of breast cancer: toward the detection of subtle signs," *Journal of the Franklin Institute*, vol. 344, no. 3-4, pp. 312–348, 2007.
- [31] A. Jalalian, S. Mashohor, R. Mahmud, B. Karasfi, M. I. B. Saripan, and A. R. B. Ramli, "Foundation and methodologies in computer-aided diagnosis systems for breast cancer detection," *EXCLI Journal*, vol. 16, pp. 113–137, 2017.
- [32] C. J. Vyborny, M. L. Giger, and R. M. Nishikawa, "Computer aided detection and diagnosis of breast cancer," *Radiologic Clinics of North America*, vol. 38, no. 4, pp. 725–740, 2000
- [33] J.D. Keen, J.M. Keen, J.E. Keen. Utilization of Computer-Aided Detection for Digital Screening Mammography in the United States, 2008 to 2016. *J Am Coll Radiol* 2018 Dec;15(1 Pt A):44-48. [doi: 10.1016/j.jacr.2017.08.033] [Medline: 28993109]
- [34] E.L. Henriksen, J.F. Carlsen, I.M. Vejborg, M.B. Nielsen, C.A. Lauridsen. The efficacy of using computer-aided detection (CAD) for detection of breast cancer in mammography screening: a systematic review. *Acta Radiol* 2019 Jan;60(1):13-18. [doi: 10.1177/0284185118770917] [Medline: 29665706]
- [35] J. Shan, et al. 2016. Computer-Aided Diagnosis for Breast Ultrasound Using Computerized BI-RADS Features and Machine Learning Methods. *Ultrasound in Medicine and Biology*, Volume 42, Issue 4, 980 – 988
- [36] Y. Gao, K.J. Geras, A.A. Lewin, L. Moy. New Frontiers: An Update on Computer-Aided Diagnosis for Breast Imaging in the Age of Artificial Intelligence. *American Journal of Roentgenology*. 212, 300–307 (2019).
- [37] Welcome to The Cancer Imaging Archive. The Cancer Imaging Archive (TCIA) n.d. <https://www.cancerimagingarchive.net/> (accessed 28 Dec 2019)
- [38] B.Q. Huynh, H. Li, M.L. Giger. Digital mammographic tumor classification using transfer learning from deep convolutional neural networks. *J Med Imaging*. 2016;3(3):034501.
- [39] M. H. Yap et al., "Automated Breast Ultrasound Lesions Detection Using Convolutional Neural Networks," in *IEEE Journal of Biomedical and Health Informatics*, vol. 22, no. 4, pp. 1218-1226, July 2018, doi: 10.1109/JBHI.2017.2731873.
- [40] W.K. Moon, Y.W. Lee, H.H. Ke, S.H. Lee, C.S. Huang, R.F. Chang. Computer aided diagnosis of breast ultrasound images using ensemble learning from convolutional neural networks, *Computer Methods and Programs in Biomedicine*, Volume 190, 2020, 105361, ISSN 0169-2607, <https://doi.org/10.1016/j.cmpb.2020.105361>.
- [41] M. H. Yap, M. Goyal, F. Osman, E. Ahmad, R. Martí, E. Denton, ... & R. Zwigelaar. (2018, March). End-to-end breast ultrasound lesions recognition with a deep learning approach.

In *Medical Imaging 2018: Biomedical Applications in Molecular, Structural, and Functional Imaging* (Vol. 10578, p. 1057819). International Society for Optics and Photonics.

[42] B. Xu, N. Wang, T. Chen, M. Li. Empirical evaluation of rectified activations in convolutional network. *arXiv* **2015**, arXiv:1505.00853.

[43] M.G. Ertosun, D.L. Rubin. Probabilistic visual search for masses within mammography images using deep learning. In Proceedings of the 2015 IEEE International Conference on Bioinformatics and Biomedicine (BIBM), Washington, DC, USA, 9–12 November 2015; pp. 1310–1315. *Cancers* 2019, 11, 1235 31 of 36

[44] B. Swiderski, J. Kurek, S. Osowski, M. Kruk, W. Barhoumi. Deep learning and non-negative matrix factorization in recognition of mammograms. In Proceedings of the Eighth International Conference on Graphic and Image Processing, International Society of Optics and Photonics, Tokyo, Japan, 8 February 2017; Volume 10225, p. 102250B

[45] Y. LeCun, Y. Bengio, G. Hinton. Deep learning. *Nature* **2015**, 436–444. [CrossRef] [PubMed]

[46] R. Miotto, F. Wang, S. Wang, X. Jiang, J.T. Dudley. Deep learning for healthcare: Review, opportunities and challenges. *Brief Bioinform.* 2017. [CrossRef] [PubMed]

[47] H.C. Shin, H.R. Roth, M. Gao, L. Lu, Z. Xu, I. Nogues, R.M. Summers. Deep Convolutional Neural Networks for Computer-Aided Detection: CNN Architectures, Dataset Characteristics and Transfer Learning. *IEEE Trans. Med. Imaging* 2016, 35, 1285–1298. [CrossRef] [PubMed]

[48] J.G. Lee, S. Jun, Y.W. Cho, H. Lee, G.B. Kim, J.B. Seo, N. Kim. Deep Learning in Medical Imaging: General Overview. *Korean J. Radiol.* 2017, 18, 570–584

[49] K Suzuki. Overview of deep learning in medical imaging. *Radiol. Phys.Technol.* 2017, 10, 257–273. [CrossRef] [PubMed]

[50] M.L. Giger. Machine Learning in Medical Imaging. *J Am Coll Radiol* 2018 Mar;15(3 Pt B):512-520. [doi: 10.1016/j.jacr.2017.12.028] [Medline: 29398494]

[51] K. S. Khan, R. Kunz, J. Kleijnen, & G. Antes. (2003). Five steps to conducting a systematic review. *Journal of the Royal Society of Medicine*, 96(3), 118–121. <https://doi.org/10.1258/jrsm.96.3.118>

[52] J. Suckling. The Mammographic Image Analysis Society Digital Mammogram Database. In *Exerpta Medica*. International Congress Series 1069, York, England. 1994; 1069:375–378.

[53] S. Han, H-K. Kang, J-Y. Jeong et al. A deep learning framework for supporting the classification of breast lesions in ultrasound images. *Phys Med Biol.* 2017; 62:7714.

[54] J. E. E. Oliveira, M. O. Gueld, A. D. A. Araujo, B. Ott, and T. M. Deserno, “Towards a standard reference database for computeraided mammography,” in Proceedings of the Medical Imaging 2008—Computer-Aided Diagnosis, Proceedings of SPIE, San Diego, Calif, USA, February 2008.

[55] C. Moreira, I. Amaral, I. Domingues, A. Cardoso, M.J. Cardoso, J.S. Cardoso. INbreast: Toward a Full-field Digital Mammographic Database, *Academic Radiology*, Volume 19, Issue 2, 2012, Pages 236-248, ISSN

10766332, <https://doi.org/10.1016/j.acra.2011.09.014>. (<http://www.sciencedirect.com/science/article/pii/S107663321100451X>)

[56] D. Abdelhafiz, C. Yang, R. Ammar, S. Nabavi Deep convolutional neural networks for mammography: advances, challenges and applications. *BMC Bioinform.* 2019;20(Suppl 11):281.

[57] S. Prapavesis, B. Fornage, A. Palko, C. Weismann, and P. Zoumpoulis, *Breast Ultrasound and US-Guided Interventional Techniques: A Multimedia Teaching File*. Thessaloniki, Greece, 2003.

[58] Z. Jiao, X. Gao, Y. Wang, J. Li, A deep feature based framework for breast masses classification, *Neurocomputing* 197 (2016) 221–231, doi:10.1016/j.neucom.2016.02.060.

[59] J. Arevalo, F.A. González, R. Ramos-Pollán, J.L. Oliveira, M.A. Guevara Lopez, Representation learning for mammography mass lesion classification with convolutional neural networks, *Comput. Methods Programs Biomed.* 127 (2016) 248–257, doi:10.1016/j.cmpb.2015.12.014.

[60] I.C. Moreira, I. Amaral, I. Domingues, A. Cardoso, M.J. Cardoso, J.S. Cardoso, INbreast: toward a full-field digital mammographic database, *Acad. Radiol* 19 (2012) 236–248, doi:10.1016/j.acra.2011.09.014.

[61] W. Peng, R.V. Mayorga, E.M.A. Hussein, An automated confirmatory system for analysis of mammograms, *Comput. Methods Programs Biomed.* 125 (2016) 134–144, doi:10.1016/j.cmpb.2015.09.019.

[62] W. Al-Dhabyani, M. Gomaa, H. Khaled, A.Fahmy, Dataset of breast ultrasound images, *DataBrief* (2019) 104863.

[63] J. W. Tian, Y. Wang, J. H. Huang, C. P. Ning, H. M. Wang, Y. Liu, & X. L. Tang. (2008, December). The digital database for breast ultrasound image. In 11th Joint International Conference on Information Sciences. Atlantis Press.

[64] M.H. Yap, G. Pons, J. Marti, et al. Automated Breast Ultrasound Lesions Detection Using Convolutional Neural Networks. *IEEE J Biomed Health Inform.* 2018;22(4):1218–1226. doi:10.1109/JBHI.2017.2731873

[65] H. Piotrkowska-Wr, K. Dobruch-Sobczak, M. Byra, A. Nowicki. Open access database of raw ultrasonic signals acquired from malignant and benign breast lesions. *Med Phys.* 2017; 44:6105–6109.

[66] J. Deng, W. Dong, R. Socher, L-J. Li, K. Li, L Fei-Fei. Imagenet: a large-scale hierarchical image database. In: *IEEE Conference on Computer Vision and Pattern Recognition*, 2009. CVPR 2009; 2009:248–255.

[67] H. Fujita, AI-based computer-aided diagnosis (AI-CAD): the latest review to read first. *Radiol Phys Technol* 13, 6–19 (2020). <https://doi.org/10.1007/s12194-019-00552-4>

[68] H.A. Leopold, J.S. Zelek, & V. Lakshminarayanan. (2018). Deep Learning for Retinal Analysis.

[69] R.M. Nishikawa, M.L. Giger, K. Doi; C.E. Metz, F.F. Yin, C.J. Vyborny, R.A. Schmidt. “Effect of case selection on the performance of computer-aided detection schemes”, *Med. Phys.* 21, 265-269 (1994).

- [70] R. Guo, G. Lu, B. Qin, and B. Fei, "Ultrasound imaging technologies for breast cancer detection and management: a review," *Ultrasound in medicine & biology*, vol. 44, pp. 37-70, 2018.
- [71] L. Cadena et al (2019) Proceedings of the World Congress on Engineering and Computer Science 2019 WCECS 2019, October 22-24, 2019, San Francisco, USA ISBN: 978-988-14048-7-9 ISSN: 2078-0958 (Print); ISSN: 2078-0966 (Online)
- [72] J. Dabass, S. Arora, R. Vig and M. Hanmandlu, "Segmentation Techniques for Breast Cancer Imaging Modalities-A Review," 2019 9th International Conference on Cloud Computing, Data Science & Engineering (Confluence), Noida, India, 2019, pp. 658-663, doi: 10.1109/CONFLUENCE.2019.8776937.
- [73] Y.M. Abdallah, S.N. Elgak, H. Zain, M. Rafiq, E.A. Ebaid, & A.A. Elnaema. (2018). Breast cancer detection using image enhancement and segmentation algorithms. *Biomedical Research-tokyo*, 29, 3732-3736.
- [74] G.P. Raj. (2016). OBJECTIVE QUALITY ASSESSMENT OF IMAGE ENHANCEMENT METHODS IN DIGITAL MAMMOGRAPHY-A COMPARATIVE STUDY. *Signal & Image Processing: An International Journal (SIPIJ)* Vol.7, No.4, August 2016
- [75] M. J. George and S. P. Sankar, "Efficient preprocessing filters and mass segmentation techniques for mammogram images," 2017 IEEE International Conference on Circuits and Systems (ICCS), Thiruvananthapuram, 2017, pp. 408-413, doi: 10.1109/ICCS1.2017.8326032.
- [76] M. Talha, G.B. Sulong, & A. Jaffar. (2016). Preprocessing digital breast mammograms using adaptive weighted frost filter. *Biomedical Research-tokyo*, 27, 1407-1412.
- [77] M. J. Kshema, and D. A. S. Dhas, "Preprocessing filters for mammogram images: A review," 2017 *Conference on Emerging Devices and Smart Systems (ICEDSS)*, Tiruchengode, 2017, pp. 1-7, doi: 10.1109/ICEDSS.2017.8073694.
- [78] C.C. Kang, W.-J. Wang, and C.-H. Kang, "Image segmentation with complicated background by using seeded region growing," *AEU-International Journal of Electronics and Communications*, vol. 66, pp. 767-771, 2012.
- [79] K. Prabusankarlal, P. Thirumoorthy, and R. Manavalan, "Computer aided breast cancer diagnosis techniques in ultrasound: a survey," *Journal of Medical Imaging and Health Informatics*, vol. 4, pp. 331-349, 2014.
- [80] S. Chen, S. Abhinav, S. Saurabh, G. Abhinav. Revisiting unreasonable effectiveness of data in deep learning era. In: *ICCV*; 2017. p. 843–52.
- [81] C. Shorten, T.M. Khoshgoftaar. A survey on Image Data Augmentation for Deep Learning. *J Big Data* 6, 60 (2019). <https://doi.org/10.1186/s40537-019-0197-0>
- [82] W. Karl, M.K. Taghi, W. Ding. A survey of transfer learning. *J Big Data*. 2016; 3:9.
- [83] L. Shao. Transfer learning for visual categorization: a survey. *IEEE Trans Neural Netw Learn Syst*. 2015;26(5):1019–34.
- [84] Z. Zhun, Z. Liang, K. Guoliang, L. Shaozi, Y Yi. Random erasing data augmentation. *ArXiv e-prints*. 2017.

- [85] J.G. Ian, P.A. Jean, M. Mehdi, X. Bing, W.F. David, O. Sherjil, C. Aaron, B. Yoshua. Generative adversarial nets. NIPS. 2014.
- [86] A.G. Leon, S.E. Alexander, B. Matthias A neural algorithm of artistic style. ArXiv. 2015.
- [87] A. Rodriguez-Ruiz et al (2018) Pectoral muscle segmentation in breast tomosynthesis with deep learning. In: Proceedings of SPIE 10575, medical imaging 2018: computer-aided diagnosis, p 105752J. <https://doi.org/10.1117/12.2292920>
- [88] W. Gomez, A. Rodriguez, W. Pereira, and A. Infantosi, "Feature selection and classifier performance in computer-aided diagnosis for breast ultrasound," in 2013 10th International Conference and Expo on Emerging Technologies for a Smarter World (CEWIT), 2013, pp. 1-5.
- [89] J. Saeed. (2020). A SURVEY OF ULTRASONOGRAPHY BREAST CANCER IMAGE SEGMENTATION TECHNIQUES. *Academic Journal Of Nawroz University*, 9(1), 1-14. doi:10.25007/ajnu.v9n1a523
- [90] Y. B. Fadhel, S. Ktata, and T. Kraiem, "Cardiac scintigraphic images segmentation techniques," in 2016 2nd International Conference on Advanced Technologies for Signal and Image Processing (ATSIP), 2016, pp. 364
- [91] H. Cheng, et al. Automated breast cancer detection and classification using ultrasound images: a survey. *Pattern Recognit* 2010;43(1): 299-317.
- [92] S. Han, H-K. Kang, J-Y. Jeong, M.-H. Park, W. Kim, W.C. Bang, Y.-K. Seong (2017). A deep learning framework for supporting the classification of breast lesions in ultrasound images, *Physics in Medicine & Biology*, doi 10.1088/1361-6560/aa82ec 62, 19,7714-7728 <https://doi.org/10.1088/1361-6560/aa82ec>
- [93] M. Vasantha, D. Bharathi, S. Dhamodharan. Medical image feature, extraction, selection and classification. *Int J Eng Sci* 2010; 2:2071-6.
- [94] K. Verma, B.K Singh, P. Tripathi, A.S Thoke. Review of Feature Selection Algorithms for Breast Cancer Ultrasound Image. *New Trends in Intelligent Information and Database Systems*, Springer International Publishing (2015), pp. 23-32
- [95] J. Sikorski. Identification of malignant melanoma by wavelet analysis. In Proceedings of the Student/Faculty Research Day, New York, NY, USA, 7 May 2004.
- [96] A. Chiem, A. Al-Jumaily, N.R. Khushaba. A novel hybrid system for skin lesion detection. In Proceedings of the 3rd International Conference on Intelligent Sensors, Sensor Networks and Information Processing (ISSNIPâ™07), Melbourne, Australia, 3–6 December 2007; pp. 567–572.
- [97] I. Maglogiannis, E. Zafiroopoulos, C. Kyranoudis. Intelligent segmentation and classification of pigmented skin lesions in dermatological images. In *Advances in Artificial Intelligence*; Springer: Berlin/Heidelberg, Germany, 2006; pp. 214–223.
- [98] T. Tanaka, S. Torii, I. Kabuta, K. Shimizu, M. Tanaka, H. Oka. Pattern classification of nevus with texture analysis. In Proceedings of the 26th Annual International Conference of the IEEE Engineering in Medicine and Biology Society (EMBCâ™04), San Francisco, CA, USA, 1–5 September 2004; pp. 1459–1462.
- [99] H. Zhou, M. Chen, J.M. Rehg. Dermoscopic interest point detector and descriptor. In Proceedings of the 6th IEEE International Symposium on Biomedical Imaging: From Nano to Macro (ISBIâ™09), Boston, MA, USA, 28 June–1 July 2009; pp. 1318–1321.

- [100] C. Lee, D.A. Landgrebe. Feature extraction based on decision boundaries. *IEEE Trans. Pattern Anal. Mach. Intell.* 1993, 15, 388–400.
- [101] Hu, F.; Xia, G.-S.; Hu, J.; Zhang, L. Transferring Deep Convolutional Neural Networks for the Scene Classification of High-Resolution Remote Sensing Imagery. *Remote Sens.* **2015**, *7*, 14680-14707.
- [102] S. Sengupta, A. Singh, H. A. Leopold, T. Gulati, V. Lakshminarayanan (2020). Ophthalmic diagnosis using deep learning with fundus images – A critical review, *Artificial Intelligence in Medicine*, Volume 102,2020,101758,ISSN 0933-3657, <https://doi.org/10.1016/j.artmed.2019.101758>
- [103] J. Long, E. Shelhamer, and T. Darrell, “Fully convolutional networks for semantic segmentation,” in *Proc. IEEE Conf. Comput. Vis. Pattern Recognit.*, 2015, pp. 3431–3440.
- [104] Y. Liu, X.Yao, Ensemble learning via negative correlation, *Neural netw.* 12 (1999) 1399-1404.
- [105] K. Munir, H. Elahi, A. Ayub, F. Frezza, A. Rizzi. Cancer Diagnosis Using Deep Learning: A Bibliographic Review. *Cancers (Basel)*. 2019;11(9):1235. Published 2019 Aug 23. doi:10.3390/cancers11091235
- [106] A. Krizhevsky, I. Sutskever, G.E. Hinton. ImageNet classification with deep convolutional neural networks. *Adv Neural Inf Process Syst.* 2012; 25:1106–14.
- [107] S. Karen, Z. Andrew. Very deep convolutional networks for large-scale image recognition. arXiv e-prints. 2014.
- [108] H. Kaiming, Z. Xiangyu, R. Shaoqing, S. Jian. Deep residual learning for image recognition. In: *CVPR*, 2016.
- [109] S. Christian, V. Vincent, I. Sergey, S. Jon, W. Zbigniew. Rethinking the inception architecture for computer vision. arXiv e-prints, 2015.
- [110] H. Gao, L. Zhuang, M. Laurens, Q.W. Kilian. Densely connected convolutional networks. arXiv preprint. 2016.
- [111] A. Krizhevsky, I. Sutskever, G.E. Hinton. Imagenet classification with deep convolutional neural networks. In *Proceedings of the Twenty-Sixth Annual Conference on Neural Information Processing Systems*. Lake Tahoe, NY, USA, 3–8 December 2012; pp. 1097–1105.
- [112] O. Russakovsky, J. Deng, H. Su, J. Krause, S. Satheesh, S. Ma, Z. Huang, A. Karpathy, A. Khosla, M. Bernstein, *et al.* Imagenet large scale visual recognition challenge. *Int. J. Comput. Vis.* 2015, doi: 10.1007/s11263-015-0816-y.
- [113] R.K. Samala, H.-P. Chan, L. Hadjiiski, et al. (2016) Mass Detection in Digital Breast Tomosynthesis: Deep Convolutional Neural Network with Transfer Learning from Mammography. *Medical Physics*, 43, 6654-6666 <https://doi.org/10.1118/1.4967345>
- [114] K. Simonyan and A. Zisserman, "Very deep convolutional networks for largescale image recognition," arXiv preprint arXiv:1409.1556, 2014.
- [115] L. Zheng, Y. Zhao, S. Wang, J. Wang, Q. Tian. Good practice in CNN feature transfer; 2016. arXiv Prepr arXiv160400133.

- [116] K. He, X Zhang, S. Ren, J. Sun, Deep residual learning for image recognition, in : Proceedings of the IEEE Conference on Computer Vision and Pattern Recognition, 2016, pp. 770-778.
- [117] G. Huang, Z. Liu, K.Q. Weinberger, L. Van der Maaten, Densely connected convolutional networks, in: Proceedings of the IEEE Conference on Computer Vision and Pattern Recognition, 2017, p.3.
- [118] S. Szegedy, V. Lofte, A.A. Vanhoucke, I. Alemi, inception-resnet and the impact of residual connections on learning, in: AAAI, 2017, p.12.
- [119] K. Das, S. Conjeti, A.G. Roy, J. Chatterjee, & D. Sheet. (2018, April). Multiple instance learning of deep convolutional neural networks for breast histopathology whole slide classification. In *2018 IEEE 15th International Symposium on Biomedical Imaging (ISBI 2018)* (pp. 578-581). IEEE.
- [120] Z. Cao, L. Duan, G. Yang *et al.* An experimental study on breast lesion detection and classification from ultrasound images using deep learning architectures. *BMC Med Imaging* **19**, 51 (2019). <https://doi.org/10.1186/s12880-019-0349-x>
- [121] J.Y. Chiao, K.Y. Chen, K.Y. Liao, P.H. Hsieh, G. Zhang, T.C. Huang. Detection and classification the breast tumors using mask R-CNN on sonograms. *Medicine (Baltimore)*. 2019;98(19): e15200. doi:10.1097/MD.00000000000015200
- [122] Y. LeCun, L. Bottou, Y. Bengio, and P. Haffner, "Gradient-based learning applied to document recognition," Proc. IEEE, vol. 86, no. 11, pp. 2278–2324, Nov. 1998.
- [123] O. Ronneberger, P. Fischer, and T. Brox, "U-net: Convolutional networks for biomedical image segmentation," in *Proc. Int. Conf. Med. Image Comput. -Assisted Intervention*, 2015, pp. 234–241.
- [124] B. Huynh, K. Drukker, and M. Giger, "Mo-de-207b-06: Computer-aided diagnosis of breast ultrasound images using transfer learning from deep convolutional neural networks," *Med. Phys.*, vol. 43, no. 6, pp. 3705–3705, 2016.
- [125] T. Kooi et al., "Large scale deep learning for computer aided detection of mammographic lesions," *Med. Image Anal.*, vol. 35, pp. 303–312, 2017.
- [126] D.A. Ragab, M. Sharkas, S. Marshall, and J. Ren. "Breast cancer detection using deep convolutional neural networks and support vector machines." *PeerJ* 7 e6201, 2019.
- [127] M.A. Al-Masni, M.A. Al-Antari, J.M. Park, G. Gi, T.Y. Kim, P. Rivera, E. Valarezo, M.T. Choi, S.M. Han, and T. S. Kim. "Simultaneous detection and classification of breast masses in digital mammograms via a deep learning YOLO-based CAD system." *Computer methods and programs in biomedicine* 157, pp. 85-94, 2018.
- [128] A. Duggento, M.A. Carlo Cavaliere, G.L. Cascella, D. Cascella, G. Conte, M. Guerrisi, and N. Toschi. "An Ad Hoc Random Initialization Deep Neural Network Architecture for Discriminating Malignant Breast Cancer Lesions in Mammographic Images." *Contrast media & molecular imaging* 2019, 2019.
- [129] H. Chougrad, H. Zouaki, and O. Alheyane. "Deep convolutional neural networks for breast cancer screening." *Computer methods and programs in biomedicine* 157, pp. 19-30, 2018

- [130] M. Byra, T. Sznajder, D. Korzinek, H. Piotrkowska-Wroblewska, K. Dobruch-Sobczak, A. Nowicki, and K. Marasek, "Impact of ultrasound image reconstruction method on breast lesion classification with neural transfer learning," 2018, arXiv:1804.02119. [Online]. Available: <http://arxiv.org/abs/1804.02119>
- [131] J. Shan, S. Kaisar Alam, B. Garra, Y. Zhang, T. Ahmed. Computer-Aided Diagnosis for Breast Ultrasound Using Computerized BI-RADS Features and Machine Learning Methods, *Ultrasound in Medicine & Biology*, Volume 42, Issue 4, 2016, Pages 980-988, ISSN 0301-5629, <https://doi.org/10.1016/j.ultrasmedbio.2015.11.016>.
- [132] J. Liu et al (2018) Radiation dose reduction in digital breast tomosynthesis (DBT) by means of deep-learning-based supervised image processing. In: *Proceedings of SPIE 10574, medical imaging 2018: image processing*, p 105740F. <https://doi.org/10.1117/12.2293125>
- [133] S.Y. Shin et al (2017) Joint weakly and semi-supervised deep learning for localization and classification of masses in breast ultrasound images. arXiv: 1710.03778v1
- [134] L. Zou , S. Yu, T. Meng, Z. Zhang, X. Liang, Y. Xie (2019) A Technical Review of Convolutional Neural Network-Based Mammographic Breast Cancer Diagnosis 6509357 2019 <https://doi.org/10.1155/2019/6509357> *Computational and Mathematical Methods in Medicine Hindawi*
- [135] J. Dheebea, N. Albert Singh, S. Tamil Selvi, Computer-aided detection of breast cancer on mammograms: A swarm intelligence optimized wavelet neural network approach, *Journal of Biomedical Informatics*, Volume 49, 2014, Pages 45-52, ISSN 1532-0464, <https://doi.org/10.1016/j.jbi.2014.01.010>.
- [136] T.G. Debelee et al (2018) Classification of mammograms using convolutional neural network-based feature extraction. *ICT4DA 2017 LNICST 244:89–98*
- [137] E. Trivizakis, G.S. Ioannidis, V.D. Melissianos, G.Z. Papadakis, A. Tsatsakis, D.A., & M. Spandidos. (2019). A novel deep learning architecture outperforming 'off-the-shelf' transfer learning and feature-based methods in the automated assessment of mammographic breast density. *Oncology Reports*, 42, 2009-2015. <https://doi.org/10.3892/or.2019.7312>
- [138] R. Samala, H-P. Chan, L.M. Hadjiiski, M.A. Helvie, C. Richter, K. Cha (2018b) Cross-domain and multi-task transfer learning of deep convolutional neural network for breast cancer diagnosis in digital breast tomosynthesis. In: *Proceedings of SPIE 10575, medical imaging 2018: computer-aided diagnosis*. <https://doi.org/10.1117/12.2293412>
- [139] M.M. Jadoon et al (2017) Three-class mammogram classification based on descriptive CNN features. *Hindawi Biomed Res Int*. <https://doi.org/10.1155/2017/3640901>
- [140] A. H. Ahmed and M. A. -. Salem, "Mammogram-Based Cancer Detection Using Deep Convolutional Neural Networks," *2018 13th International Conference on Computer Engineering and Systems (ICCES)*, Cairo, Egypt, 2018, pp. 694-699, doi: 10.1109/ICCES.2018.8639224.
- [141] Y. Xu, Y. Wang, J. Yuan, Q. Cheng, X. Wang, P. L. Carson. Medical breast ultrasound image segmentation by machine learning, *Ultrasonics*, Volume 91, 2019, Pages 1-9, ISSN 0041-624X, <https://doi.org/10.1016/j.ultras.2018.07.006>.
- [142] J. Shan, S.K. Alam, B. Garra, Y. Zhang, T. Ahmed. Computer-Aided Diagnosis for Breast Ultrasound Using Computerized BI-RADS Features and Machine Learning Methods. *Ultrasound Med Biol*. 2016;42(4):980-988. doi: 10.1016/j.ultrasmedbio.2015.11.016

- [143] P. Gu, W.M. Lee, M.A. Roubidoux, J. Yuan, X. Wang, P.L. Carson. Automated 3D ultrasound image segmentation to aid breast cancer image interpretation. *Ultrasonics*. 2016;65:51-58. doi:10.1016/j.ultras.2015.10.023
- [144] Q. Zhang, Y. Xiao, W. Dai, et al. Deep learning-based classification of breast tumors with shear-wave elastography. *Ultrasonics*. 2016; 72:150-157. doi: 10.1016/j.ultras.2016.08.004
- [145] R. Almajalid, J. Shan, Y. Du and M. Zhang, "Development of a Deep-Learning-Based Method for Breast Ultrasound Image Segmentation," *2018 17th IEEE International Conference on Machine Learning and Applications (ICMLA)*, Orlando, FL, 2018, pp. 1103-1108, doi: 10.1109/ICMLA.2018.00179.
- [146] B. K. Singh, K. Verma, and A. S. oke, "Fuzzy cluster based neural network classifier for classifying breast tumors in ultrasound images," *Expert Systems with Applications*, vol. 66, pp. 114–123, 2016.
- [147] J.Z. Cheng, D. Ni, Y.-H. Chou et al., "Computer-Aided Diagnosis with Deep Learning Architecture: Applications to Breast Lesions in US Images and Pulmonary Nodules in CT Scans," *Scientific Reports*, vol. 6, Article ID 24454, 2016.
- [148] J. Shi, S. Zhou, X. Liu, Q. Zhang, M. Lu, and T. Wang, "Stacked deep polynomial network-based representation learning for tumor classification with small ultrasound image dataset," *Neurocomputing*, vol. 194, pp. 87–94, 2016.
- [149] T. Kooi et al (2017) Large scale deep learning for computer aided detection of mammographic lesions. *Med Image Anal* 35:303–312
- [150] T.G. Debelee, F. Schwenker, A. Ibenthal, *et al.* Survey of deep learning in breast cancer image analysis. *Evolving Systems* **11**, 143–163 (2020). <https://doi.org/10.1007/s12530-019-09297-2>
- [151] Thitivirut, M., Leekitviwat, J., Pathomsathit, C., & Phasukkit, P. (2019, November). Image Enhancement by using Triple Filter and Histogram Equalization for Organ Segmentation. In 2019 12th Biomedical Engineering International Conference (BMEiCON) (pp. 1-5). IEEE.
- [152] Gandhi K.R, Karnan M.," Mammogram image enhancement and segmentation", IEEE international conference on computational intelligence and computing research (ICIC) 2010-1:1-4
- [153] Pizer SM, Philip Amburn E, Austin JD, Cromartie R, Geselowitz A, Greer T, Ter Haar Romeny B, Zimmerman JB, Zuiderveld K. 1987. Adaptive histogram equalization and its variations. *Computer Vision, Graphics, and Image Processing* 39:355–368.
- [154] Pisano ED, Zong S, Hemminger BM, DeLuca M, Johnston RE, Muller K, Braeuning MP, Pizer SM. 1998. Contrast limited adaptive histogram equalization image processing to improve the detection of simulated spiculations in dense mammograms. *Journal of Digital Imaging* 11:193–200.
- [155] Wan, et al 2020. Progressive residual networks for image super-resolution. *Applied Intelligence* <https://doi.org/10.1007/s10489-019-01548-8> doi 10.1007/s10489-019-01548-8
- [156] Jiang, Y., & Li, J. (2020). Generative Adversarial Network for Image Super-Resolution Combining Texture Loss. *Applied Sciences*, 10(5), 1729.

- [157] D. Glasner, S. Bagon and M. Irani, "Super-resolution from a single image," 2009 IEEE 12th International Conference on Computer Vision, Kyoto, 2009, pp. 349-356, doi: 10.1109/ICCV.2009.545927
- [158] Schultz, R.R.; Stevenson, R.L. A Bayesian approach to image expansion for improved definition. *IEEE Trans. Image Process.* 1994, 3, 233–242. [CrossRef] [PubMed]
- [159] Gribbon, K.T.; Bailey, D.G. A novel approach to real-time bilinear interpolation. In *Proceedings of the DELTA, Second IEEE International Workshop on Electronic Design, Test and Applications*, Perth, WA, Australia, 28–30 January 2004; pp. 126–131.
- [160] Zhang, L.; Wu, X. An edge-guided image interpolation algorithm via directional filtering and data fusion. *IEEE Trans. Image Process.* 2006, 15, 2226–2238. [CrossRef] [PubMed]
- [161] Dong, C., Loy, C. C., He, K., & Tang, X. (2015). Image super-resolution using deep convolutional networks. *IEEE transactions on pattern analysis and machine intelligence*, 38(2), 295–307.
- [162] Kim, J., Kwon Lee, J., & Mu Lee, K. (2016). Accurate image super-resolution using very deep convolutional networks. In *Proceedings of the IEEE conference on computer vision and pattern recognition* (pp. 1646–1654).
- [163] Al-Masni, M. A., Al-Antari, M. A., Park, J. M., Gi, G., Kim, T. Y., Rivera, P., ... & Kim, T. S. (2018). Simultaneous detection and classification of breast masses in digital mammograms via a deep learning YOLO-based CAD system. *Computer methods and programs in biomedicine*, 157, 85-94.
- [164] Badrinarayanan, V., Kendall, A., & Cipolla, R. (2017). Segnet: A deep convolutional encoder-decoder architecture for image segmentation. *IEEE transactions on pattern analysis and machine intelligence*, 39(12), 2481-2495.
- [165] Almajalid, R., Shan, J., Du, Y., & Zhang, M. (2018, December). Development of a deep-learning-based method for breast ultrasound image segmentation. In *2018 17th IEEE International Conference on Machine Learning and Applications (ICMLA)* (pp. 1103-1108). IEEE.
- [166] Ronneberger, O., Fischer, P., & Brox, T. (2015, October). U-net: Convolutional networks for biomedical image segmentation. In *International Conference on Medical image computing and computer-assisted intervention* (pp. 234-241). Springer, Cham.
- [167] Geras, K. J., Wolfson, S., Shen, Y., Wu, N., Kim, S., Kim, E., ... & Cho, K. (2017). High-resolution breast cancer screening with multi-view deep convolutional neural networks. arXiv preprint arXiv:1703.07047.
- [168] Rumelhart, D. E., Hinton, G. E., & Williams, R. J. (1985). *Learning internal representations by error propagation* (No. ICS-8506). California Univ San Diego La Jolla Inst for Cognitive Science.
- [169] Krizhevsky, A., Sutskever, I., & Hinton, G. E. (2012). Imagenet classification with deep convolutional neural networks. In *Advances in neural information processing systems* (pp. 1097-1105).

- [170] Han, S., Kang, H. K., Jeong, J. Y., Park, M. H., Kim, W., Bang, W. C., & Seong, Y. K. (2017). A deep learning framework for supporting the classification of breast lesions in ultrasound images. *Physics in Medicine & Biology*, 62(19), 7714.
- [171] Dong, C., Loy, C. C., He, K., & Tang, X. (2015). Image super-resolution using deep convolutional networks. *IEEE transactions on pattern analysis and machine intelligence*, 38(2), 295-307.
- [172] Dhungel, N., Carneiro, G., & Bradley, A. P. (2017). A deep learning approach for the analysis of masses in mammograms with minimal user intervention. *Medical image analysis*, 37, 114-128.
- [173] Singh, V. K., Rashwan, H. A., Abdel-Nasser, M., Sarker, M., Kamal, M., Akram, F., ... & Puig, D. (2019). An efficient solution for breast tumor segmentation and classification in ultrasound images using deep adversarial learning. *arXiv preprint arXiv:1907.00887*.
- [174] Rodrigues, P. S. (2017). Breast Ultrasound Image. *Mendeley Data*, 1.
- [175] Cheng, J. Z., Ni, D., Chou, Y. H., Qin, J., Tiu, C. M., Chang, Y. C., ... & Chen, C. M. (2016). Computer-aided diagnosis with deep learning architecture: applications to breast lesions in US images and pulmonary nodules in CT scans. *Scientific reports*, 6(1), 1-13.
- [176] Abdelhafiz, D., Yang, C., Ammar, R., & Nabavi, S. (2019). Deep convolutional neural networks for mammography: advances, challenges and applications. *BMC bioinformatics*, 20(11), 281.
- [177] Wang, J., Ding, H., Bidgoli, F. A., Zhou, B., Iribarren, C., Molloy, S., & Baldi, P. (2017). Detecting cardiovascular disease from mammograms with deep learning. *IEEE transactions on medical imaging*, 36(5), 1172-1181.
- [178] Zhu, W., Lou, Q., Vang, Y. S., & Xie, X. (2017, September). Deep multi-instance networks with sparse label assignment for whole mammogram classification. In *International Conference on Medical Image Computing and Computer-Assisted Intervention* (pp. 603-611). Springer, Cham.
- [179] Dhungel, N., Carneiro, G., & Bradley, A. P. (2017, April). Fully automated classification of mammograms using deep residual neural networks. In *2017 IEEE 14th International Symposium on Biomedical Imaging (ISBI 2017)* (pp. 310-314). IEEE.
- [180] Kim, T., Cha, M., Kim, H., Lee, J. K., & Kim, J. (2017). Learning to discover cross-domain relations with generative adversarial networks. *arXiv preprint arXiv:1703.05192*.
- [181] Romera, E., Alvarez, J. M., Bergasa, L. M., & Arroyo, R. (2017). Erfnet: Efficient residual factorized convnet for real-time semantic segmentation. *IEEE Transactions on Intelligent Transportation Systems*, 19(1), 263-272.
- [182] Dong, C., Loy, C. C., He, K., & Tang, X. (2014, September). Learning a deep convolutional network for image super-resolution. In *European conference on computer vision* (pp. 184-199). Springer, Cham.
- [183] Lotter, W., Sorensen, G., & Cox, D. (2017). A multi-scale CNN and curriculum learning strategy for mammogram classification. In *Deep Learning in Medical Image Analysis and Multimodal Learning for Clinical Decision Support* (pp. 169-177). Springer, Cham.

- [184] Carneiro, N. D. G., & Bradley, A. P. Automated Mass Detection from Mammograms using Deep Learning and Random Forest (2016)
- [185] Arevalo, J., González, F. A., Ramos-Pollán, R., Oliveira, J. L., & Lopez, M. A. G. (2016). Representation learning for mammography mass lesion classification with convolutional neural networks. *Computer methods and programs in biomedicine*, 127, 248-257.
- [186] Sharma, J., Rai, J. K., & Tewari, R. P. (2014, November). Identification of pre-processing technique for enhancement of mammogram images. In *2014 International Conference on Medical Imaging, m-Health and Emerging Communication Systems (MedCom)* (pp. 115-119). IEEE.
- [187] Kooi, T., Litjens, G., Van Ginneken, B., Gubern-Mérida, A., Sánchez, C. I., Mann, R., ... & Karssemeijer, N. (2017). Large scale deep learning for computer aided detection of mammographic lesions. *Medical image analysis*, 35, 303-312.
- [188] Antropova, N., Huynh, B. Q., & Giger, M. L. (2017). A deep feature fusion methodology for breast cancer diagnosis demonstrated on three imaging modality datasets. *Medical physics*, 44(10), 5162-5171.
- [189] Mordang, J. J., Janssen, T., Bria, A., Kooi, T., Gubern-Mérida, A., & Karssemeijer, N. (2016, June). Automatic microcalcification detection in multi-vendor mammography using convolutional neural networks. In *International Workshop on Breast Imaging* (pp. 35-42). Springer, Cham.
- [190] Akselrod-Ballin, A., Karlinsky, L., Alpert, S., Hasoul, S., Ben-Ari, R., & Barkan, E. (2016). A region based convolutional network for tumor detection and classification in breast mammography. In *Deep learning and data labeling for medical applications* (pp. 197-205). Springer, Cham.
- [191] Jiao, Z., Gao, X., Wang, Y., & Li, J. (2016). A deep feature based framework for breast masses classification. *Neurocomputing*, 197, 221-231.
- [192] Zhu, W., Xiang, X., Tran, T. D., & Xie, X. (2016). Adversarial deep structural networks for mammographic mass segmentation. *arXiv preprint arXiv:1612.05970*.
- [193] Lévy, D., & Jain, A. (2016). Breast mass classification from mammograms using deep convolutional neural networks. *arXiv preprint arXiv:1612.00542*.
- [194] Sert, E., Ertekin, S., & Halici, U. (2017, July). Ensemble of convolutional neural networks for classification of breast microcalcification from mammograms. In *2017 39th Annual International Conference of the IEEE Engineering in Medicine and Biology Society (EMBC)* (pp. 689-692). IEEE.
- [195] Dhungel, N., Carneiro, G., & Bradley, A. P. (2016, October). The automated learning of deep features for breast mass classification from mammograms. In *International Conference on Medical Image Computing and Computer-Assisted Intervention* (pp. 106-114). Springer, Cham.
- [196] Abdelhafiz, D., Yang, C., Ammar, R., & Nabavi, S. (2019). Deep convolutional neural networks for mammography: advances, challenges and applications. *BMC bioinformatics*, 20(11), 281.
- [197] Kooi, T., Gubern-Merida, A., Mordang, J. J., Mann, R., Pijnappel, R., Schuur, K., ... & Karssemeijer, N. (2016, June). A comparison between a deep convolutional neural network and

radiologists for classifying regions of interest in mammography. In *International Workshop on Breast Imaging* (pp. 51-56). Springer, Cham.

[198] Kooi, T., van Ginneken, B., Karssemeijer, N., & den Heeten, A. (2017). Discriminating solitary cysts from soft tissue lesions in mammography using a pretrained deep convolutional neural network. *Medical physics*, 44(3), 1017-1027.

[199] Chan, H. P., Lo, S. C. B., Sahiner, B., Lam, K. L., & Helvie, M. A. (1995). Computer-aided detection of mammographic microcalcifications: Pattern recognition with an artificial neural network. *Medical physics*, 22(10), 1555-1567.

[200] Valvano, G., Della Latta, D., Martini, N., Santini, G., Gori, A., Iacconi, C., ... & Chiappino, D. (2017). Evaluation of a Deep Convolutional Neural Network method for the segmentation of breast microcalcifications in Mammography Imaging. In *EMBECC & NBC 2017* (pp. 438-441). Springer, Singapore.

[201] Carneiro, G., Nascimento, J., & Bradley, A. P. (2015, October). Unregistered multiview mammogram analysis with pre-trained deep learning models. In *International Conference on Medical Image Computing and Computer-Assisted Intervention* (pp. 652-660). Springer, Cham.

[202] Carneiro, G., Nascimento, J., & Bradley, A. P. (2017). Automated analysis of unregistered multi-view mammograms with deep learning. *IEEE transactions on medical imaging*, 36(11), 2355-2365.

[203] Umehara, K., Ota, J., & Ishida, T. (2017). Super-resolution imaging of mammograms based on the super-resolution convolutional neural network. *Open Journal of Medical Imaging*, 7(4), 180-195.

Figure Captions

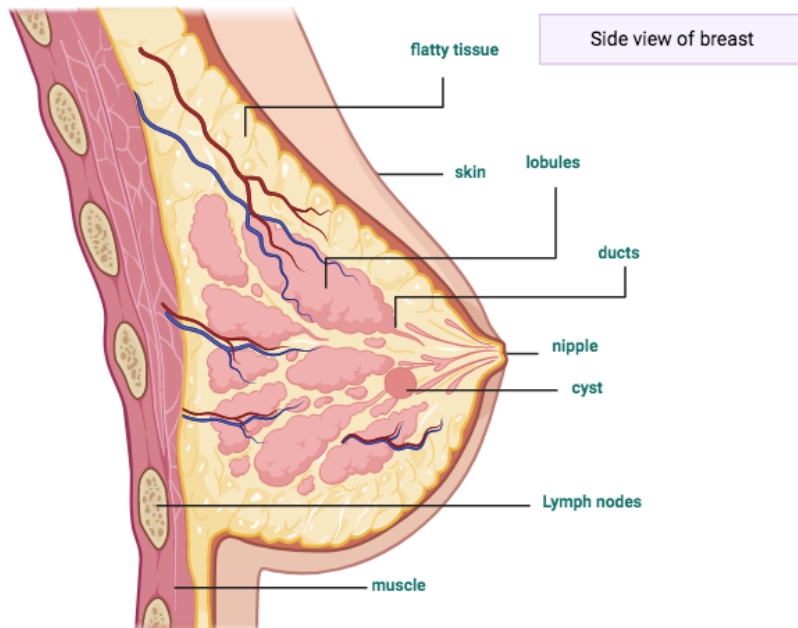


Fig 1. This scheme represents the anatomy of the woman breast. Inside the lobes are the zones where the epithelial tumors or cyst grow. Designed by Biorender.

Systematic Review Process

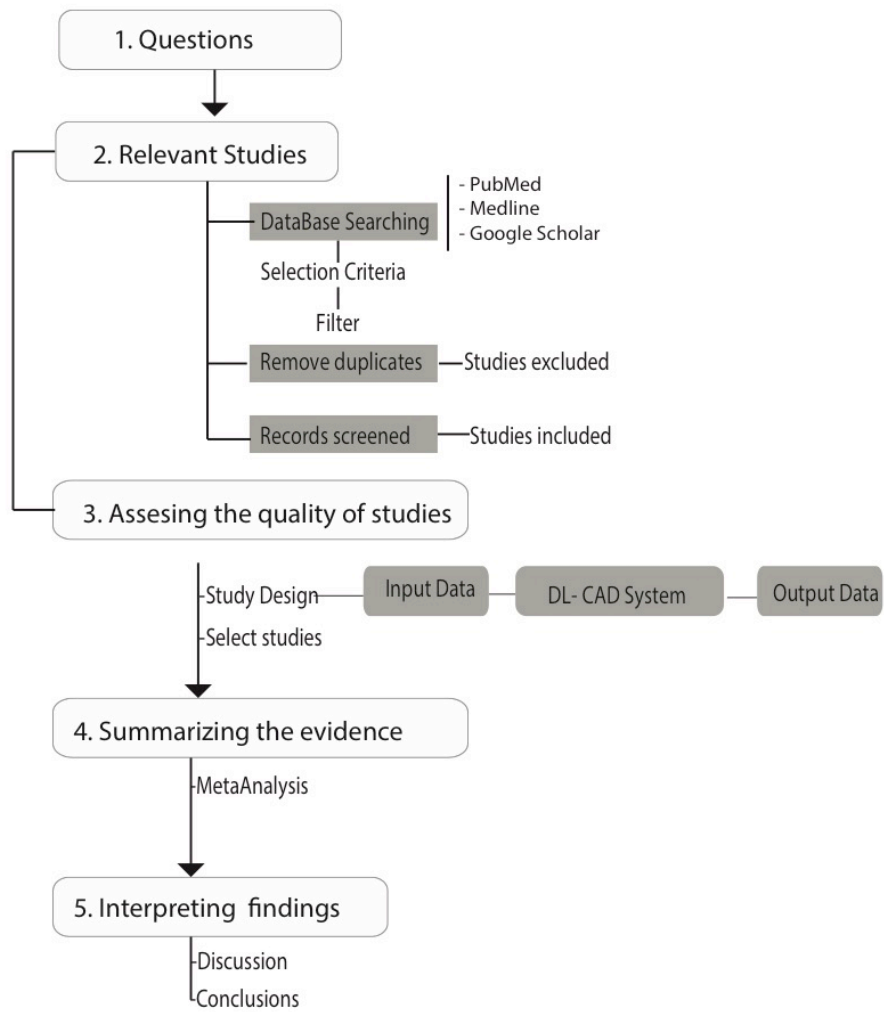


Fig 2. This Flowchart diagram represents the review process of articles in this paper

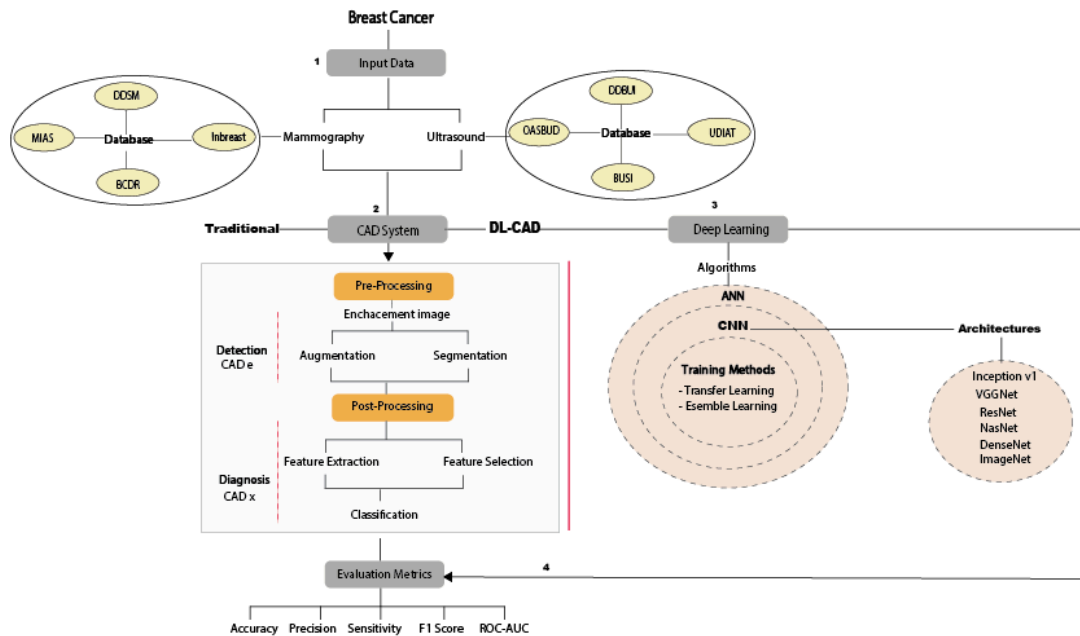


Fig 3. The general diagram is a flowchart which describes how an CAD system process can be used with DM and US images from public and private databases.. Normally, the CAD system consists of several stages such us segmentation, feature extraction-selection and classification. However, DL-CAD systems are based on CNN models and architectures to feature extraction-selection and classification with convolutional and fully connected layers automatically through a self-learning. Finally, CAD systems are validated by different metrics.

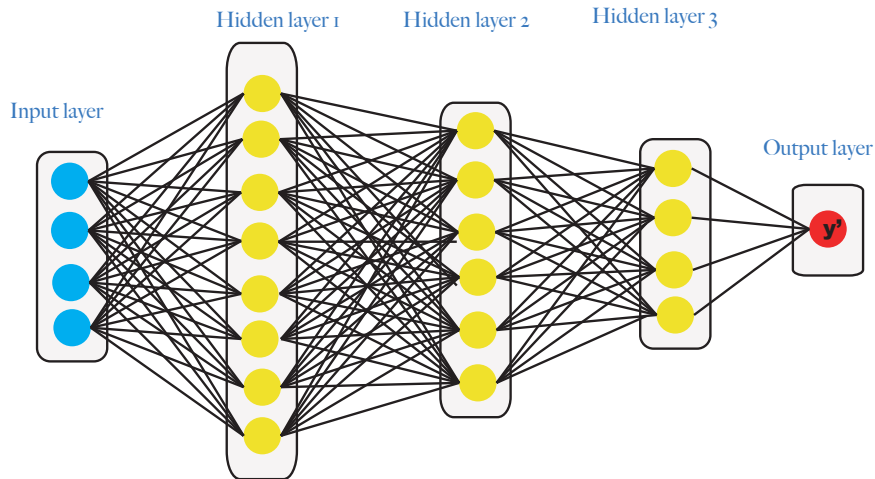


Fig 4. Artificial Neural Network (ANNs). It learns by processing images, each of which contains input, hidden and result layer.

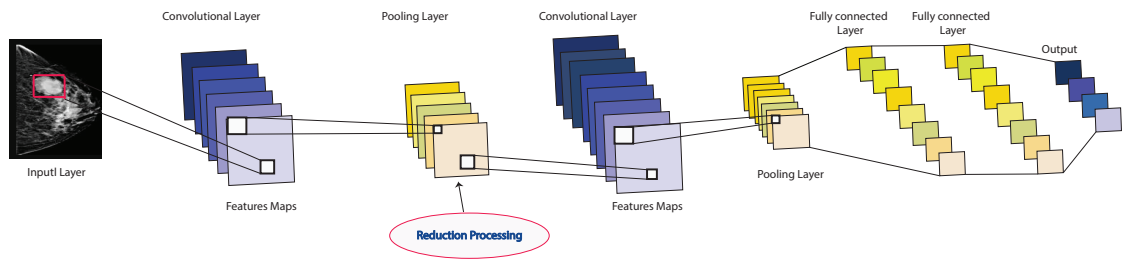


Fig 5. A feed-forward CNN network, where the convolutional layers are the main components, followed by a nonlinear layer (ReLU), pooling layer for feature map extraction, loss function (Softmax) and the fully connected layers for classification. The output can be benign or malignant classes.

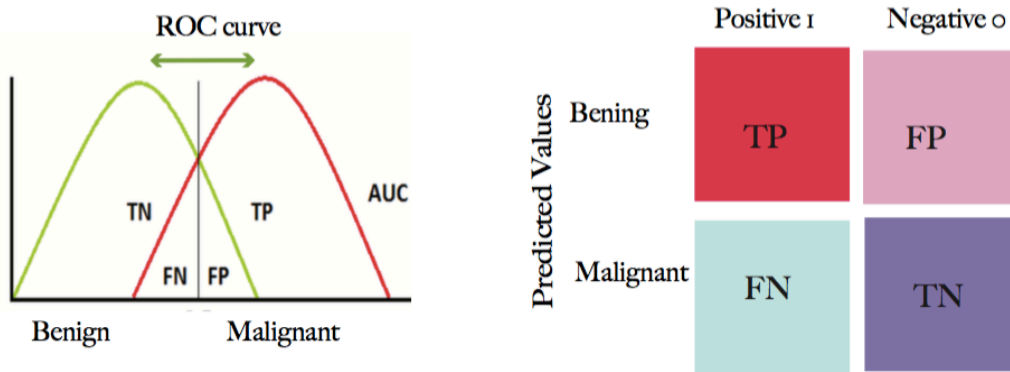


Fig 6. The confusion matrix regarding to the *Receiver Operating Characteristic Curve*. The number of images correctly predicted by the classifier is located on the diagonal. ROC curve utilizes TPR in the y-axis and the FPR fraction in the x-axis.

TABLES

Table 1. Summary of public breast cancer databases, most commonly used in the literature.

Type	Database	Annotations	Link	Author
Mammograms	DDSM	2620 patients including MLO and CC	http://www.eng.usf.edu/cvprg/Mammography/Database.html	Jiao et al. [58]
	BCCR	736 biopsy prove lesion of 344 patients including CC, MLO	https://bcdr.eu/	Arevalo et al. [59]
	INbreast	419 cases including CC, MLO of 115 patients	http://medicalresearch.inescporto.pt/breastresearch/index.php/Get_INbreast_Database	IMoreira et al. [60]
	Mini-MIAS	322 digitized MLO images of 161 patients	http://peipa.essex.ac.uk/info/mias.html	Peng et al. [61]
Ultrasound	BUSI	The dataset consist in 600 female patients. The 780 images including 133 normal images without masses, 437 images with cancer masses, and 210 images with benign masses	https://scholar.cu.edu.eg/?q=afahmy/pages/dataset	Dhabyani et al. [62]
	DDBUI	285 cases and 1132 images in total.	https://www.atlantispress.com/proceedings/jcis2008/1735	Tian et al. [63]
	Dataset A	Private dataset with 306 (60 malignant and 246 benign) images.	goo.gl/SJmoti	Yap et al. [64]
	Dataset B	Private dataset with 163 (53 malignant and 110 benign) images.		Prapavesis et al. [57]
	SNUH	Private dataset with a total of 1225 patients, with 1687 tumors with biopsy-proven diagnosis were included in this study.		Moon et al [40]
	OASBUD	52 malignant and 48 benign masses	Zenodo repository (DOI: 10.5281/zenodo.545928) website http://bluebox.ippt.gov.pl/~hpiotrk	Piotrkowska et al.[65]
	ImageNet	882 US images, consisting of 678 benign and 204 malignant lesions.	http://www.image-net.org/	Deng et al. [66]

Table 2. Summary of CNN architecture information for breast imaging processing

Reference	Model	Description	Way of training	Application
Krizhevsky et al. [111]	AlexNet	AlexNet is a deep CNN architecture and a winning model in the 2012 ImageNet Large Scale Visual Recognition Challenge [112]. Consist of 8 neural network layers, 5 convolutional. Some of which are followed by max-pooling layers, and 3 fully-connected layers with a final 1000-way softmax. The Deep CNN was evaluated in Imagenet LSVRC-2010 dataset with a top-1 and top-5 error rates of 37.5% and 17.0%. And ILSVRC-2012 achieved a winning top-5 test error rate of 15.3%, compared to 26.2%	Training from dropout model to reduce overfitting in the fully-connected layers	ImageNet classification
Samala et al [113]	DL-CNN	(CAD) system for masses in digital breast tomosynthesis (DBT) volume using a Depp CNN with transfer learning from mammograms. The performance of the trained DL-CNN and CNN for classification of the true microcalcifications and false positives in the test set is compared in terms of the area under the receiver operating characteristic (ROC) curve (AUC). The best AUC of 0.933 was obtained for the number of filters of (32, 32, 32, 32) with filter kernel sizes of 5, 5 and partial sum values of 18, 16 for the two convolution layers, respectively. The improvement was statistically significant ($p < 0.05$).	Training from CNN architecture with two hidden layers 12 and 8 node groups with filter kernel of 5 and 3 respectively. The classification performance of this CNN was compared with DL-CNN	Image detection in breast tomosynthesis from DM
Simoyan et al. [114]	VGG-VD	The very deep CNN models (VGG-VD16, VGG-VD19 [115]) were evaluated in ILSVRC-2014	Training from Deep ConvNet architecture with 19 weight layers for largescale image classification	ImageNet classification
He et al. [116]	ResNet	These ResNet are easier to optimize, and can gain accuracy from considerably increased depth. An ensemble of these residual nets achieves 3.57% error on the ImageNet (ILSVRC 2015) test set. Evidence shows that the best ImageNet models using convolutional and fully-connected layers typically contain between 16 and 30 layers.	Training on the ImageNet dataset and evaluated by ResNet with a depth of up to 152 layers 8× deeper than VGG nets but still having lower complexity.	Imagenet recognition
Huang et al.[117]	DenseNet	Dense Convolutional Network (DenseNet), which connects layers in a feed-forward fashion way. Also, alleviate the vanishing-gradient problem, strengthen feature propagation, encourage feature reuse and substantially reduce the number of parameters.	Training on CIFAR-10, CIFAR-100, SVHN, and ImageNet with CNN with L layers and L connections. The network has L (L+1)/2 direct connections. For each layer, the feature-maps of all preceding layers are used as inputs, and its own feature-maps are used as inputs into all subsequent layers.	Object recognition
Szegedy et al. [27, 118]	Inception v5	A deep CNN architecture for classification and detection in the ImageNet Large-Scale Visual Recognition Challenge 2014 (ILSVRC14) was proposed.	Training on Deep CNN, the main hallmark of this architecture is the improved utilization of the computing resources inside the network.	ImageNet clasification
Das et al [119]	VGGNet	BreakHist dataset with 58 malignant and 24 benign cases was evaluated with Deep CNN. The best accurate percentage was reached with 100x (89.06%).	Training from Multiple instances learning (MIL) architecture for CNN by designing a new pooling layer as multiple pooling layer (MPL) in torch 7.	Histopathology

Cao et al [120]	Deep CNN	Private dataset collected in Sichuan Provincial Hospital. Contains 577 benign and 464 malignant,	<p>Training protocols for detection are Fast Region based CNN, Faster R-CNN, YOLO v3, SSD. YOLO and SSD perform significantly better than other methods.</p> <p>Training protocols for classification are AlexNet, VGG, ResNet, GoogleNet, ZFNet and Densenet. Here DenseNet achieves best results than others methods.</p>	US lesion detection and classification.
Chiao et al. [121]	Deep CNN	Private imaging dataset, collected from China medical University Hospital. Contains 307 images of ultrasound with 107 benign and 129 malignant.	<p>Training from Mask R-CNN with ROI alignment to avoid the loss of spatial information.</p> <p>Based on Faster R-CNN using region proposal network (RPN) to extract features.</p>	Sonogram (ultrasound) lesion detection and classification.
Yap et al. [64]	LeNet UNet	CNNs have become an important technique in image analysis, particularly in image analysis. However, it has not been used in breast ultrasound lesion detection. For these reasons, this work studies the performance of CNNs in breast US lesion detection.	Deep learning approaches for breast US lesion detection in three different methods LeNet [122], U-Net [123] and transfer Learning [124], their performance is compared in two private datasets A and B	Breast lesion detection using US
Geras, K. et al. [167]	Multi-view DL-CNN	INBreast [58] and DDSM [60] databases were used in the research. As a result of this technique the size of features maps were greatly reduce, and the model achieved the AUC of 0.68%.	The network is trained jointly by stochastic gradient descent with back propagation [168] and data augmentation by random cropping [169]. Finally, a CNN aggressive with pooling layers was used for improving High-resolution [167].	High Resolution, augmentation and DM classification.
Han, S. et al [170]	Google Net with Ensemble learning	Dataset was built from 5151 patients' cases with a total of 7408 US breast images. Where 6579 were used as training set, 829 as test set (489 benign lesions and 340 malignant lesions).	CNN was training to differentiate malignant from benign tumors with optimal parameters as 10-fold cross validation. Data augmentation was necessary to make more robust the variability of breast tumor, employing the Caffe method. As results the mean accuracy reached 90.21% with 1 channel.	Data augmentation, detection and classification of breast lesions in US.
Dhungel, N. et al [172]	LeNet for CNN models in cascade	INbreast dataset was used, with 115 cases and 410 images (116 cases contains benign or malign masses and the remaining ones do not contain any masses), from MLO and CC views.	For detection a cascade of DL methods (Fast R-CNN, Multi scale Deep Belief Network m-DBN, Random Forest) were used to select hypotheses based on Bayesian Optimization (Gaussian Mixture Model, GMM).	Detection, segmentation and classification of masses in DM.

			<p>For segmentation a Deep structured output (Conditional Random Forest, CRF) learning was used.</p> <p>For classification methodology two steps were proposed based on regression, 1. Pre training of CNN model and 2. Fine-tuning the pre-training data.</p> <p>The final results showed that DL-CAD system is able to detect 90% of masses at one FPR per image, with segmentation accuracy of 85%, where the final classification (into benign or malignant) for the detected masses reached sensitivity of 0.98 and specificity of 0.7</p>	
Singh, V. K. Et al [173]	Generative Adversial Network (GAN)	The Mendeley database [174] was used, it contains 150 malignant and 100 benign tumors. Where the 70% was training set, the other 20% validation and the remaining 20%.	The experts first had manually segmented tumors. Then data augmentation was carried out by scale the images, gamma correlation, flip and rotate image. Finally, the segmentation was carried out with GAN learning. The metrics used to evaluate the performance were Dice and Intersection Over Union (IoU), it achieves scores of 93.76% and 88.82% respectively.	Breast tumor segmentation and classification in US images.
Cheng, J. Z. [175]	Stacked denoising auto-encoder (SDAE) based - CADx	The LIDC private database form Taipei Veterans General Hospital Taiwan was used, with 520 breast sonograms (275 benign and 245 malignant lesions)	A CNN model called OverFeat was used to classify nodules with the esemble method. The AUC performance reached around of 0.80. Furthermore, SDAE model was used to differentiate between distinctive types of lesions and nodules.	Breast lesion /nodules diagnosis in US images

Table 3. Confusion matrix for a binary classifier to distinguish between two classes bening and malignant; where TP: is the number of True Positives; FN; False Negative; FP: False positive; TN: True Negative; TPR (true positive rate); FPR(false positive rate).

Classes	Predicted classes		Equation
	C ₁	C ₂	
C ₁ (Bening)	TP	FN	$TPR = \left(\frac{TP}{TP + FN} \right)$
C ₂ (Malignant)	FP	TN	$FPR = \left(\frac{FP}{FP + TN} \right)$

Table 4. Validation assessment measures.

Model	Equation
<i>Accuracy</i>	$Acc = \left(\frac{TP + TN}{TP + TN + FP + FN} \right)$
<i>Sensitivity</i> TPR or	$Sen = \left(\frac{TP}{TP + FN} \right)$
<i>Specificity</i> TNR or	$Spe = \left(\frac{TN}{TN + FP} \right)$
<i>Precision</i>	$Precision = \left(\frac{TP}{TP + FP} \right)$
<i>F1 Score</i>	$F1score = 2 \times \left(\frac{precision \times recall}{precision + recall} \right)$
<i>MCC</i>	$MCC = \frac{TP \times TN - FP \times FN}{\sqrt{(TP + FP)(TP + FN)(TN + FP)(TN + FN)}}$

Table 5. Quantitative indicators used to evaluate the performance between different CNN architectures in DM datasets.

Reference	Database	Deep CNN Model	ACC %	SEN %	SPEC %	Precision %	F1 Score %	AUC %
Al-Masni et al [127]	DDSM with 600 mamograms	CNN YOLO5- Fold cross validation in both datasets.		93.20	78	-	-	87.74
		CAD mass detection	96.73					
	CAD mass classification	85.52						
	DDSM augmentation with 2.400 mamograms	CAD mass detection	97	100	94	-	-	96.45
		CAD mass classification	99					
Ragab et al [126]	DDSM with 2620 cases	Depp CNN based Linear SVM						
		ROI Manually						
	ROI threshold	79	76.3	82.2	85	80	88	
CBIS- DDSM with 1644 cases			80.5	77.4	84.2	86	81.5	88
		SVM based médium Gaussian	87.2	86.2	87.7	88	87.1	94
Duggento et al. [128]	CBIS-DDSM	CNN	71	84.4	62.4			77
Chougrad et al. [129]	BCCR	Deep CNN Inceptionv3	96.67	-	-	-	-	96
	DDSM		97.35	-	-	-	-	98
	INbreast		95.50	-	-	-	-	97
	MIAS		98.23	-	-	--		99

Table 6. Quantitative indicators used to evaluate different CNN architectures performance in US datasets.

Reference	Database	Deep CNN Model	ACC %	SEN %	SPEC %	Precision %	F1 Score %	AUC %
Kyung et al [27]	BUSI SNUH	VGGNet Like	84.57	73.65	93.12	89.34	80.74	91.98
		VGGNet 16	84.57	73.64	93.12	89.34	80.74	93.22
		ResNet 18	81.60	86.49	77.77	75.29	80.50	91.85
		ResNet 50	81.60	75.68	86.24	81.16	78.32	88.83
		ResNet 101	84.57	75.00	92.06	88.10	81.02	91.04
		DenseNet 40	85.46	79.05	90.48	86.67	82.69	93.52
		DenseNet 12	86.35	77.70	93.12	89.84	83.33	92.48
		DenseNet 161	83.09	69.59	93.65	89.57	78.33	89.18
Byra et al. [130]	ImageNet	VGG 19 combined with the Matching layer.	88.7	0.848	0.897	-	-	93.6
	UDIAT		84	0.851	0.834	-	-	89.3
	OASBUD[115]		83	0.807	0.854	-	-	88.1
Cao et al [120]	Private dataset consistin of 579 benign and 464 malignant cases.	Single Shot MultiBox Detector (SSD)300+ZFN	96.89	67.23	-	-	79.38	-
		YOLO	96.81	65.83	-	-	78.37	-
		SSD300 +VGG16	96.42	66.70	-	-	78.85	-
Han et al [53]	Private database with 5151 patients, with a total of 7408 US mages. 4254 benign and 3154 malignant lesions.	CNN-based GoogleNet	91.23	84.29	96.07	-	-	91
Shan et al [131]	Private database, contains 283 breast US images, collected by the Second Affiliated Hospital of Harbin Medical University (Harbin, China) Among them, 133 cases are benign and 150 cases are malignant.	ANN	78.1	78	78.2	-	-	82.3

Table 7. DL- CAD system vs traditional methods

Reference	Application	Method	Dataset	ACC %	SEN %	SPEC %	AUC %	Error %
Dheeba [135]	DM classification	Wavelet Neural Network	Private database consisting of 216 images of 54 patients taken in two different views CC and MLO.	93.671	94.167	92.105	96.853	0.96853
Trivizakis et al. [137]	DM classification	ML with transfer learning and feature-based with ImageNet and CNN architecture of 15 layers.	Mini MIAS 16 patients with 322 mammograms DDSM 2,500 patients with 10,239 multi-view images including benign, malignant and normal cases.	79.3	-	-	84.2	-
				74.8	-	-	78.00	-
Samala et al [138]	DM classification	Multi-task transfer learning framework to transfer knowledge learned from non-medical images by a Deep CNN.	ImageNet	90	-	-	82	-
Jadoon et al. [139]	DM Extraction	CNN discrete wavelet CNN curvelet transform, with SVM for classification	IRMA with 2796 mammogram images, including 2,576 images from DDSM, 150 images from MIAS.	81.83	-	-	83.1	15.43
				83.74	-	-	83.9	17.46
Debelee et al. [136]	DM Extraction	CNN based SVM	MIAS (61 DM)	97.46	96.26	100	-	-
			DDSM(320 DM, 112 abnormal and the rest are normal)	99	99.48	98.16	-	-
		MLP	MIAS	87.64	96.65	75.73	-	-
			DDSM	97	97.40	96.26	-	-
		KNN-SVM	MIAS	91.11	86.66	100	-	-
			DDSM	97.18	100	95.65	-	-
Ahmed et al. [140]	DM detection	Deep CNN with 5 – fold cross validation	INbreast	80.10	80	-	78	-
Yuan Xu et al [141]	US image segmentation	CNNs 8-layer with convolutional and pooling layer 1-3, fully connected layer and softmax layer. Inputs of 128 x 128	Private 3D breast US	90.13	88.98	-	-	-
Shan et al [142]	US image segmentation	ML methods: Decision tree	Private breast US consisting of 283 images with 133 cases are benign and 150 cases are malignant.	77.7	74.0	82.0	80	-
		ANN		78.1	78.0	78.2	82	-
		Random forest		78.5	75.3	82.0	82	-
		SVM		77.7	77.3	78.2	84	-
Gu et al [143]	3D US image segmentation	Pre-processing with morphological reconstruction minimizes the speckle noise and segmentation with region-based approach.	Private database with 21 cases, with masses prior of biopsy. Each case contains 250 slices.	85.7	-	-	-	-
Zhang et al	US image	Two-layer DL architecture for US (elastography) feature extraction and	The private dataset consisting of 121 female patients, with a total of 227 shear-wave elastography images, 135 of benign tumors	93.4	88.6	97.1	94.7	-

[144]	classification	classification, comprised of the point-wise gated Boltzmann machine (PGBM) and the restricted Boltzmann machine (RBM). Experimental evaluation was performed with five-fold cross validation on the dataset.	and 92 of malignant tumors.					
Almajalid et al. [145]	US image segmentation	DL architecture u-net, for breast ultrasound imaging. U-net is a convolutional neural network with two-fold cross validation designed for biology image segmentation with limited training data.	The private dataset contains 221 BUS images, collected from the Second Affiliated Hospital of Harbin Medical University in China.	82.52	78.66	18.59	-	-
Singh et al. [146]	US image classification	Classification technique by combining an unsupervised learning technique (i.e. fuzzy c-means clustering (FCM)) and supervised learning technique (i.e. back-propagation artificial neural network (BPANN))	178 B-mode breast US containing 88 benign and 90 malignant cases	95.86	95.14	96.58	95.85	-
Cheng et al [147]	US (sonograms) classification	DL architecture with Stacked denoising Autoencoder (SDAE)	520 breast sonograms were scanned from 520 patients. The data involves 275 benign and 245 malignant lesions.	82.4	78.7	85.7	89.6	-
Shi, et al [148]	US image classification	Deep polynomial network	A total of 200 pathology-proved breast US images (100 benign masses and 100 7 malignant tumors	92.40	92.67	91.36	-	-