

# Towards Automatic Lesion Classification in the Upper Aerodigestive Tract Using OCT and Deep Transfer Learning Methods

Nils Gessert<sup>1</sup> · Matthias Schlüter<sup>1</sup> · Sarah Latus<sup>1</sup> · Veronika Volgger<sup>2</sup> · Christian Betz<sup>3</sup> · Alexander Schlaefer<sup>1</sup>

Preprint, submitted to CARS 2019, accepted for publication

**Abstract** Early detection of cancer is crucial for treatment and overall patient survival. In the upper aerodigestive tract (UADT) the gold standard for identification of malignant tissue is an invasive biopsy. Recently, non-invasive imaging techniques such as confocal laser microscopy and optical coherence tomography (OCT) have been used for tissue assessment. In particular, in a recent study experts classified lesions in the UADT with respect to their invasiveness using OCT images only. As the results were promising, automatic classification of lesions might be feasible which could assist experts in their decision making. Therefore, we address the problem of automatic lesion classification from OCT images. This task is very challenging as the available dataset is extremely small and the data quality is limited. However, as similar issues are typical in many clinical scenarios we study to what extent deep learning approaches can still be trained and used for decision support.

**Keywords** UADT · Invasive Lesions · Deep Learning · OCT

## 1 Methods

We use the data set from the study performed by Volgger et al. [1] which contains 100 lesions with 91 benign and 9 invasive lesions. Example images are shown in Figure 1. An invasive lesion is characterized by the absence of a clear border between the epithelial layer and the lamina propria. This notable difference should be a learnable feature from the images. The binary ground-truth labels were obtained by histological evaluation of a biopsy taken after OCT imaging. Due to

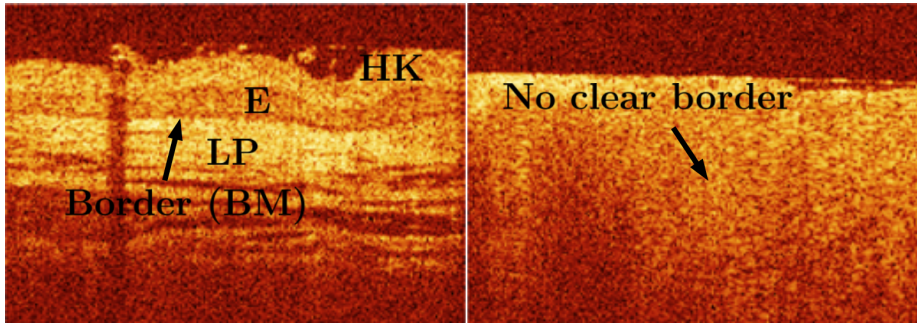
---

✉ Nils Gessert, E-mail: nils.gessert@tuhh.de, Tel.: +49 (0)40 42878 3389, <https://orcid.org/0000-0001-6325-5092>

<sup>1</sup> Hamburg University of Technology, Hamburg, Germany

<sup>2</sup> Ludwig-Maximilians-Universitt Mnchen, Clinic and Polyclinic for Otolaryngology, Munich, Germany

<sup>3</sup> University Medical Center Hamburg-Eppendorf, Clinic and Polyclinic for Otolaryngology, Hamburg, Germany



**Fig. 1:** Left, a hyperkeratotic lesion at the floor of the mouth is shown. BM denotes the basement membrane, LP denotes the lamina propria, E denotes the epithelial layer and HK denotes hyperkeratosis. Right, an invasive lesion at the floor of the mouth is shown. There is no clear border between the epithelial layer and the lamina propria.

the small size of the data set, we use a form of leave-one-invasive-lesion-out cross-validation, i.e., we construct 8 validation splits with 1 invasive and 9 benign lesions each. We employ the state-of-the-art deep learning models Resnet18, Densenet121 and SE-ResNeXt50 which are pretrained on ImageNet for transfer learning which has been successful for OCT classification tasks [2]. The OCT images are resized from 260x180 pixels to 224x224 pixels using bilinear interpolation to match the models standard input size. The classification layer is replaced by a layer with two outputs. We consider transfer learning with fine-tuning of all weights and a variant where we only retrain the classifier. For comparison, we also train the models from scratch. We employ online data augmentation with random flipping along the horizontal dimension and we apply random changes in brightness, contrast and saturation. Furthermore, we use regularization with dropout ( $p = 0.2$ ) and a small batch size ( $b = 5$ ), which induces more variation during optimization. We use Adam for optimization with a very small learning rate of  $10 \times 10^{-6}$ . As the two classes are highly unbalanced, we employ loss balancing with the normalized inverse class frequency as a weight factor in the loss function. For evaluation, we report the sensitivity, specificity, accuracy and F1-score.

## 2 Results

The results are shown in Table 1. We compare to the mean sensitivity and specificity of human raters reported in [1]. As expected, training from scratch is not very successful as the performance across all metrics is low with an accuracy of 60% and a sensitivity of 37.50%-50%. Also, transfer learning with fine-tuning of all weights only improves performance marginally. Retraining the classifier only achieves a reasonable performance with a sensitivity and specificity of 75.00% and 82.76% for SE-ResNeXt50 which is similar to the average human rater with a sensitivity of 81.50% and a specificity of 72.50%. All three architecture variants perform similar across the different training scenarios and the highest sensitivity is achieved by the average human rater. It is notable that SE-ResNeXt50 performs best for this problem while also being the most recent and best performing model on ImageNet out of the three models we chose.

**Table 1:** Results in percent for different training scenarios and models compared to the average human rater in [1]. We compare training from scratch (SCR), transfer learning with fine-tuning (FT) and retraining of only the classifier (RC). The values are the mean for leave-one-invasive-lesion-out cross-validation.

	Accuracy	Sensitivity	Specificity	F1-Score
Densenet121 SCR	60.18	37.50	69.63	61.00
Densenet121 FT	64.10	50.00	58.17	62.74
Densenet121 RC	77.10	75.00	77.32	73.18
Resnet18 SCR	60.90	50.00	60.98	60.06
Resnet18 FT	55.63	62.50	54.25	52.01
Resnet18 RC	76.10	75.00	79.65	75.42
SE-Resnext50 SCR	60.19	37.50	68.17	62.09
SE-Resnext50 FT	66.19	62.50	69.73	64.27
SE-Resnext50 RC	82.76	75.00	84.95	81.98
Human Rater	-	81.50	72.50	-

### 3 Conclusions

We consider the problem of automatic lesion classification in the UADT using OCT images and deep learning despite facing the challenge of a very small dataset. We tackle this issue with transfer learning techniques, data augmentation and regularization. Our results show that a model where only the classifier is retrained performs similar to the average human rater from a previous study. Training the model from scratch and also transfer learning with fine-tuning of all weights, a typical approach for medical image classification [2], fails in this case. This is likely caused by the small dataset size. Our results with a retrained classifier indicate that OCT combined with deep learning methods might be useful to assist experts in their decision making when assessing lesions in the UADT. This holds true for three recent architectures. Moreover, a larger dataset of high quality full resolution OCT images will likely improve the classification performance.

### References

1. Volgger, V., Stepp, H., Ihrler, S., Kraft, M., Leunig, A., Patel, P.M., Susarla, M., Jackson, K., Betz, C.S. (2013) Evaluation of optical coherence tomography to discriminate lesions of the upper aerodigestive tract. *Head & Neck* **35**(11), 1558–1566
2. Gessert, N., Lutz, M., Heyder, M., Latus, S., Leistner, D.M., Abdelwahed, Y.S., Schlaefer, A. (2019) Automatic plaque detection in ivoct pullbacks using convolutional neural networks. *IEEE transactions on medical imaging* **38**(2), 426–434