

# ISLES'24: Improving final infarct prediction in ischemic stroke using multimodal imaging and clinical data

Ezequiel de la Rosa<sup>a,\*</sup>, Ruisheng Su<sup>b</sup>, Mauricio Reyes<sup>c,d</sup>, Roland Wiest<sup>e,f</sup>, Evamaria O. Riedel<sup>i</sup>, Florian Kofler<sup>a,i,l</sup>, Kaiyuan Yang<sup>a</sup>, Hakim Baazaoui<sup>g</sup>, David Robben<sup>j</sup>, Susanne Wegener<sup>g,h</sup>, Jan S. Kirschke<sup>i,k</sup>, Benedikt Wiestler<sup>†k,m</sup>, Bjoern Menze<sup>†a</sup>

<sup>a</sup>Department of Quantitative Biomedicine, University of Zurich, Zurich, Switzerland.

<sup>b</sup>Medical Image Analysis group, Department of Biomedical Engineering, Eindhoven University of Technology, Eindhoven, the Netherlands.

<sup>c</sup>ARTORG Center for Biomedical Research, University of Bern, Bern, Switzerland.

<sup>d</sup>Department of Radiation Oncology, University Hospital Bern, University of Bern.

<sup>e</sup>Support Center of Advanced Neuroimaging (SCAN), University Institute of Diagnostic and Interventional Neuroradiology, Inselspital, Bern, Switzerland.

<sup>f</sup>University Institute of Diagnostic and Interventional Neuroradiology, University Hospital Bern, Inselspital, University of Bern, Bern, Switzerland.

<sup>g</sup>Department of Neurology, University Hospital of Zurich, Zurich, Switzerland.

<sup>h</sup>University of Zurich, Zurich, Switzerland.

<sup>i</sup>Department of Diagnostic and Interventional Neuroradiology, School of Medicine and Health, Klinikum rechts der Isar, Technical University of Munich, Germany.

<sup>j</sup>icomatrix, Leuven, Belgium

<sup>k</sup>TranslaTUM, Center for Translational Cancer Research, Technical University of Munich, Germany.

<sup>l</sup>Helmholtz AI, Helmholtz Munich, Germany.

<sup>m</sup>AI for Image-Guided Diagnosis and Therapy, School of Medicine and Health, Technical University of Munich, Munich, Germany.

---

## Abstract

Accurate estimation of core (irreversibly damaged tissue) and penumbra (salvageable tissue) volumes is essential for ischemic stroke treatment decisions. Perfusion CT, the clinical standard, estimates these volumes but is affected by variations in deconvolution algorithms, implementations, and thresholds. Core tissue expands over time, with growth rates influenced by thrombus location, collateral circulation, and inherent patient-specific factors. Understanding this tissue growth is crucial for determining the need to transfer patients to comprehensive stroke centers, predicting the benefits of additional reperfusion attempts during mechanical thrombectomy, and forecasting final clinical outcomes. This work presents the ISLES'24 challenge, which addresses final post-treatment stroke infarct prediction from pre-interventional acute stroke imaging and clinical data. ISLES'24 establishes a unique 360-degree setting where all feasibly accessible clinical data are available for participants, including full CT acute stroke imaging, sub-acute follow-up MRI, and clinical tabular data. The contributions of this work are two-fold: first, we introduce a standardized benchmarking of final stroke infarct segmentation algorithms through the ISLES'24 challenge; second, we provide insights into infarct segmentation using multimodal imaging and clinical data strategies by identifying outperforming methods on a finely curated dataset. The outputs of this challenge are anticipated to enhance clinical decision-making and improve patient outcome predictions. All ISLES'24 materials, including data, performance evaluation scripts, and leading algorithmic strategies, are available to the research community following <https://isles-24.grand-challenge.org/>.

**Keywords:** Ischemic stroke, Lesion segmentation, Final infarct, Multimodal data

---

\*Corresponding author: ezequiel.delarosa@uzh.ch

\*\*†Equal contribution

## 1. Introduction

Accurate segmentation of ischemic stroke lesions is crucial for guiding treatment decisions during acute stages (e.g., determining eligibility for thrombectomy), evaluating outcomes, clinical follow-up, and optimizing therapeutic strategies in sub-acute and chronic stages. The Ischemic Stroke Lesion Segmentation (ISLES) Challenge (<https://www.isles-challenge.org/>) significantly advances stroke image analysis by bringing together experts in neurointervention, radiology, and computer science from top institutions. Biomedical challenges like ISLES are now considered the *de facto* gold standard for algorithm comparison by the research community and have been organized multiple times, covering diverse pathologies and imaging modalities, thereby further cementing their role in advancing medical imaging technologies [1, 2, 3, 4, 5, 6].

The ISLES Challenge has been a recurring feature at MICCAI. The inaugural ISLES’15 focused on segmenting sub-acute ischemic stroke lesions from post-interventional MRI and acute perfusion lesions from pre-interventional MRI [7]. Subsequent challenges, ISLES’16 and ISLES’17, emphasized stroke outcome prediction by requiring the segmentation of follow-up stroke lesions from acute multimodal MR imaging and estimating patient disability scores [8]. ISLES’18 addressed acute stroke segmentation indirectly and cross-modally by predicting core tissue delineated in concomitant MRI from acute perfusion CT series [9]. The latest ISLES’22 expanded to segment acute, sub-acute, and chronic ischemic strokes in over 2000 MRI scans [10, 11, 12]. Thus, the ISLES Challenge has garnered considerable attention over the years.

Building on this rich history, ISLES’24 aims to segment the final stroke infarct using pre-interventional acute stroke data. Unlike standard clinical imaging techniques for core estimation, participants have access to the full CT trilogy (non-contrast CT (NCCT), CT angiography (CTA), and perfusion CT (CTP)); follow-up imaging data (DWI and ADC); and clinical tabular data (demographics, clinical history, laboratory results, and stroke outcomes). This creates a unique 360-degree challenge setting where all feasibly accessible clinical data are available for participants. Additionally, ISLES’24 enables the combination and learning from diverse CT techniques with and without contrast, evaluation of brain tissue changes before and after recanalization treatment through follow-up imaging, and inclusion of variables known to impact ischemic tissue status. This comprehensive approach allows participants to refine segmentation models through multimodal data learning strategies. In brief, the main contributions of this work are three-fold:

1. The standardized benchmarking of final, post-treatment stroke infarct segmentation algorithms through the ISLES’24 challenge (<https://isles-24.grand-challenge.org/>).
2. Performance evaluation of multimodal imaging and clinical data strategies over a finely curated stroke dataset, including clinical data, acute (NCCT, CTA, CTP), and follow-up (DWI, ADC) stroke imaging.
3. The open access provision of ISLES’24 materials for the research community, including data, performance evaluation scripts, and leading algorithmic strategies.

## 2. Related work

### 2.1. Final infarct prediction using perfusion CT

Perfusion CT is the reference imaging modality for predicting stroke lesion volumes in clinical settings. The workflow involves estimating perfusion maps using established deconvolution approaches and then deriving penumbra and core volumes through thresholding [13]. Although the preferred perfusion map for initial infarct (core) estimation varies among software vendors, cerebral blood flow (CBF) and cerebral blood volume maps have been widely adopted. In the last years, various studies propose deep-learning methods for estimating stroke lesions. For instance, de la Rosa et al. [14] propose a deep-learning enhanced SVD-deconvolution method to estimate core tissue. Robben et al. [15] bypass traditional deconvolution by predicting final infarct volumes using native CT Perfusion images and clinical metadata. Their approach combines diverse inputs—CTP, time and treatment parameters, and CTP-derived vascular functions—into a DeepMedic-based model [16], allowing for the simulation of diverse clinical scenarios. Validation of their model over clinical data shows improved estimation of final infarct compared to traditional deconvolution software. Building on this foundation, Amador et al. [17, 18] introduce a deep spatio-temporal CNN to predict final infarct from raw perfusion data. Their model combines a U-Net-like architecture with temporal convolutional networks to efficiently process 4D data. de Vries et al. present PerfU-Net [19], a spatio-temporal model for estimating core tissue from CTP imaging data. PerfU-Net employs a U-Net-based architecture enhanced

with an attention module, allowing it to capture dynamic perfusion patterns. Vision transformers have been introduced for infarct segmentation by de Vries et al. [20] and have been later combined with CNN models through hybrid methods in [21]. Gutierrez et al. [22] propose the prediction of follow-up CT images from CTP data using spatio-temporal models, from which the final infarct can be derived from the generated pseudo-CT images. More recently, by leveraging physics-informed neural networks, de Vries et al. [23, 24] show promising results while using a hybrid data-driven image modeling approach.

### *2.2. Beyond ASPECTS: Final infarct segmentation using non-contrast CT*

Machine and deep learning strategies for infarct segmentation have increasingly been applied to native NCCT due to its broader availability compared to advanced imaging techniques like CTA and CTP. While NCCT reveals infarcted brain tissue as hypodense areas, these changes typically become visible later than those observed with perfusion imaging. Early ischemic changes on NCCT are challenging due to low signal-to-noise ratio, subtle signals, artifacts, and confounding factors [25]. In this context, Srivatsan et al. [26] proposed an image-processing technique for segmenting early ischemic changes by creating a relative NCCT map that highlights subtle hypoattenuation differences between contralateral hemispheres. Qiu et al. [27] trained a standard U-Net model to segment ischemia. Their model, validated over 100 independent scans, demonstrated high volumetric agreement with DWI-derived annotations. Similarly, El-Hariri et al. [28] assessed the performance of the self-adapting nnU-Net model, showcasing high volumetric agreement with ground truth and intraclass correlations over 80%. In 2021, Pan et al. [29] tested a ResNet-based CNN combined with a maximum a posteriori probability model. Later on, Kuang et al. introduced EIS-Net, a multi-task learning model designed to simultaneously segment early infarcts and score the Alberta Stroke Program Early CT Score (ASPECTS) [30]. EIS-Net employs a 3D triplet convolutional neural network that incorporates original and mirrored NCCT images along with an atlas to improve feature extraction. This model excelled in both segmentation and ASPECTS scoring tasks, showing high volumetric agreement with ground-truth annotations and accurate ASPECTS ratings. Wang et al. [31], instead, showed marginal gains of a SwinUNETR model compared to a traditional U-Net method. More recently, Kuang et al. [32] leveraged circular feature interaction and bilateral difference learning in a hybrid CNN-Transformer model to segment ischemia on NCCT.

### *2.3. CTA-based final infarct prediction*

CTA is a vital imaging modality in stroke management, primarily used to assess cerebral vasculature and identify large vessel occlusions (LVOs). While CTA is traditionally employed for diagnostic purposes, several studies have revealed the potential of CTA-derived features in infarct prediction [33, 34]. Unlike perfusion CT, which provides direct information about blood flow and tissue viability, CTA-based approaches rely on vascular biomarkers such as collateral flow [35, 36, 37] and ASPECTS [33, 38, 36] to estimate the final infarct size.

Building on these findings, Sheth et al. [39] developed an automated deep learning model called Deep-SymNet to identify large vessel occlusions (LVO) and the infarct core from CTA source images. Their method demonstrated an ability to determine the infarct core with an AUC of approximately 0.88. Recently, Hokkinen et al. [40] reported that a CTA-based CNN method showed a moderate correlation with final infarct volumes in the late time window for patients with large vessel occlusion who were successfully treated with endovascular therapy. Giancardo et al. [41] further advanced the field by introducing a deep learning method that incorporates a novel weighted gradient-based approach for stroke ischemic core segmentation using image-level labeling. This approach outperforms nnUNet models trained on voxel-level data. More recently, Palsson et al. [42] introduced a U-Net-based convolutional neural network for lesion prediction, augmented with a spatial and channel-wise squeeze-and-excitation block. Their study demonstrates the feasibility of predicting 24-hour follow-up infarcts using acute CTA imaging, achieving results comparable to those of CTP-based algorithms.

### *2.4. Multimodal final infarct prediction models*

While single-modality approaches using CTP, NCCT, or CTA have shown promise in predicting final infarct volumes, there are growing research efforts on combining multiple imaging modalities for enhanced accuracy and reliability in final infarct prediction. Multimodal approaches could leverage the complementary

strengths of different imaging techniques, potentially enabling a more comprehensive assessment of ischemic stroke. In this context, Wang et al. [43] developed a hybrid multiscale CNN model that integrates NCCT, CTA, and CTA+ (acquired with an 8-second delay after CTA) to identify the infarct core and deficit. Their quantitative analysis demonstrated a high level of agreement with CTP-based definitions, highlighting the feasibility of employing commonly accessible imaging modalities (NCCT and CTA) for ischemic stroke assessment using deep learning. Other studies also explored the benefits of combining imaging data with tabular clinical information for enhanced stroke prediction. For instance, Robben et al.[15] leverage models including images, vascular functions, and treatment information. Building on this approach, Amador et al.[44] developed a multimodal spatio-temporal model that employs cross-attention mechanisms to simultaneously fuse information from 4D CTP and clinical metadata, resulting in improved accuracy in stroke infarct prediction.

### 3. Methods

#### *Dataset*

The dataset used in ISLES’24 has been specially prepared for the challenge. It includes multi-scanner and multi-center data derived from large vessel occlusion ischemic stroke cohorts. The dataset includes acute and sub-acute stroke imaging and clinical (tabular) data. Acute imaging data has been acquired at patient admission and includes the diagnostic CT trilogy: NCCT, CTA, and CTP, as well as CTP-derived perfusion maps (namely CBF, cerebral blood volume, mean transit time, and time-to-maximum a.k.a Tmax). Follow-up imaging data was acquired 2 to 9 days later and included DWI and ADC. Moreover, the clinical data contains demographics (age, sex, etc.), patient history, admission scores (e.g., admission NIHSS), and clinical outcomes (e.g., 3-month mRS). In Figure XXX, an example data case is shown.

The dataset is released in raw and preprocessed formats, thus allowing participants to devise algorithms with diverse degrees of freedom. For anonymization purposes, all scans are defaced based on brain and face masks obtained with TotalSegmentator [45], and the clinical tabular data de-identified by adding  $\pm 5\%$  random noise to the laboratory variables. Preprocessing of the CTP series has been performed using the FDA-approved clinical software icobrain cva [46, 47]. The 4D CTP series are motion-corrected through image co-registration and temporally resampled at 1 frame/second. Afterwards, perfusion maps are generated using a traditional tracer-kinetics deconvolution algorithm. The CTA scans are released after cropping the images around the head, thus removing the thoracic region when available. Preprocessing of the images has been performed by linearly interpolating and registering all the imaging series to the NCCT scans. Except for the MRI scans, where affine transformations are used, all remaining images are registered following rigid transformations. Registration is performed using the Elastix [48] and NiftyReg [49] toolboxes. Furthermore, MRI scans are skull-stripped using HD-BET [50]. Lesion masks are derived from DWI images using the ISLES’22 ensemble algorithm [12]. Quality control and correction of the lesion masks are performed when needed by medical students (TAB, HPM) supervised by two neuroradiologists (JSK, BW) with more than 10 years of experience.

The dataset ( $N = 250$ ) is split into train ( $N = 150$ ) and test subsets ( $N = 100$ ). The train (test) set contains  $N = 100$  ( $N = 50$ ) scans from the University Hospital of Munich and  $N = 50$  ( $N = 50$ ) scans from the University Hospital of Zurich. All the train subset is publicly available, while the test subset is hidden from the public, precluding participants from model overfitting strategies. The ISLES’24 data is structured and maintained following the Brain Imaging Data Structure (BIDS) guidelines [51].

#### *3.1. Task*

The ISLES’24 challenge task is the segmentation of final, post-treatment infarct brain tissue from pre-treatment imaging and clinical data. Participants can choose which image modalities to use and if using them *raw* or already preprocessed. Multimodal data approaches can be used, as the data involves 1D, 3D, and 4D modalities. An overview of the challenge task and the involved data modalities is depicted in Figure 1.

#### *Algorithms’ evaluation*

##### *Metrics*

The algorithmic results are evaluated by comparing the predicted lesions masks with the (manually traced) ground-truth masks. The four following segmentation and task-specific, clinically relevant metrics

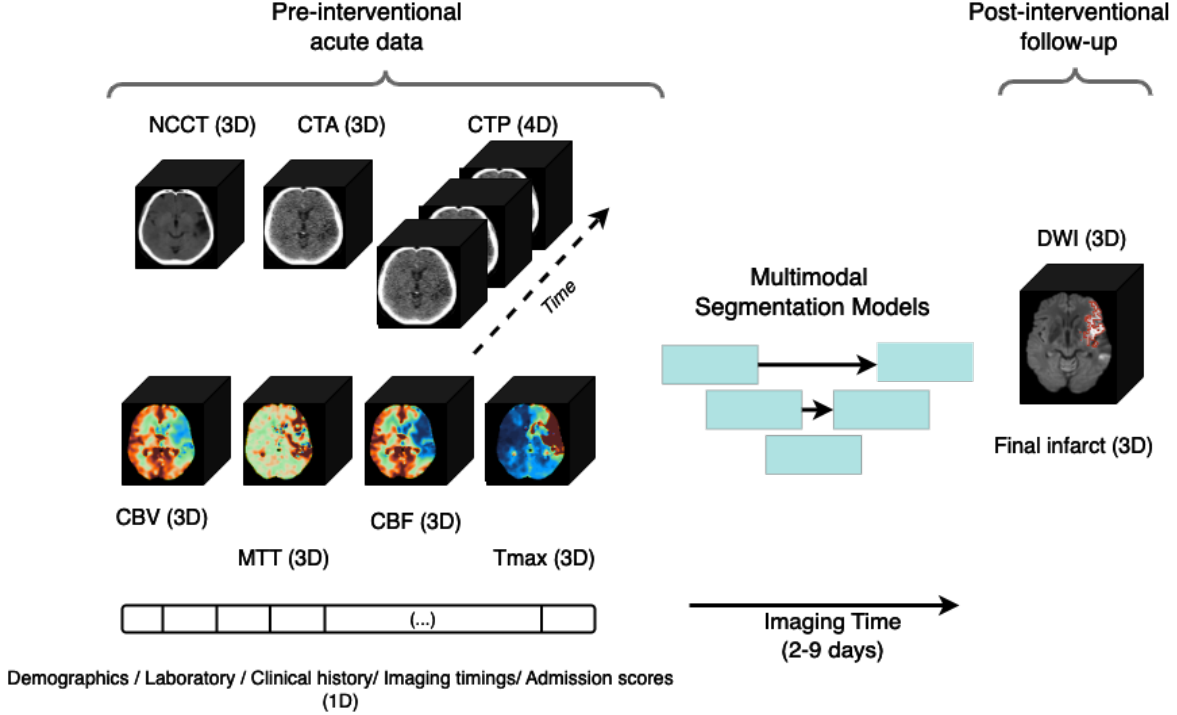


Figure 1: Overview of the ISLES'24 task and data modalities. Participants can exploit 1D/2D/3D/4D final infarct learning strategies. NCCT: non-contrast CT; CTA: CT angiography; CTP: perfusion CT; CBV: cerebral blood volume; CBF: cerebral blood flow; MTT: mean transit time; Tmax: time-to-maximum; DWI: diffusion weighted imaging.

are used: *i*) Dice Similarity Coefficient[52] ( $DSC = \frac{2 \cdot TP}{2 \cdot TP + FP + FN}$ , with  $TP$  the true positive lesion voxels,  $FP$  the false positive lesion voxels, and  $FN$  the false negative lesion voxels), *ii*) absolute volume difference ( $AVD = |\text{Volume}_{\text{predicted}} - \text{Volume}_{\text{ground truth}}|$ ), *iii*) lesion-wise  $F1_{\text{score}} = \frac{2 \cdot TP_{\text{lesion}}}{2 \cdot TP_{\text{lesion}} + FP_{\text{lesion}} + FN_{\text{lesion}}}$ , and *iv*) absolute lesion count difference ( $ALD = |\# \text{Lesions}_{\text{predicted}} - \# \text{Lesions}_{\text{ground truth}}|$ ).

### Ranking

The final challenge ranking is determined by evaluating each method's performance on the unseen test set. The test phase of the challenge is blind and single-shot; participants do not have access to the input images, their output results, or the ground truth images. This setup entirely precludes any manual intervention, visual quality assessments, or case-specific overfitting strategies by the teams.

The ranking is performed as in previous ISLES editions [7, 8, 9, 12]. The ranking scheme is derived from the average ranking position obtained from all the individual rankings by case and by metric. First, for each scan and metric, the participants are ranked. Then, for each participant, the average rank across all the metrics for each case is computed, leading to a 'per-case average rank' for each team. The final ranking is obtained by averaging these 'per-case average ranks' across the entire dataset.

### Data and Code availability

The ISLES'24 dataset is accessible at <https://isles-24.grand-challenge.org/>. To facilitate team participation and metric quantification, two Git repositories have been pre-released. The first repository, <https://github.com/ezequieldlrosa/isles24>, provides an introduction to the challenge and includes a Python notebook that demonstrates the computation of performance metrics. The second repository (<https://github.com/ezequieldlrosa/isles24-docker-template>) offers a template Docker algorithm, designed to streamline the creation of algorithmic Dockers. The F1-score and absolute lesion count difference metrics are computed using the *panoptica* Python library [53]. Connected components are identified using the *cc3d* [54] Python package. The final challenge ranking is determined using the *rankThenAggregate* function from the *challengeR* [55] package implemented in R [56].

## 4. Results

This section presents the ISLES'24 algorithmic rankings and performance metrics obtained during the hidden test phase. For the best-performing methods, we also conduct further analysis to gain deeper insights into their performance, encompassing both quantitative and qualitative evaluations.

## 5. Discussion

Predicting final infarct stroke lesions from pre-interventional acute data is a complex task due to multiple factors. Acute CT imaging, while widely used, is less sensitive compared to the gold-standard DWI and often suffers from artifacts (e.g. streak) and low signal-to-noise ratio. These technical limitations make it particularly challenging to identify small stroke lesions, such as embolic shower patterns, which are crucial for understanding the full extent of the stroke (Boers et al., 2013). Furthermore, the dynamic nature of stroke progression adds additional complexities. Infarct growth can occur unpredictably, and small DWI lesions may even be generated during the recanalization procedure itself (Albers et al., 2006). Edema can compress brain structures, altering anatomy in ways that may not be visible in acute images (Kucinski et al., 2002). Additionally, technical challenges in data processing and handling, such as image interpolation and registration due to different image spaces and resolutions between acute CT and follow-up MRI, further complicate accurate segmentation (Crum et al., 2004). This multifaceted problem underscores the need for advanced techniques and careful interpretation in stroke lesion segmentation.

## Acknowledgement

SW is supported by the Swiss National Science Foundation (Grant No. 310030\_200703), the UZH Clinical Research Priority Program (CRPP) Stroke, and the Swiss Heart Foundation. EdlR and BM are supported by the Helmut Horten Foundation. EOR is supported by the TUM KKF Clinician Scientist Program

## References

- [1] B. H. Menze, A. Jakab, S. Bauer, J. Kalpathy-Cramer, K. Farahani, J. Kirby, Y. Burren, N. Porz, J. Slotboom, R. Wiest, et al., The multimodal brain tumor image segmentation benchmark (brats), *IEEE transactions on medical imaging* 34 (10) (2014) 1993–2024.
- [2] A. Sekuboyina, M. E. Hussein, A. Bayat, M. Löffler, H. Liebl, H. Li, G. Tetteh, J. Kukačka, C. Payer, D. Štern, et al., Verse: a vertebrae labelling and segmentation benchmark for multi-detector ct images, *Medical image analysis* 73 (2021) 102166.
- [3] A. Lalande, Z. Chen, T. Decourselle, A. Qayyum, T. Pommier, L. Lorgis, E. de la Rosa, A. Cochet, Y. Cottin, D. Ginjac, et al., Emidec: a database usable for the automatic evaluation of myocardial infarction from delayed-enhancement cardiac mri, *Data* 5 (4) (2020) 89.
- [4] M. Antonelli, A. Reinke, S. Bakas, K. Farahani, A. Kopp-Schneider, B. A. Landman, G. Litjens, B. Menze, O. Ronneberger, R. M. Summers, et al., The medical segmentation decathlon, *Nature communications* 13 (1) (2022) 4128.
- [5] F. Kofler, F. Meissen, F. Steinbauer, R. Graf, E. Oswald, E. de da Rosa, H. B. Li, U. Baid, F. Hoelzl, O. Turgut, et al., The brain tumor segmentation (brats) challenge 2023: Local synthesis of healthy brain tissue via inpainting, *arXiv preprint arXiv:2305.08992*.
- [6] K. Yang, F. Musio, Y. Ma, N. Juchler, J. C. Paetzold, R. Al-Maskari, L. Höher, H. B. Li, I. E. Hamamci, A. Sekuboyina, et al., Benchmarking the cow with the topcow challenge: Topology-aware anatomical segmentation of the circle of willis for cta and mra, *ArXiv*.
- [7] O. Maier, B. H. Menze, J. von der Gablentz, L. Häni, M. P. Heinrich, M. Liebrand, S. Winzeck, A. Basit, P. Bentley, L. Chen, et al., Isles 2015-a public evaluation benchmark for ischemic stroke lesion segmentation from multispectral MRI, *Medical image analysis* 35 (2017) 250–269.

- [8] S. Winzeck, A. Hakim, R. McKinley, J. A. Pinto, V. Alves, C. Silva, M. Pisov, E. Krivov, M. Belyaev, M. Monteiro, et al., Isles 2016 and 2017-benchmarking ischemic stroke lesion outcome prediction based on multispectral MRI, *Frontiers in neurology* 9 (2018) 679.
- [9] A. Hakim, S. Christensen, S. Winzeck, M. G. Lansberg, M. W. Parsons, C. Lucas, D. Robben, R. Wiest, M. Reyes, G. Zaharchuk, Predicting infarct core from computed tomography perfusion in acute ischemia with machine learning: lessons from the isles challenge, *Stroke* 52 (7) (2021) 2328–2337.
- [10] S.-L. Liew, B. P. Lo, M. R. Donnelly, A. Zavaliangos-Petropulu, J. N. Jeong, G. Barisano, A. Hutton, J. P. Simon, J. M. Juliano, A. Suri, et al., A large, curated, open-source stroke neuroimaging dataset to improve lesion segmentation algorithms, *Scientific data* 9 (1) (2022) 320.
- [11] M. R. Hernandez Petzsche, E. de la Rosa, U. Hanning, R. Wiest, W. Valenzuela, M. Reyes, M. Meyer, S.-L. Liew, F. Kofler, I. Ezhov, et al., Isles 2022: A multi-center magnetic resonance imaging stroke lesion segmentation dataset, *Scientific data* 9 (1) (2022) 762.
- [12] E. de la Rosa, M. Reyes, S.-L. Liew, A. Hutton, R. Wiest, J. Kaesmacher, U. Hanning, A. Hakim, R. Zubal, W. Valenzuela, et al., A robust ensemble algorithm for ischemic stroke lesion segmentation: Generalizability and clinical utility beyond the isles challenge, *arXiv preprint arXiv:2403.19425*.
- [13] A. Fieselmann, M. Kowarschik, A. Ganguly, J. Hornegger, R. Fahrig, Deconvolution-based ct and mr brain perfusion measurement: theoretical model revisited and practical implementation details, *International Journal of Biomedical Imaging* 2011 (1) (2011) 467563.
- [14] E. de la Rosa, D. Robben, D. M. Sima, J. S. Kirschke, B. Menze, Differentiable deconvolution for improved stroke perfusion analysis, in: *Medical Image Computing and Computer Assisted Intervention—MICCAI 2020: 23rd International Conference, Lima, Peru, October 4–8, 2020, Proceedings, Part VII* 23, Springer, 2020, pp. 593–602.
- [15] D. Robben, A. M. Boers, H. A. Marquering, L. L. Langezaal, Y. B. Roos, R. J. van Oostenbrugge, W. H. van Zwam, D. W. Dippel, C. B. Majoie, A. van der Lugt, et al., Prediction of final infarct volume from native ct perfusion and treatment parameters using deep learning, *Medical image analysis* 59 (2020) 101589.
- [16] K. Kamnitsas, C. Ledig, V. F. Newcombe, J. P. Simpson, A. D. Kane, D. K. Menon, D. Rueckert, B. Glocker, Efficient multi-scale 3d cnn with fully connected crf for accurate brain lesion segmentation, *Medical image analysis* 36 (2017) 61–78.
- [17] K. Amador, M. Wilms, A. Winder, J. Fiehler, N. Forkert, Stroke lesion outcome prediction based on 4d ct perfusion data using temporal convolutional networks, in: *Medical Imaging with Deep Learning*, PMLR, 2021, pp. 22–33.
- [18] K. Amador, M. Wilms, A. Winder, J. Fiehler, N. D. Forkert, Predicting treatment-specific lesion outcomes in acute ischemic stroke from 4d ct perfusion imaging using spatio-temporal convolutional neural networks, *Medical Image Analysis* 82 (2022) 102610.
- [19] L. de Vries, B. J. Emmer, C. B. Majoie, H. A. Marquering, E. Gavves, Perfu-net: baseline infarct estimation from ct perfusion source data for acute ischemic stroke, *Medical image analysis* 85 (2023) 102749.
- [20] L. de Vries, B. Emmer, C. Majoie, H. Marquering, E. Gavves, Transformers for ischemic stroke infarct core segmentation from spatio-temporal ct perfusion scans, *Learning* 7 (2021) 9.
- [21] K. Amador, A. Winder, J. Fiehler, M. Wilms, N. D. Forkert, Hybrid spatio-temporal transformer network for predicting ischemic stroke lesion outcomes from 4d ct perfusion imaging, in: *International Conference on Medical Image Computing and Computer-Assisted Intervention*, Springer, 2022, pp. 644–654.

- [22] A. Gutierrez, K. Amador, A. Winder, M. Wilms, J. Fiehler, N. D. Forkert, Annotation-free prediction of treatment-specific tissue outcome from 4d ct perfusion imaging in acute ischemic stroke, *Computerized Medical Imaging and Graphics* 114 (2024) 102376.
- [23] L. de Vries, R. L. van Herten, J. W. Hoving, I. Išgum, B. J. Emmer, C. B. Majoie, H. A. Marquering, E. Gavves, Spatio-temporal physics-informed learning: A novel approach to ct perfusion analysis in acute ischemic stroke, *Medical image analysis* 90 (2023) 102971.
- [24] L. de Vries, R. L. M. Van Herten, J. W. Hoving, I. Isgum, B. Emmer, C. B. Majoie, H. Marquering, S. Gavves, Accelerating physics-informed neural fields for fast ct perfusion analysis in acute ischemic stroke, in: *Medical Imaging with Deep Learning*, 2024.
- [25] I. Rekik, S. Allasonnière, T. K. Carpenter, J. M. Wardlaw, Medical image analysis methods in mr/ct-imaged acute-subacute ischemic stroke lesion: Segmentation, prediction and insights into dynamic evolution simulation models. a critical appraisal, *NeuroImage: Clinical* 1 (1) (2012) 164–178.
- [26] A. Srivatsan, S. Christensen, M. G. Lansberg, A relative noncontrast ct map to detect early ischemic changes in acute stroke, *Journal of Neuroimaging* 29 (2) (2019) 182–186.
- [27] W. Qiu, H. Kuang, E. Teleg, J. M. Ospel, S. I. Sohn, M. Almekhlafi, M. Goyal, M. D. Hill, A. M. Demchuk, B. K. Menon, Machine learning for detecting early infarction in acute stroke with non-contrast-enhanced ct, *Radiology* 294 (3) (2020) 638–644.
- [28] H. El-Hariri, L. A. S. M. Neto, P. Cimfova, F. Bala, R. Golan, A. Sojoudi, C. Duszynski, I. Elebute, S. H. Mousavi, W. Qiu, et al., Evaluating nnu-net for early ischemic change segmentation on non-contrast computed tomography in patients with acute ischemic stroke, *Computers in biology and medicine* 141 (2022) 105033.
- [29] J. Pan, G. Wu, J. Yu, D. Geng, J. Zhang, Y. Wang, Detecting the early infarct core on non-contrast CT images with a deep learning residual network, *Journal of Stroke and Cerebrovascular Diseases* 30 (6) (2021) 105752.
- [30] J. W. Pexman, P. A. Barber, M. D. Hill, R. J. Sevick, A. M. Demchuk, M. E. Hudon, W. Y. Hu, A. M. Buchan, Use of the alberta stroke program early ct score (aspects) for assessing ct scans in patients with acute stroke, *American Journal of Neuroradiology* 22 (8) (2001) 1534–1542.
- [31] W.-C. Wang, S.-Y. Chien, S.-T. Tsai, Y.-W. Yang, D.-K. Nguyen, Y.-L. Wu, M.-K. Lu, T.-H. Sun, J. Yu, C.-T. Lin, et al., Automated delineation of acute ischemic stroke lesions on non-contrast ct using 3d deep learning: A promising step towards efficient diagnosis and treatment, *Biomedical Signal Processing and Control* 93 (2024) 106139.
- [32] H. Kuang, Y. Wang, J. Liu, J. Wang, Q. Cao, B. Hu, W. Qiu, J. Wang, Hybrid cnn-transformer network with circular feature interaction for acute ischemic stroke lesion segmentation on non-contrast ct scans, *IEEE Transactions on Medical Imaging*.
- [33] S. B. Coutts, M. H. Lev, M. Eliasziw, L. Roccatagliata, M. D. Hill, L. H. Schwamm, J. W. Pexman, W. J. Koroshetz, M. E. Hudon, A. M. Buchan, et al., Aspects on cta source images versus unenhanced ct: added value in predicting final infarct extent and clinical outcome, *stroke* 35 (11) (2004) 2472–2476.
- [34] J.-S. Park, J. M. Lee, H.-S. Kwak, G. H. Chung, Predictive value of ct angiography source image aspects in patients with anterior circulation acute ischemic stroke after endovascular treatment: ultimate infarct size and clinical outcome, *Journal of neurointerventional surgery* 11 (4) (2019) 342–346.
- [35] A. Angermaier, S. Langner, M. Kirsch, C. Kessler, N. Hosten, A. Khaw, Ct-angiographic collateralization predicts final infarct volume after intra-arterial thrombolysis for acute anterior circulation ischemic stroke, *Cerebrovascular diseases* 31 (2) (2011) 177–184.
- [36] J. Aoki, Y. Tateishi, C. L. Cummings, E. Cheng-Ching, P. Ruggieri, M. S. Hussain, K. Uchino, Collateral flow and brain changes on computed tomography angiography predict infarct volume on early diffusion-weighted imaging, *Journal of Stroke and Cerebrovascular Diseases* 23 (10) (2014) 2845–2850.



- [37] L. Eljovitch, N. Goyal, S. Mainali, D. Hoit, A. S. Arthur, M. Whitehead, A. F. Choudhri, Cta collateral score predicts infarct volume and clinical outcome after endovascular therapy for acute ischemic stroke: a retrospective chart review, *Journal of neurointerventional surgery* 8 (6) (2016) 559–562.
- [38] V. Puetz, P. Sylaja, M. Hill, S. Coutts, I. Dzialowski, U. Becker, G. Gahn, R. von Kummer, A. Demchuk, Ct angiography source images predict final infarct extent in patients with basilar artery occlusion, *American journal of neuroradiology* 30 (10) (2009) 1877–1883.
- [39] S. A. Sheth, V. Lopez-Rivera, A. Barman, J. C. Grotta, A. J. Yoo, S. Lee, M. E. Inam, S. I. Savitz, L. Giancardo, Machine learning-enabled automated determination of acute ischemic core from computed tomography angiography, *Stroke* 50 (11) (2019) 3093–3100.
- [40] L. Hokkinen, T. Mäkelä, S. Savolainen, M. Kangasniemi, Computed tomography angiography-based deep learning method for treatment selection and infarct volume prediction in anterior cerebral circulation large vessel occlusion, *Acta Radiologica Open* 10 (11) (2021) 20584601211060347.
- [41] L. Giancardo, A. Niktabe, L. Ocasio, R. Abdelkhaleq, S. Salazar-Marioni, S. A. Sheth, Segmentation of acute stroke infarct core using image-level labels on ct-angiography, *NeuroImage: Clinical* 37 (2023) 103362.
- [42] F. Palsson, N. D. Forkert, L. Meyer, G. Broocks, F. Flottmann, M. E. Maros, M. Bechstein, L. Winkelmeier, E. Schlemm, J. Fiehler, et al., Prediction of tissue outcome in acute ischemic stroke based on single-phase ct angiography at admission, *Frontiers in Neurology* 15 (2024) 1330497.
- [43] C. Wang, Z. Shi, M. Yang, L. Huang, W. Fang, L. Jiang, J. Ding, H. Wang, Deep learning-based identification of acute ischemic core and deficit from non-contrast ct and cta, *Journal of Cerebral Blood Flow & Metabolism* 41 (11) (2021) 3028–3038.
- [44] K. Amador, A. Gutierrez, A. Winder, J. Fiehler, M. Wilms, N. D. Forkert, Providing clinical context to the spatio-temporal analysis of 4d ct perfusion to predict acute ischemic stroke lesion outcomes, *Journal of Biomedical Informatics* 149 (2024) 104567.
- [45] J. Wasserthal, H.-C. Breit, M. T. Meyer, M. Pradella, D. Hinck, A. W. Sauter, T. Heye, D. T. Boll, J. Cyriac, S. Yang, et al., Totalsegmentator: robust segmentation of 104 anatomic structures in ct images, *Radiology: Artificial Intelligence* 5 (5).
- [46] E. de la Rosa, D. M. Sima, B. Menze, J. S. Kirschke, D. Robben, Aifnet: Automatic vascular function estimation for perfusion analysis using deep learning, *Medical Image Analysis* 74 (2021) 102211.
- [47] E. de la Rosa, D. M. Sima, J. S. Kirschke, B. Menze, D. Robben, Detecting CTP truncation artifacts in acute stroke imaging from the arterial input and the vascular output functions, *PloS one* 18 (3) (2023) e0283610.
- [48] S. Klein, M. Staring, K. Murphy, M. A. Viergever, J. P. Pluim, Elastix: a toolbox for intensity-based medical image registration, *IEEE transactions on medical imaging* 29 (1) (2009) 196–205.
- [49] S. Ourselin, R. Stefanescu, X. Pennec, Robust registration of multi-modal images: towards real-time clinical applications, in: *International Conference on Medical Image Computing and Computer-Assisted Intervention*, Springer, 2002, pp. 140–147.
- [50] F. Isensee, M. Schell, I. Pfueger, G. Brugnara, D. Bonekamp, U. Neuberger, A. Wick, H.-P. Schlemmer, S. Heiland, W. Wick, et al., Automated brain extraction of multisequence MRI using artificial neural networks, *Human brain mapping* 40 (17) (2019) 4952–4964.
- [51] K. J. Gorgolewski, T. Auer, V. D. Calhoun, R. C. Craddock, S. Das, E. P. Duff, G. Flandin, S. S. Ghosh, T. Glatard, Y. O. Halchenko, et al., The brain imaging data structure, a format for organizing and describing outputs of neuroimaging experiments, *Scientific data* 3 (1) (2016) 1–9.
- [52] L. R. Dice, Measures of the amount of ecologic association between species, *Ecology* 26 (3) (1945) 297–302.

- [53] F. Kofler, H. Möller, J. A. Buchner, E. de la Rosa, I. Ezhov, M. Rosier, I. Mekki, S. Shit, M. Negwer, R. Al-Maskari, et al., Panoptica–instance-wise evaluation of 3d semantic and instance segmentation maps, arXiv preprint arXiv:2312.02608.
- [54] W. Silversmith, cc3d: Connected components on multilabel 3D & 2D images., if you use this software, please cite it as below. (Sep. 2021). doi:10.5281/zenodo.5719536.  
URL <https://doi.org/10.5281/zenodo.5719536>
- [55] M. Wiesenfarth, A. Reinke, B. A. Landman, M. Eisenmann, L. A. Saiz, M. J. Cardoso, L. Maier-Hein, A. Kopp-Schneider, Methods and open-source toolkit for analyzing and visualizing challenge results, Scientific reports 11 (1) (2021) 1–15.
- [56] R Core team, et al., R: A language and environment for statistical computing, Vienna: R Core Team.