

SNeurodCNN: Structure-focused Neurodegeneration Convolutional Neural Network for Modeling and Classification of Alzheimer's Disease

Simisola Odimayo¹, Chollette C. Olisah^{1,*}, and Khadija Mohammed²

¹ School of Engineering, University of the West of England, United Kingdom

² Computer Science, Baze University, Abuja, Nigeria

*Correspondence to chollette.olisah@uwe.ac.uk, UWE, Coldharbour Ln, Stoke Gifford, Bristol BS16 1QY

ABSTRACT

Alzheimer's disease (AD), the predominant form of dementia, poses a growing global challenge and underscores the urgency of accurate and early diagnosis. The clinical technique radiologists adopt for distinguishing between mild cognitive impairment (MCI) and AD using Machine Resonance Imaging (MRI) encounter hurdles because they are not consistent and reliable. Machine learning has been shown to offer promise for early AD diagnosis. However, existing models focused on focal fine-grain features without considerations to focal structural features that give off information on neurodegeneration of the brain cerebral cortex. Therefore, this paper proposes a machine learning (ML) framework that integrates Gamma correction, an image enhancement technique, and includes a structure-focused neurodegeneration convolutional neural network (CNN) architecture called SNeurodCNN for discriminating between AD and MCI. The ML framework leverages the mid-sagittal and para-sagittal brain image viewpoints of the structure-focused Alzheimer's Disease Neuroimaging Initiative (ADNI) dataset. Through experiments, our proposed machine learning framework shows exceptional performance. The parasagittal viewpoint set achieves 97.8% accuracy, with 97.0% specificity and 98.5% sensitivity. The midsagittal viewpoint is shown to present deeper insights into the structural brain changes given the increase in accuracy, specificity, and sensitivity, which are 98.1% 97.2%, and 99.0%, respectively. Using GradCAM technique, we show that our proposed model is capable of capturing

the structural dynamics of MCI and AD which exist about the frontal lobe, occipital lobe, cerebellum, and parietal lobe. Therefore, our model itself as a potential brain structural change Digi-Biomarker for early diagnosis of AD.

Keywords: Alzheimer's disease, mild cognitive impairment, classification, deep learning, convolutional neural network.

Introduction

Alzheimer's disease (AD) is a specific type of dementia associated with severe neurological deficit that affects cognitive, visual, sensory and motor functions in people living with the disease¹. With AD, neurodegeneration, the progressive loss of structure or function of neurons, is inevitable and unfortunately there is currently no cure to reverse this process. However, clinical studies have shown it is progressive. This means if neurodegeneration is identified early enough at the mild cognitive impairment stage, which can be a precursor of AD, treatment and therapeutic options can be provided to slow the process. At the present, a definitive diagnosis of Alzheimer's disease (AD) remains a complex task because a test for the presence of amyloid plaques and phosphorylated tau are the true determinants of AD and it is achievable posthumously². Other clinical practice depends on a multitude of evaluations, including clinical assessments, medical history reviews, cognitive assessments, and neuroimaging over years of study in order to make clinical diagnostic decision³. Unlike others, neuroimaging is good for understanding and computing the extent of the structural changes in the brain. Of the neuroimaging methods, positron emission tomography (PET) and magnetic resonance imaging (MRI), the MRI provide structural brain imaging relevant to the pathological alteration characteristic of brain neurodegeneration⁴. The structural changes in the brain due to neurodegeneration can be viewed from several axis (axial, coronal, and sagittal) of the brain which are richly produced through MRI imaging. Notably, the axial view unveils substantial atrophy of the cerebral cortex, leading to a shrinkage of the cerebrum's outer layer. This atrophy is accompanied by ventricle enlargement, reduced brain volume, and diminished grey matter⁵. In contrast, the coronal view, highlights ventricle enlargement, emphasizes significant temporal lobe and cortical atrophy. It is a window into the widespread

loss of neurons throughout the brain, accompanied by sulci widening and gyrus thinning⁵. The sagittal plane provides the most visible information for AD diagnosis⁷. This statement is further heightened in⁷. The regions where degeneration of the brain neurons is predominant, which are significantly visible in the sagittal plane, are useful for understanding the impact of MCI and AD on learning and memory decline, mental function, motor function, and sensory function⁷. The visible regions are the frontal lobe, cerebellum, occipital lobe, thalamus, corpus callosum.

Despite the diagnostic potential of MRI which makes AD disease analysis visually possible, sole reliance on MRI findings for early AD diagnosis can face numerous limitations⁹. For example, subtle structural changes, especially when numerous samples of MCI and AD from different patients are to be analysed, AD may elude visual detection, thus necessitating reliable methods of comprehensive clinical evaluation. The interpretation of MRI scans varies among radiologists and clinicians, introducing potential inconsistencies. Even experts find it challenging to classify different AD stages. The ability to distinguish these stages represents a pivotal advancement in AD understanding. Current MRI analysis methods fall short in achieving this. However, emerging techniques in deep learning (DL) offer tremendous promise in improving AD diagnosis. Particularly, the enhancement of accuracy and timeliness of diagnosis, thereby paving way for more effective AD management and intervention.

Over the past decade, deep learning algorithms, pretrained networks and custom designed architectures, have successfully been adopted for AD modeling. The pretrained networks have a long-standing relevance in AD diagnostic research. Bae tailored a residual network-50 (ResNet50)¹⁰ for the task of classification of MCI and AD subjects and achieved an accuracy of 82.4%. The GoogLeNet, AlexNet, and ResNet-18 pretrained networks were exploited to classify patients into cognitively normal, early mild cognitive impairment, mild cognitive impairment, and late mild cognitive impairment categories¹¹. With accuracies of 96.39%, 94.08%, and 97.51% for GoogLeNet, AlexNet, and ResNet-18, respectively, ResNet-18 shows to supersede in AD diagnosis. A 3D EfficientNet which incorporated a 3D mobile inverted bottleneck convolution (MBConv) block, was proposed to facilitate AD diagnosis¹². Their model was assessed for

several AD classification tasks, and achieved accuracy, sensitivity, specificity, and AUC, of 86.67%, 75.00%, 90.91%, 97.16%, and 83.33%, respectively, on sMCI versus pMCI sets. The DenseNet-169 and ResNet-50 CNN architectures were adopted for early AD diagnosis¹³. Notably, DenseNet-169 exhibited superior performance during both the training and testing phases, surpassing ResNet-50 in accuracy with values of 97.7% and 83.82%, respectively, versus 88.7% and 81.92%. Another study employed a family of ResNet pre-trained network¹⁴, ResNet-18. They also proposed Mish Activation Function (MAF) for enhancing the model's learning adaptability and adopted weighted cross-entropy loss function in order to ensure equitable consideration for AD, MCI, and CN classes. Using preprocessed data from the ADNI dataset, their methods achieved a notable 88.3% accuracy.

Tailored deep learning algorithms are now paving ways in AD diagnosis. Basaiaa et al.¹⁵ proposed a 3D CNN consisting of 2 convolutional blocks of $5 \times 5 \times 5$ filter sizes and 10 blocks of $3 \times 3 \times 3$ filter sizes. It utilized strides in place of maxpooling for downsampling. Using ADNI stable (s-MCI) and MCI conversion (c-MCI) sets, 74.8%, 75.1%, and 75.3% were recorded for accuracy, sensitivity, and specificity, respectively, and reached 85.9%, 83.6%, and 88.3% with AD and s-MCI sets. Another research worthy of noting¹⁶ proposed a CNN for AD diagnosis and stratification. Their work did not only facilitate fast and accurate AD diagnosis but also offered classification for normal, MCI, and AD cases. Additionally, it tackled the challenging task of stratifying MCI into very mild dementia (VMD), mild dementia (MD), and moderate dementia (MoD) stages, akin to prodromal AD. Their shallow network achieved an overall testing accuracy of 99.68% which was higher in comparison to the pretrained networks such as DenseNet121, ResNet50, VGG 16, EfficientNetB7, and InceptionV3. Though the dataset used was the Open Access Series of Imaging Studies (OASIS) dataset, it is important to note that their work shows the importance of custom-trained networks in AD diagnosis. A fine-tuned CNN classifier¹⁷ called AlzheimerNet was shown to be capable of classifying Alzheimer's disease into five stages. With data preprocessing and augmentation, their method achieved a 98.67% accuracy using the RMSProp optimizer. An extended study into the classification of healthy control (HC) vs. AD, HC vs. pMCI, HC vs. sMCI, pMCI vs. AD, sMCI vs. AD, and sMCI vs. pMCI was proposed¹⁸. They developed a machine learning framework that included a deep belief network (DBN) with dropout and zero-masking for overcoming

overfitting, a preprocessing algorithm, a principal component analysis for dimensionality reduction, and a multi-task feature selection approach. Using the ADNI dataset, their method achieved high accuracy ranging from 87.78% to 99.62% in the various classification tasks. Hazarikar et al.¹⁹ replaced the downsampling layer in the traditional LeNet architecture with a fusion of minpooling and maxpooling to retain both minimum-valued and maximum-valued signals. Their model achieved accuracy, precision, recall, and F1-score of 98%, 96%, 97%, and 98%, respectively, on the ADNI dataset. A VGG-TSwinformer architecture²⁰ which combines VGG-16 convolutional neural network and Transformer network was proposed. The model was validated on the ADNI sMCI and pMCI sets and reached accuracy, sensitivity, specificity, and AUC of 77.2%, 79.97%, 71.59%, and 0.8153, respectively. Utilizing a hybrid architecture which combines LeNet and AlexNet²¹ an accuracy, precision, recall, and F1-Score of 0.96%, 0.93%, 0.93%, and 0.96% were achieved. The hybrid model reconstructed the CNN layers of both networks by varying the filter sizes (1×1 , 3×3 , and 5×5) to achieve good accuracy. A Multiplane Convolutional Neural Network (Mp-CNN), which simultaneously processes three planes (axial, coronal, sagittal) of 3D MRI was proposed²². The Mp-CNN's architecture, comprising 14 layers with Rectified Linear Unit (ReLU) activation and softmax for multiclass classification, outperforms traditional 2D CNN methods. Leveraging brain extraction tools for non-brain tissue removal and spatial normalization techniques, such as FLIRT, the authors demonstrate the Mp-CNN's superiority in classifying 500 AD, 500 Mild MCI, and 500 NC subjects from the ADNI database. With an impressive 93% accuracy for AD-MCI-NC classification and notable precision scores for individual classes. The performance of the transformer-based CNN termed Swinformer, was explored²³ for AD classification. Swinformer combines a CNN module for planar feature extraction and a transformer encoder module for 3D semantic connections. They argue that Swinformer can capture local features more accurately. The pipeline included data preprocessing, and augmentation strategies like random rotation and mirror reflection and exhibited an impressive accuracy of 88.3%, outperforming traditional models and showcasing its potential for nuanced AD classification.

While it is obvious that transfer learning with the use of state-of-the-art pre-trained networks is a promising technique in AD diagnosis, the custom-built deep learning algorithm supersedes in performance, and show that tailored networks are better at preserving the

underlying structure of data for AD diagnosis. However, no work has captured the structural dynamics of neurodegeneration of the brain volume given MCI and AD, which leaves room for more work to be done. Therefore, this paper seeks to bridge this research gap and makes the following contributions in AD research.

- Proposed a machine learning framework that integrates the proposed novel SNeurodCNN architecture for modeling the structural neurodegeneration of the brain cerebral cortex. This is to identify Digi-Biomarker relevant for discriminating between MCI and AD.
- This research investigates two planes of the sagittal axis, midsagittal and parasagittal, to be understand whether their varying viewpoints provide differing insights into structural neurodegeneration.

Results

This section presents the results and findings of this paper. We begin by outlining the findings of the SNeurodCNN and then progress to its analysis using GradCAM to identify features strongly indicative of the model’s sensitivities to brain neurodegeneration.

Evaluation on Structure-focused ADNI Dataset

Experiments on the structure-focused ADNI data version of the brain are relevant for understanding the structural changes that are contributors to brain neurodegeneration. The performance of SNeurodCNN was evaluated on the midsagittal and parasagittal planes of the sagittal axis of the brain. The parasagittal view of the sagittal plane is the version taken from off-center plane, while the midsagittal is the version taken at the exactly the center of the plane. The use of both planes is to investigate whether the model is impacted differently by neurodegeneration as it pertains to the parasagittal, which exposes regions of motor control, sensation, and perception, and the midsagittal, which exposes regions that are responsible for visuospatial integration, memory, and self-awareness. The results of this experiment are presented in Table 1.

Table 1: Performance evaluation of Classification Models in Midsagittal and Parasagittal Planes

Metric	Midsagittal Plane	Parasagittal Plane
Accuracy	98.1%	97.8%
Precision	97.2%	97.2%
Sensitivity	99.0%	98.5%
Specificity	97.2%	97.0%
F1-score	98.1%	97.8%
AUC	98.1%	97.8%

As can be observed in Table 1 the accuracy, precision, recall, specificity, f1-score, and AUC scores of SNeurodCNN are outstanding. This is an indication that the model is capable of modelling the structural neurogenerative impacts of MCI and AD occurring at both parts of the sagittal plane - midsagittal and parasagittal. While the accuracies recorded are high, which shows the model’s capability to distinguish between instances of AD from the instances of MCI, the midsagittal accuracy was higher by 0.3%. Given that the structure-focused ADNI is used, the performance conforms with the medical statement, “midsagittal cerebral morphology provides a homologous geometrical reference for brain shape and cortical vs. subcortical spatial relationships”²⁴. In medical diagnosis, a high recall is preferred - the higher the value the more confidence we have in the model’s ability to minimize false positives, that is, diagnosing AD when in fact it is MCI and vice-versa. Furthermore, the high f1-scores for both models reflect well-balanced performance in terms of precision and recall, ensuring a lower rate of both false-negative and false-positive predictions.

As an additional measure of our model’s performance, we utilize the AUC metric which is another metric that gives an unbiased view of a model’s performance amidst class imbalance aside from f1-score. The data presented were in the proportion of 180:105 for AD and

MCI patients, respectively. The AUC scores of 98.1% and 97.8%, respectively, for the midsagittal and parasagittal underscores the models' discriminatory capability in AD diagnosis.

SNeurodCNN Sensitivity to Brain Neurodegeneration

To understand the sensitivity of SNeurodCNN to brain neurodegeneration, we sampled the same slices from the MCI and AD category for midsagittal and parasagittal planes. This sensitivity is visualized using the Grad-CAM, a tool for visualizing the activation maps of the last convolutional layer of a network. We visualized the output of Grad-CAM using heatmap - the yellowish, the most significant, and the greenish the more significant and highlights region where brain neurodegeneration are prominent. The reverse is the case for shades of colour closer to purple.

As can be observed from the MCI (sMCI and pMCI) and AD slices in Figure 1, the frontal lobe, occipital lobe, and cerebellum are the regions highlighted as being highly significant, with the frontal lobe being the most prominent. Therefore, these regions reveal SNeurodCNN sensitivity to brain neurodegeneration in relation to AD. The observation made with the midsagittal plane is consistent with the parasagittal plane and can be observed in Figure 2, though the parasagittal plane shows an additional prominent region about the locations of the parietal lobe. Since we used the structure-focused ADNI, it is only expected that the highlights relates to changes in structure caused by shrinkage of the cerebral cortex, known as the cerebral atrophy. An obvious interpretation of this observations, is that the SNeurodCNN can sense a significant difference in structural characteristics of the frontal lobe, occipital lobe, and cerebellum and possibly the parietal regions in MCI (sMCI and pMCI) and AD.

The insights into the functions of frontal lobe, occipital lobe, and cerebellum, and possibly the parietal lobe is important for understanding the roles these regions play in brain neurodegeneration in relation to AD. The frontal lobe is mainly responsible for motor action and the temporal integration of behavior²⁵. In a recent clinical study²⁶, the frontal lobes of patients with MCI are shown to

experience cortical atrophy but its severe volume deficit is evident in patients with AD. The region associated with visual processing for depth perception, color determination, object, and face recognition, and responsible for memory formation, is the occipital lobe²⁷. Clinical research reports structural changes is evident at the occipital lobe and it is an indication of early progressive MCI²⁸. The clinical study²⁹ discovers that there is a degree of functional connectivity disruptions in the cerebellum of MCI and AD patients. In this paper, our proposed SNeurodCNN showed its impact is subtle compared to others highlighted. The cerebellum is responsible for regulating motor movement and controlling balance³⁰. The additional highlight from the parasagittal viewpoint, the parietal lobe, might significantly indicate the impact that neurodegeneration can have on sensory functions of the brain. This region has not been computational confirmed in DL based studies, but a clinical study³¹ has shown that the parietal grey matter volumes distinguish between MCI, and AD. These regions analysed are visible in the midsagittal or parasagittal axis of the brain but does not exclude other regions impacted as well, like the temporal lobe. Memory loss, to a considerable extent, affects MCI and AD patients with the former is less pronounced than the latter^{32,33}. However, the temporal lobe responsible for memory loss is not visible in the midsagittal or parasagittal axis of the brain.

Discussion

In this discussion, we delve into the results presented in Section 3 of the study, which primarily focuses on the application of advanced classification methods and visualization techniques in neuroimaging analysis. Neuroimaging analysis plays a pivotal role in comprehending AD and the various types of MCI. Traditionally, it served as a tool for confirming neurodegeneration, but this research

MIDSAGITAL PLANE

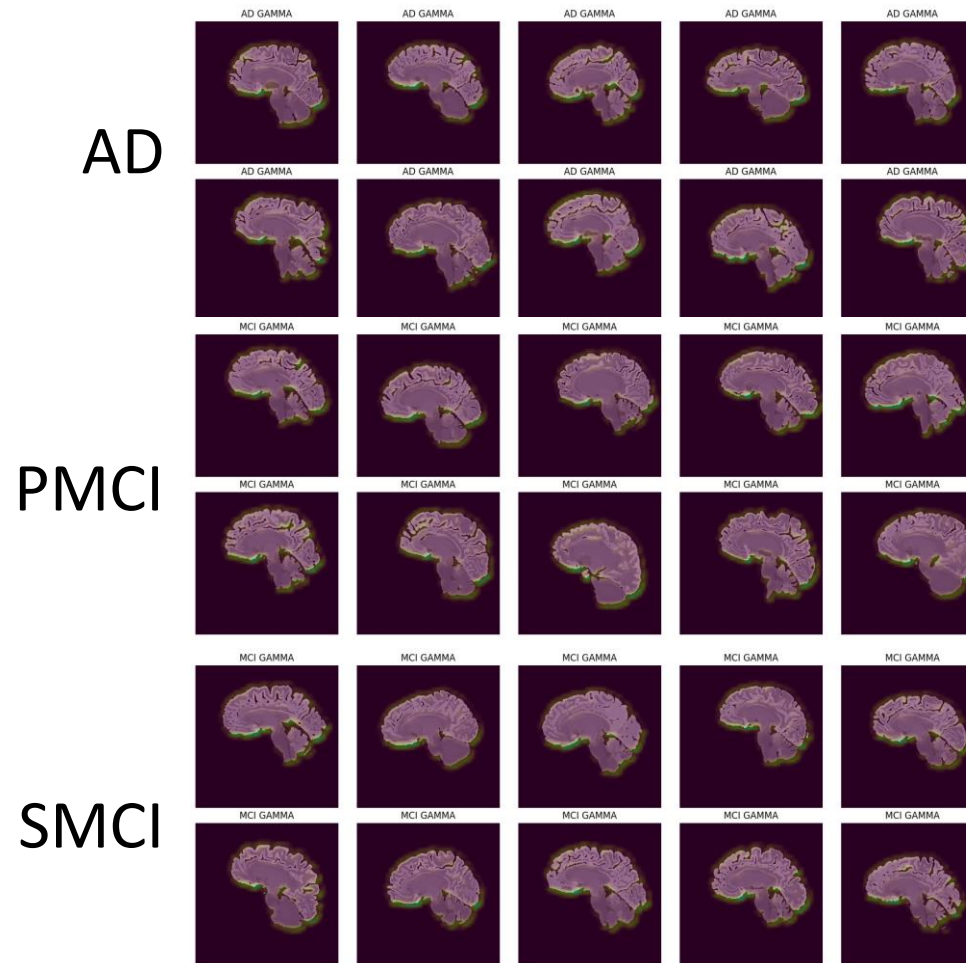


Figure 1: Visualisation of regions of interest on the midsagittal plane identified by the CNN model in AD, pMCI and sMCI subjects.

PARASAGITTAL PLANE

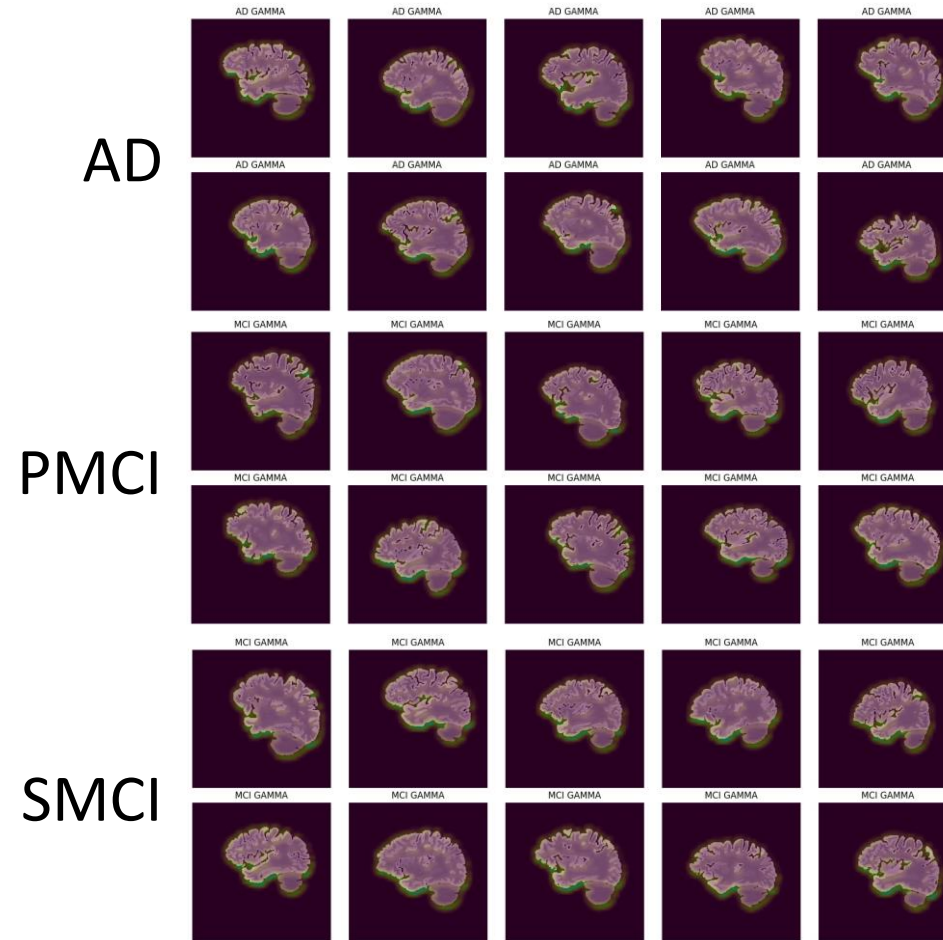


Figure 2: Visualisation of regions of interest on the parasagittal plane identified by the CNN model in AD, pMCI and sMCI subjects

demonstrates that automated diagnosis not only aids in prediction but also reveals regions susceptible to further neurodegeneration, in addition to classifying the disease stage. This research substantiates the effectiveness of the proposed SNeurodCNN model for early

diagnosis of AD. The evaluation of neurodegeneration using the midsagittal and parasagittal planes of the brain results in remarkable performance. It surpasses the performance of previous studies, particularly^{7,10}. SNeurodCNN has showcased prowess in capturing neurodegenerative features from MRI images. As observed with Grad-CAM, the structural changes are prominent about the frontal lobe, occipital lobe, cerebellum, of the midsagittal MRI slices. The frontal lobe dysfunction has been implicated in various neurodegenerative conditions, including AD and MCI³⁴. The parasagittal view shows an additional structural change is possible at the parietal lobe, which were not obvious in the midsagittal slices. The regions the SNeurodCNN model are most sensitive to, frontal lobe, occipital lobe, cerebellum, and parietal lobe, are consistent with clinical studies²⁵⁻³¹ and in some cases consistent with regions identified in one of the DL based studies⁷, though our study further confirms the significance of cerebral atrophy on brain structure. Therefore, these discovery shows that our proposed SNeurodCNN can significantly contribute to AD diagnosis and prognosis. This necessitates the integration of deep learning into healthcare practices for providing early cues of AD that might be present in the MCI patients, minimizing the occurrences of false positives and false negatives that mitigates against misdiagnosis.

Furthermore, the structural changes that our proposed SNeurodCNN highlights sets a record as a potential brain structural change digi-biomarker for early diagnosis of AD. The benefits of digi-biomarker are numerous, 1) can help clinicians to develop targeted and personalized treatment plans and interventions through personalized analysis of disease states. This could provide valuable targets for therapeutic interventions and monitoring and the assessment of novel treatments accordingly.

Materials and Method

This section elucidates the dataset employed in this study and outlines the methodologies encompassing data preprocessing pipeline and the design of deep convolutional neural network architecture.

Data

The ADNI AD benchmark dataset commonly used for AD analysis is relevant to this study. This dataset is designed from study that enrolled individuals aged 55 to 90 from 57 sites across the United States and Canada after obtaining their informed consent. In all, the ADNI comprises of 368 subjects, categorized into 180 AD patients (82 females, 98 males; age \pm SD = 75.28 ± 7.57 years), 105 stable sMCI subjects (41 females, 64 males; age \pm SD = 74.69 ± 7.41 years). Their average mini-mental state examination (MMSE) scores were 23 for AD, 28 for sMCI, and 27 for pMCI. All subjects possessed a T1-weighted baseline from ADNI1/Go/2. The sMCI group consisted of individuals who were diagnosed as MCI at baseline and remained so for at least two years. A summary of the demographics of the ADNI participants are provided in Table 2.

We particularly explored the skull-free version available¹. This version utilized ADNI dataset preprocessed to correct for imaging distortion through gradwarping using gradient inhomogeneity correction applied, intensity correction, and scaling to address gradient drift. Then, were further processed using multi-atlas label propagation with expectation maximization (MALPEM) to segment, on local scales, the cross-sectional structural volume changes of the brain which makes up this paper's structure focused ADNI dataset. It should be noted that each slice of the structure-focused ADNI dataset is characterized by the region of the grey matter that forms the anatomical structures of the MRI brain images and not the grey matter itself.

¹ <https://doi.org/10.12751/g-node.aa605a>

Table 2 Demographics and clinical characteristics of the study population of the ADNI dataset

Group	Subject	Age	Gender		MMSE
			M	F	
AD	180	75.28 ± 7.57	98	82	23
sMCI	105	74.69 ± 7.41	64	41	28
pMCI	83	73.82 ± 6.65	49	34	27

Preprocessing

Considering that the structural changes in the brain and AD pathology is more prominent in the sagittal plane and their efficacy in AD classification has long been established ^{7,12}. This study explored two views of the sagittal plane, the midsagittal and parasagittal viewpoints from the ADNI volumetric data with multiple image planes (axial, coronal, and sagittal). From the 3D structured focused ADNI dataset comprising of 368 subjects with 155 slices each. However, only slices showing full brain components were retained and as such the number of slices varied from sample to sample. In this study, we consider a different approach which is an unusual practice in literature where the disease case of a sample is described by all/fraction of their slices. The slices from the sMCI and pMCI are accumulated and referred as the MCI set, while the slices from the AD samples are likewise accumulated into an AD set. We consider AD diagnosis to be a task that is sample-independent, therefore, it is only logical to teach the deep learning algorithm to capture the factors of variation of the two categories, MCI and AD, to better understand the disparity that exist between the two. In all, a total of 4228 midsagittal AD and MCI sets were retained with each consisting of 2160 and 2068, respectively. The parasagittal AD and MCI sets are 2700, 2820, respectively, which is altogether 5520 data points.

The nonlinearity property of Gamma function is found to be a useful method³⁵ for expanding the brightness of intensity of a poorly illuminated image and contributed greatly to the technique proposed³⁵. Despite the intensity correction on original ADNI, the structure-focused ADNI dataset were shown to have been affected by poor illumination conditions during acquisition and as such, the Gamma

Correction is considered relevant to the task of intensity brightness expansion in this paper. Gamma Correction is an inverse of the gamma function. Subsequently, AD and MCI samples are split into training and testing sets in the ratio 80:20. The testing set is further split in halves to accommodate set for validation.

The SNeurodCNN Architecture

Generally theorized is, *the deeper a deep network the better it is at encoding disentangled feature abstractions at higher layers of representations*. However, it does not always apply in a task-specific scenario, like the task the structure-focused ADNI presents. As earlier stated, each slice is characterized by the region of the grey matter that forms the anatomical structures of the MRI brain images. The reason the region as opposed to the grey matter is used is to capture the focal structural changes pertaining to neurodegeneration of the cerebral cortex as opposed to the focal fine-grain changes within the anatomical structures. For this reason, the SNeurodCNN architecture is designed to be a deep convolutional neural network for modeling the structural neurodegeneration of the brain for discriminating between MCI and AD.

The overview of the SNeurodCNN architecture, as summarized in Table 3, comprises of two downsampling convolution blocks growing in number of convolutional layers. The first block consists of a convolutional layer with 3×3 filter size and 32 filter depth, varying image dimension, nonlinear activation function, rectified linear unit (ReLU), and 2×2 maxpooling layer. The second convolution block only differs from the first by the two convolutional layers made up of 32 and 64 filter depths, respectively. This feeds into the fully connected layer with 500 hidden neurons, and then a dropout layer, which is a regulariser that optimizes learning by randomly dropping some nodes in the hidden neuron by a designated probability, which in our case, is 50%. This is followed by the output layer which is set to two and represents the two classes which the softmax activation function uses to classify an image as belonging to MCI or AD.

Table 3: Architecture summary of the neural network model

Layer (type)	Output Shape	Param #
conv2d (Conv2D)	(None, 178, 178, 32)	320
max_pooling2d(MaxPooling2D)	(None, 89, 89, 32)	0
conv2d_1 (Conv2D)	(None, 89, 89, 32)	9248
conv2d_2 (Conv2D)	(None, 89, 89, 64)	18496
max_pooling2d_1(Maxpooling 2D)	(None, 44, 44, 64)	0
flatten (Flatten)	(None, 123904)	0
dense (Dense)	(None, 500)	61952500
dropout (Dropout)	(None, 500)	0
dense_1 (Dense)	(None, 2)	1002

Experiments and Evaluation

The networks hyperparameters were chosen in ways that best optimizes the network’s learning capability. The optimizer is the Adam optimizer with a learning rate fixed at 0.0001. The number of epochs is set to 100 and the batch size of 32 is used. We adopted early stopping, a regulariser that prevents overfitting by actioning immediate halt on training when the performance of the network does not improve after several epochs. The parameter of the early stopping used are patience set to 5, restore_best_weights set to a Boolean value, true. During training, model learns through a method called backpropagation³⁶ which updates the weight of the network towards minimizing the gradient error. Taken into consideration the impact of hardware resources on model performance, we provide the hardware configuration of the system used for training the network. A Keras library running on Python-TensorFlow environment with a Google Collab GPU, Tesla K80 (T4).

To evaluate the SNeurodCNN performance, the following metrics are identified and are consistent with metrics used in literature for AD diagnosis. They are accuracy, precision, recall, specificity, F1-score, and area under the receiver operating curve (AUC) and provide a comprehensive assessment of the model's performance in binary classification. Provide a brief description of how the metrics work.

Limitations

The growing global population and the projected increase in AD cases underscore the pressing necessity to propel research in deep learning. Our proposed SNeurodCNN achieves remarkable classification accuracies of 98.1% and 97.8% in both midsagittal and parasagittal brain slices. This level of performance surpasses many existing studies, highlighting the potential of deep learning, particularly, our proposed model in transforming the landscape of neurodegenerative disease diagnosis. The adoption of Grad-CAM in this study to visualize the model sensitivities to neurodegeneration in the brain structure has not only substantiated our model's efficacy but deepens our comprehension of the intricate nature of neurodegenerative diseases in relation to MCI and AD, thereby opening doors to the development of more precise, targeted therapeutic interventions.

While our proposed SNeurodCNN model show to be significantly contribute to AD diagnostic research, its findings are constrained by several limitations. The trainable parameters are large and is computationally expensive, especially with respect to reliability and usefulness in real-time clinical diagnosis. Therefore, efforts to achieve high performance while minimizing the computational cost will be explored. Also, this paper is directed towards structural function of the brain analysis which led to the use of structure-focused ADNI. However, it will be interesting to understand how the SNeurodCNN model performs on focal fine-grain features available with skull free ADNI. This is to enable us to better analyse which of the features, focal fine-grain or focal structure, are representative of the characteristics of neurodegeneration in the brain in a way that makes early diagnosis of AD feasible and reliable in clinical analysis. It is our expectation that the outcome of the aforementioned study will lead to an understanding the underlying neurobiological mechanisms involved in MCI and AD which will help towards AD progression study.

Conclusion

In this paper we proposed a structure-focused neurodegeneration convolutional neural network (CNN) architecture called SNeurodCNN integrated in the machine learning framework along with preprocessing techniques for image enhancement and data preparation. The proposed framework leveraged the midsagittal and parasagittal brain image viewpoints of the structure-focused ADNI dataset. Through experiments, the proposed framework achieved 97.8% accuracy, with 97.0% specificity and 98.5% sensitivity on classification of the parasagittal slices. On the midsagittal slices, an accuracy, specificity, and sensitivity of 98.1% 97.2%, and 99.0%, were achieved, respectively. Using GradCAM, we showed that the viewpoint of the midsagittal highlighted frontal lobe, occipital lobe, cerebellum, while the parasagittal extended to the parietal lobe as regions of the brain where structural dynamics occurrences are prominent due to MCI and AD. We consider this discovery useful for Digi-Biomarker considerations in early diagnosis of AD. For the future work, efforts will be made to minimize the computational cost of the proposed model while achieving the same level of neurodegeneration modeling. Also, it will be interesting to apply the proposed model to focal fine-grain feature learning. This is to enable us to better analyse which of the features, focal fine-grain or focal structure, are representative of the characteristics of neurodegeneration in the brain in a way that makes early diagnosis of AD feasible and reliable in clinical analysis.

Conflict of interest

The authors declare that there is no conflict of interest.

Authors Contributions

Conceptualization, methodology, and project supervision, C.C.O.; literature review, project scope, S.O., K.M, C.C.O.; data collection, implementation, coding, validation, testing, S.O.; result analysis and interpretation S.O, C.C.O; manuscript – original draft, S.O, K.M, C.C.O.; All authors reviewed, edited, and approved the final manuscript.

References

1. Alzheimer's Association, 2018. 2018 Alzheimer's disease facts and figures. *Alzheimer's & Dementia*, 14(3), pp.367-429.
2. Gonzalez-Ortiz, F. *et al.* Plasma phospho-tau in Alzheimer's disease: towards diagnostic and therapeutic trial applications. *Mol Neurodegener* **18**, 18 (2023).
3. Galvin, J. E. & Sadowsky, C. H. Practical Guidelines for the Recognition and Diagnosis of Dementia. *The Journal of the American Board of Family Medicine* **25**, 367–382 (2012).
4. Zeng, H.-M., Han, H.-B., Zhang, Q.-F. & Bai, H. Application of modern neuroimaging technology in the diagnosis and study of Alzheimer's disease. *Neural Regen Res* **16**, 73 (2021).
5. Van de Mortel, L. A., Thomas, R. M. & van Wingen, G. A. Grey Matter Loss at Different Stages of Cognitive Decline: A Role for the Thalamus in Developing Alzheimer's Disease. *Journal of Alzheimer's Disease* **83**, 705–720 (2021).
6. Lin, H.-Y. *et al.* Differential Patterns of Gyral and Sulcal Morphological Changes During Normal Aging Process. *Front Aging Neurosci* **13**, (2021).
7. Hoang, G. M., Kim, U.-H. & Kim, J. G. Vision transformers for the prediction of mild cognitive impairment to Alzheimer's disease progression using mid-sagittal sMRI. *Front Aging Neurosci* **15**, (2023).
8. Apostolova, L. G. *et al.* Hippocampal Atrophy and Ventricular Enlargement in Normal Aging, Mild Cognitive Impairment (MCI), and Alzheimer Disease. *Alzheimer Dis Assoc Disord* **26**, 17–27 (2012).
9. McEvoy, L. K. & Brewer, J. B. Quantitative structural MRI for early detection of Alzheimer's disease. *Expert Rev Neurother* **10**, 1675–1688 (2010).
10. Bae, J. *et al.* Transfer learning for predicting conversion from mild cognitive impairment to dementia of Alzheimer's type based on a three-dimensional convolutional neural network. *Neurobiol Aging* **99**, 53–64 (2021).

11. Shanmugam, J. V., Duraisamy, B., Simon, B. C. & Bhaskaran, P. Alzheimer's disease classification using pre-trained deep networks. *Biomed Signal Process Control* **71**, 103217 (2022).
12. Zheng, B. *et al.* A modified 3D EfficientNet for the classification of Alzheimer's disease using structural magnetic resonance images. *IET Image Process* **17**, 77–87 (2023).
13. Al Shehri, W. Alzheimer's disease diagnosis and classification using deep learning techniques. *PeerJ Comput Sci* **8**, e1177 (2022).
14. Oktavian, M.W., Yudistira, N. and Ridok, A., 2022. Classification of Alzheimer's Disease Using the Convolutional Neural Network (CNN) with Transfer Learning and Weighted Loss. *arXiv preprint arXiv:2207.01584*.
15. Basaia, S., *et al.* Alzheimer's Disease Neuroimaging Initiative, 2019. Automated classification of Alzheimer's disease and mild cognitive impairment using a single MRI and deep neural networks. *NeuroImage: Clinical*, **21**, p.101645.
16. Marwa, E.G., Moustafa, H.E.D., Khalifa, F., Khater, H. & Abdelhalim, E., 2023. An MRI-based deep learning approach for accurate detection of Alzheimer's disease. *Alexandria Engineering Journal*, **63**, pp.211-221.
17. Shamrat, F. M. J. M. *et al.* AlzheimerNet: An Effective Deep Learning Based Proposition for Alzheimer's Disease Stages Classification From Functional Brain Changes in Magnetic Resonance Images. *IEEE Access* **11**, 16376–16395 (2023).
18. Zeng, N., Li, H. & Peng, Y. A new deep belief network-based multi-task learning for diagnosis of Alzheimer's disease. *Neural Comput Appl* **35**, 11599–11610 (2023).
19. Hazarika, R.A., Abraham, A., Kandar, D. & Maji, A.K. An improved LeNet-deep neural network model for Alzheimer's disease classification using brain magnetic resonance images. *IEEE Access*, **9**, pp.161194-161207, (2021).
20. Hu, Z., Wang, Z., Jin, Y. and Hou, W., VGG-TSwinformer: Transformer-based deep learning model for early Alzheimer's disease prediction. *Computer Methods and Programs in Biomedicine*, **229**, p.107291, (2023).
21. Hazarika, R.A., Maji, A.K., Kandar, D., Jasinska, E., Krejci, P., Leonowicz, Z. and Jasinski, M., 2023. An Approach for Classification of Alzheimer's Disease Using Deep Neural Network and Brain Magnetic Resonance Imaging (MRI). *Electronics*, **12**(3), p.676.

22. Angkoso, C. V., Agustin Tjahyaningtijas, H. P., Purnama, I., & Purnomo, M. H. Multiplane Convolutional Neural Network (Mp-CNN) for Alzheimer's Disease Classification. *International Journal of Intelligent Engineering and Systems* **15**, (2022).
23. Hu, Z., Li, Y., Wang, Z., Zhang, S. & Hou, W. Conv-Swinformer: Integration of CNN and shift window attention for Alzheimer's disease classification. *Comput Biol Med* **164**, 107304 (2023).
24. Bruner, E., Martin-Loeches, M. and Colom, R. Human midsagittal brain shape variation: patterns, allometry and integration. *Journal of Anatomy*, *216*(5), pp.589-599, (2010).
25. Hoffmann, M., 2013. The human frontal lobes and frontal network systems: an evolutionary, clinical, and treatment perspective. *International Scholarly Research Notices*, 2013.
26. Shi, C., Deng, H., Deng, X., Rao, D. and Yue, W., 2023. The Structural Changes of Frontal Subregions and Their Correlations with Cognitive Impairment in Patients with Alzheimer's Disease. *Journal of Integrative Neuroscience*, *22*(4), p.99.
27. Rehman A, Al Khalili Y. Neuroanatomy, Occipital Lobe. In: *StatPearls*. StatPearls Publishing, PMID: 31335040, (2023).
28. Zhao, L., *et al.* & Alzheimer Disease Neuroimaging Initiative. Risk estimation before progression to mild cognitive impairment and Alzheimer's disease: an AD resemblance atrophy index. *Aging (Albany NY)*, *11*(16), p.6217, (2019).
29. Tang, F., Zhu, D., Ma, W., Yao, Q., Li, Q. and Shi, J., 2021. Differences changes in cerebellar functional connectivity between mild cognitive impairment and Alzheimer's disease: a seed-based approach. *Frontiers in Neurology*, *12*, p.645171.
30. D'Angelo, E., Physiology of the cerebellum. *Handbook of clinical neurology*, *154*, pp.85-108, (2018).
31. Hänggi, J., Streffer, J., Jäncke, L. and Hock, C. Volumes of lateral temporal and parietal structures distinguish between healthy aging, mild cognitive impairment, and Alzheimer's disease. *Journal of Alzheimer's Disease*, *26*(4), pp.719-734, (2011).
32. Chetelat, G., Desgranges, B., De La Sayette, V., Viader, F., Eustache, F. and Baron, J.C. Mapping gray matter loss with voxel-based morphometry in mild cognitive impairment. *Neuroreport*, *13*(15), pp.1939-1943, 2002.
33. Saykin, A.J., Wishart, H.A., Rabin, L.A., Santulli, R.B., Flashman, L.A., West, J.D., McHugh, T.L. and Mamourian, A. Older adults with cognitive complaints show brain atrophy similar to that of amnesic MCI. *Neurology*, *67*(5), pp.834-842, 2006.

34. Dubois, B., Picard, G. & Sarazin, M. Early detection of Alzheimer's disease: new diagnostic criteria. *Dialogues Clin Neurosci* **11**, 135–139 (2009).
35. Chude-Olisah, C.C., Sulong, G., Chude-Okonkwo, U.A. and Hashim, S.Z., Illumination normalization for edge-based face recognition using the fusion of RGB normalization and gamma correction. In *2013 IEEE International Conference on Signal and Image Processing Applications*, pp. 412-416, (2013).
36. Miller, A.S., Blott, B.H. and Hames, T.K. Review of neural network applications in medical imaging and signal processing. *Medical and Biological Engineering and Computing*, 30, pp.449-464, 1992.