

Multiple Sclerosis Lesion Inpainting Using Non-Local Partial Convolutions

Hao Xiong, Dacheng Tao

Brain and Mind Centre and Central Clinical School, The University of Sydney, Sydney, NSW, Australia

UBTECH Sydney Artificial Intelligence Centre and School of Information Technologies, The University of Sydney, Sydney, NSW, Australia

Abstract

Multiple sclerosis (MS) is an inflammatory demyelinating disease of the central nervous system (CNS) that results in focal injury to the grey and white matter. The presence of white matter lesions biases morphometric analyses such as registration, individual longitudinal measurements and tissue segmentation for brain volume measurements. Lesion-inpainting with intensities derived from surround healthy tissue represent one approach to alleviate such problems. However, existing methods inpaint lesions based on texture information derived from local surrounding tissue, often leading to inconsistent inpainting and the generation of artifacts such as intensity discrepancy and blurriness. Based on these observations, we propose non-local partial convolutions (NLPC) which integrates a Unet-like network with the non-local module. The non-local module is exploited to capture long range dependencies between the lesion area and remaining normal-appearing brain regions. Then, the lesion area is filled by referring to normal-appearing regions with more similar features. This method generates inpainted regions that appear more realistic and natural. Our quantitative experimental results also demonstrate superiority of this technique of existing state-of-the-art inpainting methods.

Keywords: Multiple Sclerosis, Lesions Inpainting, Non-Local Module, MRI, Partial Convolution

2010 MSC: 00-01, 99-00

1. Introduction

Multiple sclerosis (MS) is an immune-mediated disease that results in progressive damage to the central nervous system (CNS). MS is characterised by

[☆]Fully documented templates are available in the elsarticle package on CTAN.

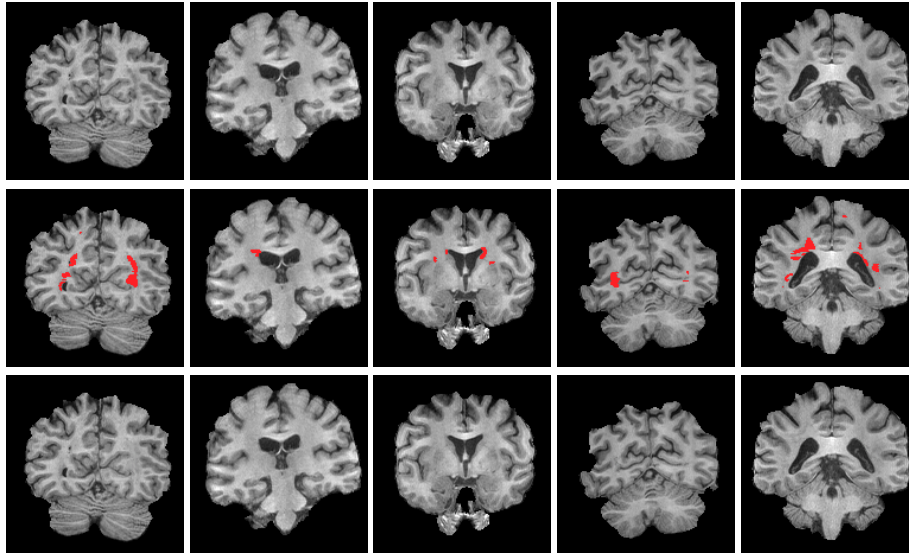


Figure 1: Lesion inpainting examples using non-local partial convolutions. **Top Row:** coronal MS images from 5 patient **Middle Row:** superimposed lesion mask (red) derived from FLAIR images (not shown) **Bottom Row:** inpainted results.

focal inflammatory demyelinating lesions in both the grey and white matter, formation of which is may be accompanied by acute episodes of neurological dysfunction or relapses. In the longer term, progressive axonal loss and gliosis, both within lesions and normal appearing white matter (NAWM), results in brain atrophy and the accumulation of physical and cognitive disability.

Accordingly, morphological measurements derived from magnetic resonance imaging (MRI) scans are extensively utilized to monitor disease progression [1, 2]. The link between brain volume loss and the evolution of motor and cognitive disability in MS is well established. Estimation of brain atrophy is therefore considered an important surrogate for, and predictor of, clinical disability.

The measurement of brain substructures, such as white matter, gray matter and cerebrospinal fluid (CSF), requires brain tissue segmentation on MRI images [3, 4, 5]. Based on voxel intensity, substructures are independently measured. However, in the presence of white matter lesions, which are of similar intensity to normal grey matter, substructure volume measurements may be erroneous [6, 7, 8, 9]. Misclassification of MS lesions generates biased white and grey matter volume estimations, and necessitates the development of effective means to address the impact of lesions on morphological analysis.

Imaging processing methods currently use filling algorithms to inpaint lesions with normal appearing white matter-like intensities. Both local and global white matter lesion inpainting methods have been proposed [10]. Local inpainting methods base filling algorithms on surrounding tissue, whilst global methods employ an average intensity derived from the whole brain white matter. More recent models [11] utilize a normal tissue intensity distribution. By sampling the

distribution, the lesion is filled with the most probable white matter intensity. Based on this approach, Magon *et al.* [12] proposed slice by slice inpainting of the whole brain and Valverde *et al.* [13] performed lesion filling with mean intensity of two periplaque NAWM voxels.

The above approaches assume that lesions should, without exception, be filled with white matter like intensities. This hypothesis is flawed, as lesions may occur within grey matter or overlap white and adjacent grey matter. Additionally, lesion masks are generally provided by either manual labeling or automated methods. Automated lesion segmentation often results in misclassifications, and in some cases generates "lesions" that inappropriately involve the CSF. In such circumstances, the aforementioned lesion inpainting methods fail.

Rather than filling lesions with white matter like intensity only, Battaglini *et al.* [14] inpainted lesions with either white matter or grey matter using a histogram derived from peri-lesional white and grey matter, resulting in improved blending with neighbourhood normal appearing tissues. In the method described by Guizard *et al.* [15], lesions are first pre-filled with the median of intensity from surrounding normal-appearing tissues, and the most similar patches calculated using only the nearby regions. The same group subsequently proposed an iterative, concentric patch-based filling approach to preserve local anatomical information [16]. Similarly, Prados *et al.* [17] use neighbourhood patches to fill lesions with the most appropriate intensity; and exploit a minimal kernel-based convolution to achieve better inpainting effects.

In the general (non-medical) computer vision community, various inpainting techniques have been proposed to remove objects, texts or scratches from images using the remaining information in the image. Examples include (1) an "onion-peel" strategy that fills regions of interest (ROI) from an outermost to innermost concentric ring with reference to available patches has been described [18]; (2) an exemplar-based method [19] that fills specific regions by directly copying similar patches extracted from the whole image; and (3) synthesis of ROI intensities with textures from matched patches by applying a Non-Local Means algorithm [20, 21]. Advances in deep learning have significantly enhanced inpainting effects. Initial deep learning based inpainting frameworks, in which networks are trained to fill ROI contents based on its surroundings, have been described by a number of groups [22, 23, 24, 25]. These techniques suffer from both pixel-wise reconstruction loss and adversarial loss, and tend to generate artifacts between inpainted and neighbourhood areas. The addition of more convolutions, which integrates distant areas into inpainting algorithms, has been applied [22, 26] to mitigate the appearance discrepancies introduced by deep learning; and further optimization undertaken [27] to minimize the difference between filled regions and their neighbourhood. However, increasing convolutional layers and applying optimization are computationally intensive and are substantially more time consuming.

Liu *et al.* [28] have recently described a model that uses so-called partial convolutions, unlike traditional convolutional layers, which masks the convolution and thus performs convolution operations on non-missing pixels only. By incorporating VGG-16 [29] based features into loss function, [28] achieves remarkable

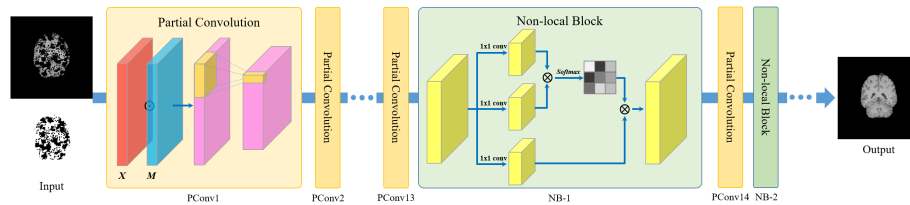


Figure 2: Network architecture. The network takes both the T1 brain image and associated lesion mask as inputs, and then outputs inpainted results. In the training stage, the lesion areas are randomly synthesized to generate training masks. Two non-local blocks are inserted after PCConv13 and PCConv14, respectively.

inpainting effects. Based on the superiority of deep learning based techniques for inpainting of non-medical color images, we explore MS lesion inpainting under this framework (Fig. 1). Unlike color images, which are morphologically heterogeneous, the human brain consists of defined, reproducible structures such as WM, GM and CSF. More specifically, color images may contain arbitrary object types, such as scenery, faces, furniture that do not necessarily have uniform structure or properties. Therefore, when designing deep learning frameworks for color image ROI inpainting, very few assumptions can be made. By contrast, the relative uniformity of brain structure and appearance among individuals permits the integration of a deep learning framework with a non-local module to facilitate brain lesion inpainting.

The non-local module links one brain voxel with spatially long range brain voxels. Hence, the response of one voxel is a weighted sum of the features from all relevant local (neighbourhood) and distant (all voxels beyond neighbourhood) voxels. By modeling long range dependencies, the algorithm is able to inpaint lesion area with reference to the whole brain area rather than only the local neighbourhood. Therefore, we propose a model with the following distinguishing features: 1) the model does not make any assumption that the lesion area is/should be filled with white matter like intensity; 2) the model integrates of global brain information based on the consistency of brain structure, rather than using neighbourhood texture as the key factor to determine filled intensity; 3) when a lesion mask that erroneously overlaps with normal tissues (such as CSF) is supplied as an input, our algorithm is able to inpaint the lesion ROI with appropriately disposed normal tissue intensities. In other words, the algorithm is able to maintain normal tissue architecture rather than simply filling lesion masks ROIs with white matter like intensity. Synthetic lesions can be generated by non-linear co-registration of MS lesion masks with healthy subject MRI scans to validate the technique and provide a ready-made ground truth for comparative experiments. Herein, we demonstrate the effectiveness and efficiency of MS lesion inpainting using these methods.

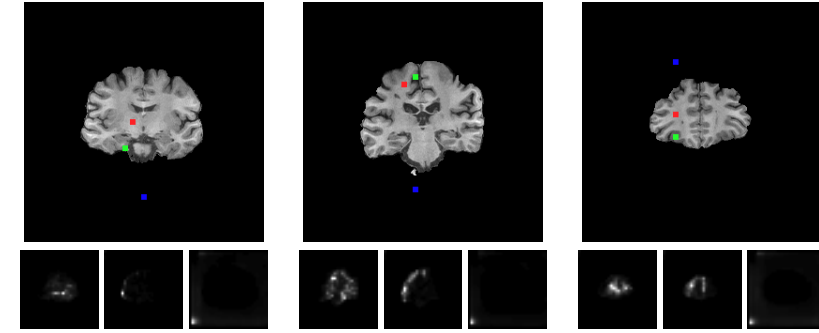


Figure 3: The attention maps of color coded queries. **Top Row:** Brain slices with query locations **Bottom Row:** attention maps **Red Dot:** query on white matter or thalamus **Green Dot:** query on grey matter **Blue Dot:** query on background(regions outside brain area). Here, the size of attention map is 64×64 , while the size of testing slice is 256×256 . Note that the whitest regions in the grayscale attention map are best correlated to the queries and vice versa. Despite differing resolution between the attention map and testing slice, the whitest regions within attention maps are appropriately located in regions that correspond to the respective queries. The attended areas all are within the global domain rather than a local region.

2. Material and methods

Our proposed inpainting model is stacked by partial convolutions and simultaneously integrates several non-local blocks. We first explain concepts of partial convolution and non-local block, and then introduce network architecture and implementation.

2.1. Partial convolution

In general, partial convolution operation is consist of two parts: a partial convolutional layer and mask updating.

Suppose X refers to the feature values or intensity of the MRI slice, M is the binary mask indicating lesion and normal brain tissue areas. The partial convolution is defined as:

$$x = \begin{cases} W^T(X \odot M) \frac{1}{sum(M)} + b, & \text{if } sum(M) > 0 \\ 0, & \text{otherwise} \end{cases}, \quad (1)$$

where W and b are convolutional weights and bias respectively. By taking mask M into account, the output of the partial convolution only relies on unmasked values.

Concurrently, mask M is updated as follows:

$$m = \begin{cases} 1, & \text{if } sum(M) > 0 \\ 0, & \text{otherwise} \end{cases}. \quad (2)$$

2.2. Non-Local block

Traditional convolution operations focus on the cues within the ROI neighbourhood and thus ignore global information. Even with a large receptive field, convolution operations are still based on local information. In contrast, the non-local module aims to perform inpainting by taking long distance cues into consideration. More specifically, given a specific location within brain slice, the non-local module will compute the responses between this location and its counterparts within the whole image, exploiting the relative homogeneity and internal correlation of brain structure.

Given feature maps $x \in R^{C \times N}$ from a partial convolution layer, the non-local block then transforms x into three feature spaces f , g and h , where $f(x) = W_f x, g(x) = W_g x$ and $h(x) = W_h x$. Here, W_f , W_g and W_h are weight matrices to be learned and such linear operations can be implemented as 1×1 convolutions.

The self-attention module subsequently requires $f(x)$ and $g(x)$ for attention map calculation. More specifically, the attention map a can be obtained by:

$$a_{ji} = \text{softmax}(f(x_i)^T g(x_j)), \quad (3)$$

Here, a_{ji} is namely the softmax operation along the dimension j . Evidently, the softmax operation here measures the similarity between i^{th} and j^{th} locations in x . The self-attention form is finally expressed as:

$$s = ah(x). \quad (4)$$

This is to say that the self-attention module computes a response at a location by attending all positions and taking their weighted average in an embedding space. Subsequently, the self-attention module is incorporated into the non-local block as:

$$y = W_s s + x, \quad (5)$$

where y refers to the non-local block and W_s is the weight matrix of the 1×1 convolution to be learned. Initially, W_s is set as zero and thus y is exactly x , which means the inpainting task only relies on neighbourhood cues initially. After gradually updating W_s , more non-local evidence is considered in the training and future inpainting. In our model, the non-local block is integrated with a partial convolution layer. As shown in the first row of Fig. 3, the red, green, blue dots represent query locations within the white matter, grey matter and background (regions outside brain area) respectively. In the second row, the corresponding attention maps of the color coded query dots are displayed. Note that the size of each attention map here is 64×64 (more details in section 2.3), while the size of input MRI slice is 256×256 . Meanwhile, the most-attended regions are the whitest areas in the attention map and vice versa. Though the size of the attention map and input slice are discrepant, the attended area approximates its expected anatomic counterpart. For example, attended regions for grey matter queries are generally located at the periphery of the brain

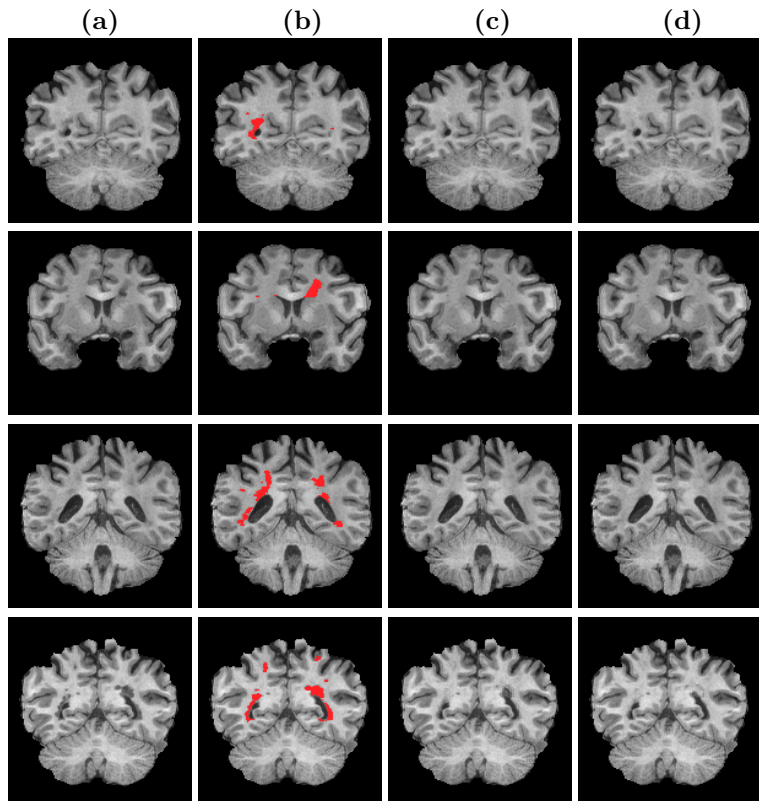


Figure 4: Effect of the non-local module on lesion inpainting. (a) MS data. (b) Lesion mask generated using a semi-automated thresholding technique by an expert neuroimaging analyst using coregistered FLAIR images. Inpainting results without (c) and with (d) non-local module. Lesion inpainting is affected by proximity to the lateral ventricles without the non-local module. In contrast, lesion-filling results in this region are cleaner and more realistic with the non-local module.

in areas that approximate the location of the cortex; and attended regions for background queries are consistently located outside the brain area in attention maps. Moreover, Fig. 4 illustrates the inpainting effects with and without the non-local module.

2.3. Network design and implementation

Our network is based on the architecture described by Liu *et al.* [28] (Table 1), and exploits partial convolutional layers to stack the network rather than traditional convolutional layers. Both the encoder and decoder in network has 8 layers. The feature maps and binary masks from encoder stage are concatenated by skip links into the decoder stage. Furthermore, the size of the binary mask is exactly matched with the respective input brain slice and will be updated in the following encoder and decoder stages. The values of weight matrix and bias for the binary mask are initially set as 1 and 0, and kept fixed during training.

Likewise, the values of weight matrices and bias for f , g and h are initially set as 1 and 0, respectively, but only bias is fixed during training.

However, the integration of a non-local module into the network is computationally intensive. In order to facilitate computational efficiency, the number of channels with feature spaces f , g and h is therefore reduced to half of the number of channels of x in our method. Meanwhile, in Eq.5 the number of channels of s can be increased with W_s so as to match the number of channels of x . Additionally, a max pooling layer is applied after g and h to speed computation. In our case, the stride of max pooling layer is 2.

In the experimental work presented, the following principals are applied with respect to the integration of non-local blocks:

1. Non-local blocks should be inserted in the decoder stage, where they are closer to the output of the network.
2. The more non-local blocks embedded within the network, the more accurate the inpainting effects are.

Based on Eq. 5, it is optimal to insert two non-local blocks directly after PConv13 and PConv14, respectively. Though some techniques are applied to speed up computation, the maximum number of added non-local blocks is 2. PConv15 is physically the closest layer to the output layer but this layer’s feature maps are relatively larger than those relating to PConv13 and PConv14.

Therefore, computational efficiency is improved by not inserting a non-local block after PConv15, while not sacrificing model accuracy at same time. The training set contains approximately 50800 slices; the initial learning rate is set as 0.00005 and the batch size as 10. The learning rate for fine-tuning is set as 0.00001. There are approximately 125 and 10 epochs for training and fine-tuning respectively.

2.4. Loss function

Let I_{out} be the output of the above network, it will then be fed into the following loss function for more accurate per-pixel reconstruction:

$$L_{total} = L_{valid} + 6L_{hole} + 0.05L_{perceptual} + 120L_{style} + 0.1L_{tv}, \quad (6)$$

where L_{valid} and L_{hole} are the loss terms aiming to enhance per-pixel reconstruction accuracy of the whole brain slice including any inpainted region. The inclusion of $L_{perceptual}$ and L_{style} ensure that the inpainted areas have a more realistic and natural texture and structure. Besides, the 3D median filter is applied to alleviate the minor inconsistency between every slice.

Rather than directly accepting output I_{out} , $L_{perceptual}$ and L_{style} only accept feature vectors by projecting I_{out} into a high level feature space with a pretrained VGG-16 network. Here, the layers pool1, pool2, pool3 in VGG-16 are utilized for feature extraction in our work. Furthermore, since the VGG-16 network requires an image of at least 236×236 , all brain slices in our model are padded to size 256×256 for training and testing.

Lastly, L_{tv} represents the total variation term for smoothing penalty. We adopt the same hyperparameter values of loss term weights as described by Liu *et al.* in [28].

Partial Convolution based Network

Encoder	Decoder
PConv1	Concat1(NearestUpSample1/ PConv7) PConv9
PConv2	Concat2(NearestUpSample2/ PConv6) PConv10
PConv3	Concat3(NearestUpSample3/ PConv5) PConv11
PConv4	Concat4(NearestUpSample4/ PConv4) PConv12
PConv5	Concat5(NearestUpSample5/ PConv3) PConv13
PConv6	Concat6(NearestUpSample6/ PConv2) PConv14
PConv7	Concat7(NearestUpSample7/ PConv1) PConv15
PConv8	Concat8(NearestUpSample8/ Input) PConv16(Output Layer)

Table 1: **Partial Convolution based Network.** **PConv**: Partial Convolution Layer **Concat**: concatenate the previous nearest neighbour upsampled results with feature maps from corresponding PConv in encoder stage. Two non-local blocks are inserted directly after PConv13 and PConv14, respectively.

2.5. Data

Three different MRI datasets were used in training and testing stages.

1. IXI dataset: a publically available collection of 665 MR images from normal, healthy subjects (<https://brain-development.org/ixi-dataset/>). The IXI data was acquired on three different MRI scanners (Philips 3T system, Philips 1.5T system, GE 1.5T system). The acquisition protocol for each subject includes the following sequences: T1, T2, proton density (PD), and diffusion-weighted images (15 directions). Here, we use only T1 images, but our method can be applied to other MRI sequences. Brain volumes were randomly selected for training (n=300) and testing (n=50). All brain volumes were normalized with mean and variance before training and testing. Synthetic lesions, generated by non-linear co-registration with MS lesion masks (see below), were applied to the 50 selected testing volumes and regarded as ground truth for subsequent evaluation.

2. The second dataset consists of MRI scans from 20 patients with relapsing-remitting multiple sclerosis (RRMS). T1-weighted sequences were acquired on a 3T GE Discovery MR750 scanner(GE Medical Systems, Milwaukee, WI) with the following parameters: FOV 256mm, slice thickness 1mm, TE 2.7ms, TR 7.2ms, Flip angle 12, Pixel spacing 1mm. Acquisition Matrix (Freq. Phase) is 256×256, which results in 1mm isotropic acquisition voxel size. The reconstruction matrix is 256×256. This data, which has no ground truth, was utilized for demonstration in Fig. 1, Fig. 3 and Fig. 4.

3. The third dataset contains MRI scans from 50 patients with RRMS and is primarily exploited for generating synthetic lesions on the IXI healthy control testing dataset. Sagittal FLAIR CUBE (pre-contrast) sequences were acquired on a 3T GE Discovery MR750 scanner (GE Medical Systems, Milwaukee, WI) with the following parameters: FOV 256mm, slice thickness 1.2mm, TE 163ms, TR 8000ms, TI 2180ms. Acquisition Matrix (Freq. Phase) is 256×244 . Additionally, pre-contrast axial T1-weighted (IR-FSPGR) sequences were acquired with the following parameters: FOV 256mm, slice thickness 1mm, TE 3.2ms, TR 8.1ms, TI 900ms, pixel spacing 1mm. Acquisition Matrix (Freq. Phase) is 256×256 , which results in 1mm isotropic acquisition voxel size. The reconstruction matrix is 256×256 . All lesion ROIs for MS cases were performed semiautomatically on FLAIR using JIM6.0 (<https://www.xinapse.com>) by experienced MS neuroimaging analyst.

All datasets were acquired cross-sectionally and included both female and male subjects.

3. Results

We compared four lesion inpainting algorithms on T1 images, including 1) the lesion filling tool included in FSL v6.0 [30]. FSL is a comprehensive library of analysis tools for FMRI, MRI and DTI brain imaging data; 2) multi-time-point modality-agnostic lesion filling method (MMLF); and 3) partial convolutions(PC) based inpainting method (PC); and 4) our proposed non-local partial convolutions (NLPC) inpainting method. Both the FSL and MMLF tools are publically available. To the best of our knowledge, MMLF is the most recently described lesion filling method in the medical image field; whereas PC based inpainting method is considered state-of-the art in the computer vision community.

3.1. Qualitative evaluation

In this experiment, white matter lesions masks derived from MS FLAIR images were used to inpaint matching, coregistered MS T1 images; and to create and inpaint synthetic lesions generated on non-linearly coregistered T1 images from healthy controls. Since visible T1 hypointensities are usually a subset of T2 (FLAIR) hyperintensities, the FLAIR-derived manually labelled lesion mask may involve isointense regions on matching MS T1 images. Synthetic lesions generated by non-linear co-registration of MS lesion masks and healthy control T1 images is also highly likely to produce lesion masks that erroneously overlap with tissues other than white matter. Synthetic lesions were generated on T1 brain images from 50 healthy controls and inpainted with FSL, MMLF, PC and NLPC, respectively. Inpainted images from all 4 methods were visually inspected and blindly rated by a neuroimaging expert (MB) based on similarity to the ground truth (original) images. The NLPC method best approximated the ground truth in the majority (28/50) of cases reviewed. Fig. 5, Fig. 6 and Fig. 7 provides examples of visual comparison of our inpainting method with existing methods.

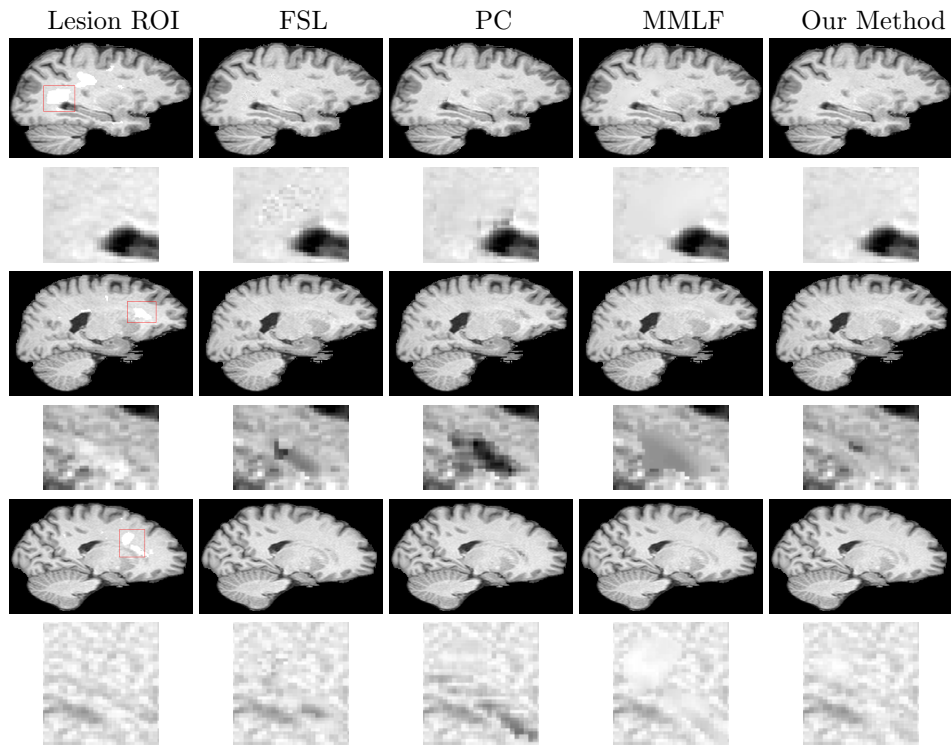


Figure 5: The sagittal and zoomed views of the T1 slice with fake lesions mask. Note the noisy samples generated by FSL and PC methods, the blurred boundaries obtained by MMLF method.

3.2. Quantitative evaluation

Since MRI scans acquired from patients with MS have no lesion-region ground truth, quantitative analysis was performed using synthetically generated lesions in MRI slices of 50 healthy subjects. The original, pre-lesional tissue ROI intensities were regarded as the ground truth for comparison. We employed several quantitative approaches to facilitate comparison of the MMLF, FSL, PC inpainting techniques, and our own method. The mean square error (MSE) was adopted to measure the difference between the inpainted and ground truth intensities; a smaller MSE value signifies more realistic filled intensities. As a primary goal of lesion inpainting is improve the accuracy of brain substructure volume measurement, we also evaluated WM, GM, and CSF volumes using SIENAX on the native healthy control T1 images (ground truth) and images with synthetic lesions inpainted with each technique. Closer approximation to the ground truth volumes therefore denotes a more accurate the inpainting technique. The results of quantitative assessment are shown in Table 2.

3.2.1. Synthetic lesion generation

The process of lesion generation is as follows:

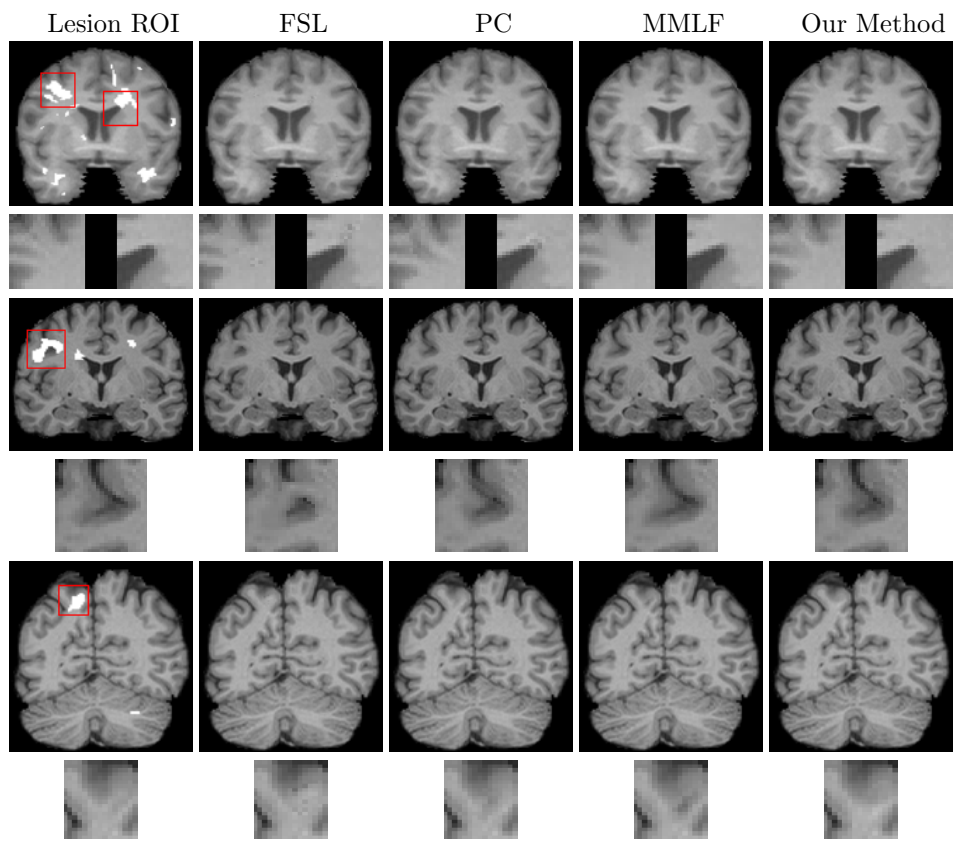


Figure 6: The coronal and zoomed views of the T1 slice with fake lesions mask. In coronal views, the artifacts generated by FSL and PC are more obvious. However, the difference between MMLF and our method NLPC can be seen clearly in the last row.

1. Whole brain tissue was extracted from all images with the Brain Extraction Tool (BET). Note that the tool BET is part of FSL.
2. MS brain volumes were firstly affine and then non-rigidly registered to healthy brain volumes.
3. Binary lesion masks derived from MS FLAIR images were registered to the healthy T1 images with estimated non rigid transformations.
4. Synthetic lesion masks generated on healthy subject T1 images were constrained within the relevant whole brain mask derived in Step 1.

Lesion inpainting is not dependent on the intensities of lesion area to be filled; therefore, none of the techniques generate noise of any kind within the region of lesion mask.

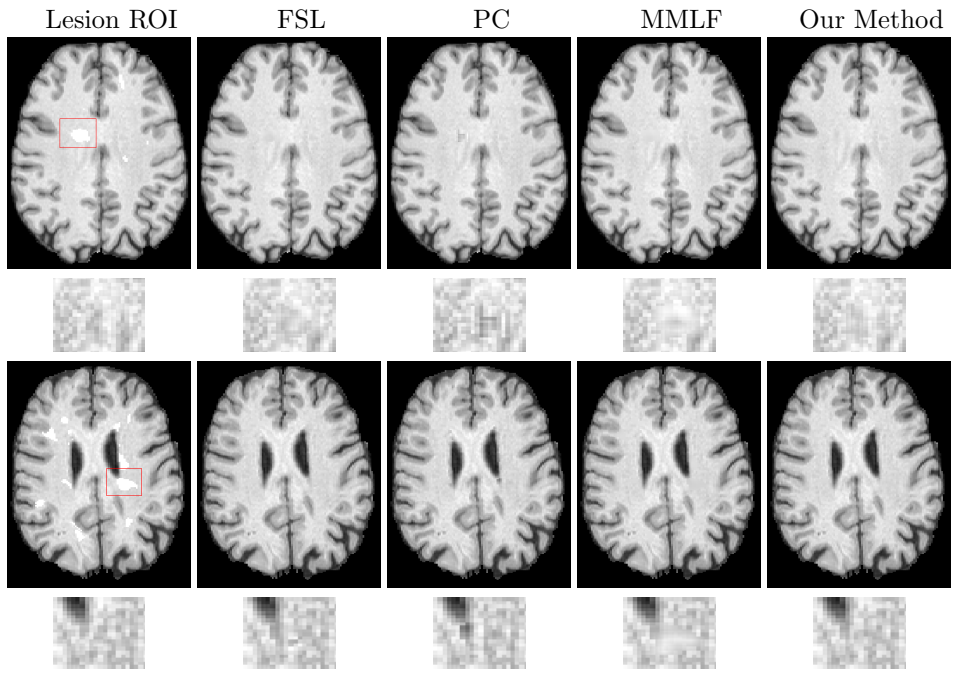


Figure 7: The axial and zoomed views of the T1 slice with fake lesions mask. Note the noisy samples generated by FSL and PC methods, the blurred boundaries obtained by MMLF method.

3.2.2. Synthesis error

The mean square error is defined as:

$$MSE = \frac{1}{N} \sum_i^n (I_T - I_0)^2, \quad (7)$$

where n is the number of testing volumes and N is the number of lesion voxels. I_T and I_0 refer to the intensities of ground truth volume and inpainted volume, respectively.

3.2.3. WM, GM, CSF Volume Error

SIENAX-based [31] segmentation was performed on healthy control T1 brain volumes, yielding ground truth WM, GM and CSF volumes respectively. Following insertion of synthetic lesions into T1 brain slices and lesion inpainting by each method, SIENAX-derived WM, GM and CSF volumes were re-estimated. To measure the impact of lesion inpainting using each method, we measured the similarity of substructure volumes derived from T1-inpainted slices to those derived from native (ground truth) images by calculating both the mean error (ME) and mean absolute error (MAE). The mean error is defined as:

$$ME = 100 \frac{V_T - V_0}{V_0}, \quad (8)$$

where V_0 and V_T are ground truth volume and the volume estimated after inpainting with different methods respectively.

Table 2: Quantitative evaluation results. There are 5140 slices with fake lesions were used for evaluation here. The first row shows mean square error (MSE) in comparison with ground truth. The rows 2-4 show mean error (ME). It indicates that all methods tend to expand GM and CSF volumes while reduce WM volume. The rows 5-7 show mean absolute error (MAE). In general, our method outperforms other methods with MSE, ME and MAE.

	FSL	PC	MMLF	Proposed
MSE	0.000915	0.001647	0.000520	0.000482
ME(GM)	0.0323	0.0394	0.0317	0.0274
ME(WM)	-0.0526	-0.0638	-0.0658	-0.0503
ME(CSF)	0.0095	0.0007	0.0230	0.0423
MAE(GM)	189.023	227.735	171.854	150.383
MAE(WM)	230.260	281.297	270.596	217.103
MAE(CSF)	58.5919	60.615	73.296	130.388

4. Discussion

The proposed non-local partial convolutions (NLPC) lesion inpainting method, which exploits a non-local module under the framework of deep learning, demonstrated quantitative and qualitative superiority over the FSL inpainting tool, based on local intensity histogram information; MMLF, a state-of-the-art method in neuroimaging that fills lesions with the most plausible texture within a larger neighbourhood; and PC, the most recent deep learning based inpainting approach in the computer vision field.

Blinded qualitative assessment confirmed the superiority of our method (NLPC) for inpainting synthetic lesions embedded in healthy control data (examples shown in Figs. 5 - 7). The proposed method is therefore not affected by neighbouring structures; rather, it learns to fill local lesions by referring to global structures and texture information. As illustrated in Figs. 5 - 7, the inpainted results of other methods are more or less affected by neighbourhood, especially when the white matter lesion is close to ventricle or grey matter. In the quantitative evaluations (Table 2), the proposed method generated the smallest MSE and therefore the most realistic inpainting result of all four techniques. Moreover, ME and MAE values show that GM, WM, CSF volume estimates using SIENAX on brain volumes inpainted by our method are most accurate.

5. Conclusion

We propose a new deep learning model for realistic lesion inpainting in MRI slices by exploiting the non-local module. Rather than considering the neighbourhood texture for lesion filling, our method inpaints lesion areas with the most plausible intensities by observing the structure and texture information contained within the whole image. To achieve this, the non-local module compares similarities between the features within lesion regions and remaining brain areas. Although some existing methods take into account non-local information, they are limited by algorithms that search for similar patches within a constrained bounding box, rather than the whole domain. As such, these methods prove inferior to those described in this work. Moreover, integrating the non-local module under the framework of deep learning generates an effective algorithm that outperforms traditional non-local based methods and can be incorporated into image analysis pipelines for more accurate quantitative assessment of brain substructure volumes.

References

References

- [1] O. Ganiler, A. Oliver, Y. Diez, J. Freixenet, J. Vilanova, B. Beltran, L. Rami-Torrent, A. Rovira, X. Llad, A subtraction pipeline for automatic detection of new appearing multiple sclerosis lesions in longitudinal studies, *Neuroradiology* 56 (5) (2014) 363–374, <http://dx.doi.org/10.1007/s00234-014-1343-124590302>.
- [2] H. Kearney, M. Rocca, P. Valsasina, L. Balk, J. Sastre-Garriga, J. Reinhardt, S. Ruggieri, A. Rovira, C. Stippich, L. Kappos, T. Sprenger, P. Tortorella, M. Rovaris, C. Gasperini, X. Montalban, J. Geurts, C. Polman, F. Barkhof, M. Filippi, D. Altmann, O. Ciccarelli, D. Miller, D. Chard, Magnetic resonance imaging correlates of physical disability in relapse onset multiple sclerosis of long disease duration, *Multiple Sclerosis* (Houndmills, Basingstoke, England) 20 (1) (2014) 72–80, <http://dx.doi.org/10.1007/s00234-014-1343-124590302>.
- [3] A. Zijdenbos, R. Forghani, A. Evans, Automatic quantification of ms lesions in 3d mri brain data sets: validation of insect, in: *Medical Image Computing and Computer-Assisted InterventionMICCAI98*, 1998, pp. 439–448.
- [4] K. Nakamura, E. Fisher, Segmentation of brain magnetic resonance images for measurement of gray matter atrophy in multiple sclerosis patients, *Neuroimage* 44 (2009) 769–776, doi: 10.1016/j.neuroimage.2008.09.059.
- [5] D. T. Chard, J. S. Jackson, D. H. Miller, C. A. M. Wheeler-Kingshott, Reducing the impact of white matter lesions on automated measures of brain gray and white matter volumes, *J. Magn. Reson. Imaging* 32 (2009) 223–228. doi:10.1002/jmri.22214.

- [6] M. Battaglini, M. Jenkinson, N. De Stefano, Evaluating and reducing the impact of white matter lesions on brain volume measurements, *Human Brain Mapping* 33 (2012) 2062–2071, <http://dx.doi.org/10.1002/hbm.21344>21882300.
- [7] R. Gelineau-Morel, V. Tomassini, M. Jenkinson, H. Johansen-Berg, P. Matthews, J. Palace, The effect of hypointense white matter lesions on automated gray matter segmentation in multiple sclerosis, *Human Brain Mapping* 33 (2012) 2802–2814, <http://dx.doi.org/10.1002/hbm.21402>21976406.
- [8] M. Sdika, D. Pelletier, Nonrigid registration of multiple sclerosis brain images using lesion inpainting for morphometry or lesion mapping, *Human Brain Mapping* 30 (2009) 1060–1067, <http://dx.doi.org/10.1002/hbm.20566>18412131.
- [9] Y. Diez, A. Oliver, M. Cabezas, Valverde, S., R. Mart, J. Vilanova, L. Rami-Torrent, A. Rovira, X. Llad, Intensity based methods for brain mri longitudinal registration. a study on multiple sclerosis patients, *Neuroinformatics* 12 (2014) 365–379, <http://dx.doi.org/10.1007/s12021-013-9216-z>24338728.
- [10] M. Sdika, D. Pelletier, Nonrigid registration of multiple sclerosis brain images using lesion inpainting for morphometry or lesion mapping, *Hum. Brain Mapp.* 30 (2008) 1060–1067. doi:<http://dx.doi.org/10.1002/hbm.20566>.
- [11] D. Chard, J. Jackson, D. Miller, C. Wheeler-Kingshott, Reducing the impact of white matter lesions on automated measures of brain gray and white matter volumes, *J. Magn. Reson. Imaging.* 32 (2010) 223–228. doi:<http://dx.doi.org/10.1002/jmri.22214>.
- [12] S. Magon, L. Gaetano, M. Chakravarty, J. Lerch, Y. Naegelin, C. Stippich, L. Kappos, E. Radue, T. Sprenger, White matter lesion filling improves the accuracy of cortical thickness measurements in multiple sclerosis patients: a longitudinal study, *BMC Neurosci.* 106.
- [13] S. Valverde, A. Oliver, X. Llad, A white matter lesion-filling approach to improve brain tissue volume measurements, *Neuroimage Clin.* 6 (2014) 86–92.
- [14] M. Battaglini, M. Jenkinson, N. D. Stefano, Evaluating and reducing the impact of white matter lesions on brain volume measurements., *Hum. Brain Mapp.* 33 (2014) 2062–2071. doi:<http://dx.doi.org/10.1002/hbm.21344>.
- [15] N. Guizard, K. Nakamura, P. Coupe, D. Arnold, D. Collins, Non-local ms mri lesion inpainting method for image processing, in: *The endMS Conf.*, 2013.

- [16] N. Guizard, K. Nakamura, P. Coup, S. Vladimir, V. Fonov, D. Arnold, D. Collins, Non-local means inpainting of ms lesions in longitudinal image processing, *Front. Neurosci* 456.
- [17] F. Prados, M. J. Cardoso, B. Kanber, O. Ciccarelli, d. S. O. R. Kapoor, Claudia A.M. Gandini Wheeler-Kingshott b, A multi-time-point modality-agnostic patch-based method for lesion filling in multiple sclerosis, *Neuroimage* 139 (2016) 376–384. doi:<https://doi.org/10.1016/j.neuroimage.2016.06.053>.
- [18] A. A. Efros, T. K. Leung, Texture synthesis by non-parametric sampling, in: *International Conference on Computer Vision*, 1999.
- [19] A. Criminisi, P. Perez, K. Toyama, Region filling and object removal by exemplar-based image inpainting, *IEEE Trans. Image Process* 13 (2004) 1200–1212. doi:[doi:10.1109/TIP.2004.833105](https://doi.org/10.1109/TIP.2004.833105).
- [20] A. Wong, J. Orchard, A nonlocal-means approach to exemplar-based inpainting, in: *International Conference on Image Processing*, 2008.
- [21] A. Buades, B. Coll, J. M. Morel, A non-local algorithm for image denoising, in: *Comput. Vision Pattern Recogn.*, 2005, pp. 60–65.
- [22] S. Iizuka, E. Simo-Serra, H. Ishikawa, Globally and locally consistent image completion, *ACM Transactions on Graphics (TOG)* 36 (4) (2017) 107.
- [23] Y. Li, S. Liu, J. Yang, M.-H. Yang, Generative face completion, arXiv preprint [arXiv:1704.05838](https://arxiv.org/abs/1704.05838).
- [24] D. Pathak, P. Krahenbuhl, J. Donahue, T. Darrell, A. A. Efros, Context encoders: Feature learning by inpainting, in: *IEEE Conference on Computer Vision and Pattern Recognition*, 2016, pp. 2536–2544.
- [25] R. Yeh, C. Chen, T. Y. Lim, M. Hasegawa-Johnson, M. N. Do, Semantic image inpainting with perceptual and contextual losses, arXiv preprint [arXiv:1607.07539](https://arxiv.org/abs/1607.07539).
- [26] F. Yu, V. Koltun, Multi-scale context aggregation by dilated convolutions, arXiv preprint [arXiv:1511.07122](https://arxiv.org/abs/1511.07122).
- [27] C. Yang, X. Lu, Z. Lin, E. Shechtman, O. Wang, H. Li, High-resolution image inpainting using multi-scale neural patch synthesis, arXiv preprint [arXiv:1611.09969](https://arxiv.org/abs/1611.09969).
- [28] G. Liu, F. A. Reda, K. J. Shih, T.-C. Wang, A. Tao, B. Catanzaro, Image inpainting for irregular holes using partial convolutions, arXiv preprint [arXiv:1804.07723](https://arxiv.org/abs/1804.07723).
- [29] K. Simonyan, A. Zisserman, Very deep convolutional networks for large-scale image recognition, arXiv preprint [arXiv:1409.1556](https://arxiv.org/abs/1409.1556).

- [30] M. Jenkinson, C. Beckmann, T. Behrens, M. Woolrich, S. Smith, Fsl, *NeuroImage* 62 (2012) 782–790.
- [31] S. Smith, Y. Zhang, M. Jenkinson, J. Chen, P. Matthews, A. Federico, N. De Stefano, Accurate, robust and automated longitudinal and cross-sectional brain change analysis, *NeuroImage* 17 (1) (2002) 479–489.