

OCTID: Optical Coherence Tomography Image Database

Peyman Gholami^{1,*}, Priyanka Roy^{*}, Mohana Kuppuswamy Parthasarathy,
Vasudevan Lakshminarayanan

*Theoretical & Experimental Epistemology Lab (TEEL), School of Optometry and Vision Science, University of Waterloo, 200
University Ave. West Waterloo, ON, Canada N2L 3G1*

Abstract

Optical coherence tomography (OCT) is a non-invasive imaging modality which is widely used in clinical ophthalmology. OCT images are capable of visualizing deep retinal layers which is crucial for the early diagnosis of retinal diseases. In this paper, we describe a comprehensive open-access database containing more than 500 high-resolution images categorized into different pathological conditions. The image classes include Normal (NO), Macular Hole (MH), Age-related Macular Degeneration (AMD), Central Serous Retinopathy, and Diabetic Retinopathy (DR). The images were obtained from a raster scan protocol with a 2mm scan length and 512x1024 pixels resolution. We have also included 25 normal OCT images with their corresponding ground truth delineations which can be used for accurate evaluation of OCT image segmentation.

Keywords: Optical Coherence Tomography, Image database, Image processing, retinal disease

1. Introduction

Optical Coherence Tomography (OCT)

Optical Coherence Tomography (OCT) is a non-invasive imaging modality which is of great importance in clinical ophthalmology. OCT is utilized for the cross-sectional visualization of the retinal structures which is crucial for the early diagnosis of several pathologies that affect the retina and the optic nerve head, such as macular degeneration and macular edema [1]. Studies have shown that OCT can also be used to monitor the functionality of tissues [2] and blood flow within the retina as well as assess the level of blood oxygenation [3,4].

There are several SD-OCT databases available in the literature [5-10]. Most of these databases have several limitations, e.g., some have a limited number of images [8] and some only contain images from normal subjects [6]. However, the shape and the thickness of the retinal layers change based on different ocular conditions and OCT images are capable of visualizing these changes. Therefore, these databases are not able to provide such information. Some other databases have only focused on a specific ocular disease such as age-related macular degeneration [7] or glaucoma [8]. However, most of these databases differ with each other in terms of resolution, quality, size, and other

¹ email:pgholami@uwaterloo.ca

* These authors have contributed equally to this work

properties of the images and due to these differences, comparing them is a challenging task. All the available OCT databases are discussed in detail in a recent review paper [9]. A database which contains different ocular conditions with the same image characteristics would be an ideal solution for researchers in this field.

Such databases are of practical importance for evaluating the performance of different segmentation and classification algorithms. Moreover, such an organized database helps researchers to create more efficient methods for computer-aided identification of ocular diseases. . We have created an open-access OCT image database which includes high-resolution OCT images with different retinal related diseases. We also include manual segmentation by an experienced clinician of a set of images as the ground truth delineations and these can be used as the gold standard for the evaluation of different image analysis methods.

2. Structure of the Database

Database Images properties

The database contains OCT images categorized into different diseases and includes high-resolution jpeg images that can be downloaded as zip files. The database consists of more than 500 spectral-domain OCT volumetric scans, consisting of four categories: Normal (NO), Macular Hole (MH), Age-related Macular Degeneration (AMD), Central Serous Retinopathy, and Diabetic Retinopathy (DR). The images were from a raster scan protocol with a 2mm scan length, containing 512x1024 pixels, captured using a Cirrus HD-OCT machine (Carl Zeiss Meditec, Inc., Dublin, CA) at Sankara Nethralaya (SN) eye hospital, Chennai, India. In each volumetric scan, a fovea-centered image was selected by an experienced clinical optometrist (MKP). The images were then resized to 500x750 pixels. The pathologies were diagnosed by clinicians and image class labeling was done based on the diagnosis of retinal clinical experts at SN hospital.

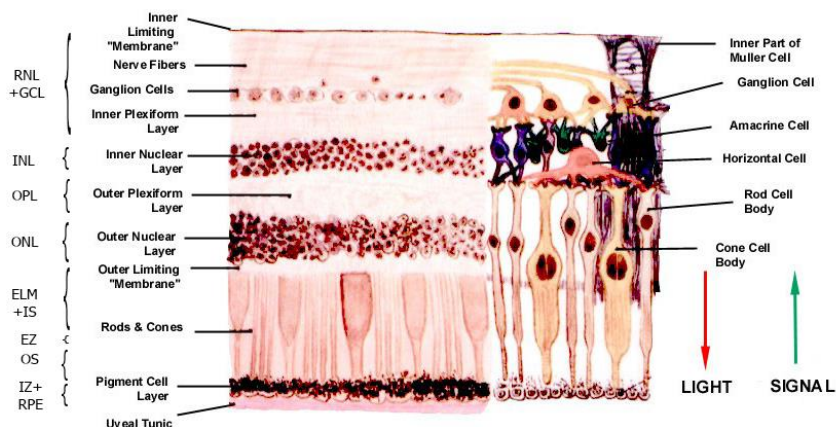


Figure 1. The structure of the normal retina with different retinal layers

Pathological conditions

In this section, we provide a brief discussion about each of the disease groups. These diseases account for over 25% of severe visual impairment causes [12,13] and affect different retinal layers. Figure 1 shows the structure of the normal retina with different layers indicated on it. In what follows, we present some general information about each disease and their symptoms:

- Diabetic retinopathy (DR), is one of the most leading causes of blindness in adults over the age of 65 years in the United States [14]. Due to diabetes, retinal blood vessels can break down, leak or become blocked. Diabetic macular edema can occur in any stage of DR and cause several changes to the morphology of retinal layers, including increased retinal thickness and focal retinal detachments. This is due to intra-retinal fluid accumulation and is indicated by reduced intra-retinal reflectivity. Other visible changes on OCT images include abnormal foveal contour, changes in the central macular thickness, and intra-retinal hyper-reflective exudates. [14].

- Age-related Macular Degeneration (AMD) is the leading cause for sever visual impairments and vision loss in Western countries. AMD affects the part of the retina responsible for sharp central vision, namely the macula. The OCT image for AMD usually appears with thickening of Retinal Pigment Epithelium (RPE) layer which results in the elevation of the photoreceptor layer and thickened, irregular, and disorganized retinal layers. Also, it usually causes fluid accumulation beneath the fovea and in some cases, the detachment of the RPE layer can occur [14].

- Macular Hole (MH) is also one of the other common age-related eye diseases and causes a decrease in visual acuity. MH retinal defects can vary from small hypoflective breaks to full-thickness intra-retinal spaces in the OCT images. Other signs include thickened edges with cavities of reduced reflectivity, macular edema, and fluid accumulation [14]. Furthermore, using OCT images one can understand the etiology of the MH disease.

- Central Serous Chorioretinopathy (CSC) is one of the common diseases of the middle age (third and fourth decade) that causes visual distortions and a decrease in visual acuity. It is characterized by focal detachments of the retina and the RPE layer due to the leakage of fluid into the retina through an RPE defect. On OCT, CSC appears as hypo reflective spaces at the sub-retinal and sub-RPE levels with

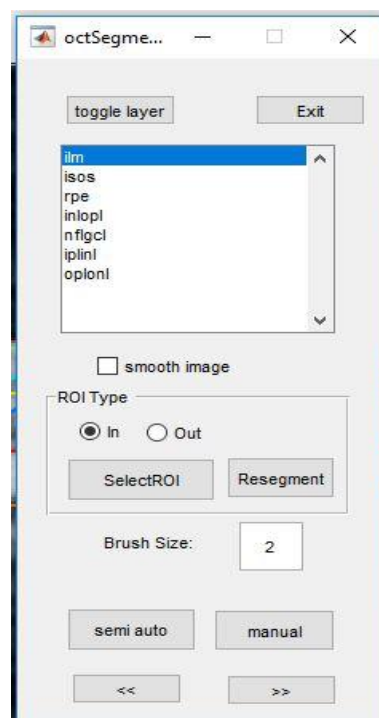


Figure 2: The Graphical user interface (GUI) for manual segmentation

occasional hyper-reflective deposits sub-retinally. OCT also helps in differentiating CSC from other confounding choroidal diseases [15].

Manual segmentation

We also included 25 normal images along with the corresponding ground truth delineations, which have been determined by an expert. The ground truth locations are added as MAT files in the database. The manual segmentation was done by an experienced clinician (MKP). In addition, to aid the novice user or clinician, we have developed an easy to use GUI (Figure 1) for use with the dataset. The clinician will have the ability to select the name of the boundary from the listing box. He/she can choose to re-segment the whole of that boundary manually by clicking on the “manual” button or re-segment only the erroneous portions within the boundaries by clicking on the “semi auto” button. After re-segmentation of all the layers is completed by the clinician, the “Exit” button is clicked, when it prompts the user whether the user wanted to save the new segmentation or not.

Database structure

Our database consisted of 102 MH, 55 AMD, 107 DR, and 206 NO retinal images. Figure 2 presents samples of each of the database classes. The database is available to the public at:

<https://dataverse.scholarsportal.info/dataverse/OCTID>

Each of the different classes have been categorized as a separate dataset and is available with a unique DOI link. The images can be viewed and downloaded separately or entirely as a zip file.

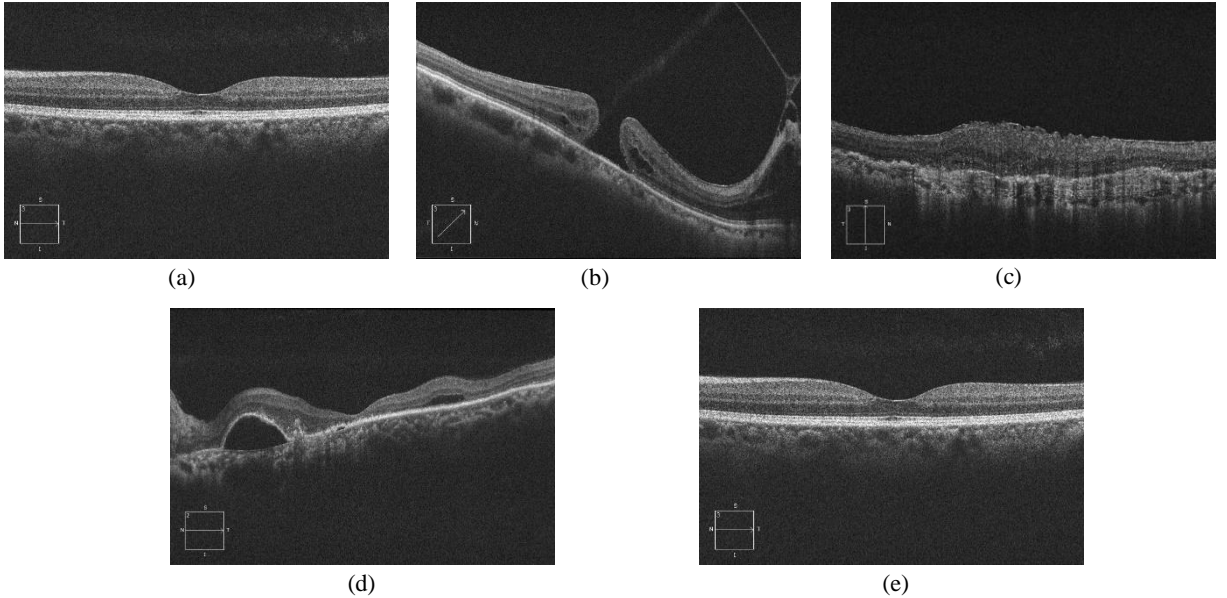


Figure 3: Sample of images in each class in the database (a) NO (b) MH (c) DR (d) CSR (e) AMD

3. Future Work and Conclusion

In this paper, we introduced an open access OCT image database (OCTID). This is one of the largest OCT databases that are currently available for researchers that provides a comprehensive collection of high-resolution images and is categorized based on pathological conditions. The ultimate goal for creating this database was to facilitate public access to OCT images in order to help researchers worldwide who want to develop computer-aided algorithms for the analysis of OCT images and might not have access to a sufficient number of good quality images. This is also important for researchers in deep learning developing neural networks for automated classification of diseases [16, 17]. Therefore, by removing such a barrier, we hope that more efficient techniques can be created, tested and validated which can be of use for accurate diagnosis.

In addition, we will further work on improving this database in order to create a much more comprehensive data set. We also have access to a number of images (greater than 100,000). We are in the process of examining and categorizing these images and incorporating them. Therefore, by establishing such a huge database, we can build novel neural networks and train them using these images. It is expected that by using such a large database, the performance of the neural network will increase dramatically, and we can create a highly reliable identification and classification technique for automated diagnosis of ocular diseases.

Acknowledgment

The authors would like to acknowledge Sankara Nethralaya (SN) eye hospital, Chennai, India, and in particular Dr. Muna Bhende and Ms. Girija for providing the images and diagnosing pathological conditions. This research is supported by an NSERC discovery grant to VL.

References

- [1] M. R. Hee, J. A. Izatt, E. A. Swanson, D. Huang, J. S. Schuman, C. P. Lin, C. A. Puliafito, and J. G. Fujimoto, "Optical Coherence Tomography of the Human Retina," *Arch. Ophthalmol.*, vol. 113, pp. 325–332, 1995.
- [2] J. S. Schuman, "Spectral domain optical coherence tomography for glaucoma (an AOS thesis).," *Trans. Am. Ophthalmol. Soc.*, vol. 106, pp. 426–58, 2008.
- [3] S. Yazdanfar, A. M. Rollins, and J. A. Izatt, "In vivo imaging of human retinal flow dynamics by color Doppler optical coherence tomography," *Archives of Ophthalmology*, vol. 121(2), pp. 235–239, 2003.
- [4] L. E. Kagemann, G. Wollstein, M. Wojtkowski, H. Ishikawa, K. A. Townsend, M. L. Gabriele, and J. S. Schuman, "Spectral oximetry assessed with high-speed ultra-high-resolution optical coherence tomography," *Journal of biomedical optics*, vol. 12(4), pp. 041212, 2007.
- [5] R. Rasti, H. Rabbani, A. Mehri, F. Hajizadeh, "Macular OCT Classification using a Multi-Scale Convolutional Neural Network Ensemble", *IEEE Transactions on Medical Imaging*, vol. 37, no. 4,

pp. 1024-1034, April 2018.

- [6] T. Mahmudi, R. Kafieh, H. Rabbani, "Comparison of macular OCTs in right and left eyes of normal people", Proc. SPIE 9038, Medical Imaging 2014: Biomedical Applications in Molecular, Structural, and Functional Imaging, 90381K, San Diego, California, United States Feb., pp. 15-20, 2014
- [7] S. Farsiu, S. J. Chiu, R. V. O'Connell, F. A. Folgar, E. Yuan, J. A. Izatt, and C. A. Toth "Quantitative Classification of Eyes with and without Intermediate Age-related Macular Degeneration Using Optical Coherence Tomography", *Ophthalmology*, vol. 121(1), pp. 162-172, Jan. 2014.
- [8] P. P. Srinivasan, L. A. Kim, P. S. Mettu, S. W. Cousins, G. M. Comer, J. A. Izatt, and S. Farsiu, "Fully automated detection of diabetic macular edema and dry age-related macular degeneration from optical coherence tomography images," *Biomedical Optics Express*, vol. 5(10), pp. 3568-3577, 2014
- [9] S. Sengupta, A. Singh, V. Lakshminarayanan, "Deep learning applications in ophthalmic diagnosis: a survey", to be submitted to *Pattern Recognition* 2018
- [10] S. J. Chiu, J. A. Izatt, R.V. O'Connell, K.P. Winter, C.A. Toth, S. Farsiu, "Validated Automatic Segmentation of AMD Pathology including Drusen and Geographic Atrophy in SDOCT Images", *Investigative Ophthalmology & Visual Science*, vol. 53(1), pp. 53-61, Jan. 2012.
- [11] L. Tang, M. K. Garvin, K. Lee, W. L. Alward, Y. H. Kwon, and M. D. Abramoff, "Robust Multi-Scale Stereo Matching from Fundus Images with Radiometric Differences," *IEEE Transactions on Pattern Analysis and Machine Intelligence*, vol. 33(11), pp. 2245, 2011.
- [12] R. R. Bourne, S. R. Flaxman, T. Braithwaite, M. V. Cicinelli, A. Das, J. B. Jonas, J. Keeffe, J. H. Kempen, J. Leasher, H. Limburg, and K. Naidoo, "Magnitude, temporal trends, and projections of the global prevalence of blindness and distance and near vision impairment: a systematic review and meta-analysis," *The Lancet Global Health*, vol. 5(9), pp. e888-e897, 2017.
- [13] V. Lakshminarayanan, The global problem of blindness and visual dysfunction, *Photonic Innovations and Solutions for Complex Environments and Systems (PISCES)*, edited by Akhlesh Lakhtakia, Judith A. Todd, Proc. of SPIE Vol. 8482, 84820A, 2012
- [14] J. S. Schuman, C. A. Puliafito, J. G. Fujimoto, and J. S. Duker, "Optical Coherence Tomography of Ocular Diseases". Online access: EBSCO eBook Clinical Collection. SLACK Incorporated, 2013.
- [15] B. Nicholson, J. Noble, F. Forooghian, and C. Meyerle, "Central serous chorioretinopathy: update on pathophysiology and treatment." *Survey of ophthalmology*, vol. 58(2), pp. 103-26, 2013.
- [16] H. Leopold, J. Zelek, V. Lakshminarayanan, *Deep Learning Methods Applied to Retinal Image Analysis in Signal Processing and Machine Learning for Biomedical Big Data*, ed. E. Sejdic and T. Falk, CRC Press, Pages 329-365, 2018.
- [17] P. Gholami, M.S. Hassani, M.K. Parthasarathy, J.S. Zelek, and V. Lakshminarayanan. "Classification of optical coherence tomography images for diagnosing different ocular diseases." In *Multimodal Biomedical Imaging XIII*, vol. 10487, p. 1048705. International Society for Optics and Photonics, 2018.